

## PDF hosted at the Radboud Repository of the Radboud University Nijmegen

The following full text is a publisher's version.

For additional information about this publication click this link.

<http://hdl.handle.net/2066/21364>

Please be advised that this information was generated on 2017-12-05 and may be subject to change.

## The value of parasternal mediastinoscopy in staging bronchial carcinoma

W. B. Barendregt<sup>1,\*</sup>, H. W. O. Deleu<sup>1</sup>, H. J. M. Joosten<sup>1</sup>, W. vd Berg<sup>2</sup>, J. P. Janssen<sup>2</sup>

<sup>1</sup> Department of General Surgery, Canisius Wilhelmina Hospital, Nijmegen, The Netherlands

<sup>2</sup> Department of Pulmonology, Canisius Wilhelmina Hospital, Nijmegen, The Netherlands

**Abstract.** Computed tomography (CT) is the non-invasive staging procedure of choice for assessment of metastasis to mediastinal lymph nodes in patients with bronchial carcinoma. Cervical mediastinoscopy can provide histologic evidence of mediastinal spread to the peritracheal, tracheobronchial and subcarinal lymph nodes. Subaortic and para-aortic nodes cannot be sampled via this route. The present study was performed to assess the staging value of the parasternal mediastinoscopy as a separate entity. Cervical and parasternal mediastinoscopy was performed in 37 patients with a proven diagnosis of non-small cell carcinoma of the left upper lobe. In 16 patients lymph node or tumor tissue could be biopsied via the parasternal route, in 21 patients no parasternal biopsy was taken. Of the 16 cases with biopsies, only one was positive (6%). Histologic examination of lymph node biopsy tissue was false negative in one other patient (6%). Of the 21 patients without biopsies taken during parasternal mediastinoscopy, three (14%) had proven lymphogenic spread to the subaortic and para-aortic nodes, detected at thoracotomy. The parasternal procedure changed treatment in only one patient (3%). Diagnostic sensitivity was 20%. It is concluded that parasternal mediastinoscopy should not be used as a routine staging procedure in patients with left upper lobe lung cancer. [Eur J Cardio-thorac Surg (1995) 9: 655–658]

**Key words:** Parasternal – Mediastinoscopy – Lung cancer

The value of mediastinoscopy in the preoperative assessment of bronchial carcinoma is a subject of ongoing discussion. Cervical mediastinoscopy should be used for staging in the case of a so-called positive computed tomography (CT) scan (mediastinal lymph nodes of 1.5 cm diameter or larger, or a group of nodes each 1.0 cm or larger) [4]. Histologic evidence of mediastinal metastasis is mandatory in all cases of enlarged nodes on CT scan.

The value of parasternal (anterior) mediastinoscopy or mediastinotomy has been discussed in only a few recent publications [1, 4, 5, 8, 11, 14]. In many instances no difference is made between the staging value of the cervical and the parasternal procedure. Due to the route of lymphogenic spread, the parasternal mediastinoscopy is supposed to be important in the preoperative assessment of left upper

lobe tumors [3, 10, 15]. The benefit of cervical mediastinoscopy is limited to patients with central mediastinal involvement. Parasternal mediastinotomy is an alternative procedure, but is apparently more invasive than mediastinoscopy. The extended cervical mediastinoscopy, as advocated by Ginsberg, is not practised by many surgeons [1]. In some institutes the attitude towards mediastinoscopy in general, and towards parasternal mediastinoscopy in particular, appears to have changed. This is partly due to the development of improved CT imaging techniques, which show mediastinal structures with a higher definition than 5 or 10 years ago.

In order to reassess the value of the staging of lymphogenic spread of bronchial carcinoma by parasternal mediastinoscopy, the results of a 3-year period are described.

### Materials and methods

A retrospective study was performed, analyzing the results of all patients who had undergone a parasternal mediastinoscopy as a preoperative staging procedure in bronchial carcinoma in the 3-year period 1990–1992. In this period all patients with proven non-small cell lung cancer (NSCLC) of the left upper lobe (above stage T1- and in

Received for publication: August 4, 1994

Accepted for publication: March 24, 1995

\* *Present address:* Department of General and Vascular Surgery, St. Radboud University Hospital, PO. Box 9101, 6500 HB Nijmegen, The Netherlands

*Correspondence to:* Dr. W. B. Barendregt



all cases of adenocarcinoma), and without signs of metastatic disease or local non-resectability, underwent a cervical and a parasternal mediastinoscopy; the patient's general condition had to permit a thoracotomy and resection if the results were found to be negative.

During the procedure of mediastinoscopy the cervical route was always employed first. The parasternal or anterior mediastinoscopy was performed before closure of the cervical wound so that bi-digital palpation was possible. A small left parasternal incision through the second intercostal space, without resection of costal cartilage, was used to allow a palpating finger and a mediastinoscope. Biopsies were only taken in the case of visible or palpable lymph nodes or tumor. The clinical data of 37 patients were investigated, together with the results from X-ray studies, mediastinoscopy and thoracotomy reports and histologic findings.

## Results

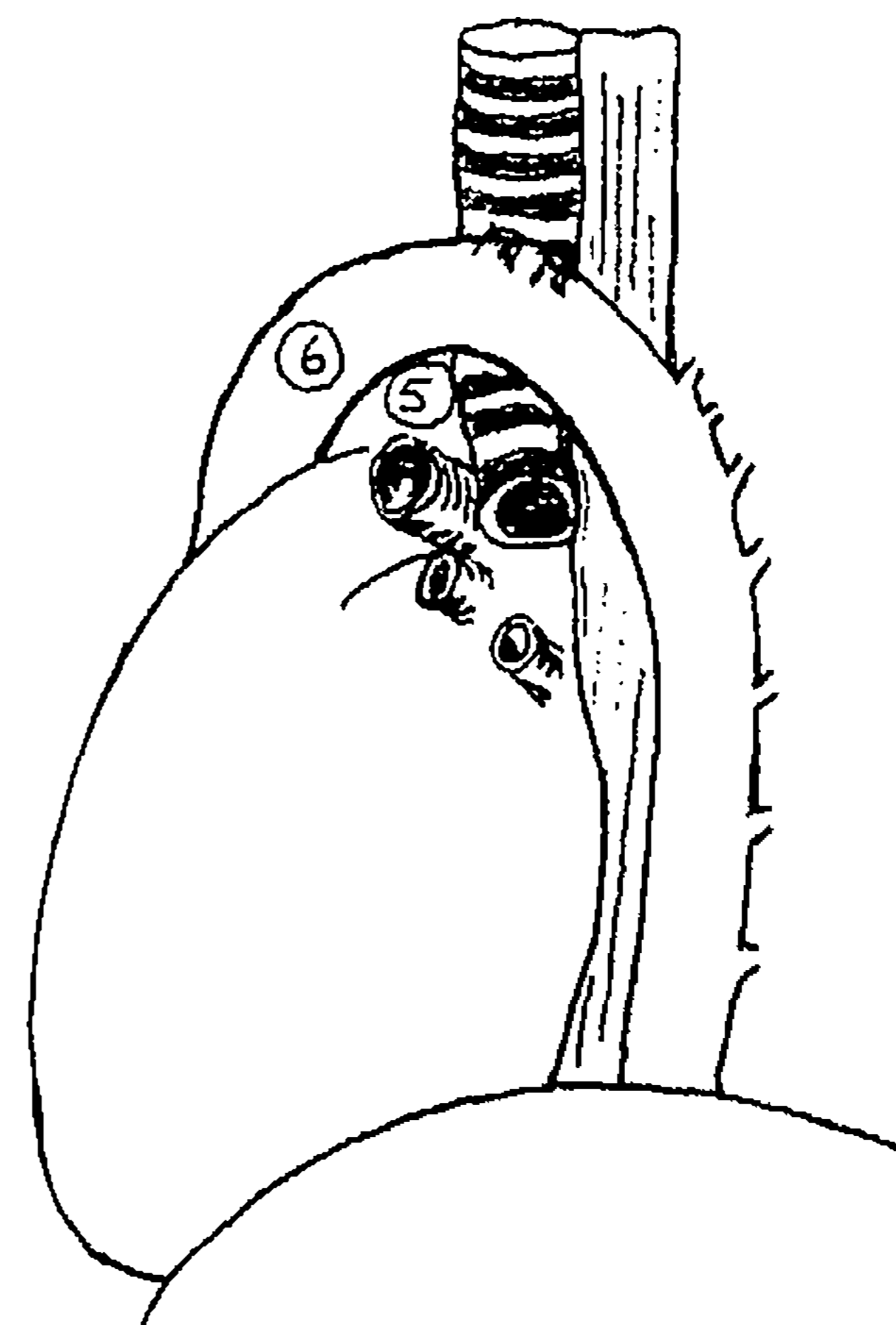
The group consisted of 34 men and 3 women. The mean age was 64.3 years. All patients had a proven left upper lobe bronchial carcinoma. Twenty-eight tumors were squamous cell carcinomas, six were adenocarcinomas and three were non-small cell undifferentiated carcinomas. Table 1 depicts pathological tumor stages as assessed retrospectively for all patients. Table 2 shows N-stages after CT scan and cervical plus parasternal mediastinoscopy versus N-stages after thoracotomy with definitive histologic investigation. In three patients the CT scan results were not available for our study. In only 16 cases of 37 (43%) parasternal mediastinoscopies was a biopsy of a lymph node or supposed tumor tissue taken. In the remaining 21 patients no lymph node or tumor was seen or palpated. Five patients had histologically proven tumor metastases in the subaortic or para-aortic lymph nodes (Fig. 1, Stations 5 and 6) according to definitive staging after thoracotomy. Of the 16 patients who underwent a prethoracotomy parasternal biopsy only one had a histologically proven adenocarcinoma in the specimen, the cervical mediastinoscopy was negative. One patient had a false negative parasternal biopsy result. Of the 21 patients who underwent parasternal mediastinoscopy without biopsy three had false negative results according to definitive

**Table 1.** pTN stages in 37 patients. Definitive tumor stages. Patients with distant metastases ( $M_1$ ) are not presented in this study

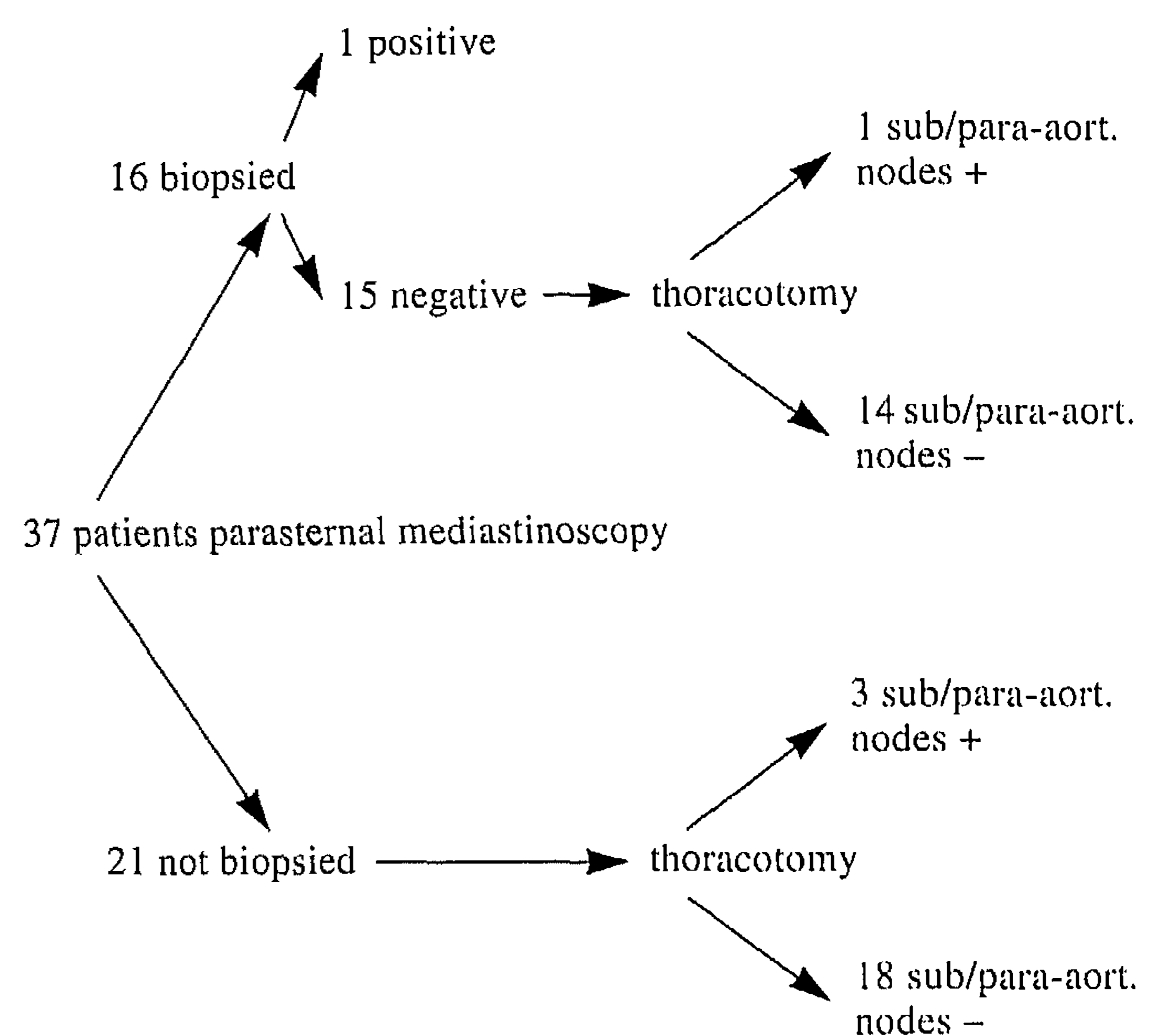
Stage I :	16 patients (T1N0 2, T2N0 14)
Stage II :	6 patients (T2N1 6)
Stage IIIa :	12 patients (T2N2 7, T3N0 1, T3N1 1, T3N2 3)
Stage IIIb :	3 patients (T4N0 1, T4N2 2)

**Table 2.** N-stages after CT and cervical plus parasternal mediastinoscopy versus definitive N-stages. Comparison of clinical lymph node staging with staging after thoracotomy showed understaging of the former. N2 disease in this table concerns metastatic spread to sub- or para-aortic nodes and/or to other N2 lymph node stations

	CT + mediastinoscopy	Definitive
N0 or N1	29	25
N2	5	12
no CT available	3	



**Fig. 1.** Schematic drawing of left lateral view of the mediastinum with subaortic (5) and para-aortic (6) lymph nodes. Numbers according to American Joint Committee on Cancer, classification of regional lymph nodes



**Fig. 2.** Flow diagram showing the numbers of procedures and the histologic results

staging at thoracotomy with sub- and para-aortic lymph nodes positive (Fig. 2, flow diagram).

The sensitivity of the parasternal mediastinoscopy was 20%: of the five patients with metastases to sub- and para-aortic lymph nodes, only one was detected before thoracotomy. The patient with positive parasternal biopsy result did not undergo resection, but in no other patient was treatment influenced by parasternal mediastinoscopy. The negative predictive value was 89%.

In ten cases (27%) the pleural cavity was inadvertently opened and three were treated with short-term drainage. The combined procedure had a mean duration of 63 min (range 45–90) compared to 43 min (range 30–60) for the cervical mediastinoscopy alone, as performed in our institution in patients with a bronchial carcinoma not located in the left upper lobe.

Computer tomography scan imaging of the sub- and para-aortic area in these 37 patients proved to be false neg-



ative in two patients (sensitivity 60%; five patients had lymphatic metastasis to sub- and para-aortic nodes). In four cases enlarged sub- and para-aortic lymph nodes on CT scan were found to be negative at histologic examination of biopsy specimens during thoracotomy. Parasternal mediastinoscopy had been negative in these patients. According to CT scan the sub- and para-aortic lymph nodes were true positive in 2 patients and true negative in 26 patients; in three patients CT scan was not available.

## Discussion

From the results of this study it appears that the parasternal mediastinoscopy does not add valuable information to preoperative staging in most cases. A negative predictive value of 89% and a sensitivity of 20% are too low to justify the parasternal mediastinoscopy as a routine procedure in patients with a left upper lobe or left main bronchus carcinoma. The added parasternal procedure changed treatment in only one patient (3%). It may even be argued that patients with subaortic or para-aortic lymph node metastasis without any further mediastinal dissemination will benefit from complete surgical resection [12, 18].

The high false negative rate could be explained by the fact that the procedure is not very easy to perform, due to lack of a clearly visible point of anatomic reference, such as the trachea in cervical mediastinoscopy. Too often no lymph nodes were found and not even a biopsy was taken. Sometimes, fatty tissue prohibited a clear view on any lymph nodes in the dangerous sub- and para-aortic area. Higher biopsy ratios can probably only be reached in highly specialized units, resulting in prolonged procedures. In most institutes other staging procedures will be beneficial, for instance a parasternal mediastinotomy. A higher morbidity may be associated with this technique, although Vallières et al. described the use of parasternal mediastinotomy on an ambulatory basis [17]. If an aggressive surgical approach towards isolated sub- and para-aortic metastasis is adopted, a parasternal mediastinoscopy can be omitted, whereas in doubtful cases a parasternal mediastinotomy is to be preferred to this procedure. The use of extended cervical mediastinoscopy is limited by the same difficult anatomic orientation as the parasternal mediastinoscopy [1]. The authors have no personal experience with the extended cervical procedure.

In our series CT scan, usually performed without the use of intravenous contrast, could not clearly differentiate between N0 or N1 and N2 disease. The reported sensitivity of mediastinal lymph node staging by CT scan is approximately 60–80% [4, 9, 13, 19]. It is to be expected that modern CT scanning techniques, with the addition of intravenous contrast studies, will indicate whether a patient could benefit from a cervical mediastinoscopy or a parasternal procedure [7, 16]. The overall accuracy of CT scanning in preoperative staging of the entire mediastinum was not studied here.

Video-assisted thoracoscopy, a rapidly developing minimally invasive surgical technique, could be useful in staging the mediastinum, especially the sub- and para-aortic lymph nodes [2, 6]. It offers a better view of the medias-

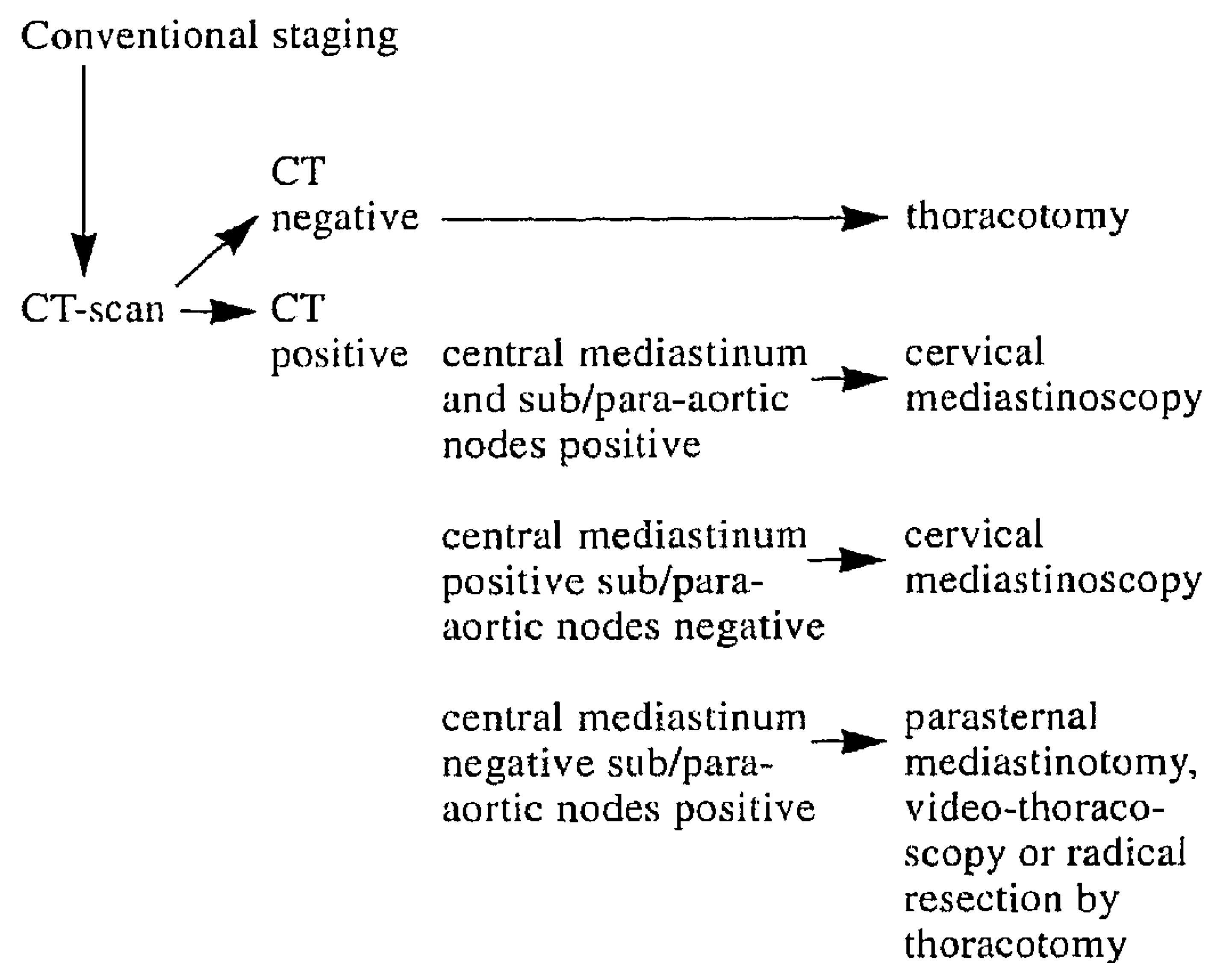


Fig. 3. Proposed decision tree for mediastinal staging in resectable left upper lobe lung cancer

tinum and could thus be a more complete staging procedure than the parasternal (anterior) mediastinoscopy. Video-assisted thoracoscopy is probably comparable to parasternal mediastinoscopy in its postoperative morbidity and it is less invasive than a parasternal mediastinotomy with resection of costal cartilage. Its accuracy in lung cancer staging has still to be settled.

The results of this study indicate that histologic staging in left upper lobe lung cancer should not be done by parasternal mediastinoscopy. In cases with central mediastinal nodes on CT scan, a cervical mediastinoscopy is the procedure of choice. In cases of isolated enlarged sub- or para-aortic nodes, a parasternal mediastinotomy or a video-assisted thoracoscopy is indicated to obtain histologic evidence, unless a resection with curative intent is planned (Fig. 3, decision tree). We therefore conclude that the parasternal mediastinoscopy is not valuable as a routine staging procedure in bronchial carcinoma. Only in cases of isolated sub- or para-aortic lymph node involvement according to CT scan, not in combination with central mediastinal lymph node involvement, could sampling via the parasternal route lead to a change in management.

## References

1. Ginsberg RJ (1994) The role of preoperative surgical staging in left upper lobe tumors. *Ann Thorac Surg* 57:526–527
2. Hazelrigg SR, Mack MJ, Landreneau RJ (1993) Video-assisted thoracic surgery for mediastinal disease. *Chest Surg Clin of North Am* 3(2):293–295
3. Jolly PC, Li W, Anderson RP (1980) Anterior and cervical mediastinoscopy for determining operability and predicting resectability in lung cancer. *J Thorac Cardiovasc Surg* 79:366–371
4. Jolly PC, Hutchinson CH, Detterbeck F, Guyton SW, Hofer B, Anderson RP (1991) Routine computed tomographic scans, selective mediastinoscopy, and other factors in evaluation of lung cancer. *J Thorac Cardiovasc Surg* 102:266–271
5. Lacquet LK, Schreinemakers JH (1990) Combined cervical and left parasternal mediastinoscopy for pre-operative staging of left upper lobe lung cancer. *Acta Chir Belg* 90(1):5–8

6. Landreneau RJ, Hazelrigg SR, Mack MJ, Fitzgibbon LD, Dowling RD, Acuff TE, Keenan RJ, Ferson PF (1993) Thoracoscopic mediastinal lymph node sampling: useful for mediastinal lymph node stations inaccessible by cervical mediastinoscopy. *J Thorac Cardiovasc Surg* 106:554–558
7. Layer G, Knopp M, Van Kaick G (1991) Der Beitrag der modernen Schnittbildverfahren CT, MRT und PET zur Diagnostik des Bronchialkarzinoms. In: Drings P, Vogt-Moykopf I (eds) *Thoraxtumoren. Diagnostik-Staging-gegenwärtiges Therapiekonzept*. Springer Verlag, Heidelberg, pp 109–122
8. Malenka DJ, Colice GL, Beck JR (1991) Does the mediastinum of patients with non-small cell lung cancer require histologic staging? *Am Rev Respir Dis* 144:1134–1139
9. McCloud TC, Bourgouin PM, Greenberg RW, Kosiuk JP, Templeton PA, Shepard JA, Moore EH, Wain JC, Mathisen DJ, Grillo HC (1992) Bronchogenic carcinoma: analysis of staging in the mediastinum with CT by correlative lymph node mapping and sampling. *Radiology* 182:319–323
10. Merav AD (1991) The role of mediastinoscopy and anterior mediastinotomy in determining operability of lung cancer: a review of published questions and answers. *Cancer Invest* 9: 439–442
11. Miller JD, Gorenstein LA, Patterson GA (1992) Staging: the key to rational management of lung cancer. *Ann Thorac Surg* 53:170–178
12. Patterson GA, Piazza D, Pearson FG, Todd TR, Ginsberg RJ, Goldberg M, Waters P, Jones D, Ilves R, Cooper JD (1987) Significance of metastatic disease in subaortic lymph nodes. *Ann Thorac Surg* 43:155–159
13. Patterson GA, Ginsberg RJ, Poon PY, Cooper JD, Goldberg M, Jones D, Pearson FG, Todd TR, Waters P, Bull S (1987) A prospective evaluation of magnetic resonance imaging, computed tomography and mediastinoscopy in the preoperative assessment of mediastinal node status in bronchogenic carcinoma. *J Thorac Cardiovasc Surg* 94:679–684
14. Pearson FG (1993) Staging of the mediastinum. Role of mediastinoscopy and computed tomography. *Chest* 103:346S–348S
15. Schreinemakers JHJ (1985) *Parasternal mediastinoscopy*. Thesis, Nijmegen
16. Shields TW (1990) The significance of ipsilateral mediastinal lymph node metastasis (N2 disease) in non-small cell carcinoma of the lung. *J Thorac Cardiovasc Surg* 99:48–53
17. Vallières E, Pagé A, Verdant A (1991) Ambulatory mediastinoscopy and anterior mediastinotomy. *Ann Thorac Surg* 52:1122–1126
18. Watanabe Y, Hayashi Y, Shimizu J, Oda M, Iwa T (1991) Mediastinal node involvement and the prognosis of non-small cell lung cancer. *Chest* 100:422–428
19. Webb WR, Gatsonis C, Zerhouni E, Heelan RT, Glazer GM, Francis IR, McNeil BJ (1991) CT and MR imaging in staging non-small cell bronchogenic carcinoma: report of the Radiologic Diagnostic Oncology Group. *Radiology* 178:705–713