

PDF hosted at the Radboud Repository of the Radboud University Nijmegen

The following full text is a publisher's version.

For additional information about this publication click this link.

<http://hdl.handle.net/2066/20983>

Please be advised that this information was generated on 2017-12-05 and may be subject to change.

Radiolabeled monoclonal antibody G250 in renal-cell carcinoma

E. Oosterwijk and F. M. J. Debruyne

Department of Urology, Academic Hospital Nijmegen, The Netherlands

Summary. The current status of iodine 131-radiolabeled monoclonal antibody G250 (mAb G250) in renal-cell carcinoma (RCC) is described. This mAb recognizes a tumor-associated antigen that is expressed on the cell surface of almost all RCC but is not expressed on normal tissues, with the exception of gastric mucosa and larger bile ducts. On the basis of these favorable characteristics, this mAb seemed a prime candidate for clinical investigations. Preclinical animal studies and *ex vivo* perfusion experiments in tumor-bearing kidneys showed excellent targeting of mAb G250 to RCC tumors. Supported by these investigations, a phase I study was initiated to define the imaging and biodistribution characteristics of ¹³¹I-labeled mAb G250 in RCC patients. Specific localized of [¹³¹I]-mAb G250 to G250-antigen-positive primary and metastatic RCC was observed. In several patients, [¹³¹I]-mAb G250 imaging revealed thus far unrecognized, i.e., occult, disease. Values obtained for [¹³¹I]-mAb G250 uptake, relative as well as absolute, were among the highest reported for tumor biopsies obtained 8 days after intravenous mAb administration. The specific localization and high accumulation encouraged us to begin a phase I/II radiotherapy trial with [¹³¹I]-mAb G250. The maximal tolerable dose was reached at 90 mCi/m² [¹³¹I]-mAb G250. In the subsequent phase I/II radiotherapy study, we observed stable disease in a great number of patients as well as minor responses in a small number of patients. Multiple treatments seemed necessary to achieve better response rates. However, anti-mouse responses prevented multiple dosing with the murine mAb G250. Therefore, we developed a chimeric version of mAb G250 (cG250), in which constant regions of the mouse immunoglobulin have been exchanged for human immunoglobulin regions. A phase I clinical trial with cG250 is ongoing and very encouraging. The general imaging and targeting characteristics of cG250 seem comparable with those of murine mAb G250. In the near future the (radio)therapeutic possibilities of this promising mAb will be investigated.

Correspondence to: E. Oosterwijk, Urological Research Laboratory, Department of Urology, Academic Hospital Nijmegen, Geert Grooteplein Zuid 16, P.O. Box 9101, NL-6500 HB Nijmegen, The Netherlands, Fax: +31 (80) 541031

Monoclonal antibodies in renal-cell carcinoma

Since the development of technologies to generate monoclonal antibodies (mAbs) [10], much effort has been focused on the isolation of mAbs reactive with tumor antigens for diagnostic and therapeutic applications [7, 8, 11, 12, 16]. For tumor immunologists, the old dream of harnessing the exquisite specificity of antibodies to bind to tumor-specific antigens and, thereby, to kill tumor cells, seemed finally within reach. However, in spite of intense research, the isolation of clinically relevant mAbs has been disappointing, mainly because of a lack of true tumor specificity. Preferably such mAbs are reactive with tumor-specific antigens (TSA) expressed by all tumor cells of a certain tumor type. However, unequivocal evidence for unique TSA in human malignancies remains lacking. Most human malignancies have weak, if any, detectable immunogenic properties, indicating that most human cancers either are nonimmunogenic or mediate strong immunomodulatory effects. Current mAbs of interest recognize tumor-associated antigens (TAA), which are either differentiation antigens that are (transiently) expressed during organogenesis or aberrantly expressed antigens that are (transiently) expressed elsewhere in nonrelated normal tissue(s).

A significant number of mAbs reactive with cell-surface antigens of renal-cell carcinoma (RCC) have been identified [1, 6, 9, 15, 19, 20, 24, 30, 35]. Their specificity has been established primarily by immunohistochemistry. Less is known about their targeting abilities and their therapeutic efficacy. The anti-RCC mAbs can be divided into two groups: mAbs recognizing differentiation antigens [1, 6, 9, 15, 20, 24, 30, 35] and mAbs recognizing RCC-TAA aberrantly expressed in RCC, i.e., recognizing an RCC antigen absent from normal kidney [6, 9, 15, 19, 30]. MAb of the latter category in general show very restricted cross-reactivity with normal tissues as judged by immunohistochemistry. It is likely that these mAbs identify different RCC-TAA, since they display different reactivity with normal tissues. The number of RCC-TAA is remarkably high in comparison to TAA identified in other tumor types, with the exception of melanoma. It is tempting to speculate that these RCC-TAA function as targets

of the (abortive) antitumor response that is sometimes observed in RCC patients. In view of the restricted cross-reactivity with normal tissues in combination with expression of a given RCC-TAA in most RCC, these mAbs are prime candidates for clinical investigations.

Monoclonal antibody G250

One of the mAbs recognizing an RCC-TAA, mAb G250, was obtained after fusion of spleen cells from a mouse immunized with fresh RCC homogenates [19]. Initially, G250 antigen expression was examined in 55 RCC; 42/47 primary RCC showed homogeneous G250 antigen expression (89%), 4 tumors showed heterogeneous G250 antigen expression, and only 1 primary tumor was completely G250-antigen-negative. More importantly, of 8 metastases examined, 5 showed homogeneous G250 expression (62%), 2 showed heterogeneous G250 expression, and 1 failed to express G250 antigen [19]. With increased numbers of RCC being tested, no difference with respect to the percentage of RCC expressing G250 antigen has been observed; in 77/95 primary RCC investigated, more than 50% of tumor cells were scored positive (81%), and in an additional 8 primary RCC, tumor cells were stained, albeit with lower frequency, i.e., approximately 90% of primary RCC express G250 antigen. For the metastatic lesions, G250-positive tumor cells were noticed in 18 of 22 tumors (82%) examined, with homogenous staining occurring in 9 of 17 metastatic RCC examined (53%). In general, clear-cell RCC tend to show homogenous G250 antigen expression, whereas non-clear-cell RCC show heterogeneous G250 expression. This RCC-TAA is absent from normal kidney and other normal tissues examined, with the exception of gastric mucosal cells and cells of the larger bile ducts. This antigen therefore meets closely the criteria for mAbs that might have clinical use.

Preclinical investigations

The targeting ability of mAb G250 was investigated in an RCC xenograft model [26]. BALB/c nu/nu mice xenografted with human RCC and/or human non-RCC tumors were injected with ¹²⁵I-labeled mAb G250 IgG1, F(ab')₂, or Fab' [26]. Specific mAb G250 accumulation was observed for all antibody forms. G250-negative tumors did not show any mAb G250 uptake, nor did the G250-positive tumors show increased uptake of nonrelevant immunoglobulin. Tumor/blood ratios were high in comparison with those obtained in other targeting studies in mice. Chiou et al. [4] studied mAb A6H, which is reactive with a normal kidney-differentiation antigen, and found comparable, relatively high tumor/blood ratios. This finding may be related to a general increase in the permeability of the vascular bed in RCC xenografts [23].

Higher mAb G250 uptake was generally found with intact immunoglobulin than with mAb G250 F(ab')₂ or Fab' fragments, associated most probably with the longer retention of the complete IgG, leaving the antibody more time to diffuse to the tumor cells. The lowest uptake was

observed for Fab' fragments, related to their short biological half-life and lower avidity.

In addition to mouse targeting studies, tumor-bearing human kidneys were perfused *ex vivo* with radiolabeled mAb G250 [25]. After flushing of the specimens with preservation fluid immediately after surgery, the kidneys were perfused with ^{99m}Tc-labeled mAb G250. [^{99m}Tc]-mAb G250 imaging of tumor-bearing kidneys resulted in clear images of RCC, with no mAb G250 uptake being observed in normal renal tissue. Despite the low temperature (0°–4°C to assure appropriate pressures) and the relatively short circulation time (16 h), tumor-to-kidney ratios were approximately 8:1 [25].

Clinical experience

Significant clinical experience with radiolabeled murine mAbs that detect TAA has been acquired in the last decade [7, 8, 11, 12, 16]. Radioimmunoscintigraphy studies of RCC with mAbs have been limited, generally being restricted to animal models [3, 4, 22, 26, 32, 33]. In a clinical study, Vessella et al. [29, 31] examined the imaging/radiotherapeutic ability of mAb A6H in RCC patients. Only in 5 of 15 patients examined were positive images obtained. This low number of positive images was attributed to the presence of circulating antigen and the formation of antigen-antibody complexes. The number of positive images increased with an altered dosing schedule, but the number of imaged lesions remained unsatisfactory. The poor performance of A6H is probably partly attributable to the cross-reactivity with normal tissues, which bind antibody, thereby hampering tumor uptake and influencing image quality.

On the basis of our targeting studies in RCC-bearing mice and in *ex vivo*-perfused tumor-bearing kidneys, we have performed a phase I protein dose-escalation study with ¹³¹I-labeled mAb G250 [21]. The primary study objectives were evaluation of the toxicity, pharmacokinetics, and localization capabilities of [¹³¹I]-mAb G250. As demonstrated by magnetic resonance imaging (MRI) and computed tomography (CT) scans more than 90% of primary and metastatic disease was imaged by [¹³¹I]-mAb G250. Metastatic lesions in lymph nodes, bone, and lung were visualized. Furthermore, additional metastatic disease documented at surgery but not detected by MRI and CT scans was visualized. For example, radioimmunoscintigraphy with [¹³¹I]-mAb G250 showed a small hot spot in the liver of one of the patients that was not visualized by other means. The patient showed recurrence of RCC at the [¹³¹I]-mAb G250-defined hot spot 9 months later. [¹³¹I]-mAb G250 imaging also revealed diffuse uptake in a polycystic kidney of another patient. On the basis of MRI and CT the process in the polycystic kidney was deemed benign. Nevertheless, as based on the [¹³¹I]-mAb G250 findings, surgery was performed at the patient's request, and diffuse metastatic RCC was found.

The images obtained by [¹³¹I]-mAb G250 were unusually clear in comparison with other mAb images, with virtually no background. The only exception was liver uptake at the lowest dose levels. However, this liver uptake

was completely saturable, and at the 10-mg dose level and higher, no normal organ uptake was observed. The smallest lesion visualized was 8 mm in diameter (estimate by CT). From the ability of mAb G250 to yield sharp images and visualize small tumor lesions, it was concluded that mAb G250 has considerable potential as an imaging agent. However, not all primary or metastatic RCC lesions express G250 antigen, or they express it in only a minority of cells. This emphasizes the need for additional RCC-specific mAbs because problems of antigen heterogeneity have to be overcome for therapeutic efficacy.

The absorbed dose to the tumor delivered by the best mAb/radionuclide combination studies thus far has been calculated at 2000–3000 cGy, whereby toxic effects of less than grade IV have been maintained [27, 28]. Vaughan et al. [27, 28] concluded that the tumor uptake should be increased by a factor of 10 for effective therapy. Calculation of the maximal fraction of the injected dose of [¹³¹I]-mAb G250 recovered in tumor sites showed that this was generally 10–100 times greater than the previously reported accumulation of radiolabeled mAb in solid tumors. Similar absolute amounts of [¹³¹I]-mAb G250 accumulated in G250-positive tumors, irrespective of the protein dose. Whether this was a reflection of tumor saturation is unclear. Nevertheless, the finding that the mean accumulation of the delivered dose, relative as well as absolute, was approximately 10-fold that of previously reported mAb/radionuclide combinations indicates that mAb G250 fulfills the requirements of Vaughan et al.

On the basis of these findings, a phase I/II trial with escalating doses of ¹³¹I labeled to 10 mg mAb G250 was initiated in patients with inoperable metastatic RCC [5]. Thus far, 21 patients have been treated and 90 mCi/m² ¹³¹I has been defined as the maximal tolerable dose. Targeting of radioactivity to all known sites of disease was seen in all G250-antigen-positive patients (19/21). Elevation of hepatic enzymes was observed in 18 patients, starting at approximately 10 days after treatment and returning to baseline by 3 weeks posttreatment. This elevation is probably attributable to mAb G250 accumulation in the liver, where G250 antigen is expressed by large-bile-duct epithelium. Examination of liver biopsies obtained in the phase I protein dose-escalation trial revealed mAb G250 accumulation in bile-duct epithelium. However, the amount of mAb G250 necessary to saturate the hepatic compartment was minimal and was estimated to be in the range of 200 µg. Nevertheless, this amount seems to be sufficient to induce mild liver toxicity on labeling at a higher specific activity. Administration of 75 mCi/m² [¹³¹I]-mAb G250 resulted in reversible grade IV thrombocytopenia in 1/6 patients,

with the nadir occurring at 4 weeks. Similar toxicity was observed in 2/3 patients treated with 90 mCi/m². No other toxicity was seen. No response was observed, but stable disease was noted in 11 patients at up to 9 months post-radioimmunotherapy. In general, these patients presenting with disseminated inoperable progressive RCC tend to do very poorly. In the subsequent phase II radioimmunotherapy study, patients received 90 mCi/m² [¹³¹I]-mAb G250 labeled to 10 mg protein. The side effects were identical to those seen in the phase I radioimmunotherapy trial. Minor responses were seen in 3 patients, 2 of whom had multiple lung metastases (C. R. Divgi, personal communication).

Improved therapeutic efficacy might be achievable by a multiple dosing schedule. However, administration of the murine mAbs elicited a human anti-mouse antibody (HAMA) response, preventing repeated administration. For repeated administration, e.g., multiple radioimmunotherapy or multiple treatment with naked antibody to induce antibody-dependent cellular cytotoxicity (ADCC), HAMA responses need to be minimized because circulating HAMA reduces the tumor uptake of mAb on subsequent administration due to mAb-HAMA cross-linking. With recombinant technology, mouse mAb G250 variable regions were grafted into human Ig constant regions. These constructs were transfected into mammalian cells, which

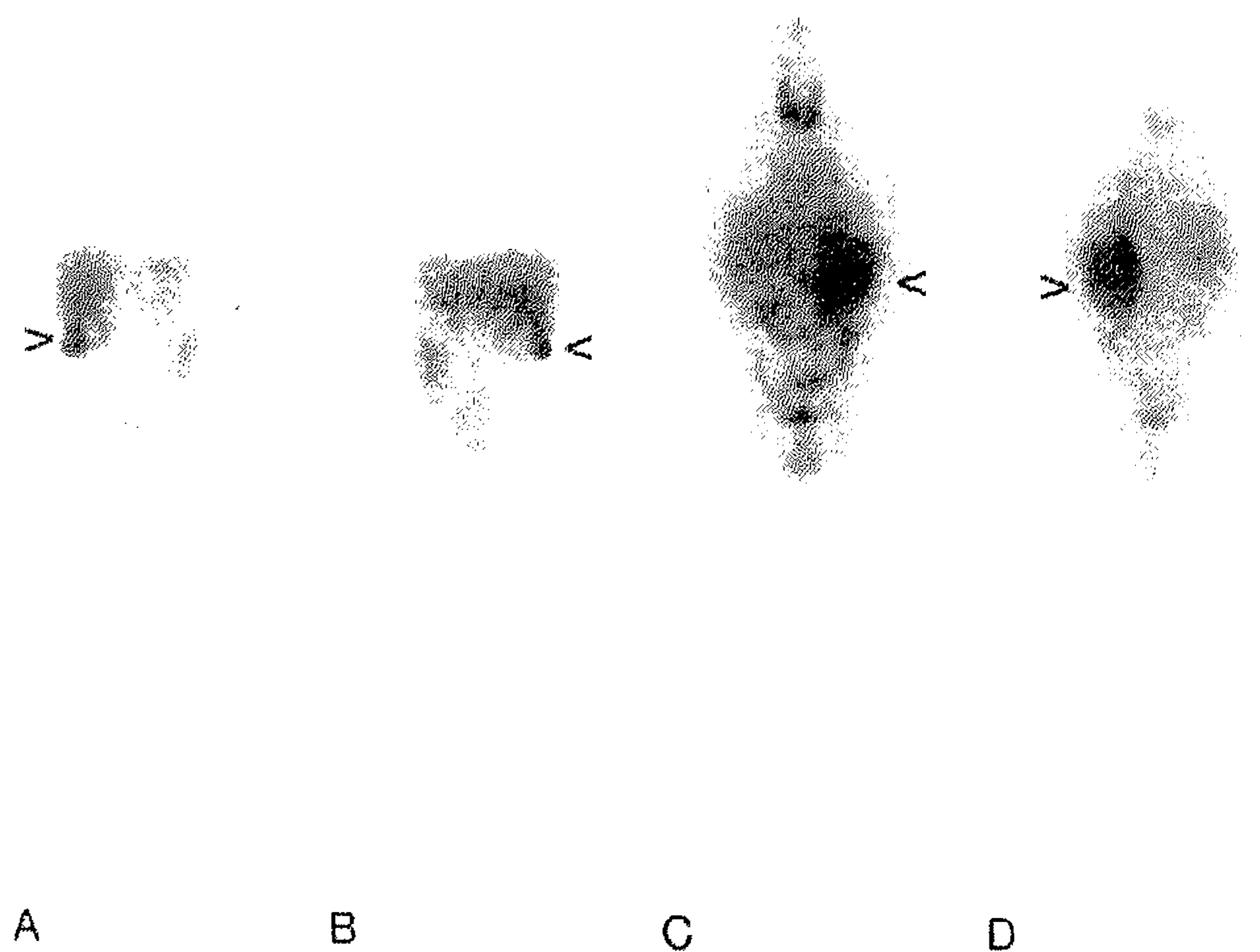


Fig. 1. A, C Anterior and B, D posterior whole-body images of RCC patients receiving A, B 2 or C, D 5 mg ¹³¹I-labeled chimeric mAb G250 obtained at 7 days after administration. The relative liver uptake decreases with increasing [¹³¹I]-cG250 dose. Tumor imaging is evident at both dose levels. Arrowheads point to the tumor masses

Table 1. Comparison of murine and chimeric mAb G250 uptake at the 2-mg dose level

Tissue	% Injected dose/kg		Ratio					
	Chimeric	murine	Tissue/serum		Tissue/liver		Tissue/kidney	
	Chimeric	murine	Chimeric	murine	Chimeric	murine	Chimeric	murine
RCC	342–32	112–9	924–87	178–14	65–6	18–1	1710–160	285–22
RCC	76–7	13–3	190–19	14–4	21–2	3–1	190–19	36–9
RCC	7–5	5–1.5	3–2	4–1	6–4	2–1	15–11	8–2
Necrosis	0.9–0.5	0.5	1.1	0.4	0.1	0.2	2	0.8

then produced chimeric immunoglobulin [17, 18, 34]. Substitution of the mouse F_c part by human F_c produces the additional advantage that all F_c -related effector functions match the human effector cells. Principally, the use of chimeric IgG should augment ADCC-mediated tumor cell lysis, and unmodified chimeric mAb might be suitable to destroy (minimal) residual disease. Chimerized antibodies are expected to be less immunogenic in humans, allowing multiple treatments.

The chimeric form of mAb G250 (c-G250, IgG1 subclass) is currently being tested in a phase I protein dose-escalation trial to investigate the safety, pharmacokinetics, and targeting ability. At the 2-mg dose level, excellent tumor targeting was observed, comparable with that observed at the 2-mg dose level of the murine form of mAb G250 (Fig. 1). Again, normal organ uptake was restricted to the liver as expected. The absolute as well as relative amounts of c-G250 delivered to the tumors were similar to those observed for murine mAb G250 (Table 1). Consequently, tumor: tissue ratios were also comparable with the ratios observed with murine mAb G250 (Table 1), indicating that chimerization of the antibody did not compromise the excellent targeting ability of mAb G250. At the 5-mg dose level, liver uptake was not visible due to the saturation of G250 sites, as was observed for murine mAb G250 (Fig. 1). This seems to indicate that the targeting ability of the chimeric form of mAb G250 is comparable with that of murine mAb G250 at all dose levels.

Surprisingly, the clearance of c-G250 was comparable with that of murine mAb G250. Apparently, chimerization of mAb G250 did not result in the slower clearance observed for other chimerized mAbs [13, 14]. Slower clearance would be disadvantageous for radioimmunotherapy because longer retention would result in enhanced bone-marrow-related toxicity due to more extensive radiation. This would negate the possible benefits of chimerization, since the maximum dose of radionuclide would have to be reduced. Whether multiple dosing would resolve this disadvantage is unclear. Currently we lack information regarding the immunogenicity of c-G250. However, Buist et al. [2] observed minor human antibody responses to chimerized mAb MoV18; only 1/25 patients receiving chimeric MoV18 developed anti-chimeric MoV18 antibodies. The human constant regions of c-MoV18 are identical to the human constant regions of c-G250, and we therefore expect that c-G250 will be immunosilent in the majority of patients.

Our future efforts will be aimed at (multiple dose) radioimmunotherapy with chimerized mAb G250. In addition to ^{131}I , we will investigate the possibilities of other radionuclides. We are currently investigating the effector functions of c-G250. If chimerization results in powerful effector functions, "naked" antibody that can coat tumor cells and thus activate human effector cells might be an attractive alternative to radioimmunotherapy.

Acknowledgements. The authors would like to thank the many investigators who have contributed to mAb G250-related studies.

References

- Bander NH, Finstad CL, Cordon-Cardo C, et al (1989) Analysis of a mouse monoclonal antibody that reacts with a specific region of the human proximal tubule and subsets renal cell carcinomas. *Cancer Res* 49:6774-6780
- Buist MR, Kenemans P, Kamp GJ van, Haisma HJ (in press) Minor human antibody response to mouse and chimeric monoclonal antibodies after a single i.v. infusion in ovarian carcinoma patients: comparison of five assays. *Cancer Immunol Immunother*
- Chiou R-K, Woodson M (1988) Monoclonal antibody-targeted radiotherapy (MRT) for renal cell carcinoma: evaluations of its potentials and limitations (abstract 1743). *Proc Am Assoc Cancer Res* 29:438
- Chiou R-K, Vessella RL, Elsen MK, et al (1985) Localization of human renal cell carcinoma xenografts with a tumor-preferential monoclonal antibody. *Cancer Res* 45:6140-6146
- Divgi CR, Bander NH, Scott AM, et al (1994) Phase I radioimmunotherapy trial of I-131 labeled monoclonal antibody G250 in metastatic renal cancer (abstract 2999). *Proc Am Assoc Cancer Res* 35:503
- Finstad CL, Cordon-Cardo C, Bander NH, et al (1985) Specificity analysis of mouse monoclonal antibodies defining cell surface antigens of human renal cancer. *Proc Natl Acad Sci USA* 82:2955-2959
- Goldenberg DM (1988) Targeting of cancer with radiolabeled antibodies: prospects for imaging and therapy. *Arch Pathol Lab Med* 112:580-586
- Goldenberg DM (1991) Current status of cancer imaging with radiolabeled antibodies. *Antibody Immunoconjugates Radiopharm* 4:517-524
- Kochevar J (1987) A renal cell carcinoma neoplastic antigen detectable by immunohistochemistry is defined by a murine monoclonal antibody. *Cancer* 60:2031-2036
- Köhler G, Milstein C (1975) Continuous cultures of fused cells secreting antibody of predefined specificity. *Nature* 256:495-497
- Larson SM (1987) Lymphoma, melanoma, colon cancer: diagnosis and treatment with radiolabeled monoclonal antibodies. The 1986 Eugene P. Pendergrass New Horizons Lecture. *Radiology* 165:297-304
- Larson SM (1990) Clinical radioimmunodetection, 1978-1988: overview and suggestions for standardization of clinical trials. *Cancer Res* 50:892S-898S
- LoBuglio AF, Wheeler RH, Trang J, et al (1989) Mouse/human chimeric monoclonal antibody in man: kinetics and immune response. *Proc Natl Acad Sci USA* 86:4220-4224
- LoBuglio AF, Meredith R, Wheeler RH, et al (1991) Chimeric monoclonal antibody studies in colorectal cancer. In: Epenetos AA (ed) *Monoclonal antibodies*. Chapman and Hall, Cambridge, pp 291-295
- Luner SJ, Ghose T, Chatterjee S, et al (1986) Monoclonal antibodies to kidney and tumor-associated surface antigens of human renal cell carcinoma. *Cancer Res* 46:5816-5820
- Mach JP, Pelegrin A, Buchegger F (1991) Imaging and therapy with monoclonal antibodies in non-hematopoietic tumors. *Curr Opin Immunol* 3:685-693
- Morrison SL (1985) Transfectomas provide novel chimeric antibodies. *Science* 229:1202-1207
- Morrison SL, Johnson MJ, Herzenberger LA, Oi VT (1984) Chimeric human antibody molecules: mouse antigen-binding domains with human constant region domains. *Proc Natl Acad Sci USA* 81:6851-6855
- Oosterwijk E, Ruiters DJ, Hoedemaeker PJ, et al (1986) Monoclonal antibody G250 recognizes a determinant present in renal-cell carcinoma and absent from normal kidney. *Int J Cancer* 38:489-494
- Oosterwijk E, Ruiters DJ, Wakka JC, et al (1986) Immunohistochemical analysis of monoclonal antibodies to renal antigens: application in the diagnosis of renal cell carcinoma. *Am J Pathol* 123:301-309
- Oosterwijk E, Bander NH, Divgi CR, et al (1993) Antibody localization in human renal cell carcinoma: a phase I study of monoclonal antibody G250. *J Clin Oncol* 11:738-750

22. Palme DF, Berkopec JM, Elson MK, et al (1988) Dosimetry and immunotherapy using monoclonal antibody (MoAb) A6H 131-iodine conjugates: radiobiological consequences and effect of escalating dosages (abstract 1706). *Proc Am Assoc Cancer Res* 29:428
23. Sands H, Jones PL, Shah SA, et al (1988) Correlation of vascular permeability and blood flow with monoclonal antibody uptake by human Clouser and renal cell xenografts. *Cancer Res* 48:188-193
24. Tagliabue E, Canevari S, Menard S, et al (1984) Human renal antigen defined by a murine monoclonal antibody. *J Natl Cancer Inst* 73:363-369
25. Van Dijk J, Oosterwijk E, Van Kroonenburgh MJPG, et al (1988) Perfusion of tumor-bearing kidneys as a model for scintigraphic screening of monoclonal antibodies. *J Nucl Med* 29:1078-1082
26. Van Dijk J, Zegveld ST, Fleuren GJ, et al (1991) Localization of monoclonal antibody G250 and bispecific monoclonal antibody CD3/G250 in renal-cell carcinoma xenografts: relative effects of size and affinity. *Int J Cancer* 48:738-743
27. Vaughan ATM, Anderson P, Dykes PW, et al (1986) Limitations to the killing of tumours using radiolabelled antibodies. *Br J Radiol* 60:567-578
28. Vaughan ATM, Bradwell AR, Dykes PW, et al (1986) Illusions of tumour killing using radiolabelled antibodies. *Lancet* I: 1492-1493
29. Vessella RL (1991) Radioimmunoconjugates in renal cell carcinoma. In: Debruyne FMS, Bukowski RM, Pontes JE, De Mulder PHH (eds) *Immunotherapy of renal cell carcinoma*. Springer, Berlin Heidelberg New York, pp 38-46
30. Vessella RL, Moon TD, Chiou R-K, et al (1985) Monoclonal antibodies to human renal cell carcinoma: recognition of shared and restricted tissue antigens. *Cancer Res* 45:6131-6139
31. Vessella RL, Chiou RK, Grund FM, et al (1987) Renal cell carcinoma (RCC) phase I-II trials with 131-I labeled monoclonal antibody A6H: imaging and pharmacokinetic studies (abstract 1525). *Proc Am Assoc Cancer Res* 28:480
32. Vessella RL, Palme DF, Berkopec JM, et al (1988) Radiotherapy of a human renal cell carcinoma (RCC) xenograft: comparison between single fraction monoclonal antibody (MoAb) A6H 131-iodine conjugates and single fraction X-ray external beam irradiation (abstract 1707). *Proc Am Assoc Cancer Res* 29:429
33. Wessels BW, Vessella RL, Palme DF, et al (1989) Radiobiological comparison of external beam radiation and radioimmunotherapy in renal cell carcinoma xenografts. *Int J Radiat Oncol Biol Phys* 17:1257-1263
34. Winter G, Milstein C (1991) Man-made antibodies. *Nature* 349: 293-299
35. Yoshida SO, Imam A (1989) Monoclonal antibody to a proximal nephrogenic renal antigen: immunohistochemical analysis of formalin-fixed, paraffin-embedded human renal cell carcinomas. *Cancer Res* 49:1802-1809