

PDF hosted at the Radboud Repository of the Radboud University Nijmegen

The following full text is a publisher's version.

For additional information about this publication click this link.

<http://hdl.handle.net/2066/20981>

Please be advised that this information was generated on 2017-12-05 and may be subject to change.

Radiographic Progression in Rheumatoid Arthritis: Results of 3 Comparative Trials

PIET L.C.M. van RIEL, DÉsirÉE M.F.M. van der HEIJDE, IKE H. NUVER-ZWART, and LEO B.A. van de PUTTE

ABSTRACT. In 3 clinical trials the effects of 6 different disease modifying antirheumatic drugs on radiographic progression were evaluated. Despite the wide range in disease duration of patients in the different studies, a statistically significant slowing of radiographic progression was found in those patients treated with aurothioglucose, sulfasalazine, and methotrexate compared to auranofin, hydroxychloroquine, and azathioprine, respectively. These drugs might therefore be considered as disease controlling antirheumatic drugs. (*J Rheumatol* 1995;22:1797-9)

Key Indexing Terms:

RHEUMATOID ARTHRITIS
AUROTHIOGLUCOSE

RADIOGRAPHS

SULFASALAZINE
METHOTREXATE

Rheumatoid arthritis (RA) is a chronic and inflammatory joint disease that often leads to destructive lesions of articular tissues, namely cartilage and periarticular bone, that is largely irreversible. The aim of the treatment of RA is therefore not only suppression of joint inflammation and relief of concomitant pain and stiffness, but also prevention or retardation of joint damage. In the new classification criteria, drugs that suppress synovial inflammation, sustain functional status and prevent or slow radiological destruction are called disease controlling antirheumatic therapies (DCART)¹. At this moment it is still unclear how many of the currently available disease modifying antirheumatic drugs (DMARD) fulfil in particular this last criterion². We present the effects of 6 different DMARD on radiological progression in RA. The results were obtained in 3 clinical trials performed in the last 15 years in our department³⁻⁵.

DMARD trials. In the 1st trial, the effects of gold thioglucose (GTG) injections were compared with auranofin (AF) treatment in patients with an established RA³. During the 1st year of the study, 50% of the patients dropped out. The main reason for discontinuing treatment with GTG was adverse reactions and in the AF group, lack of efficacy. Evaluated on an intention to treat basis, the GTG treatment was superior to AF. Radiographs of hands and feet were taken at the start, after 24 and 48 weeks. The radiographs were read by a blinded observer (A. Larsen) following the Larsen method⁶. Evaluation was performed by both the total radiographic score as well as the number of newly developed erosions after 24 and 48 weeks. A statistically significant increase in the total radiographic score at 24 and 48 weeks from

baseline was observed in the AF group and not in the GTG group. In the AF group but not in the GTG treated patients, a statistically significant increase in the mean number of new erosions was seen after 24 and 48 weeks (Figure 1). Although this study was hampered by high dropout rates, the difference between these 2 treatments might even be greater particularly as those patients in the AF group with a lack of efficacy dropped out, while in the GTG group, the dropouts due to adverse reactions could be classified as responders⁷.

In the 2nd trial the effects of sulfasalazine were investigated as compared to hydroxychloroquine in patients with early RA⁴. In the sulfasalazine treated patients a significantly earlier suppression of disease activity was found compared to the hydroxychloroquine treated patients, although after 24 and 48 weeks no statistically significant difference was found between the 2 treatments for the individual disease activity variables⁸. When using a composite index, the disease activity score (DAS), statistically significant differences between the 2 treatments were found at various time points (Figure 2)⁹. Radiographs of hands and feet were taken at the start, after 24 and 48 weeks and scored by a blinded observer (DvdH), with the modified Sharp method. After 24 and 48 weeks statistically significantly more radiographic damage was observed in the hydroxychloroquine group compared to the sulfasalazine group. After 48 weeks the trial course was broken and patients received DMARD chosen by their physicians. After 3 years the patients of the 2 treatments were evaluated again according to an intention to treat principle. The significant difference in joint damage found after 48 weeks was still present at 3 year followup, but the number of new erosions and the increase in total score (summation of narrowing and number of erosions) was not significantly different in the period after 48 weeks¹⁰.

In the 3rd trial, carried out in patients with advanced RA, the effect of methotrexate (MTX) and azathioprine were compared¹¹. The clinical evaluation revealed a statistically significant difference between the 2 treatments in favor of

From the Department of Rheumatology, University Hospital Nijmegen, Nijmegen, The Netherlands.

P.L.C.M. van Riel, MD, Associate Professor; D.M.F.M. van der Heijde, MD; I.H. Nuver-Zwart, MD; L.B.A. van de Putte, MD, Professor, Department of Rheumatology, University Hospital Nijmegen, The Netherlands.

Address reprint requests to Dr. P.L.C.M. van Riel, University Hospital Nijmegen, Geert Grooteplein 8, 6525 GA Nijmegen, The Netherlands.

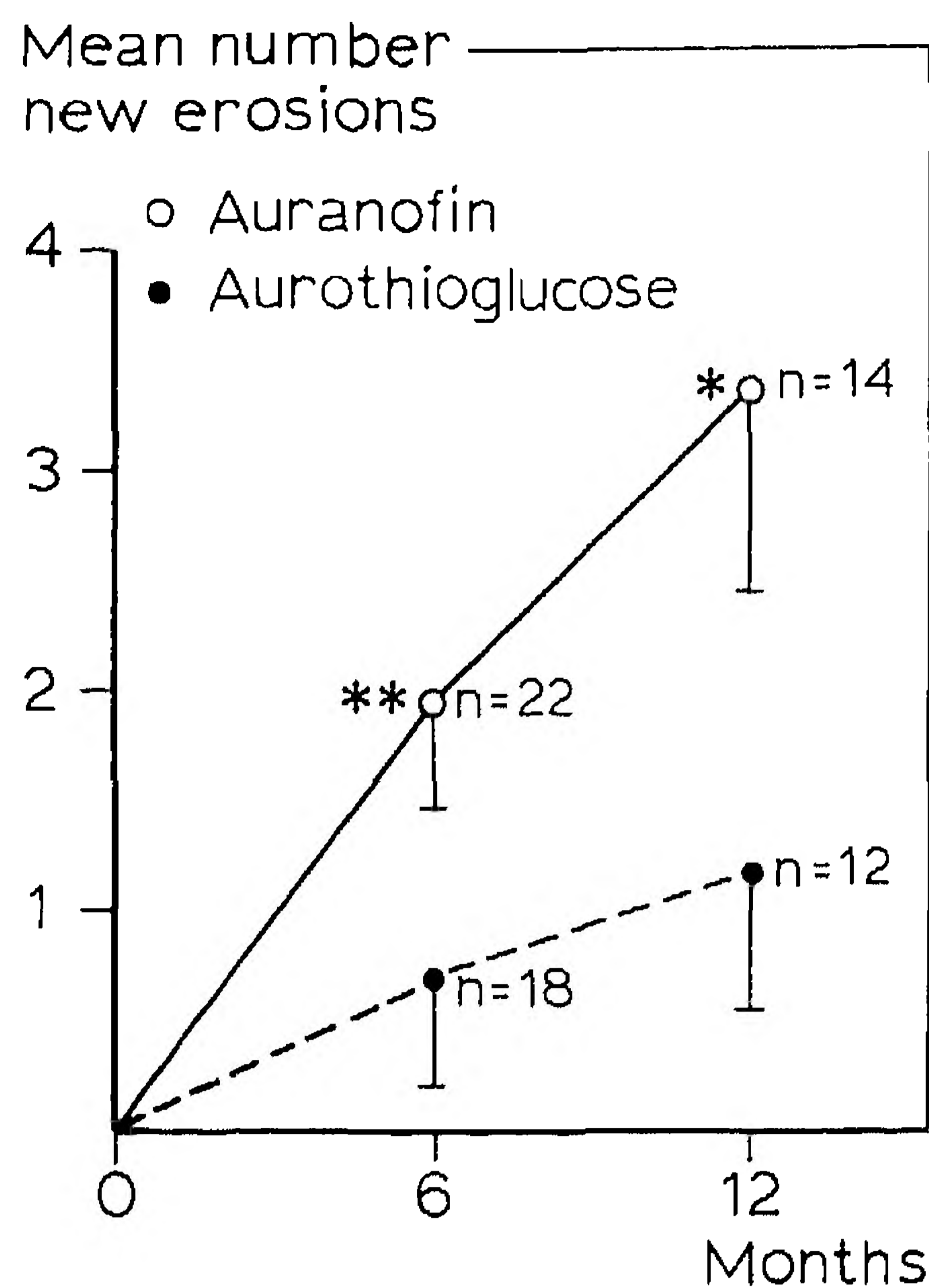


Fig. 1. Mean number of new erosions during the study in both treatment groups. *P < 0.01, paired t test. **P < 0.001, paired t test.

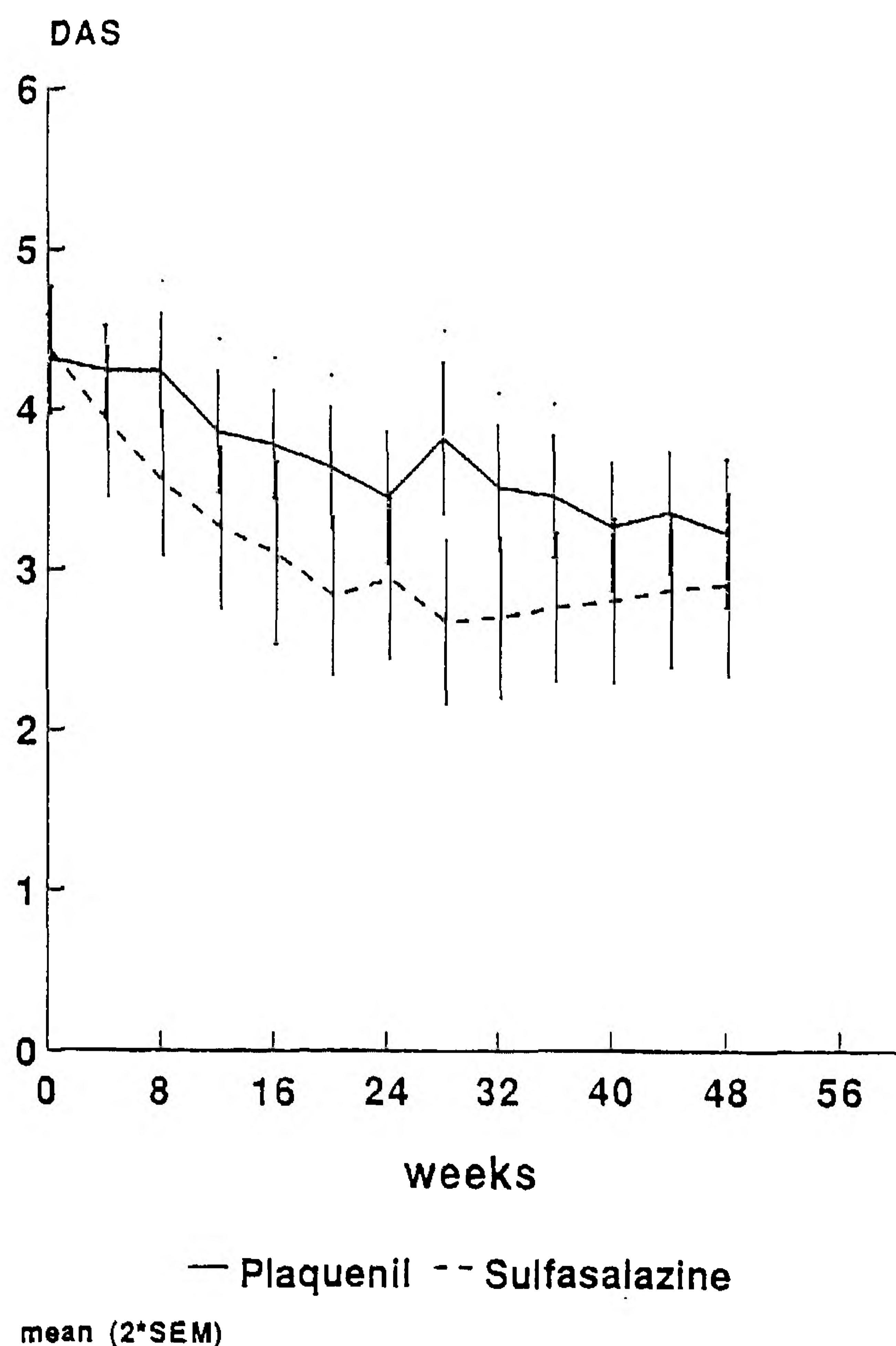


Fig. 2. Course of the disease activity in both treatment groups using the DAS. P < 0.05, t test.

MTX. Radiographs of hands and feet at the start, after 24 and 48 weeks were evaluated by a blinded observer following the modified Sharp method⁵. Although the patient groups already had considerable joint damage at baseline, significantly fewer new erosions in the MTX group compared to the azathioprine group were found after 24 and 48 weeks. In addition, the change in the total score was also significantly less pronounced in the MTX group compared with the azathioprine group after 24 and 48 weeks.

CONCLUSIONS

The disease duration of the patients in the 3 different clinical trials were different. In the 1st trial patients were included with a mean disease duration of 3.1 and 4.3 years in the AF and GTG group, respectively, in the 2nd trial patients with early RA were included (mean disease duration of 1.3 and 1.1 years in the hydroxychloroquine and sulfasalazine group, respectively) and in the 3rd trial patients with a long disease duration (9.4 and 12.8 years for azathioprine and MTX group, respectively) were included. Despite these considerable differences in disease duration in all 3 studies, statistically significant differences in radiographic progression between the comparative agents could be found. For all 3 studies these differences in radiographic progression were in accordance with the clinical evaluation of the drugs. All radiographs were scored by an observer who was not aware of the clinical and laboratory findings and the drugs the patients received. The radiographs were read in a sequential way for each patient under identical conditions. This method might be the reason that differences between treatments were found in relatively small groups of patients.

REFERENCES

- Edmonds JP, Scott DL, Furst DE, Brooks P, Paulus HE: Antirheumatic drugs: a proposed new classification. *Arthritis Rheum* 1993;36:336-9.
- Iannuzzi L, Dawson N, Zein N, Kushner I: Does drug therapy slow radiographic deterioration in rheumatoid arthritis? *N Engl J Med* 1983;309:1023-8.
- van Riel PLCM, Larsen A, van de Putte LBA, Gribnau FWJ: Effects of aurothioglucose and auranofin on radiographic progression in rheumatoid arthritis. *Clin Rheum* 1986;5:359-64.
- van der Heijde DM, van Riel PL, Nover-Zwart HH, Gribnau FW, van de Putte LB: Effects of hydroxychloroquine and sulphasalazine on progression of joint damage in rheumatoid arthritis. *Lancet* 1989;1:1036-8.
- Jeurissen MEC, Boerbooms AMTH, van de Putte LBA, et al: Influence of methotrexate and azathioprine on radiologic progression in rheumatoid arthritis: a randomized double-blind study. *Ann Intern Med* 1991;114:999-1004.
- Larsen A: Radiographic evaluation of rheumatoid arthritis in therapeutic trials. In: Paulus HE, Ehrlich GE, Lindenlaub E, eds. *Controversies in the Clinical Evaluation of Analgesic-Anti-inflammatory-Anti-rheumatic drugs*. Stuttgart: FK Schatteuer Verlag, 1981:323-9.
- van Riel PLCM, van de Putte LBA, Gribnau FWJ, et al: A single blind comparative study of auranofin and goldthioglucose in patients with rheumatoid arthritis. In: Capell HA, Cole DS,

- Manghani KK, Morris RW, eds. *Auranofin Proceedings of Smith Kline and French International Symposium*. Amsterdam: Excerpta Medica, 1983:135-46.
8. Nuver-Zwart IH, van Riel PLCM, van de Putte LBA, Gribnau FWJ: A double blind comparative study of sulphasalazine and hydroxychloroquine in rheumatoid arthritis: Evidence of an earlier effect of sulphasalazine. *Ann Rheum Dis* 1989;48:389-95.
 9. van der Heijde DMFM, van 't Hof MA, van Riel PLCM, *et al*: Judging disease activity in clinical practice in rheumatoid arthritis. First step in the development of a 'disease activity score'. *Ann Rheum Dis* 1990;49:916-20.
 10. van der Heijde DMFM, van Riel PLCM, Nuver-Zwart IH, van de Putte L: Sulphasalazine versus hydroxychloroquine in rheumatoid arthritis: 3-year follow-up. *Lancet* 1990;1:539.
 11. Jeurissen MEC, Boerbooms AMTh, van de Putte LBA: Methotrexate versus azathioprine in the treatment of rheumatoid arthritis. A forty-eight week randomized, double-blind trial. *Arthritis Rheum* 1991;34:961-72.

Part 2 of the symposium Methods of Scoring Radiographic Changes in Rheumatoid Arthritis
will appear in the October issue of The Journal
