

## PDF hosted at the Radboud Repository of the Radboud University Nijmegen

The following full text is a publisher's version.

For additional information about this publication click this link.

<http://hdl.handle.net/2066/20514>

Please be advised that this information was generated on 2017-12-05 and may be subject to change.

- ipients. *Transplant Proc* 1991; 23: 1256.
9. Hochstetler LA, Flanigan MJ, Lager DJ. Transplant-associated thrombotic microangiopathy: the role of IgG administration as initial therapy. *Am J Kidney Dis* 1994; 23: 444.
10. Schmidt RJ, Venkat KK, Dumler F. Hemolytic uremic syndrome in a renal transplant recipient on FK506 immunosuppression. *Transplant Proc* 1991; 23: 3156.

11. McCauley J, Bronsther O, Fong J, et al. Treatment of cyclosporin-induced haemolytic uraemic syndrome with FK506. *Lancet* 1989; 2: 1516.

Received 16 November 1994.

Accepted 17 January 1995.

## KIDNEY TRANSPLANTATION IN THE ABSENCE OF THE INFRARENAL VENA CAVA

J. PIRENNE,<sup>1,2</sup> E. BENEDETTI,<sup>1</sup> C.E. KASHTAN,<sup>3</sup> E. LLEDO-GARCIA,<sup>1</sup> N. HAKIM,<sup>1</sup> C.H. SCHROEDER,<sup>4</sup> M. COOK,<sup>4</sup> D.E.R. SUTHERLAND,<sup>4</sup> A.J. MATAS,<sup>4</sup> AND J.S. NAJARIAN<sup>1</sup>

*Departments of Surgery and Pediatric Nephrology, University of Minnesota, Minneapolis, Minnesota, and Department of Pediatrics, University Hospital Nijmegen, Nijmegen, The Netherlands*

The iliac fossa is the standard site for a kidney allograft. In rare cases, the iliac veins or the inferior vena cava may be occluded or congenitally absent—thus, an alternative site and type of venous drainage are required. We report herein a case of intraabdominal kidney transplantation in a young patient whose infrarenal vena cava was absent. We also review the pertinent literature on this subject.

The recipient was an 18-year-old man with end-stage renal failure due to congenital bilateral kidney hypoplasia. He began hemodialysis at age 7. At age 9, he received a cadaver kidney graft that was placed in the right iliac fossa. The iliac vein and inferior vena cava were noted to be absent; they had been replaced by a conglomerate of tortuous vessels, to which the transplant renal vein was attached. Although immediate graft function was satisfactory, it was gradually lost due to repeated rejection episodes. At age 12, he received a second kidney graft (donated by his father) that was placed in the left iliac fossa. Again, a venous conglomerate was found but no iliac vein. One of these vessels was used as the recipient site for venous connection. Graft thrombosis occurred and the graft was removed on postoperative day 1. The patient returned to peritoneal dialysis and later to hemodialysis. He also suffered from repeated episodes of deep venous thrombosis of the lower extremities. Coagulation study results, including levels of protein C, protein S, and antithrombin III, were normal.

At age 19, he was referred to the University of Minnesota for evaluation for a third kidney transplant. A venogram showed absence of the inferior vena cava below the level of the right gonadal vein; a large lumbar vein was present on the left side. This vein presumably was responsible for venous drainage of the lower abdomen and lower extremities through a collateral paravertebral venous network. In both iliac fossae, a network of tortuous vessels was present, but no iliac vein (Fig. 1). The patient's brother, a 23-year-old HLA-identical match, was medically eligible for living-related donation. An angiogram showed that his right kidney was

supplied by three arteries; his left kidney, supplied by two arteries, was selected for procurement.

On June 23, 1994, an intraabdominal kidney transplant was done through a midline incision (Fig. 2). The recipient's right kidney was absent and his left kidney was atrophic. The inferior vena cava was atretic below the level of the right gonadal vein. Both the right and the left renal veins were of small caliber. A large lumbar vein was present on the left side. During dissection, patency of these collateral veins was preserved, to conserve blood flow and minimize the risk of postoperative thrombosis. The donor operation was routine, except that the entire length of ureter was mobilized. After recipient dissection, vascular clamps were placed on the infrahepatic vena cava and on the aorta. A venotomy was done on the infrahepatic vena cava, and an excellent backflow was noted. This venotomy served as the recipient site for the end-to-side venous anastomosis. The two renal arteries were separately anastomosed end-to-side to the recipient aorta. The ureter was drawn through a retroperitoneal tunnel mimicking the normal anatomy, and an intravesical ureteroneocystostomy was done using the Leadbetter-Politano technique. Immunosuppression consisted of cyclosporine, prednisone, azathioprine, and an induction course of anti-lymphocyte therapy (ATGAM, Upjohn). Graft function was excellent immediately. Low-dose heparin (200 units/h) was administered, then low-dose coumadin (3 mg/day). Now, at 2 months posttransplant, the serum creatinine level is 1 mg/dl.

Heterotopic placement of kidney allografts in the iliac fossa is the norm. In some circumstances, however, abnormalities of the venous system may preclude use of this site. Such abnormalities include absence of suitable iliac veins or of the intraabdominal vena cava. They can be congenital, or secondary to thrombosis related to hypercoagulability, previous placement of a vena cava filter, trauma, or perinatal catheterization of the umbilical vein (1-3). Total absence of the vena cava is a rare congenital anomaly, often associated with cardiac or other visceral malformations (e.g., malrotation, dextrocardia, malformation of the spleen) (3). The precise cause of the absent iliac vein and infrarenal vena cava in our patient remains unclear.

Whatever the cause of the venous anomaly, a uniform consequence is inappropriate venous drainage from the lower extremities. This was reflected in our patient by repeated

<sup>1</sup> Department of Surgery, University of Minnesota.

<sup>2</sup> Address correspondence to J Pirenne, MD, PhD, Senior Lecturer, Queen Elizabeth Hospital, Edgbaston, Birmingham B15 2TH, UK.

<sup>3</sup> Department of Pediatric Nephrology, University of Minnesota.

<sup>4</sup> University Hospital Nijmegen.

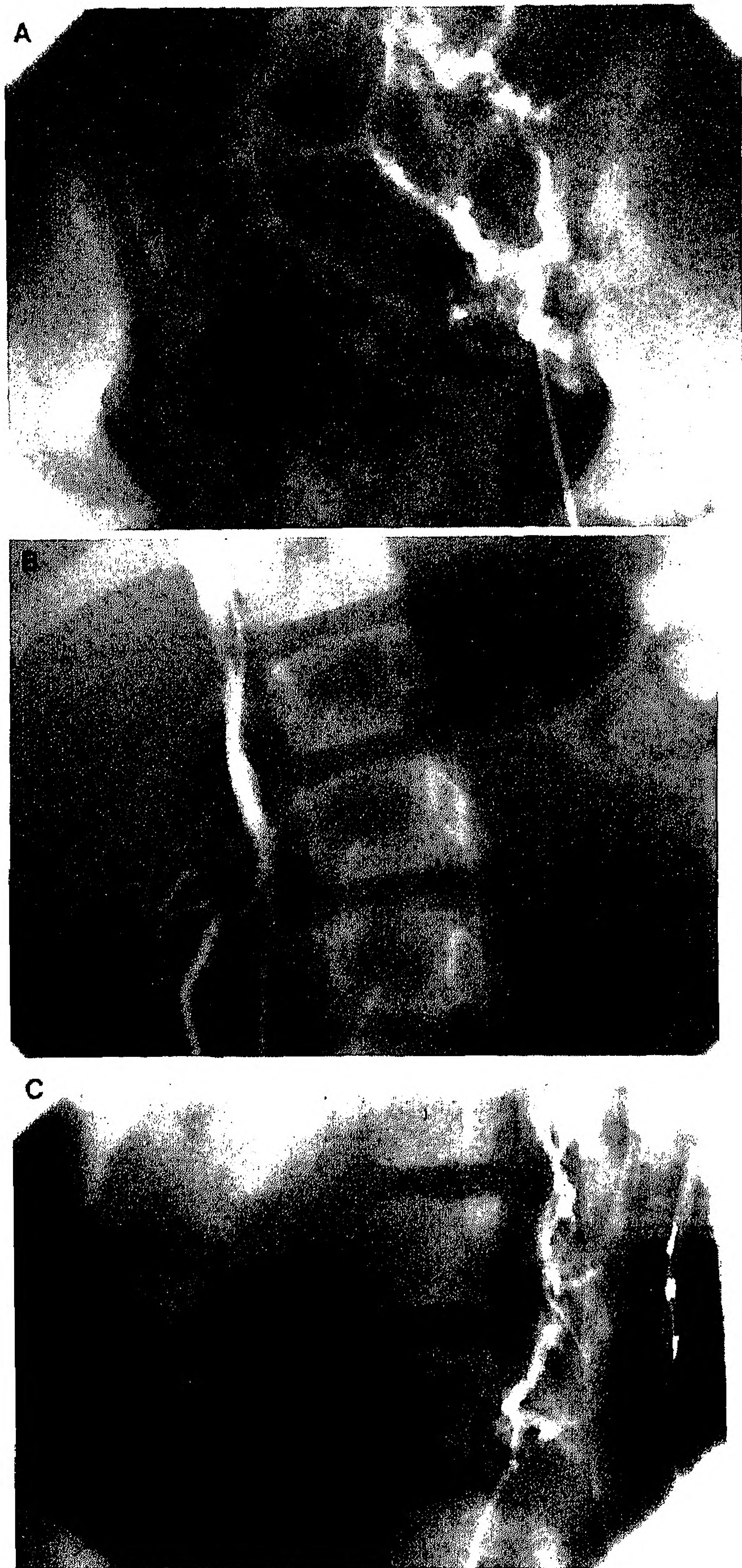


FIGURE 1. Patient's venogram showing (A) a network of tortuous vessels in the left iliac fossa, but no iliac vein, (B) absence of the inferior vena cava below the level of the right gonadal vein, and (C) venous drainage of the lower abdomen and lower extremities through a collateral paravertebral venous network.

episodes of deep venous thrombosis, and even more dramatically by the rapid graft thrombosis after his second transplant. An important lesson from this case is to use caution when placing a kidney graft in the iliac fossa in the absence of normal venous anatomy. Venous congestion and graft thrombosis may occur. In an experimental study, all minipigs who underwent a kidney autotransplant after resection of

the vena cava developed graft thrombosis, despite development of a collateral circulation before caval resection (4). Therefore, patients with end-stage renal disease who have no suitable iliac vein or vena cava require an alternative graft site (intraabdominal or native lumbar fossa) and type of venous drainage (caval or portal).

If only the infrarenal vena cava is absent, the vena cava immediately below the liver can be used for graft venous implantation, as in this case. Patency of the infrahepatic vena cava can be assessed preoperatively by venogram and confirmed intraoperatively by an adequate backflow after venotomy. All venous tributaries from this segment of upper vena cava (remnant renal veins, gonadal veins, lumbar veins) must be left intact, both to maximize the blood flow in this residual portion of the vena cava and to preserve collateral circulation and venous drainage from the lower abdomen and lower extremities. Finally, the venotomy should be made as large as possible to ensure a widely patent anastomosis and adequate venous emptying from the allograft. Alternatively, one of the native renal veins may serve as the recipient site for an end-to-side anastomosis with the transplant renal vein. We employed this technique in another kidney recipient

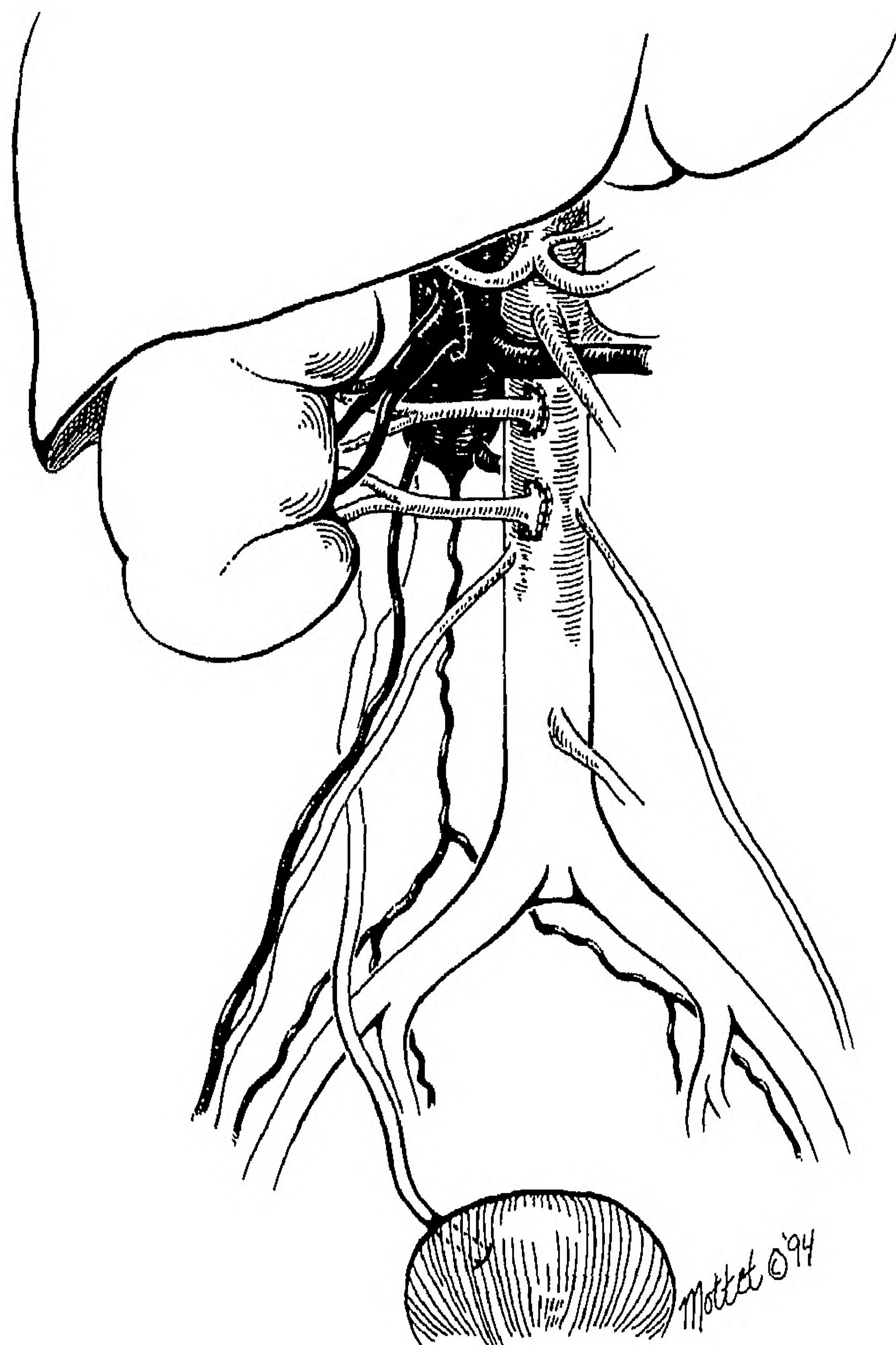


FIGURE 2. Illustration of the intraabdominal transplant in the absence of the infrarenal vena cava. Renal vein was attached end-to-side to the infrahepatic vena cava. Renal arteries were attached end-to-side to the aorta. An intravesical ureteroneocystostomy was performed.

with thrombosis of the infrarenal vena cava secondary to the use of a vena cava filter (1). At our institution, we have used an enlarged patent ovarian vein for venous implantation of a pancreas allograft in a patient with no suitable vena cava (Sutherland DER, unpublished observations).

If the vena cava is totally absent due to extensive thrombosis or agenesis, the only option is to use the portal system for graft implantation. The feasibility of draining various organ allografts (kidneys, heart, pancreas, small bowel) into the portal system has been demonstrated experimentally (5-8). Clinically, the splenic vein has been successfully used to drain pancreas allografts (9-11). We have used recipient inferior mesenteric vessels to revascularize segmental pancreas allografts; the graft splenic artery and vein were anastomosed end-to-end to the inferior mesenteric vessels, and no thrombosis occurred (12).

We know of only two reports of intraabdominal kidney transplants using the portal system for venous revascularization. One recipient was a child who had previously undergone nephrectomy and vena cava resection for Wilms' tumor; the renal artery was anastomosed end-to-side to the recipient aorta and the renal vein end-to-side to the splenic vein. Urinary continuity was restored by ureteroureterostomy. Radioisotopic scan 1 year posttransplant showed good perfusion and no signs of urinary stasis (13). In another recipient, the inferior mesenteric vein was used for revascularization; similar to our case, the ureter was reimplanted into the bladder using the standard nonrefluxing Leadbetter-Politano technique (14).

There is a theoretical immunologic advantage in using the portal system for venous connection. Several reports indicate that rejection can be ameliorated by portal drainage, an effect possibly due to inactivation by the liver of circulating transplant antigens (8). Experimentally, in certain strain of rats, portally drained kidney, heart, and small bowel allografts survive longer (5-8). The clinical reality of this effect remains controversial since it has not been repeatedly observed in larger animals (15). Based on the few human cases of portally drained kidney and pancreas allografts, there is no evidence that portal implantation dramatically ameliorates rejection. Using the portal system for graft vascular connection may even convey a physiologic disadvantage: portal pressure is higher than caval pressure, a hemodynamic difference that could impair the venous drainage of portally versus systemically drained allografts.

One alternative to intraabdominal placement is the orthotopic position. Gil-Vernet described a graft placement in the native kidney fossa through an extraperitoneal lumbar approach, similar to that used for nephrectomy from a living donor. The transplant renal artery was attached end-to-end to the splenic artery or end-to-side to the aorta, and the transplant renal vein was attached end-to-end to the native renal vein. Pyelopyelostomy was used for urinary reconstruction (10, 11). Similarly, Talbot-Wright described a splenorenal anastomosis in two patients with total agenesis of the inferior vena cava. The kidney was placed orthotopically, with end-to-end anastomosis of the transplant renal vein to the native splenic vein and of the transplant renal artery to the native splenic artery. In unexperienced hands, the orthotopic method conveys a significant risk of pancreatic injury (16). We believe this delicate technique should be used only in patients with abnormal venous anatomy in whom intraabdominal placement is not feasible.

When the vascular anastomoses are in the upper abdomen, reconstructing the urinary tract is more difficult. Of concern is the excessive distance between the graft and the bladder and the resulting risk of ischemia and stenosis of the distal ureter. However, an autotransplanted ureter, by definition completely deprived of its original blood supply, does survive with normal peristalsis and appearance and with preserved histology. Neovascularization can develop due to either repermeabilization of original vessels or to formation of new ones (17). Neovascularization of recipient origin can be improved by keeping periureteral tissues intact during procurement and by drawing the ureter through a retroperitoneal tunnel, as in our case. Development of new vessels can also be improved by wrapping the ureter with a pedicle of great omentum (18). Finally, a factor limiting the feasibility of a direct ureteroneocystostomy may be an insufficient length of available donor ureter. In such a case, a pyelopyelostomy or ureteroureterostomy can be done if the recipient urinary tract is anatomically intact and the vesicoureteral reflux is absent.

In summary, our technique allowed us to safely do a living-related kidney transplant after a standard heterotopic transplant had failed due to the absence of the infrarenal vena cava. The recipient would otherwise have been condemned to lifetime dialysis.

#### REFERENCES

1. Mozes MF, Kjellstrand CM, Simmons LR, Najarian JS. Orthotopic renal homotransplantation in a patient with thrombosis of the inferior vena cava. *Am J Surg* 1976; 131: 633.
2. Halbmayr WM, Radek J, Duschet P, et al. Recurrent venous thromboses in hypoplasia of the vena cava inferior and factor XII deficiency. *Deutch Med Wochenschr* 1993; 118: 1561.
3. Debing E, Tielemans, Jolie E, Van den Brande P. Congenital absence of inferior vena cava. *Eur J Vasc Surg* 1993; 7: 201.
4. Hernandez Fernandez C, Moncada Iribarren I, et al. Autotransplant renal derecho después de cavectomia inferior. *Arch Esp Urol* 1991; 45: 105.
5. Boeckx W, Sobis H, Lacquet A, et al. Prolongation of allogeneic heart graft survival in the rat after implantation on portal vein. *Transplantation* 1970; 9: 333.
6. Kamei T, Callery MP, Flye MW. Pre-transplant portal venous administration of donor antigen and portal venous allograft drainage synergistically prolong rat cardiac allograft survival. *Surgery* 1990; 108: 415.
7. Schraut WH, Rosemurg AS, Riddell RM. Prolongation of intestinal allograft survival without immunosuppressive drug therapy: Transplantation of small bowel allografts. *J Surg Res* 1983; 34: 597.
8. Sakai A. Role of the liver in kidney allograft rejection in the rat. *Transplantation* 1970; 108: 415.
9. Calne RY. *Lancet* 1984; 1: 595.
10. Gil-Vernet JM, Fernandez Cruz L, Caralps A, et al. Clinical experience with pancreatico pyelostomy for exocrine pancreatic drainage and portal venous drainage in pancreas transplantation. *Transplant Proc* 1985; 17: 342.
11. Gil-Vernet JM, Gil-Vernet A, Caralps A, et al. Orthotopic renal transplant and results in 139 consecutive cases. *J Urol* 1989; 142: 248.
12. Sutherland DER, Goetz FC, Moudry KC, Abouna GM, Najarian JS. Use of recipient mesenteric vessels for revascularization of segmental pancreas grafts: technical and metabolic considerations. *Transplant Proc* 1987; 19: 2300.
13. Shapira Z, Yussim A, Savir A, et al. The use of the portal system for the transplantation of a neonate kidney graft in a child with Wilms' tumor. *J Pediatr Surg* 1985; 20: 549.

14. Rosenthal JT, Loo RK. Portal venous drainage for cadaveric renal transplantation. *J Urol* 1990; 144: 969.
15. Barker CF, Corriere JN. Canine renal homotransplantation with venous drainage via the portal vein. *Ann Surg* 1967; 165: 281.
16. Talbot-Wright R, Carretero P, Alcaraz A, Vilardell J. Complex renal transplants for vascular reasons. *Transplant Proc* 1992; 24: 1865.
17. Saladié JM, Blasco FJ. Experimental model for ureteral auto-transplantation in the rat. *Eur Urol* 1992; 22: 79.
18. Mohring K, Pomer S. Preventive use of pedicled omentum majus within the scope of kidney transplantation. *Helv Chir Acta* 1991; 58: 265.

Received 22 December 1994.

Accepted 24 January 1995.

## ACETAZOLAMIDE-ASSOCIATED NEPHROCALCINOSIS IN A TRANSPLANT KIDNEY

JAY R. PARIKH,<sup>1</sup> ROBERT L. NOLAN,<sup>2</sup> AMITABHA BANNERJEE,<sup>3</sup> AND M. HENRY GAULT,<sup>4</sup>

*Department of Medicine, Memorial University, St. John's, Newfoundland, Canada; Department of Radiology, Kingston General Hospital, Queen's University, Kingston, Ontario; and Department of Radiology, San Jacinto Methodist Hospital, Baytown, Texas*

Acetazolamide is a carbonic anhydrase inhibitor used in the treatment of glaucoma. Known renal side effects in patients treated with acetazolamide include sulfonamide-type nephropathy (1), calculus formation (2), and ureteric colic (3). Recently we reported the first case of nephrocalcinosis in native kidneys secondary to diamox therapy (4). We now present the imaging findings of nephrocalcinosis in a transplant kidney associated with acetazolamide therapy.

A 22-year-old man developed renal failure from chronic glomerulonephritis and underwent kidney transplantation from a living donor, who was his sister. At age 24, he developed glaucoma that was treated with acetazolamide 250 mg every 6 hr. The glaucoma was presumed secondary to his chronic immunosuppressive therapy with prednisone 15 mg and azathioprine 100 mg/day.

At age 31, the patient's serum creatinine had risen to 155–172  $\mu\text{mol/L}$ . The patient was asymptomatic. Physical examination revealed chronic ocular findings of glaucoma. Blood pressure averaged 127/88 on hydralazine 100 mg and propranolol 80 mg/day. The remainder of the examination was unremarkable. Serum hemoglobin was 17.6 g/L. Serum chloride measured 111–114, serum bicarbonate 20–21, sodium 145, and potassium 4.1 mmol/L. Serum calcium was 2.5 mmol/L; parathyroid hormone, phosphate, and uric acid were normal. Urinalysis showed 10–15 red blood cells and 5–10 white blood cells per high power field and trace proteinuria. The 24-hr urine excretion of calcium at 3.0 and oxalate at 250  $\mu\text{mol}$  were normal. Urine pH was 6 to 7; cultures including those for tuberculosis were negative. The serum and urine chemistry were compatible with mild renal tubular acidosis secondary to acetazolamide therapy.

A sonogram of the transplant kidney (Fig. 1) demonstrated multiple foci of markedly increased echogenicity with posterior acoustic attenuation involving the distribution of the medulla. A plain radiograph of the kidney (Fig. 2) confirmed

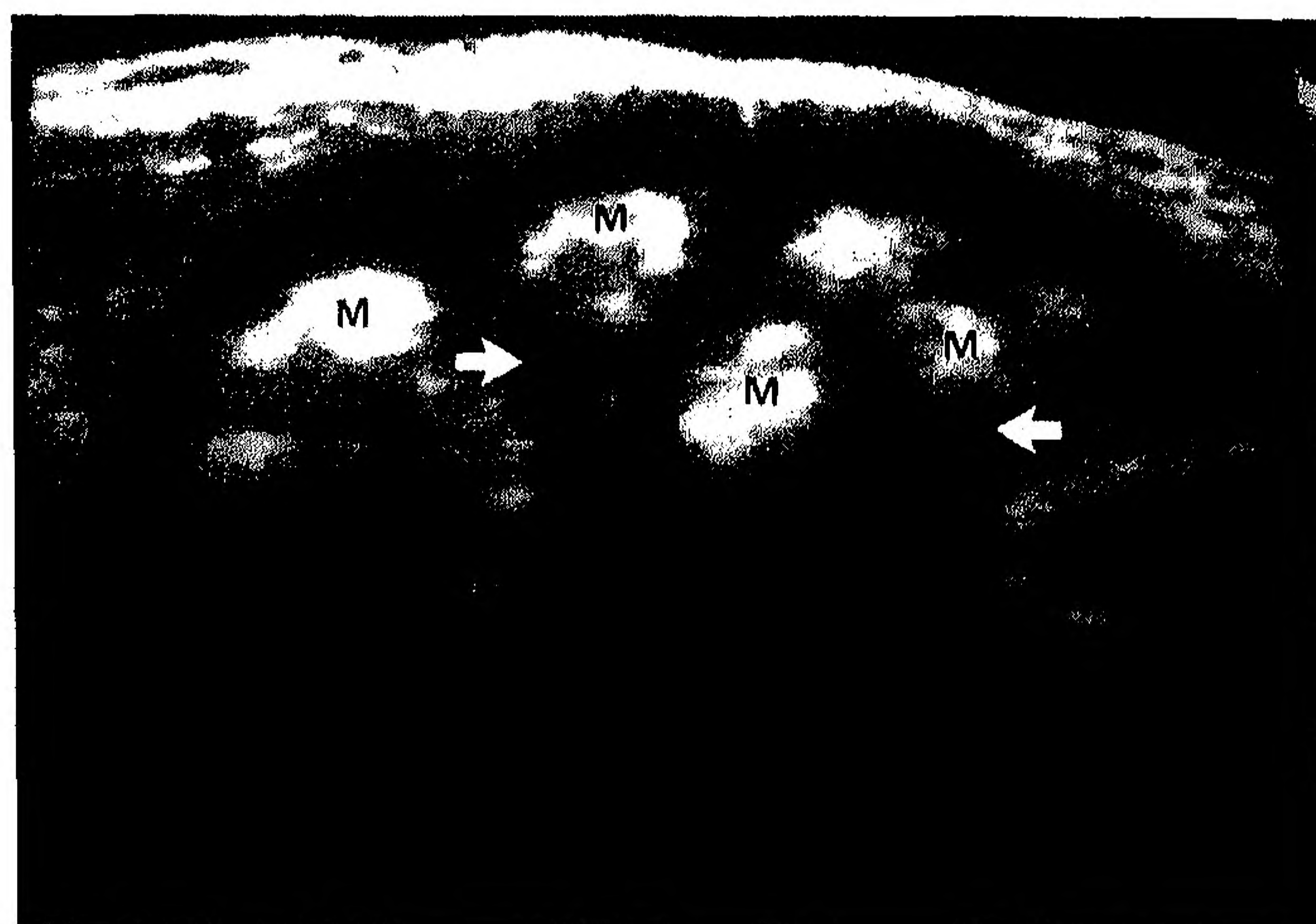


FIGURE 1. Sonogram of transplant kidney demonstrates multiple foci of increased echogenicity within the medulla (M) with associated posterior acousting shadowing (arrows).

multiple small discrete parenchymal calcifications compatible with medullary nephrocalcinosis.

The mild renal tubular acidosis secondary to acetazolamide therapy was considered to be responsible for the patient's medullary nephrocalcinosis and deterioration in renal function. The acetazolamide was discontinued and the patient's creatinine fell to 136  $\mu\text{mol/L}$  in one year and later to 95–105  $\mu\text{mol/L}$ . Serum bicarbonate rose to 27 and chloride fell to 107 mmol/L. Urine pH fell to the 5–6 range, and red blood cells and white blood cells to 2–4 per high power field on urinalysis. At age 44, the patient has done well without passing any calculi or having any episodes of renal colic. The creatinine has remained stable, and follow-up radiographs and sonograms have demonstrated no change from the patient's initial nephrocalcinosis at age 31. He has not been treated for transplant rejection since age 22. The glaucoma became stable on 10 mg daily oral prednisone and timolol 0.5% and isoptocarpine 2% eye drops.

Nephrocalcinosis, calcifications located within the renal parenchyma, is classified as cortical or medullary. Cortical

<sup>1</sup> Kingston General Hospital.

<sup>2</sup> Address Correspondence to Robert L. Nolan, M.D., F.R.C.P., Professor, Department of Radiology, Kingston General Hospital, Kingston, Ontario, Canada K7L 2V7.

<sup>3</sup> San Jacinto Methodist Hospital.

<sup>4</sup> Memorial University.