

PDF hosted at the Radboud Repository of the Radboud University Nijmegen

The following full text is a publisher's version.

For additional information about this publication click this link.

<http://hdl.handle.net/2066/16725>

Please be advised that this information was generated on 2017-12-05 and may be subject to change.

Cellular responses in the skin of rainbow trout (*Oncorhynchus mykiss*) exposed to Rhine water

Y. IGER*, H. A. JENNER† AND S. E. WENDELAAR BONGA*‡

*Department of Animal Physiology, Faculty of Science, University of Nijmegen, 6525 ED Nijmegen and †KEMA Environmental Services, KEMA, Utrechtseweg 310, 6812 AR Arnhem, The Netherlands

(Received 18 June 1993, Accepted 7 February 1994)

Trout, *Oncorhynchus mykiss*, were exposed to water from the Rhine for 24 days and their skin examined by light and electron microscopy. Relative to control fish mitotic figures were common and seen throughout the epidermis. Pavement cells in fish exposed to Rhine water contained significantly more secretory vesicles than control fish. Necrotic pavement cells were apparent after 24 h, and apoptotic cells from day 4 on. Mucous secretion was intense and the differentiation of mucous cells was stimulated. Some of these cells synthesized mucus of high electron density, probably of a serous composition. Leucocytes invaded the dermis and epidermis, and towards the end of the experiment many apoptotic and necrotic lymphocytes were found. In the dermis fibroblasts were abundant and actively producing collagen. Pigment containing cytoplasmic extensions of melanocytes penetrated into the epidermis. After 14 and 24 days of exposure many pigment cells, melanocytes, iridocytes and xanthocytes became apoptotic. Most of these changes are known from fish exposed to heavy metals, acid water or other stressful treatments, indicating that exposure to Rhine water is a stressful experience for trout.

Key words: epidermis; dermis; ultrastructure; Rhine water; *Oncorhynchus mykiss*.

INTRODUCTION

Anthropogenic influences, such as direct discharges from industries or surface runoff from contaminated areas, cause pollution of the Rhine. Contaminants such as heavy metals (e.g. copper and cadmium; Paalman & Van der Weijden, 1992) or chlorinated hydrocarbons (e.g. polychlorinated biphenyls; Dethlefsen & Tiews, 1985; Den Hartog *et al.*, 1992) have been reported at concentrations which may lead to reproductive failure and death, and thus to the disappearance of fish populations as well as other aquatic organisms (Capel *et al.*, 1988). Chronic exposure of fish to such pollutants at relatively low concentrations may also affect aquatic life forms (Crisp, 1989; Tubbing & Admiral, 1991), and pathological effects have been reported for liver and gills (Grizzle *et al.*, 1984; Albassam *et al.*, 1987; West *et al.*, 1988). Acting as stressors, they may evoke chronically elevated blood cortisol levels which increase the susceptibility to pathogenic bacteria and suppress reproductive processes (Pickering, 1989).

The body surface is in intimate contact with the water and therefore is the first tissue exposed to water pollutants. However, most studies on the effects of pollutants on the body surface have been limited to the branchial or the intestinal epithelium (cf. Albassam *et al.*, 1987; Lang *et al.*, 1987; Burkhardt-Holm *et al.*, 1990; Wendelaar Bonga & Lock, 1992). With the exception of some studies that

‡Author to whom correspondence should be addressed.

TABLE I. Some chemical parameters of Rhine water near Lobith (mean values; data from RIWA, unpublished) and the tap water used in the control experiment

Parameter	Units	Rhine water	Tap water
General:			
HCO ₃ ⁻	mg l ⁻¹	167	43
Cl ⁻	mg l ⁻¹	201	175
SO ₄ ²⁻	mg l ⁻¹	78	70
Na ⁺	mg l ⁻¹	103	89
K ⁺	mg l ⁻¹	7.1	5.8
Ca ²⁺	mg l ⁻¹	89	64
Mg ²⁺	mg l ⁻¹	11.6	9.9
NH ₄ ⁺	mg l ⁻¹	0.41	<0.05
NO ₃ ⁻	mg l ⁻¹	3.9	1.5
Heavy metals:			
Fe	mg l ⁻¹	1.0	<0.01
Al	µg l ⁻¹	190	5
As	µg l ⁻¹	1	0.1
Cd	µg l ⁻¹	0.1	0.01
Cu	µg l ⁻¹	7	10
Pb	µg l ⁻¹	5	4
Zn	µg l ⁻¹	30	2
Organic micropollutants:			
CN ⁻	µg l ⁻¹	3.5	—
Polyaromatic carbohydrates	µg l ⁻¹	0.21	—
HCB	µg l ⁻¹	<0.01	—
Atrazine	µg l ⁻¹	0.06	—
2-Chlorophenol	µg l ⁻¹	<5	—
Benzene	µg l ⁻¹	0.1	—
Cholinesterase-inhibitors (such as parathion)	µg l ⁻¹	0.26	—

revealed the formation of epidermal papillomas in fish exposed to polluted fresh water (Grizzle *et al.*, 1984; Smith *et al.*, 1989), the sensitivity of the skin to pollutants has received little attention. The skin of fish is a metabolically very active tissue, that quickly responds to stressors (Whitcar, 1986; Iger *et al.*, 1992), consisting of several cell types, in particular filament cells, mucous cells, sensory cells and chloride cells (Whitcar, 1986). We have recently reported the effects on the skin of stressors such as water contaminated with manure or heavy metals, or acidified water (Iger *et al.*, 1988; Iger *et al.*, 1992; Iger & Wendelaar Bonga, 1993). In this paper we report the changes observed in the skin of rainbow trout exposed for periods up to 24 days to Rhine water, known to contain a mixture of toxic substances (Table I) and, possibly, pathological agents. The results are discussed in relation to the general effects of stressors on fish skin that we have described in our earlier studies, and that therefore can be considered as biological indicators of poor water quality. The present study was undertaken in view of the intended attempts to restock the Rhine with salmonids towards the year 2000 (De Zwart & Folkerts, 1990; Tubbing & Admiral, 1991).

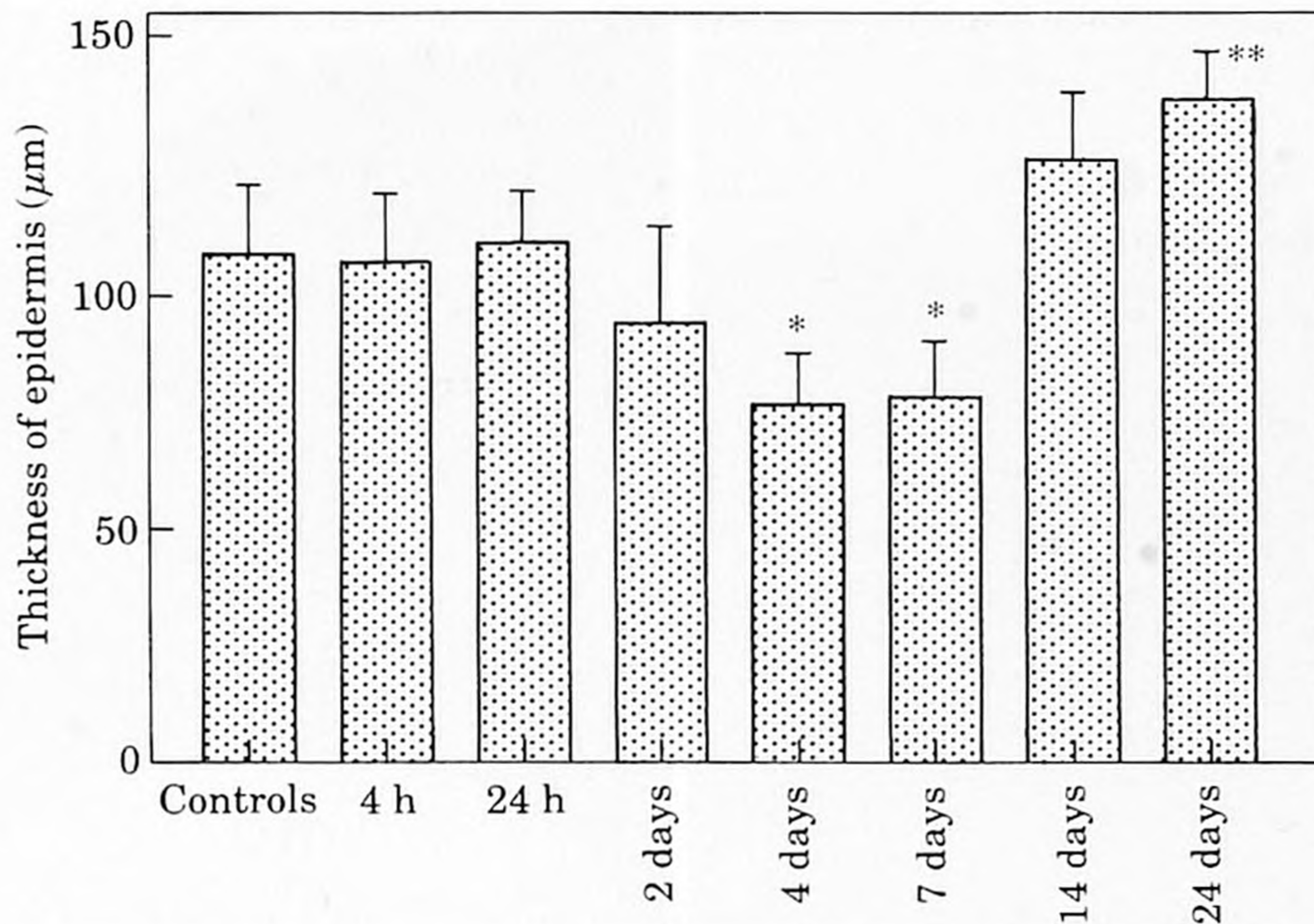


FIG. 1. Thickness of the epidermis of control fish and fish exposed to Rhine water for 4 and 24 h, and 2, 4, 7, 14 and 24 days; * $P < 0.05$; ** $P < 0.01$.

MATERIALS AND METHODS

Forty-two male and female trout *Oncorhynchus mykiss* Walbaum, weighing about 70 g, were kept in two groups for an acclimation period of 22 days in non-chlorinated tap water (pH 7.2–7.4; for composition see Table I) with a temperature of 11.4–13.0° C. One group of trout remained in tap water for the whole period. For the other group, the water was gradually changed (within 2 h) by adding Rhine water (pH 7.0–7.1; temperature 11.5–12.5° C). The water was pumped from near Arnhem, The Netherlands, and was filtered by a lamellar filter system (designed by KEMA, The Netherlands) in a sedimentation chamber, to remove particles larger than 2 mm. The water of both groups was continuously refreshed (flow through of 8–9 l min⁻¹) and well aerated. The concentrations of the main ions and the main pollutants in Rhine water are given in Table I. To reduce handling stress, both control and experimental groups were subdivided into sampling groups that were kept in separate aquaria.

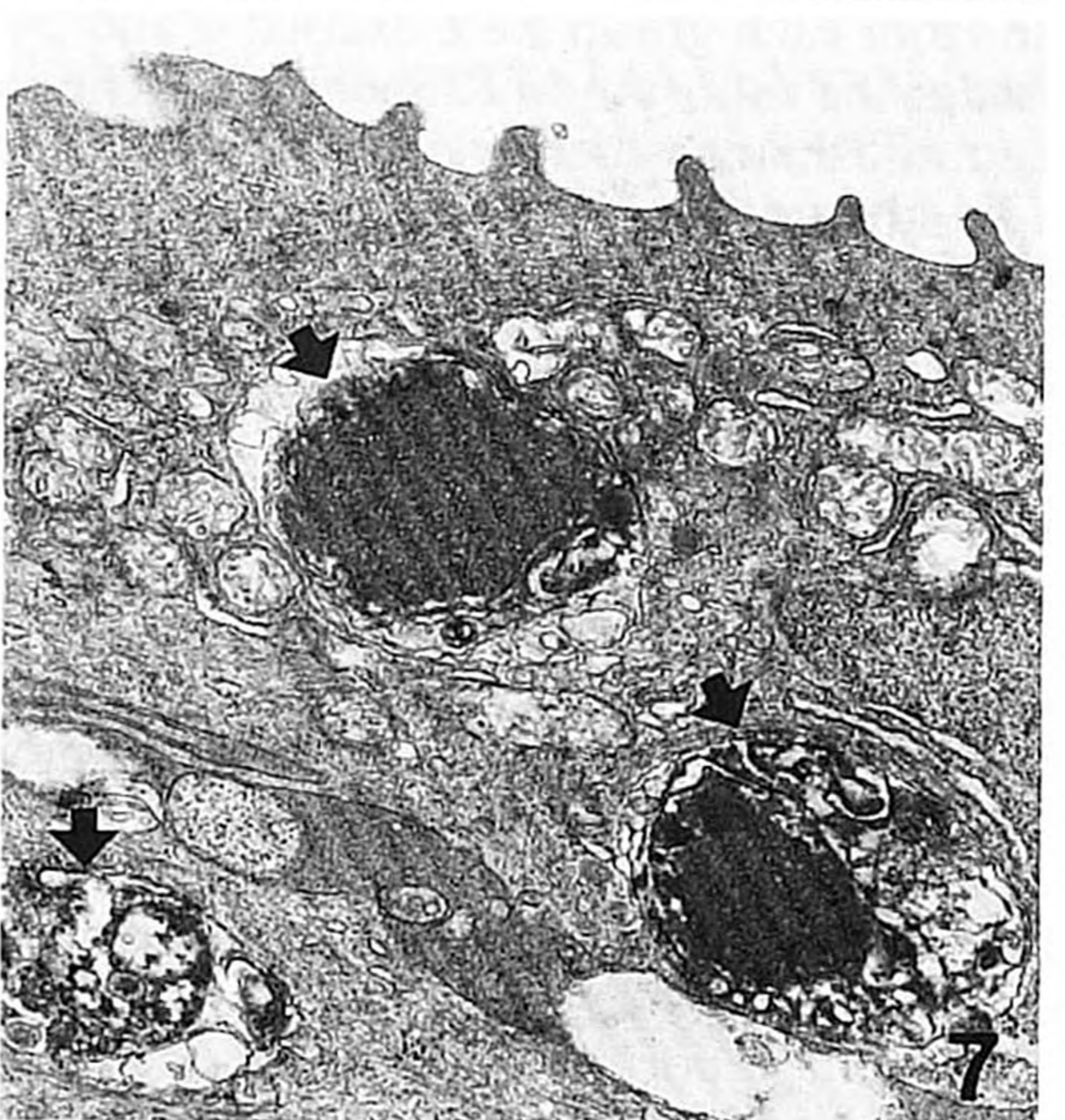
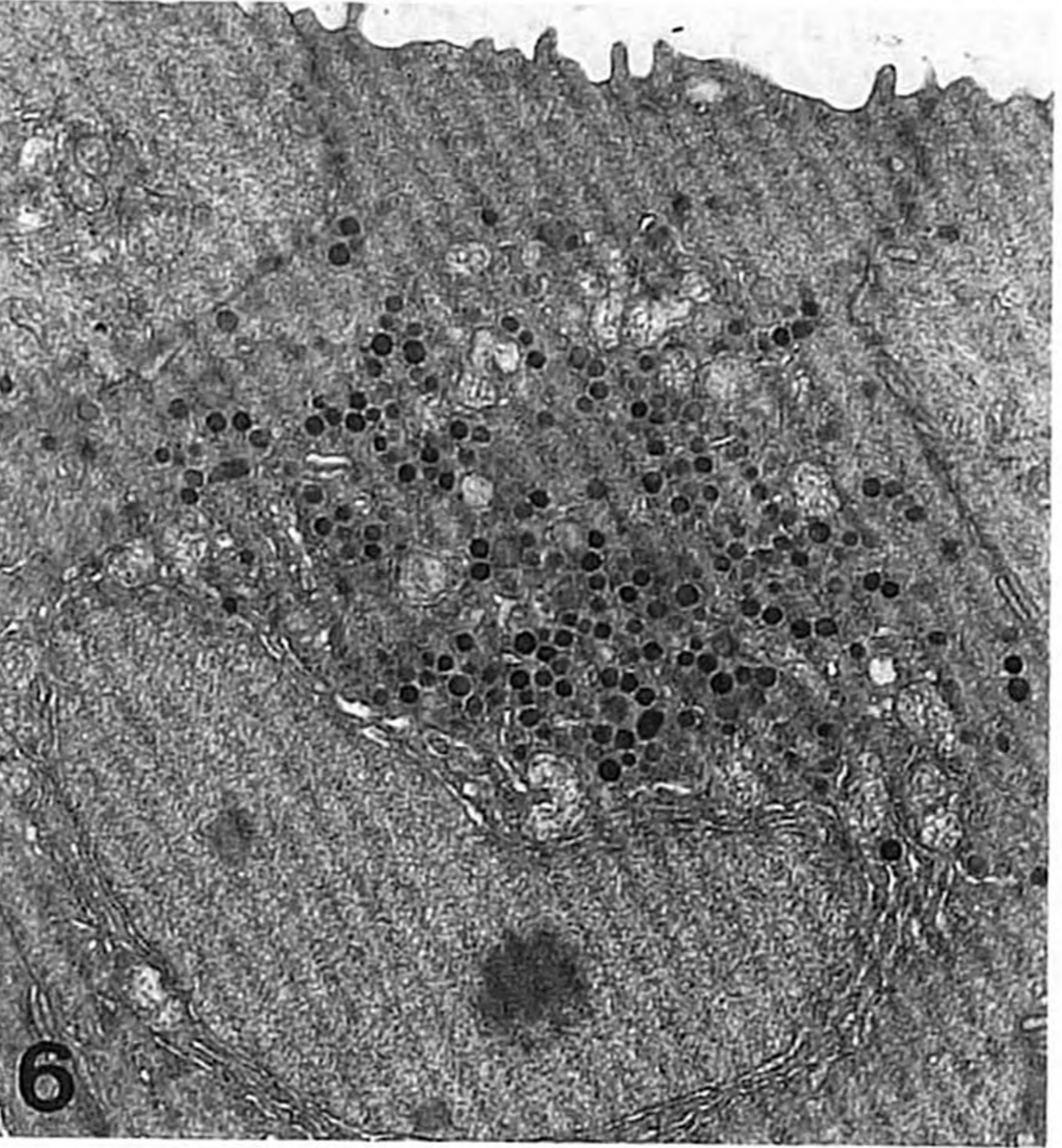

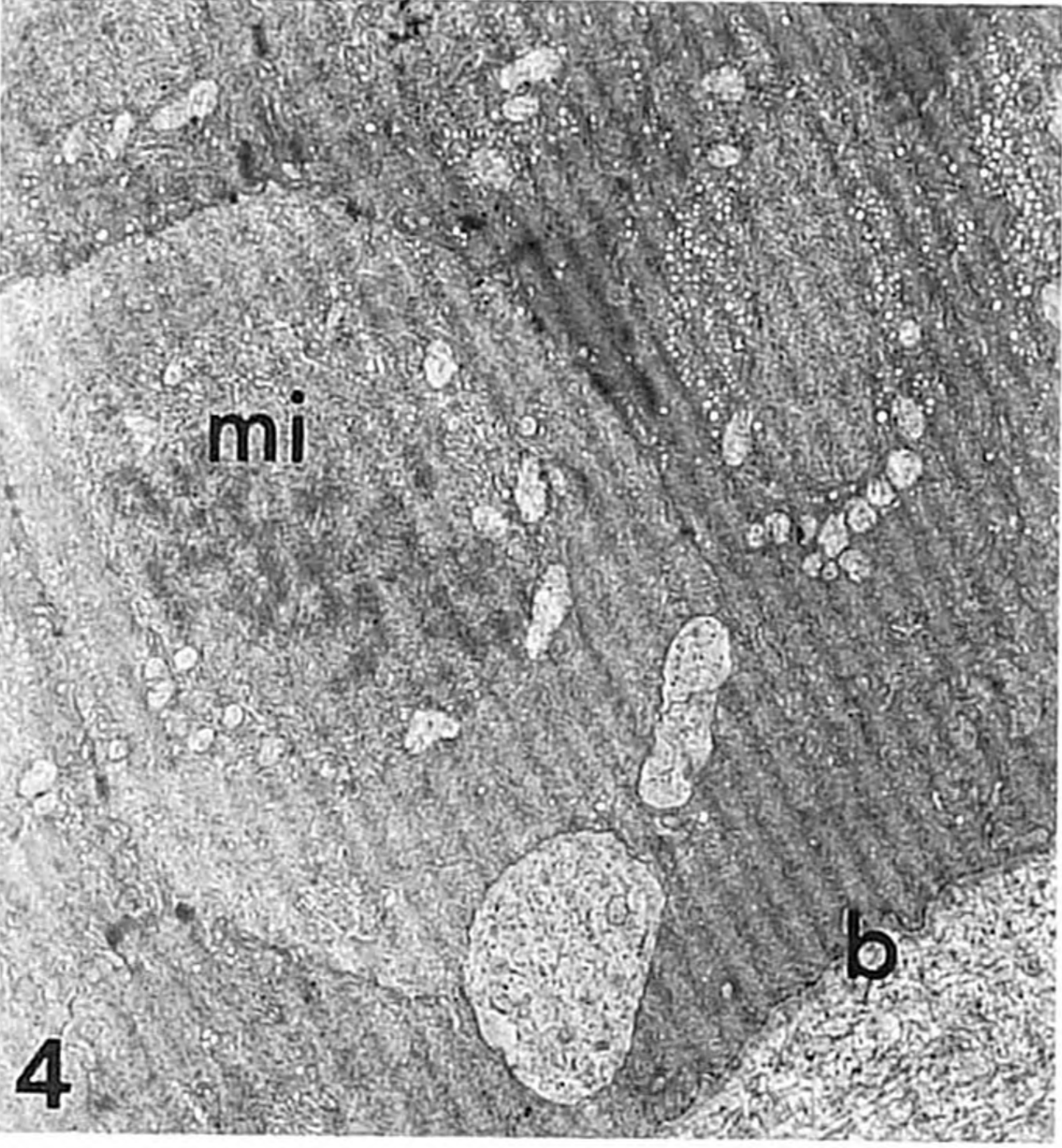
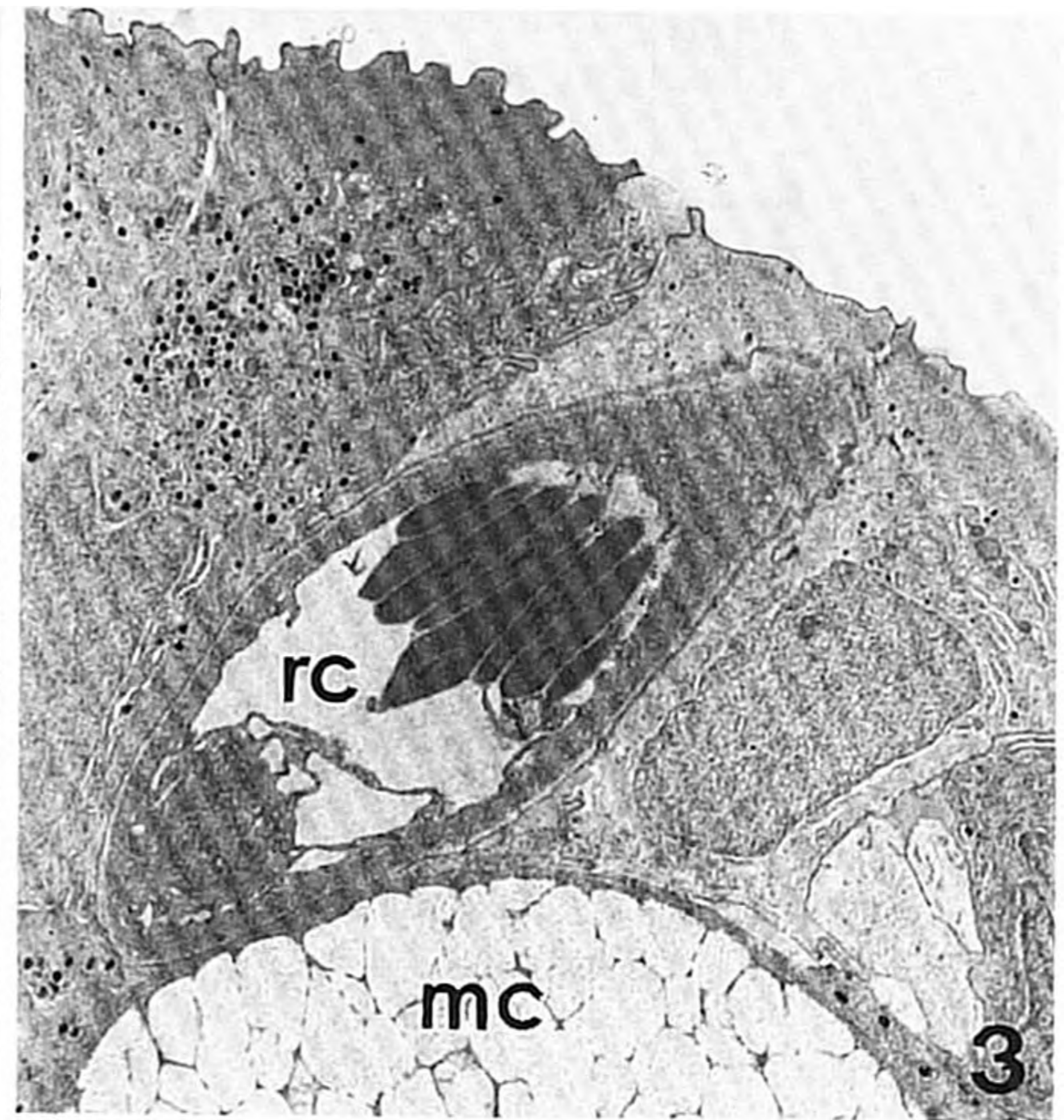
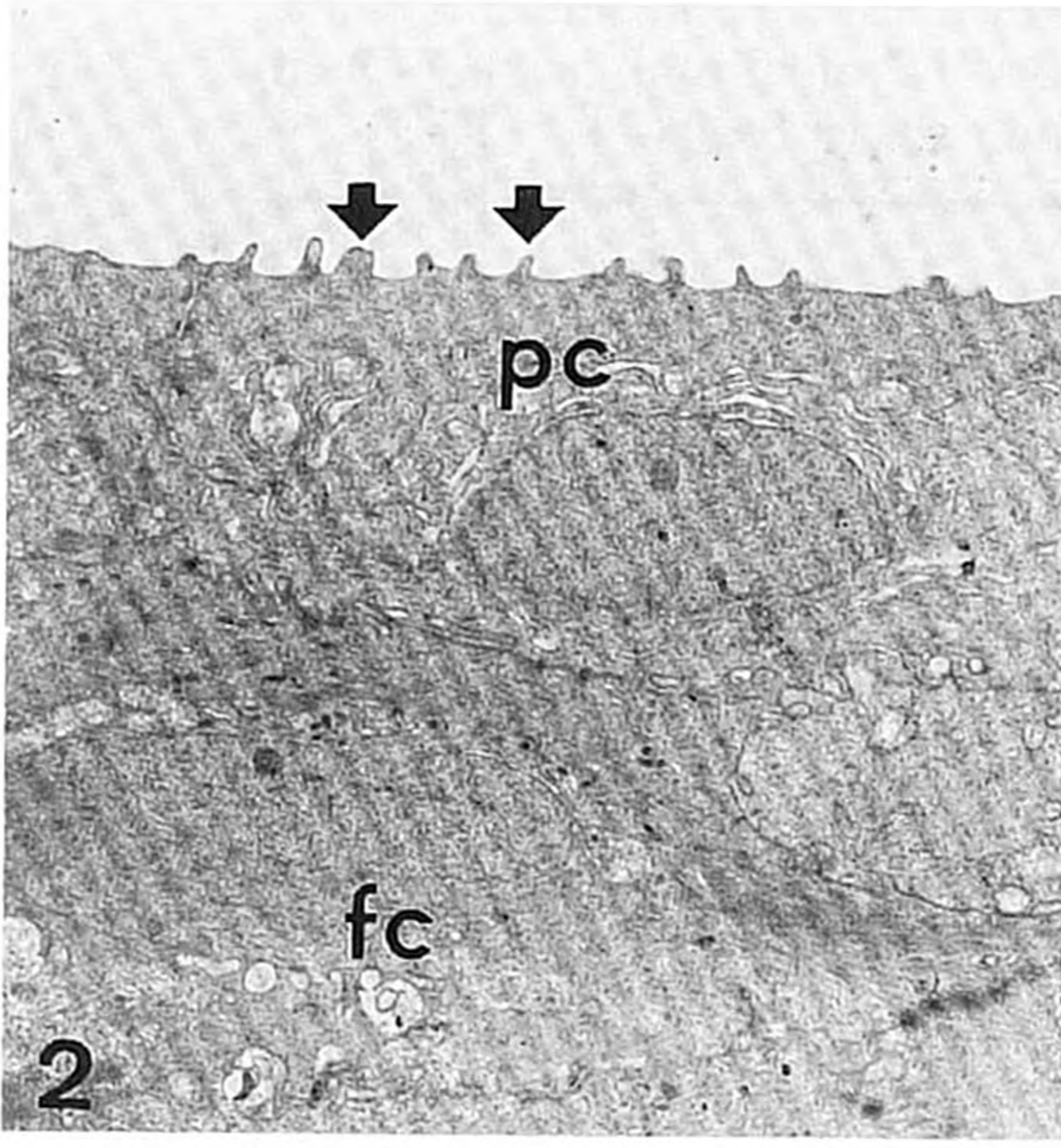
For electron microscopy, pieces of skin (about 3 × 3 mm; thickness 0.5 mm) from three fish from each group were excised 4 and 24 h as well as 2, 4, 7, 14 and 24 days after the start of the exposure to Rhine water. The samples were taken from the dorsal part of the head of fish anaesthetized in a pH-neutralized solution of MS222. The tissues were fixed in 3% glutaraldehyde in sodium cacodylate buffer (0.09 M, pH 7.35), washed in buffer and post-fixed in 1% osmium tetroxide in the same buffer. Ethanol-dehydrated tissues were embedded in Spurr's resin with the tissues oriented tangentially to the mould. Sections cut perpendicularly to the skin surface were stained with uranyl acetate and lead citrate and were examined in a Jeol 100 CXII transmission electron microscope.

The following morphometrical data were obtained from thin sections:

1. Number of secretory vesicles in pavement cells. The sections were scanned and the number of vesicles of high electron density per pavement cell (about 50 μm² of cytoplasm per cell) was counted in seven pavement cells per fish, with intervals of five cells between measured cells. Necrotic as well as apoptotic cells were excluded from this analysis.

2. Thickness of the epidermis. Ten photographs of skin sections at low magnification (× 100) were taken from each fish. Negatives were magnified four times, and then the thickness of the epidermis was measured. Areas with taste buds were excluded from this analysis.

The data reported represent the means ± s.d. of three experimental fish for each time point. Control values were stable during the whole experiment, and therefore were pooled (control values are based on 14 fish). The intra-group variation was checked with



FIGS 2-7.

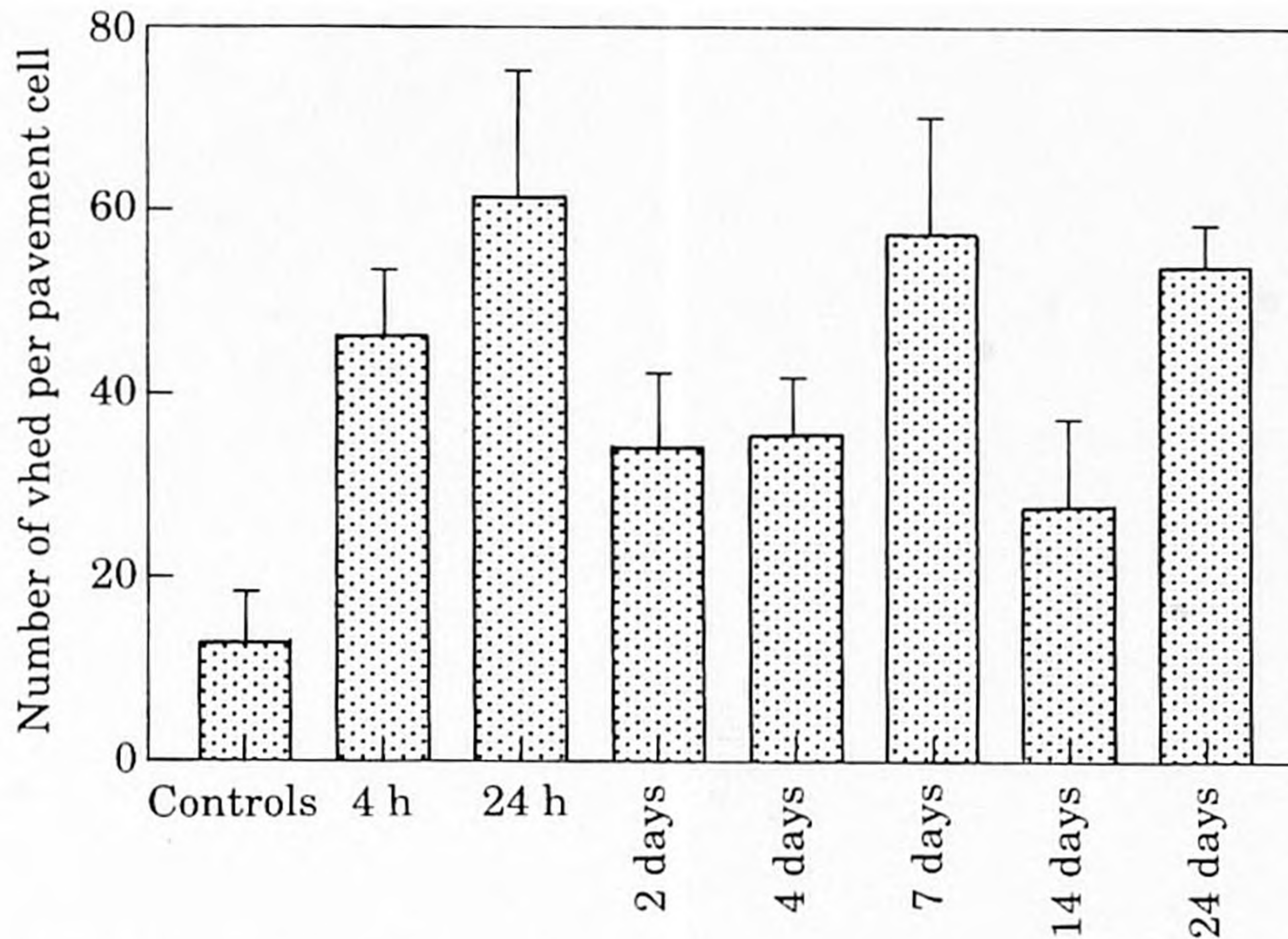


FIG. 8. Number of vesicles of high electron density (vhed) per pavement cell in EM sections. Pavement cells in all experimental groups contained significantly ($P < 0.005$) more vesicles than those of the control group.

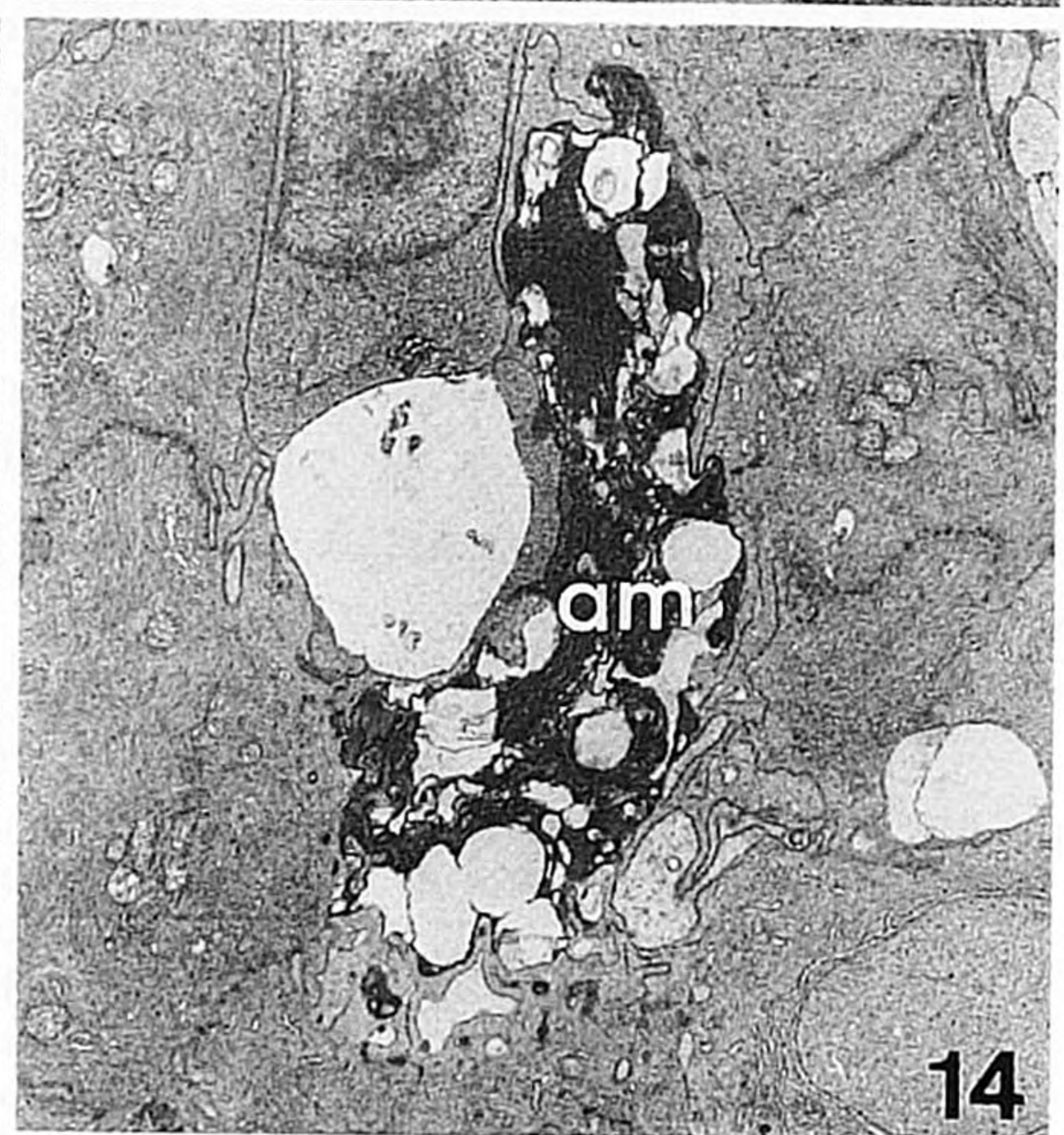
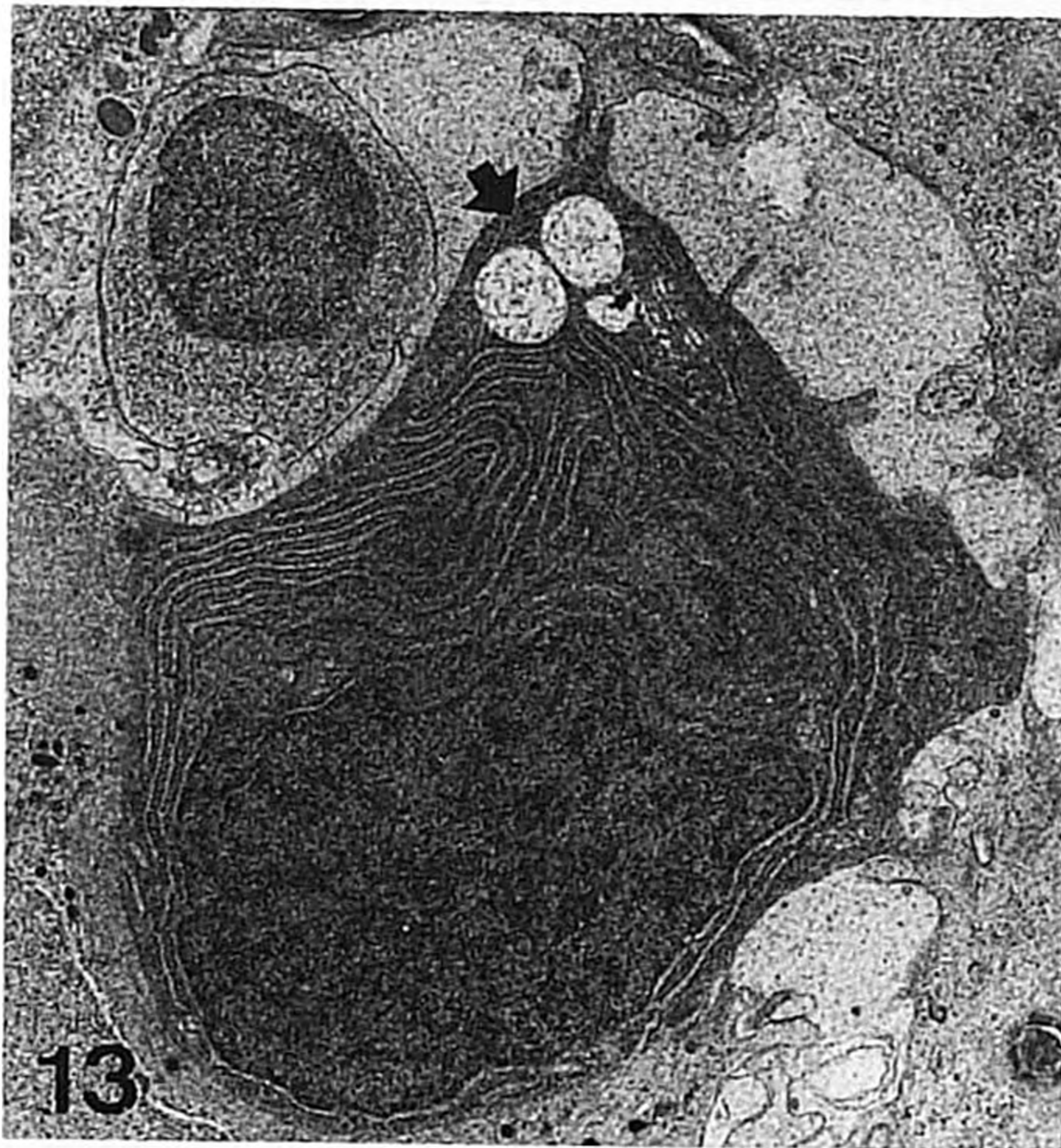
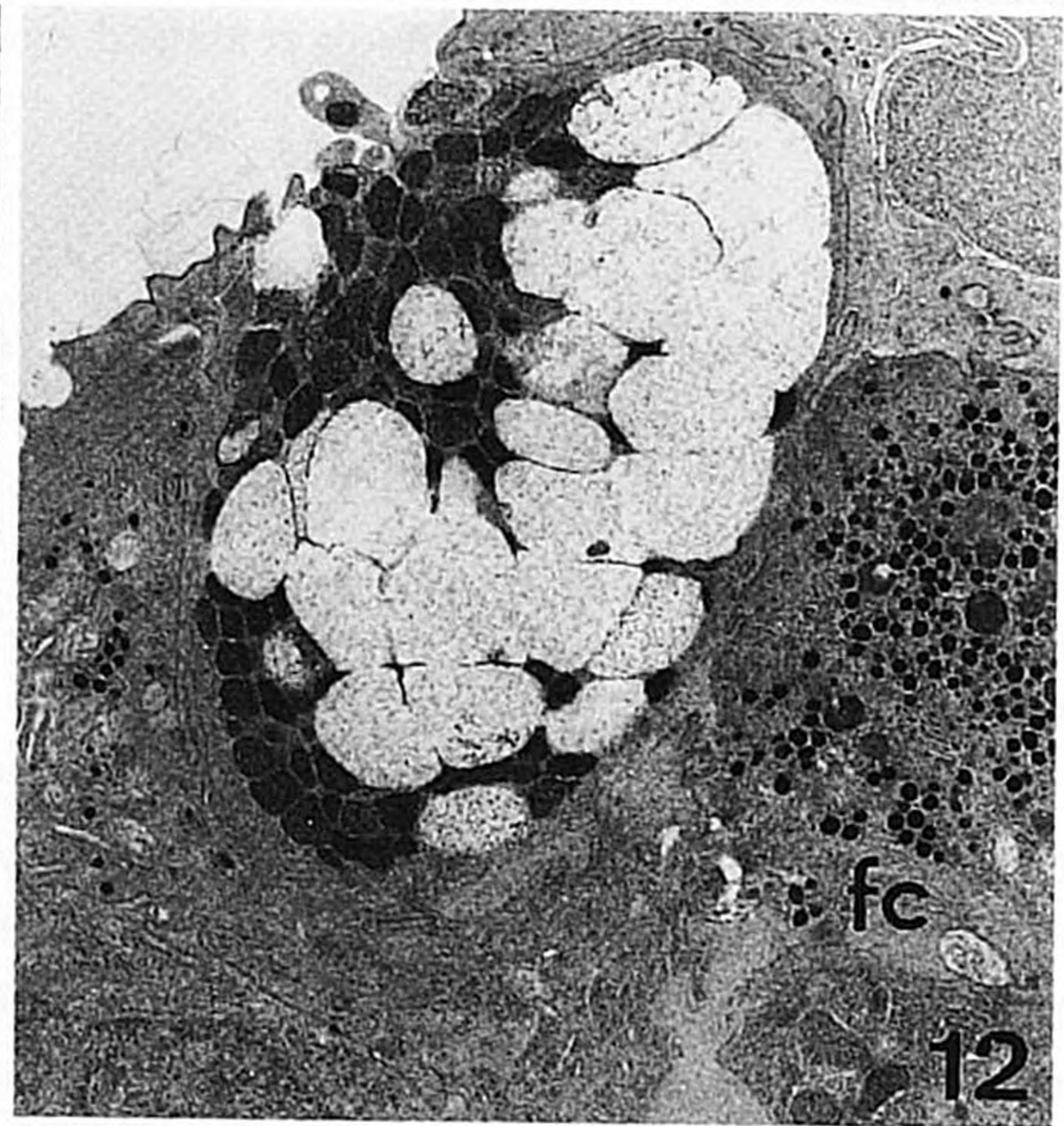
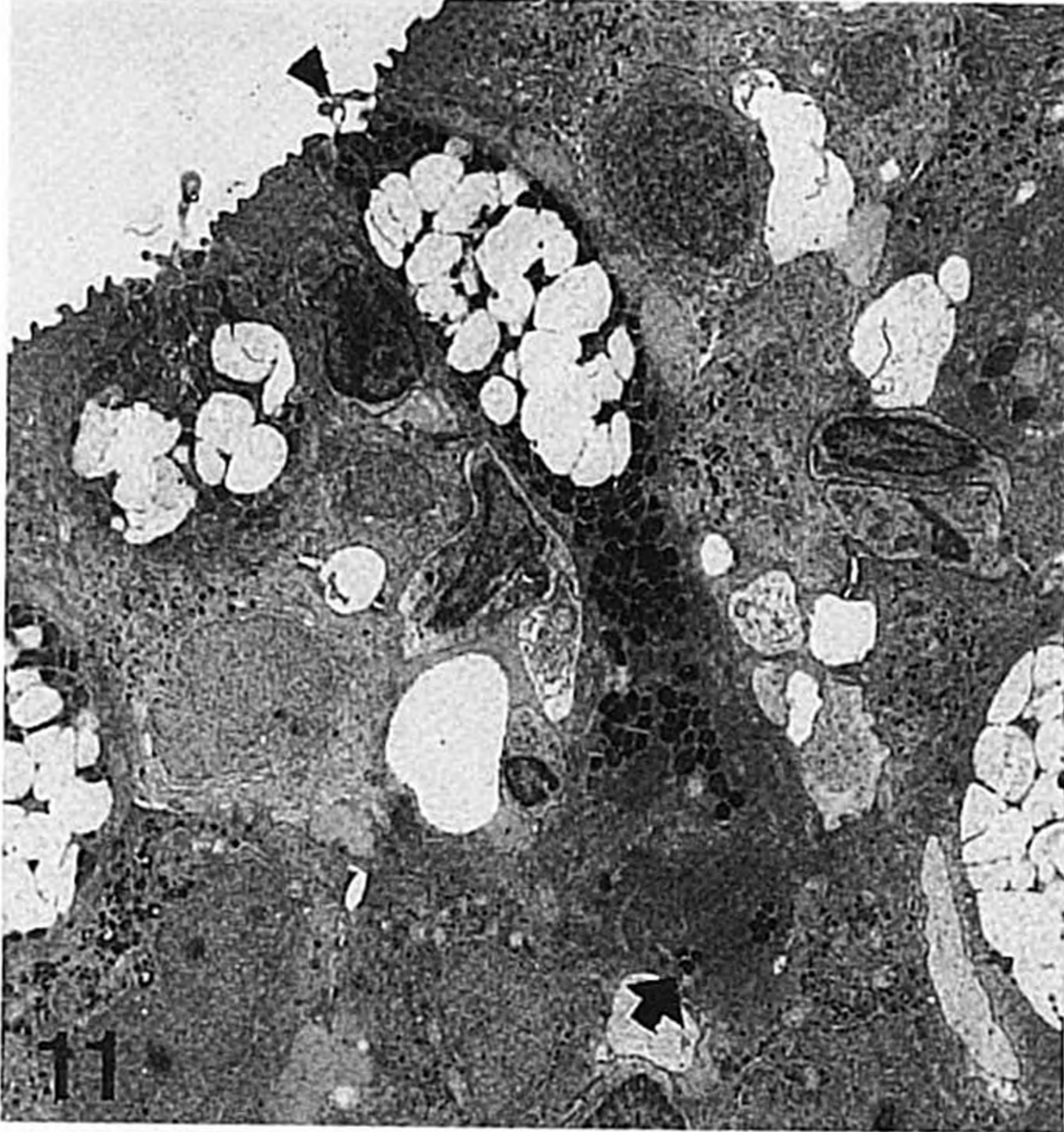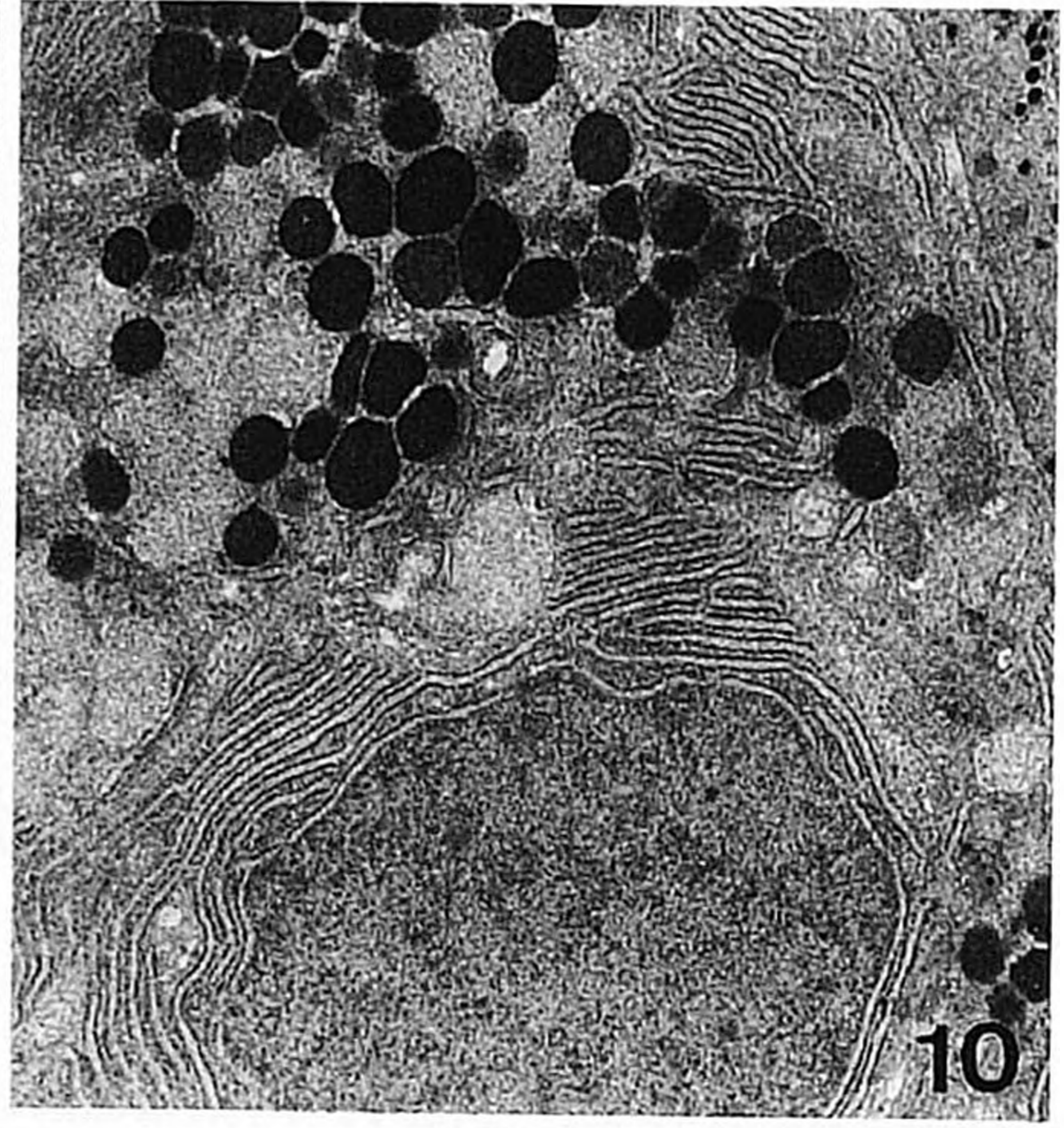
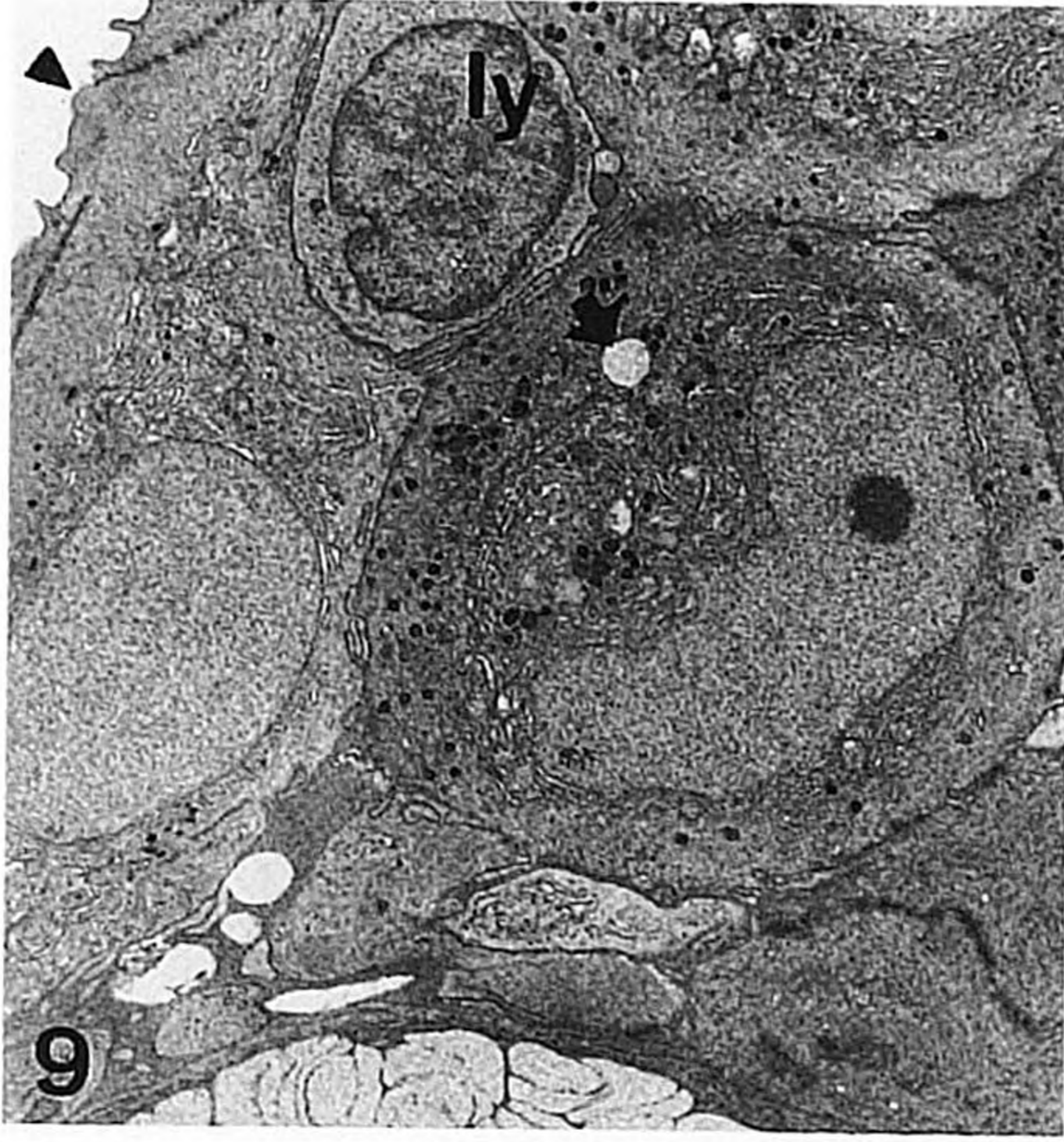
the F -test. Differences between experimental and control groups were tested with Student's t -test. Significant pathological findings are reported only when they were found in the Rhine fish and not in the control fish.

RESULTS

CONTROL

The ultrastructure of the skin of teleost fish, including that of trout, has been described before (Whitear, 1986). Briefly, the epidermis of control rainbow trout was composed of filament-containing epithelial cells (filament cells). The apical membranes of the upper layer of filament cells, called pavement cells, were folded into microridges (Fig. 2). The pavement cells produced some secretory vesicles of high electron density. Oval-shaped mucous cells appeared from the third layer of filament cells from the basal lamina (newly differentiated mucous cells) to the skin surface (mature mucous cells), and contained electron transparent mucosomes. Solitary chemosensory and Merkel cells were occasionally observed. Chloride cells were rare. In both epidermis and dermis, separate lymphocytes were occasionally found. Other types of leucocytes were rare. In the dermis, several different types of pigment cells, i.e. melanocytes, xanthocytes and iridocytes, among fibroblasts and loosely arranged collagen fibres. In the inner dermal zones capillaries were seen.

FIGS 2-7. FIG. 2. Upper layers of skin epithelium of control fish showing a pavement cell (pc) characterized by microridges (arrows) and underlying filament cells (fc); $\times 4160$. FIG. 3. Rodlet cell (rc) close to the skin surface; mc, mucous cell; 24 h Rhine water exposure; $\times 4160$. FIG. 4. Mitotic filament cell (mi) located close to the basal lamina (b); 7 days Rhine water exposure; $\times 6720$. FIG. 5. Mitotic filament cell (mi) adjacent to pavement cell; mc, mucous cell; 4 days Rhine water exposure; $\times 4160$. FIG. 6. Goblet shaped pavement cell with many electron dense secretory vesicles; 24 h Rhine water exposure; $\times 5760$. FIG. 7. Phagosomes (arrows) inside pavement cell; 14 days Rhine water exposure; $\times 11\ 840$.



FIGS 9-14.

FISH EXPOSED TO RHINE WATER

The trout survived the entire exposure period. During the first 7 days, the fish were darker than the control specimens. After 14 and 24 days, the fish appeared pale and slightly green.

Epidermis

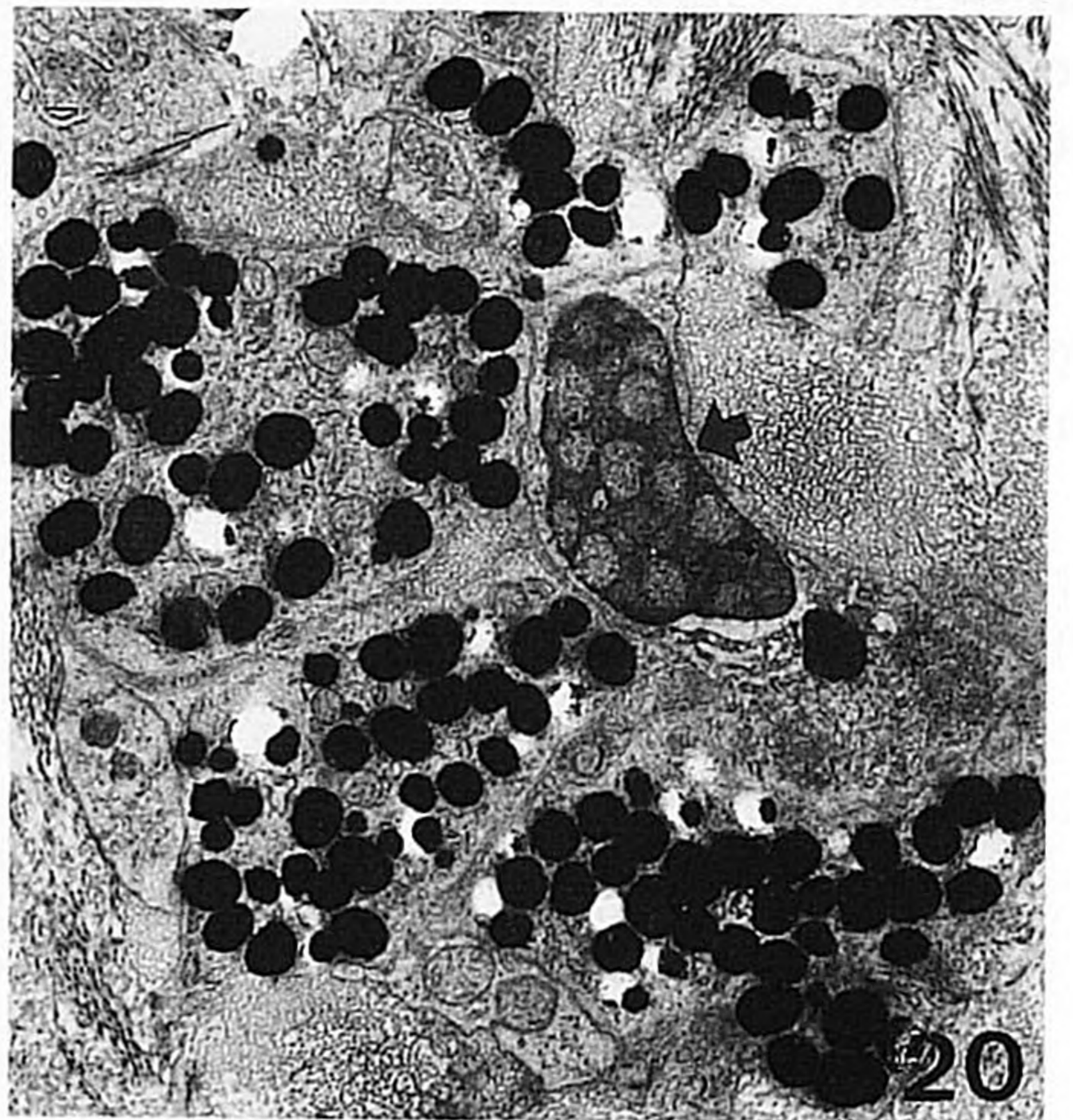
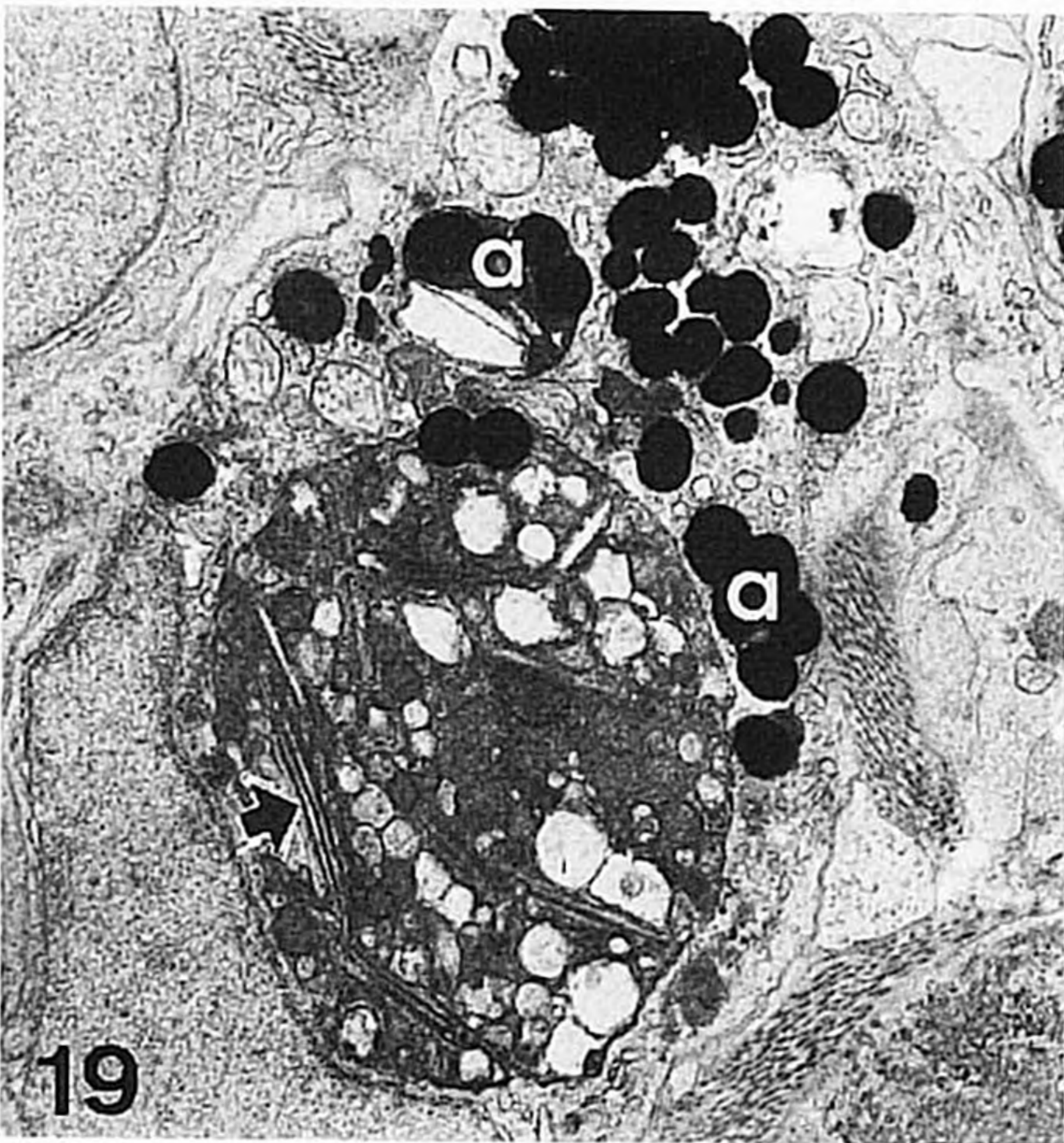
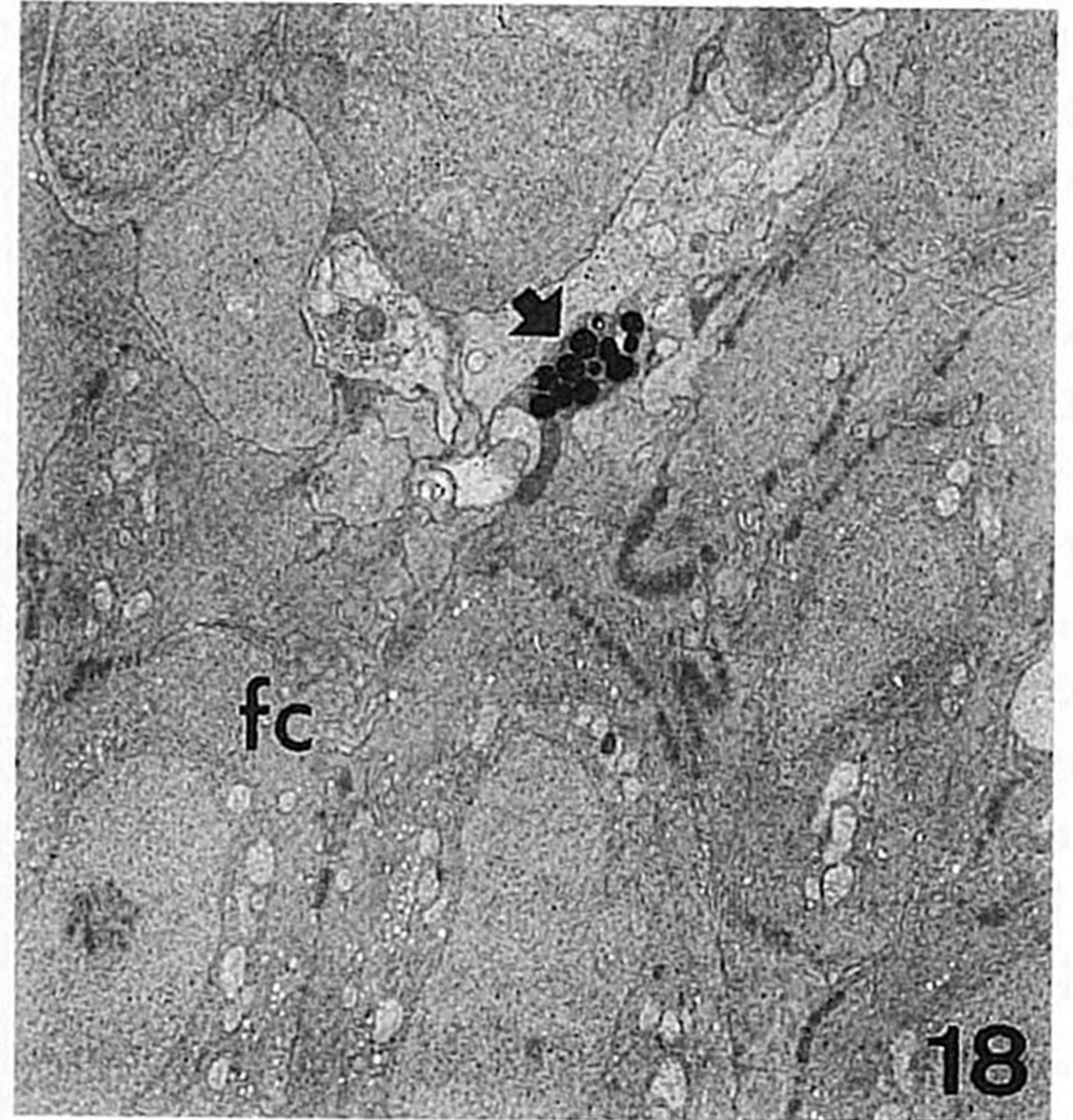
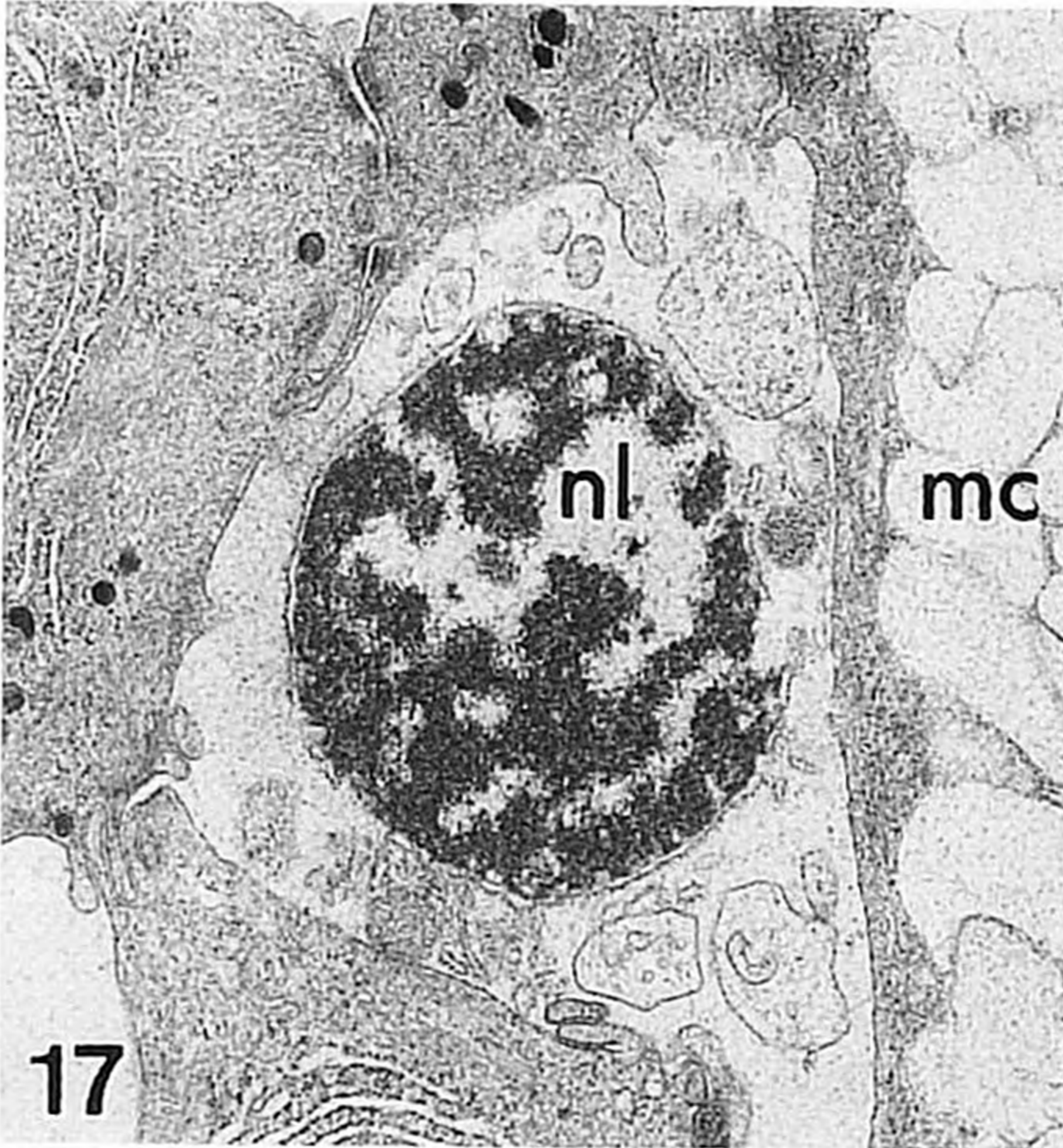
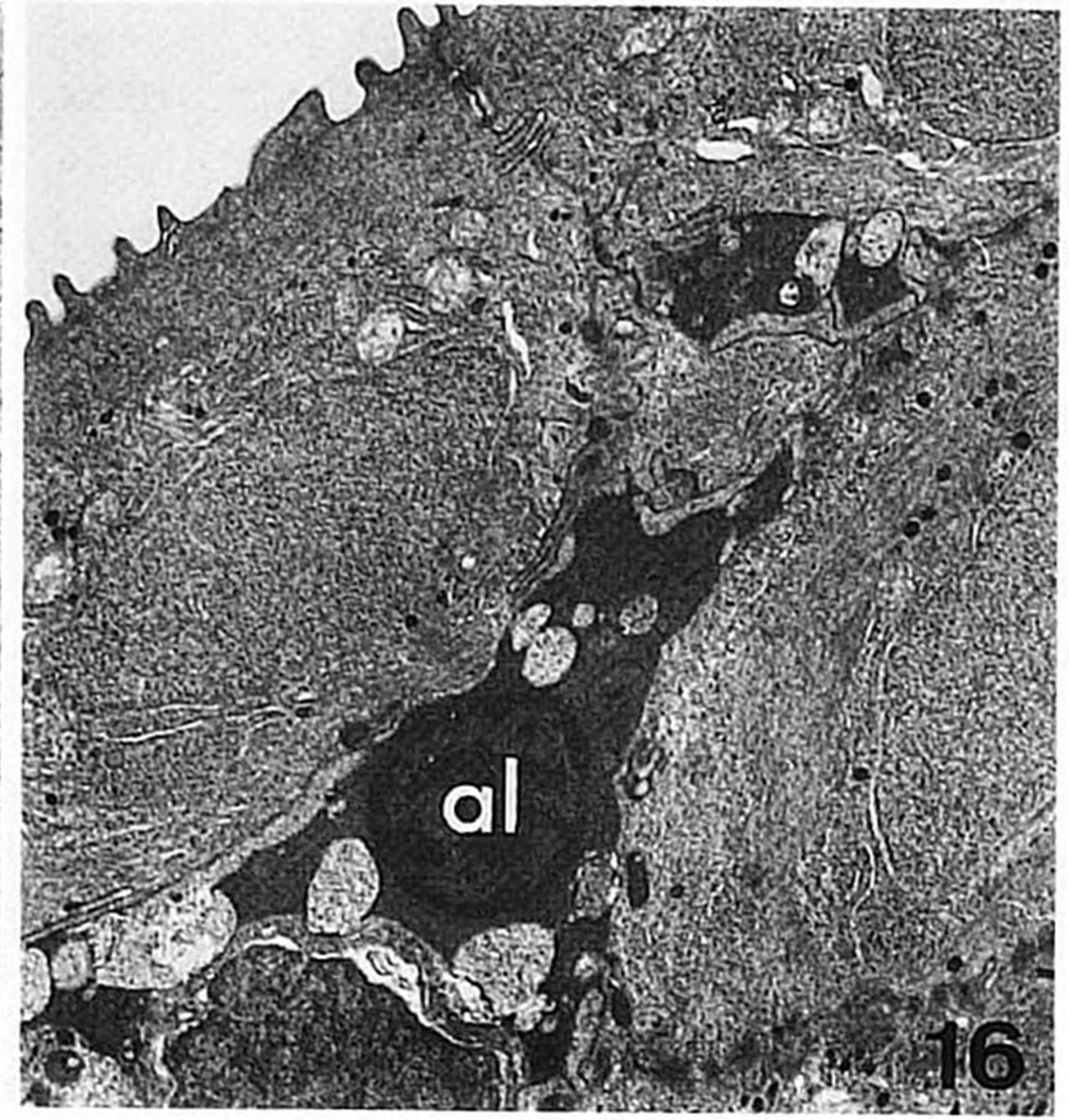
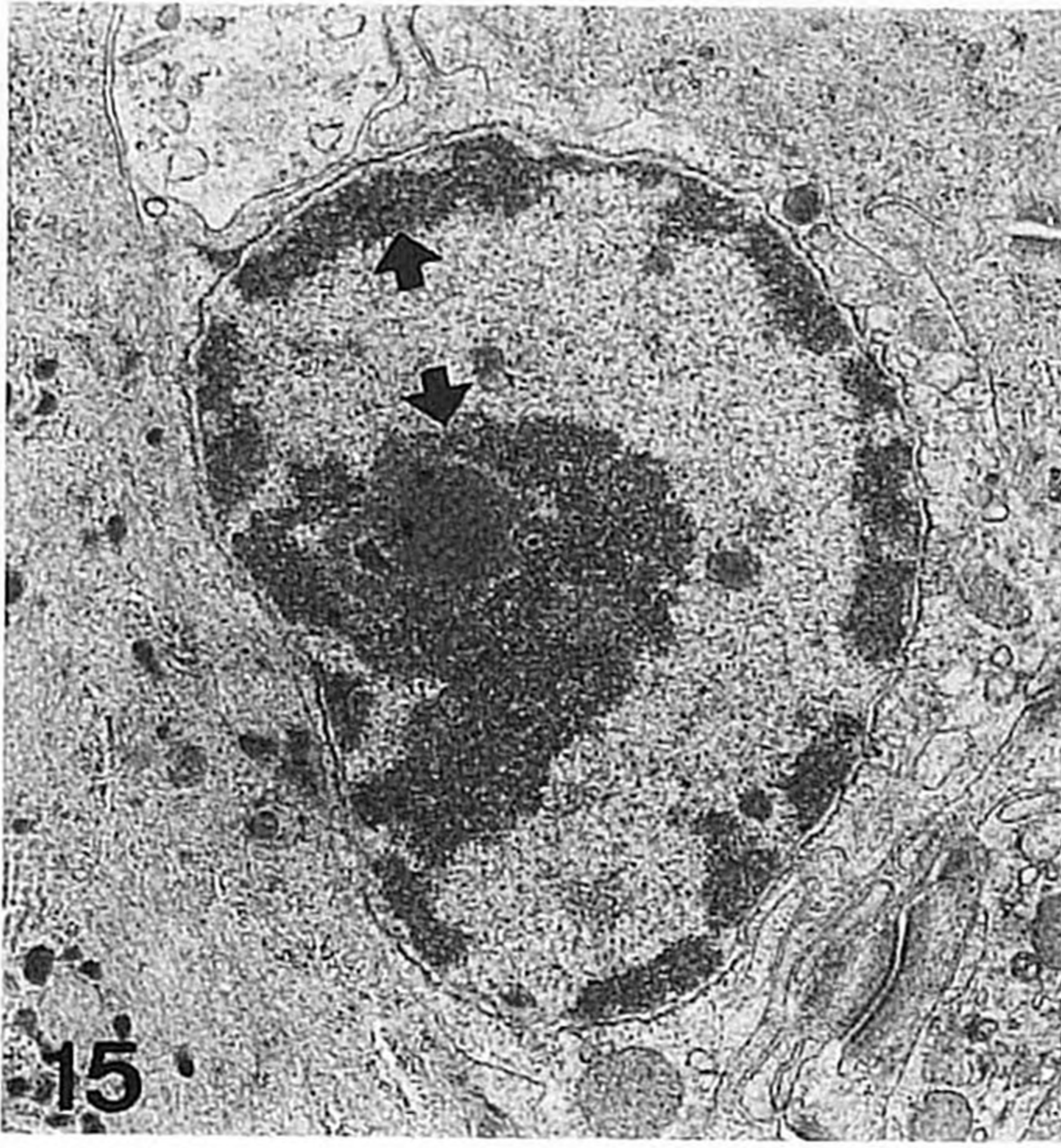
The thickness of the epidermis decreased significantly by about 30% after 4 and 7 days when compared with control values. Thickness was restored and subsequently increased significantly by about 30% after 24 days (Fig. 1).

During the first 4 days, depressed areas, probably representing sites of shedding of degenerated cells, were found at the skin surface. During the whole period, rodlet cells (Fig. 3) were commonly found in the outer epidermal layers. Chloride cells were rare.

Filament cells. Mitotic filament cells, not detected in control fish, were frequently observed from day 4, and occurred throughout the epidermis (Figs 4, 5), with exception of the pavement cell layer. Filament cells containing two nucleoli were also common. From 24 h, pavement cells showing signs of necrosis (swollen cells with disrupted membranes, cytoplasm of transparent electron density and fragmentation of nuclear heterochromatin) were found, while apoptotic pavement cells (shrunken cells showing condensation of cellular components, aggregation of heterochromatin and loss of junctional complexes) appeared from day 4. The non-degenerative pavement cells were oval in shape rather than flattened, and showed signs of increased synthetic activity: well developed rough endoplasmic reticulum (RER) and Golgi areas and many vesicles of high electron density (Fig. 6). The latter were significantly more numerous in the Rhine water exposed fish than in the controls (Fig. 8). Throughout the exposure period, notable synthesis of electron dense vesicles was also found in filament cells of the three to four outermost epidermal layers (Fig. 12) where they were absent in the controls. Towards the end of the experiment (at 14 and 24 days), these filament cells also contained many electron transparent vesicles. Filament cells containing phagosomes were found during the whole period, mainly in the external layers of the epidermis (Fig. 7).

Mucous cells. At 4 and 24 h as well as at 24 days most mature mucous cells were elongated, rather than ovoid, and were located in the outer epidermal layers. Newly differentiated mucous cells (Figs 9, 10) were already apparent at

FIGS 9-14. FIG. 9. Newly differentiated mucous cell located close to the skin surface (arrow head); arrow, mucosome; ly, lymphocyte; 48 h Rhine water exposure; $\times 4160$. FIG. 10. Newly differentiated mucous cell showing extensive RER and mucosomes of high electron density; 14 days Rhine water exposure; $\times 8640$. FIG. 11. Elongated mucous cell showing normal as well as highly electron dense mucosomes. Mucosomes are apparently secreted from the apical part (arrow head), while newly formed mucosomes are at its basal pole (arrow); 24 h Rhine water exposure; $\times 2240$. FIG. 12. Rounded mucous cell at skin surface; fc, filament cell filled with electron-dense secretory vesicles; 14 days Rhine water exposure; $\times 5760$. FIG. 13. Newly differentiated mucous cell showing cytoplasm of increased electron density, typical for the first stages of apoptosis; arrow, mucosomes; 7 days Rhine water exposure; $\times 6720$. FIG. 14. Apoptotic mucous cell (am) in mid-epidermal layers; 14 days Rhine water exposure; $\times 4160$.



FIGS 15-20.

48 h. These cells were also located in the outer epidermal layers except the pavement cell layer. During the whole exposure period, mucous cells were seen with extensive RER and with mucosomes of high electron density. In all fish mucous cells containing a mixture of electron dense and normal electron transparent mucosomes were common (Figs 11, 12). During the whole experimental period, another difference with the controls was the presence of apoptotic mucous cells, both newly differentiated (Fig. 13) and mature cells that had not yet released their contents (Fig. 14). Occasionally mucous cells were observed with a nucleus located at the apical cell pole, instead of at the basal pole.

Leucocytes. Lymphocytes were common in the skin of Rhine water-exposed trout. In the epidermis, they were frequently found as clusters adjacent to mucous cells, a phenomenon not observed in control fish. Macrophages were also common and appeared very active, with well-developed RER and Golgi areas, many lysosome-like vesicles, and several phagosomes. Degenerative macrophages, containing onion-like multilamellar bodies, were also found. After 14 and 24 days many apoptotic lymphocytes (Figs 15, 16) were seen. Occasionally also necrotic lymphocytes (Fig. 17) were found, mainly in the outer epidermal layers. Interestingly, degenerated lymphocytes were also found in the dermis, adjacent to the basal lamina.

Dermis

Fibroblasts. From day 4, an increased number of fibroblasts was found in the outer dermal zone, especially close to the basal lamina. They contained abundant RER, large Golgi areas, and many small peripheral vesicles. At 7 days, the outer dermis was filled with collagen fibres that seemed to be randomly arranged. Towards the end of the experiment (days 14 and 24) many dermal 'herrings' were found. These structures were composed of compact bundles of collagen fibres, arranged perpendicularly to the basal lamina. The herrings ran from the basal lamina to the inner dermal zones, and were only rarely observed in the controls.

Pigment cells. During the whole period, the pigment granules of melanocytes were located in the cytoplasmic extensions of these cells, rather than in their cell bodies as in controls. These extensions, restricted to the dermal zone in control fish, penetrated into the epidermis (Fig. 18) already after 24 h. Thereafter they were found all over this tissue up to the layer of the pavement cells. After 14 and 24 days, many of the extensions of the melanocytes in both dermis and epidermis were apoptotic (Fig. 19), typically engulfed by macrophages, and

FIGS 15-20. FIG. 15. Lymphocyte in early stage of degeneration, showing agglutination of heterochromatin (arrows); 14 days Rhine water exposure; $\times 11\ 840$. FIG. 16. Apoptotic lymphocyte (al) located close to skin surface; 14 days of Rhine water exposure; $\times 6720$. FIG. 17. A necrotic lymphocyte (nl) adjacent to mucous cell (mc); 24 days of Rhine water exposure; $\times 11\ 840$. FIG. 18. Process of melanocyte (arrow) in the epidermis; fc, filament cells; 24 h Rhine water exposure; $\times 5760$. FIG. 19. Apoptotic processes of melanocyte (a) in macrophage phagosomes; arrow, remnants of iridocyte platelets in another phagosome; 24 days Rhine water exposure; $\times 8640$. FIG. 20. Apoptotic part of xanthocyte (arrow) between non-degenerative processes of melanocytes; 14 days Rhine water exposure; $\times 6720$.

occasionally by filament cells. From day 7, xanthocytes were also very active, as reflected by the presence of well-developed RER and many free ribosomes as well as xanthosomes, in particular close to their nucleus. At the same time the platelets of the iridocytes were oriented towards the nucleus and only rarely towards the skin surface. After 14 and 24 days, iridocytes were rarely seen, mainly as remnants in the phagosomes of macrophages (Fig. 19). At this time also many apoptotic remnants of xanthocytes were found (Fig. 20).

DISCUSSION

This study shows that exposure of rainbow trout to water from the Rhine, has prolonged and pronounced effects on the epidermal and dermal skin layers. Part of the changes observed may represent adaptive responses of the skin, while others indicate exhaustion of this tissue. Several pathologic changes found after 24 days (e.g. apoptosis of lymphocytes or pigment cells) indicate that neither complete recovery nor successful acclimation occurred during this period.

THE EPIDERMIS AND ITS FILAMENT CELLS

The thickness of the epidermis initially decreased, and this was associated with degeneration and sloughing of pavement cells and depleted mucous cells at the epidermal surface. Necrotic cells, reflecting accidental cell death, predominated at first. Apoptotic cells, reflecting physiologically controlled cell death (Wyllie, 1981) and found from day 4 on, might be considered as an indirect effect, likely to be due to accelerated ageing or exhaustion of the highly activated cells. Phagocytotic activity of filament cells, as observed in this study, has been reported earlier for carp filament cells (Iger & Abraham, 1990). The content of the phagosomes indicates that the filament cells participate in the elimination of apoptotic bodies of epidermal cells. Necrosis and apoptosis have been reported for the skin as well as the branchial and intestinal epithelium of fish under the impact of different stressors, e.g. water acidification and pollution with heavy metals or chlorinated hydrocarbons (Burkhardt-Holm *et al.*, 1990; Wendelaar Bonga *et al.*, 1990; Iger, 1992).

Most pavement cells and many neighbouring filament cells, that were not degenerative, showed increased secretory activity. We have previously reported that the synthetic activity of these cells is stimulated by administration of ACTH, probably via cortisol (Iger, 1992). Because ACTH and cortisol are stress hormones (Pickering, 1989), the secretory activity of the pavement cells might be interpreted as part of the stress response of the fish (Iger *et al.*, 1992).

After the initial decrease, the thickness of the epidermis was restored and even significantly increased when compared with the controls. This was associated with the appearance of mitotic cells. Epidermal hyperplasia was also reported in the skin of fish exposed to water polluted with manure or lead (Iger *et al.*, 1988; Iger, 1992), as well as in the branchial epithelium of fish exposed to low water pH or nitrogenous waste products such as ammonia (Lang *et al.*, 1987; Wendelaar Bonga *et al.*, 1990). It may represent a general and adaptive response of external epithelia to stressors. In addition to proliferation of the filament cells, the infiltration by leucocytes and the moderate increase in intercellular spaces might have contributed to the epidermal thickening. These phenomena are commonly

observed in the epidermis of skin and gills of stressed fish (Whitaker, 1986; Wendelaar Bonga & Lock, 1992; Iger, 1992).

Mucous cells

Increased mucus secretion, stimulated in fish exposed to Rhine water, has been reported in fish exposed to various pollutants or to acidified water, or suffering from parasitic infection (Burton *et al.*, 1984; Benedetti *et al.*, 1989; Wendelaar Bonga *et al.*, 1990; Iger, 1992; Iger & Wendelaar Bonga, 1993). We distinguished between two responses, which were time-dependent, of the mucous cells to Rhine water. First, migration of mucous cells towards the skin surface could be concluded from the appearance of many mucous cells in the upper layers of the epidermis. Second, changes in mucus composition could be inferred from the appearance of mucosomes of high electron density, which probably reflects a more serous composition of the mucus (Whitaker, 1986). This type of mucosome was also found in skin of fish stressed by heavy metals, manure, social interaction (Iger, 1992; Iger *et al.*, 1992), or ectoparasites (Blackstock & Pickering, 1980).

Leucocytes

Exposure to Rhine water evoked invasion of the epidermis by many lymphocytes and macrophages. We have reported leucocyte infiltration in carp *Cyprinus carpio* L. skin after administration of manure or lead to the water (Iger *et al.*, 1988; Iger, 1992), in acid water (Iger & Wendelaar Bonga, 1993) and after wounding (Iger & Abraham, 1990). This infiltration has also been described for branchial epithelium in response to water pollutants or handling of many fish species (Albassam *et al.*, 1987; Wendelaar Bonga & Lock, 1992) and for intestinal epithelium of fish in response to various chemicals, mainly pesticides (Burkhardt-Holm *et al.*, 1990). It probably represents a non-specific immune response. Furthermore, this phenomenon may cause, or contribute to, the leucopenia that is characteristic of stressed fish (Pickering & Pottinger, 1987). The phagocytic activity of macrophages in the Rhine water exposed fish indicates damage of the inner epidermal layers. Macrophages participate in the elimination of apoptotic and necrotic cell remnants (Wyllie, 1981). The observed apoptosis of leucocytes may be associated with the increased susceptibility to diseases of stressed fish (Pickering, 1989; Secombes *et al.*, 1992). In this respect, it is of interest that *Glugea* infection observed in fish from coastal areas of the North Sea was ascribed to the impact of Rhine water (Vethaak & Van der Meer, 1991). The observed degeneration of leucocytes is reminiscent of the glucocorticoid-induced apoptosis of leucocytes that is well known from mammals (Munck & Crabtree, 1981).

DERMIS

Fibroblasts

Migration of fibroblasts to the periphery of the dermis, followed by fibrosis of this zone, is characteristic for different stressors including pollution with heavy metals, sewage sludge, wounding of the skin, or water acidification (Bucke *et al.*, 1983; Iger & Abraham, 1990; Iger *et al.*, 1992; Iger & Wendelaar Bonga, 1993). The resulting highly dense fibrous dermis, that also contained

many dermal herrings, suggests increased resistance of this tissue against mechanical forces.

Pigment cells

Dispersion of melanosomes into the melanocyte extensions explains the darkening of the skin that was observed during the initial exposure to Rhine water. This response has also been reported after exposure of fish to heavy metals, water acidification, social stress or thermal pollution (Iger, 1992; Iger *et al.*, 1992; Iger & Wendelaar Bonga, 1993). Thus it may be a general response to stressors, an interpretation supported by the observation that darkening of the skin of the Atlantic salmon (*Salmo salar* L.) and the common carp was observed after administration of the stress hormone ACTH (Langdon *et al.*, 1984; Iger, 1992). The melanosome dispersion was followed, in our study, by penetration of melanocyte extensions into the epidermis. We have previously suggested that this pigment migration may serve as a defence mechanism (Iger, 1992; Iger & Wendelaar Bonga, 1992), because intermediates of the melanin synthetic pathway have bactericidal capacities (Edelstein, 1971). The subsequent concentration of the melanosomes in the cell bodies of the melanocytes, and the appearance of many apoptotic melanocytes might have caused the pale colour of the fish towards the end of the experiment. Morphological colour change associated with apoptosis of melanocytes has been described earlier for the cichlid fish *Cichlasoma citrinellum* (Dickman *et al.*, 1988) and for carp exposed to heavy metals (Iger, 1992).

Our observations show that exposure to Rhine water induced changes in the skin of trout that were similar to those observed after exposure of fish to different types of stressors. This indicates that Rhine water exposed fish were indeed stressed, probably by the mixture of pollutants present in this water although other factors, such as pathological organisms, cannot be excluded. In an additional, unpublished, experiment on rainbow trout we have observed that even after 59 days of exposure to Rhine water the phenomena described in the present study after 24 days were still present. Although the quality of Rhine water has gradually improved in the last few years (Den Hartog *et al.*, 1992), our results indicate that long-term studies are necessary to analyse the feasibility of restocking the Rhine with salmonids.

The authors are grateful for the technical assistance of Mr J. C. A. van der Meij, Mr S. Spaas, Mr G. van Aerssen, Mr J. Gerretsen and Mrs E. M. Jansen-Hoorweg. The study was carried out by order of the Dutch Electricity Production Sector.

References

- Albassam, M., Moore, J. & Sharma, A. (1987). Ultrastructural and clinicopathological studies on the toxicity of cationic acrylamide-based flocculant to rainbow trout. *Veterinary Pathology* **24**, 34–43.
- Benedetti, I., Albano, A. G. & Mola, L. (1989). Histomorphological changes in some organs of the brown bullhead, *Ictalurus nebulosus* LeSueur, following short- and long-term exposure to copper. *Journal of Fish Biology* **34**, 273–280.
- Blackstock, N. & Pickering, A. D. (1980). Acidophilic granular cells in the epidermis of the brown trout, *Salmo trutta* L. *Cell and Tissue Research* **210**, 359–369.

- Bucke, D., Feist, S. W., Norton, M. G. & Rolfe, M. S. (1983). A histopathological report of some epidermal anomalies of Dover sole, *Solea solea* L., and other flatfish species in coastal waters of south east England. *Journal of Fish Biology* **23**, 565–578.
- Burkhardt-Holm, P., Braunbeck, T. & Storch, V. (1990). Auswirkung der beim Sandoz-Unfall im November 1986 in den Rhein gelagten Chemikalien auf die Ultrastruktur des Darms von Aalen. In *Limnologie Aktuell*, Vol. 1, *Biologie des Rheins* (Kinzelbach, R. & Friedrich, G., eds), pp. 393–404. Stuttgart: Gustav Fischer.
- Burton, D., Burton, M. P. & Idler, D. R. (1984). Epidermal condition in post-spawned winter flounder, *Pseudopleuronectes americanus* (Walbaum), maintained in the laboratory and after exposure to crude petroleum. *Journal of Fish Biology* **25**, 593–606.
- Capel, P. D., Giger, W., Weichert, P. & Wanner, O. (1988). Accidental input of pesticides into the river Rhine. *Environmental Science and Technology* **22**, 992–997.
- Crisp, D. T. (1989). Some impacts of human activities on trout, *Salmo trutta*, populations. *Freshwater Biology* **21**, 21–33.
- Den Hartog, C., Van der Brink, F. W. B. & Van der Velde, G. (1992). Why was the invasion of the river Rhine by *Corophium curvispinum* and *Corbicula* species so successful? *Journal of Natural History* **26**, 1121–1129.
- Dethlefsen, V. & Tiews, K. (1985). Review on the effects of pollution on marine fish life and fisheries in the North Sea. *Journal of Applied Ichthyology* **3**, 97–118.
- De Zwart, D. & Folkerts, A. (1990). Monitoring the toxicity of organic compounds dissolved in Rhine water. *Hydrobiological Bulletin* **24**, 5–12.
- Dickman, M. C., Schliwa, M. & Barlow, G. W. (1988). Melanophore death and disappearance produces color metamorphosis in the polychromatic Midas cichlid (*Cichlasoma citrinellum*). *Cell and Tissue Research* **253**, 9–14.
- Edelstein, L. M. (1971). Melanin: a unique biopolymer. *Pathobiology Annual* **1**, 309–324.
- Grizzle, J. M., Mellus, P. & Strength, D. R. (1984). Papillomas of fish exposed to chlorinated wastewater effluent. *Journal of the National Cancer Institute* **73**, 1133–1142.
- Iger, Y. (1992). Adaptive reactions in the skin of the common carp (*Cyprinus carpio*) under the impact of ecological factors and wounding. Ph.D. Thesis, The Hebrew University of Jerusalem.
- Iger, Y. & Abraham, M. (1990). The process of skin healing in experimentally wounded carp. *Journal of Fish Biology* **36**, 421–437.
- Iger, Y. & Wendelaar Bonga, S. E. (1994). Cellular responses of the skin of carp (*Cyprinus carpio*) exposed to acidified water. *Cell and Tissue Research* **275**, 481–492.
- Iger, Y., Abraham, M., Dotan, A., Fattal, B. & Rahamim, E. (1988). Cellular responses in the skin of carp maintained in organically fertilized water. *Journal of Fish Biology* **33**, 711–720.
- Iger, Y., Hilge, V. & Abraham, M. (1992). The ultrastructure of fish skin during stress in aquaculture. In *Progress in Aquaculture Research* (Moav, B., Hilge, V. & Rosenthal, H., eds), pp. 205–214. Oostende: EAS special pub. No. 17.
- Lang, T., Peters, G., Hoffmann, R. & Meyer, E. (1987). Experimental investigations on the toxicity of ammonia: effects on ventilation frequency, growth, epidermal mucous cells, and gill structure of rainbow trout *Salmo gairdneri*. *Diseases of Aquatic Organisms* **3**, 159–165.
- Langdon, J. J., Thorpe, J. E. & Roberts, R. J. (1984). Effects of cortisol and ACTH on gill Na⁺/K⁺-ATPase, SDH and chloride cells in juvenile Atlantic salmon, *Salmo salar* L. *Comparative Biochemistry and Physiology* **77A**, 9–12.
- Munck, A. & Crabtree, G. R. (1981). Glucocorticoid-induced lymphocyte death. In *Cell Death in Biology and Pathology* (Bowen, I. D. & Lockshin, R. A., eds), pp. 329–362. London: Chapman & Hall.

- Paalman, M. A. A. & Van der Weijden, C. H. (1992). Trace metals in suspended matter from the Rhine/Meuse estuary. *Netherlands Journal of Sea Research* **29**, 311–321.
- Pickering, A. D. (1989). Environmental stress and the survival of brown trout, *Salmo trutta*. *Freshwater Biology* **21**, 47–55.
- Pickering, A. D. & Pottinger, T. G. (1987). Crowding causes prolonged leucopenia in salmonid fish, despite interrenal acclimation. *Journal of Fish Biology* **30**, 701–712.
- Secombes, C. J., Fletcher, T. C., White, A., Costello, M. J., Stagg, R. & Houlihan, D. F. (1992). Effects of sewage sludge on immune response in the dab, *Limanda limanda* (L.). *Aquatic Toxicology* **23**, 217–230.
- Smith, I. R., Baker, K. W., Hayes, M. A. & Ferguson, H. W. (1989). Ultrastructure of Malpighian and inflammatory cells in epidermal papillomas of white suckers, *Catostomus commersoni*. *Diseases of Aquatic Organisms* **6**, 17–26.
- Tubbing, D. M. J. & Admiral, W. (1991). Sensitivity of bacterioplankton in the Rhine river to various toxicants measured by thymidine incorporation and activity of exoenzymes. *Environmental Toxicology and Chemistry* **10**, 1161–1172.
- Vethaak, D. & Van der Meer, J. (1991). Fish disease monitoring in the Dutch part of the North Sea in relation to the dumping of waste from titanium dioxide production. *Chemical Ecology* **5**, 149–170.
- Wendelaar Bonga, S. E. & Lock, R. A. C. (1992). Toxicants and osmoregulation. *Netherlands Journal of Zoology* **42**, 478–493.
- Wendelaar Bonga, S. E., Flik, G., Balm, P. H. M. & Van der Meij, J. C. A. (1990). The ultrastructure of chloride cells in the gills of the teleost *Oreochromis mossambicus* during exposure to acidified water. *Cell and Tissue Research* **259**, 575–585.
- West, W. R., Smith, P., Booth, G. M. & Lee, M. L. (1988). Isolation and detection of genotoxic components in a black river sediment. *Environmental Science and Technology* **22**, 224–228.
- Whitear, M. (1986). The skin of fishes including cyclostomes—Epidermis. In *Biology of the Integument*, Vol. 2, *Vertebrates* (Bereiter Hahn, J., Matoltsy, A. G. & Richards, K. S., eds), pp. 8–38. Heidelberg: Springer.
- Wyllie, A. H. (1981). Cell death: a new classification separating apoptosis from necrosis. In *Cell Death in Biology and Pathology* (Bowen, I. D. & Lockshin, R. A., eds), pp. 9–34. London: Chapman & Hall.