



PDF hosted at the Radboud Repository of the Radboud University Nijmegen

This full text is a publisher's version.

For additional information about this publication click this link.

<http://hdl.handle.net/2066/15124>

Please be advised that this information was generated on 2014-11-11 and may be subject to change.

Hip and knee arthroplasty infection

In-111-IgG scintigraphy in 102 cases

Marc W Nijhof^{1,2}, Wim J G Oyen¹, Albert van Kampen², Roland A M J Claessens¹, Jos W M van der Meer³ and Frans H M Corstens¹

We studied indium-111-labeled immunoglobulin G (In-111-IgG) scintigraphy for evaluation of total hip and knee arthroplasty infection in 100 patients (102 arthroplasties) where infection was suspected (85 total hip and 17 total knee replacements, 23 of which proved to be infected, all but 2 late infections). The sensitivity of In-111-IgG scintigraphy for infection was 1.0, for hip and knee arthroplasties the specificities were 0.8 and 0.5, respectively. False-positive results for infection occurred in cementless total hip

arthroplasties up to 14 months after implantation. Aseptic inflammation due to formation of ectopic ossification and foreign-body response, following wear of the polyethylene socket, was responsible for false-positive results. The images should be read in conjunction with radiographs, which reduces the rate of false-positive results. In-111-IgG is a highly sensitive and fairly specific tool for detecting of late infection of total hip and total knee arthroplasties.

Departments of ¹Nuclear Medicine, ²Orthopedics, ³Internal Medicine, University Hospital Nijmegen, PO Box 9101, 6500 HB Nijmegen, The Netherlands. Correspondence: Dr. WJG Oyen, Department of Nuclear Medicine, University Hospital Nijmegen, PO Box 9101, 6500 HB Nijmegen, The Netherlands. Tel +31 24-3613677. Fax -3618942
Submitted 96-08-05. Accepted 97-02-04

Several scintigraphic techniques have been suggested for diagnosis of infected arthroplasties. Although highly sensitive, the value of technetium-99m-labeled methylene diphosphonate (Tc-99m-MDP) bone scintigraphy is limited, because of its poor specificity (Palestro 1995). The value of gallium-67 scintigraphy is reduced by nonspecific uptake of the tracer in traumatized bone (Elgazzar et al. 1995). Labeled-leukocyte scintigraphy appears to be less useful in chronic infection (Elgazzar et al. 1995). To distinguish normal uptake of labeled leukocytes in marrow from pathologic uptake in infection, combined scintigraphy of labeled leukocytes and marrow tracers like Tc-99m-labeled sulfur-colloid is necessary in many cases (Palestro et al. 1990).

Indium-111-labeled immunoglobulin G (In-111-IgG) scintigraphy is a promising new imaging technique to detect focal infections, especially in the locomotor system (Oyen et al. 1992a). Preliminary data indicate that it could also be of value for diagnosing infected arthroplasties (Oyen et al 1991). In-111-IgG does not accumulate in infectious foci by binding to specific receptors, but is delivered to an infectious focus by locally increased vascular permeability for macromolecules (Claessens et al 1995). In this study, we evaluated the diagnostic value of In-111-IgG scintigraphy in infected hip or knee arthroplasties.

Patients and methods

Patients

During 1991-1995, we performed In-111-IgG scintigraphy in 100 patients (median age 62 (22-80) years, 72 women) referred for evaluation of clinically suspected late (all but 2 cases) infection of 85 total hip replacements (55 revisions) and 17 total knee replacements (3 revisions). 64 hip arthroplasties were cemented and 21 were cementless. All arthroplasties, except 1 knee were cemented. The average time between the arthroplasty and the scintigraphy was 4.5 years (6 weeks-21 years).

Radiopharmaceutical

Human nonspecific polyclonal immunoglobulin G, sterile and pyrogen-free monomeric IgG, conjugated to diethylenetriaminepentaacetic acid (MacroScint, R.W. Johnson Pharmaceutical Research Institute, Spring House, PA, USA) was labeled with In-111 (Indium chloride, Mallinckrodt Medical, Petten, The Netherlands) according to the manufacturer's instructions. The labeling efficiency was always higher than 95%. A dose of approximately 2 mg of IgG labeled with 75 MBq In-111 was administered by intravenous bolus injection.

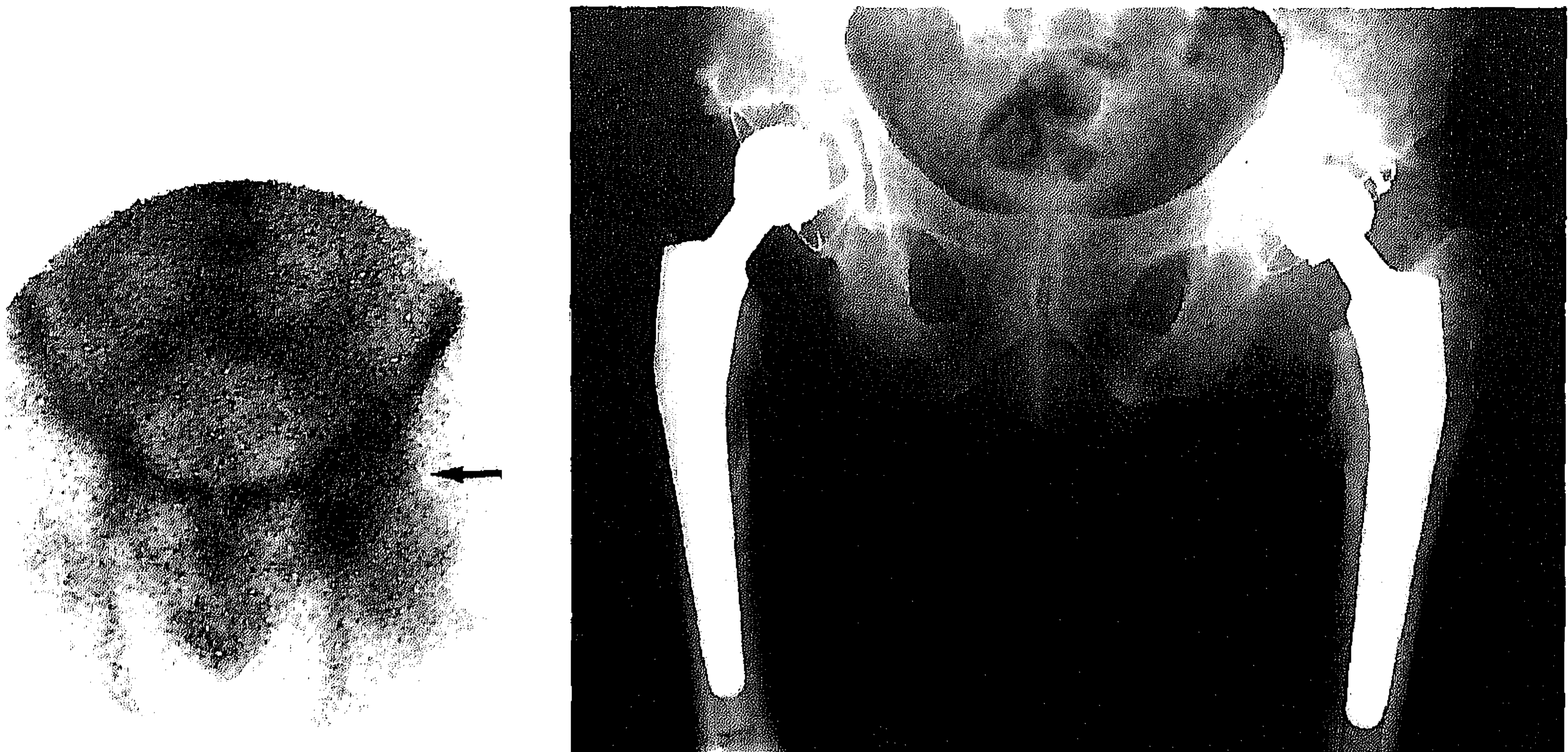


Figure 1. In-111-IgG scintigraphy of a 69-year-old man showing focal accumulation (arrow) of the radionuclide 15 months after implantation of a left total hip arthroplasty (cemented stem, cementless cup). Intraoperative culture showed infection (group G beta-hemolytic *Streptococci*). Small radiolucent zone in the calcar region and some scalloping around the left stem.

Imaging procedures

In-111-IgG images were taken at 4, 18-24 and 42-48 hours after the administration with an Orbiter gamma camera connected to a Scintiview image processor (Siemens Inc., Hoffman Estates, IL, USA).

Image interpretation

All images were interpreted in a blinded manner. The scintigram was interpreted as only positive for infection, if focal, over time, increasing accumulation occurred.

Verification of infection

Infection was confirmed by bacteriological and histological examinations of multiple tissue and fluid specimens taken at surgery (n 64) or needle aspirations (n 13). In all, 25 patients in whom no tissue or aspiration samples for microbiological analysis were obtained, clinical follow-up and repeated radiography for at least 6 months showed no evidence of infection.

23 of the 102 arthroplasties were infected. Of the samples obtained during revision operation of 64 hip and knee arthroplasties, 19 proved to be infected and 44 sterile. In 1 hip arthroplasty, no causative microorganism could be detected, despite histological signs of active inflammation. Cultures of needle aspirates confirmed infection in 3 of 13 arthroplasties, and the remainder were sterile.

In the 22 positive cultures, the pathogen was in 6 cases *Staphylococcus aureus*, in 3 cases *Staphylococcus epidermidis*, in 9 cases streptococcal species, and in 4 cases other or mixed flora.

Results (Table)

Hip arthroplasties

All 20 infected hip arthroplasties showed increased In-111-IgG uptake on the scintigrams. There were no false-negative scintigrams (Figure 1).

Isotope accumulation was false-positive for infection in 12 uninfected arthroplasties (6 revisions, 6 primary implants). 9 of these 12 arthroplasties were cementless, in 6 of them scintigraphy was done no later than 14 months after surgery. In 6 patients with false-positive scintigraphy histological specimens were available and all showed chronic inflammation near the hip arthroplasty. 1 patient with increased In-111-IgG uptake, 6 months after the arthroplasty, still had an inflamed wound, which healed. Wear of the polyethylene socket and subsequent foreign-body response in a hip 17 years after arthroplasty and substantial periarticular ossifications in another hip were responsible for 2 of the false-positive uptakes.

On 7 scintigrams, increased In-111-IgG uptake was found around the neck of the femoral component. However, in 4 of these there was no evidence of infection (2 cemented, 2 cementless, Figure 2). In each of the cases, histological examination revealed an inflammation that was not due to an infection. The remaining 3 arthroplasties (2 cemented, 1 cementless), with accumulation around the neck of the femoral component, proved to be infected.

10 of 11 true-negative In-111-IgG scintigrams of uninfected cementless arthroplasties were found 16 months or longer after implantation. Uninfected ce-

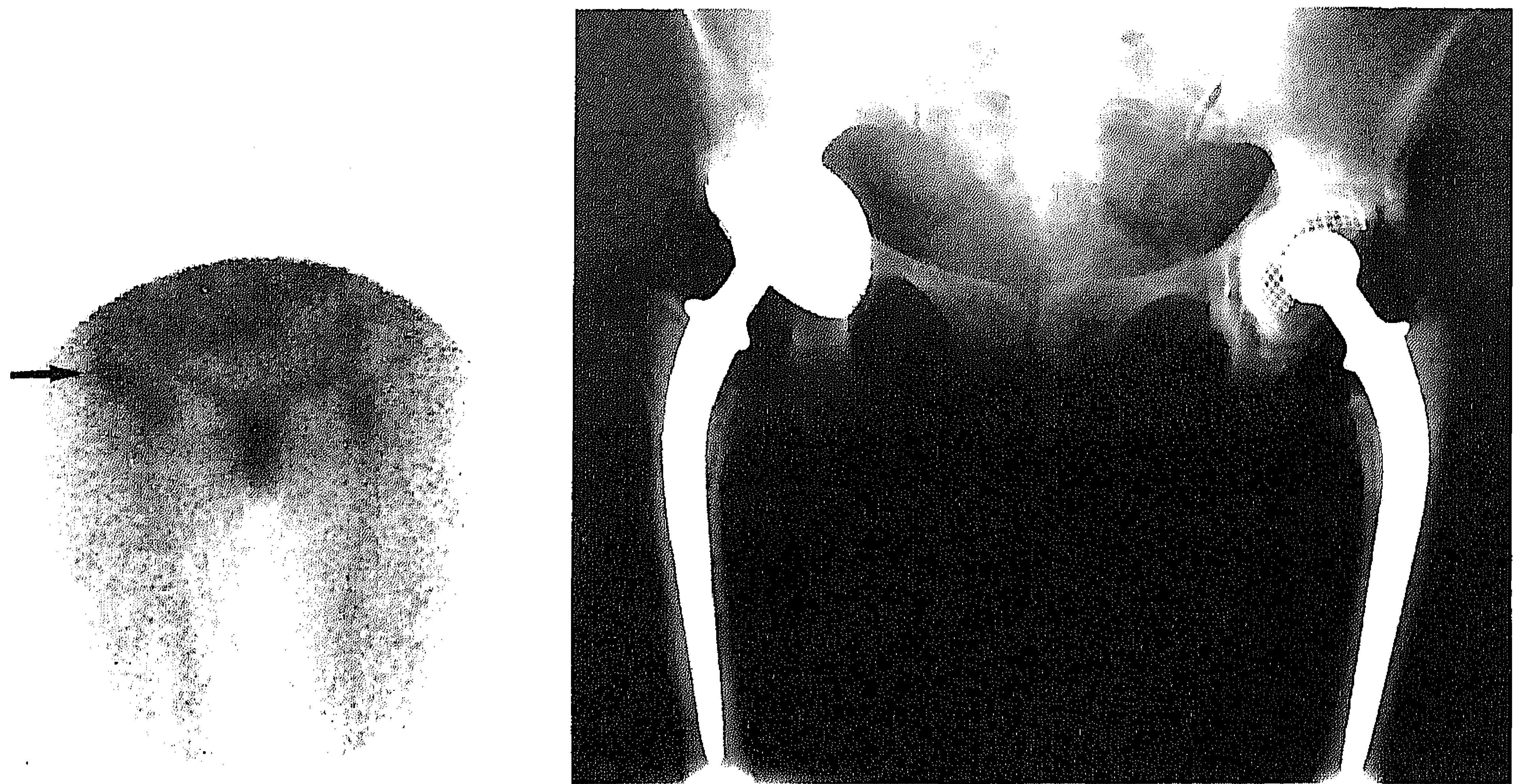

Figure 2. In-111-IgG scintigraphy of a 46-year-old woman with a cemented right total hip arthroplasty 2 years after implantation. Puncture and surgically obtained culture showed no bacteria. Focal accumulation of In-111-IgG due to aseptic inflammation (histology) is seen around the neck of the femoral component of the arthroplasty (arrow). Protrusion of the right total hip arthroplasty, radiolucent zone medial to the stem of the femoral component and periarticular ossifications.

mented arthroplasties showed a normal In-111-IgG distribution already 6 weeks after surgery. Most of the 25 In-111-IgG studies concerning patients in whom no tissue or aspiration samples for microbiological analysis were obtained were negative, while 4 were (false-) positive, due to soft tissue inflammations that were not infectious.

Knee arthroplasties

All 3 infected knee arthroplasties were adequately depicted on In-111-IgG scintigraphy. 7 of the 14 uninfected arthroplasties showed increased, false-positive In-111-IgG uptake. In 5 of these cases, cultures of synovial fluid samples were negative, while the histologic specimens showed signs of chronic inflammation. 1 patient with pain showed focal In-111-IgG ac-

cumulation 7 weeks after the operation. 1 month after the scintigraphy, the pain and the sedimentation rate of the erythrocytes decreased, making infection unlikely. Another patient showed increased In-111-IgG uptake on scintigraphy 11 months after surgery. Although the knee was still painful after 2 years, calcifications in the joint capsule were considered responsible for In-111-IgG uptake, since no signs of loosening or infection developed.

In 3 of 7 false-positive scintigrams, the increased In-111-IgG uptake was probably caused by inflammations of soft tissues with no infection. However, since In-111-IgG showed definite focal accumulation, the scintigrams were scored false-positive for infection (Figure 3).

Overall results of In-111-IgG scintigraphy in total joint arthroplasty

	n	TP	FP	TN	FN	Sensitivity	Specificity	PPV	NPV
Hip									
cemented	64	19	3	42	0	100%	93%	86%	100%
cementless	21	1	9	11	0	100%	55%	10%	100%
overall	85	20	12	53	0	100%	82%	63%	100%
Knee									
overall	17	3	7	7	0	100%	50%	30%	100%

TP true-positive
TN true-negative

FP false-positive
FN false-negative

PPV positive predictive value
NPV negative predictive value

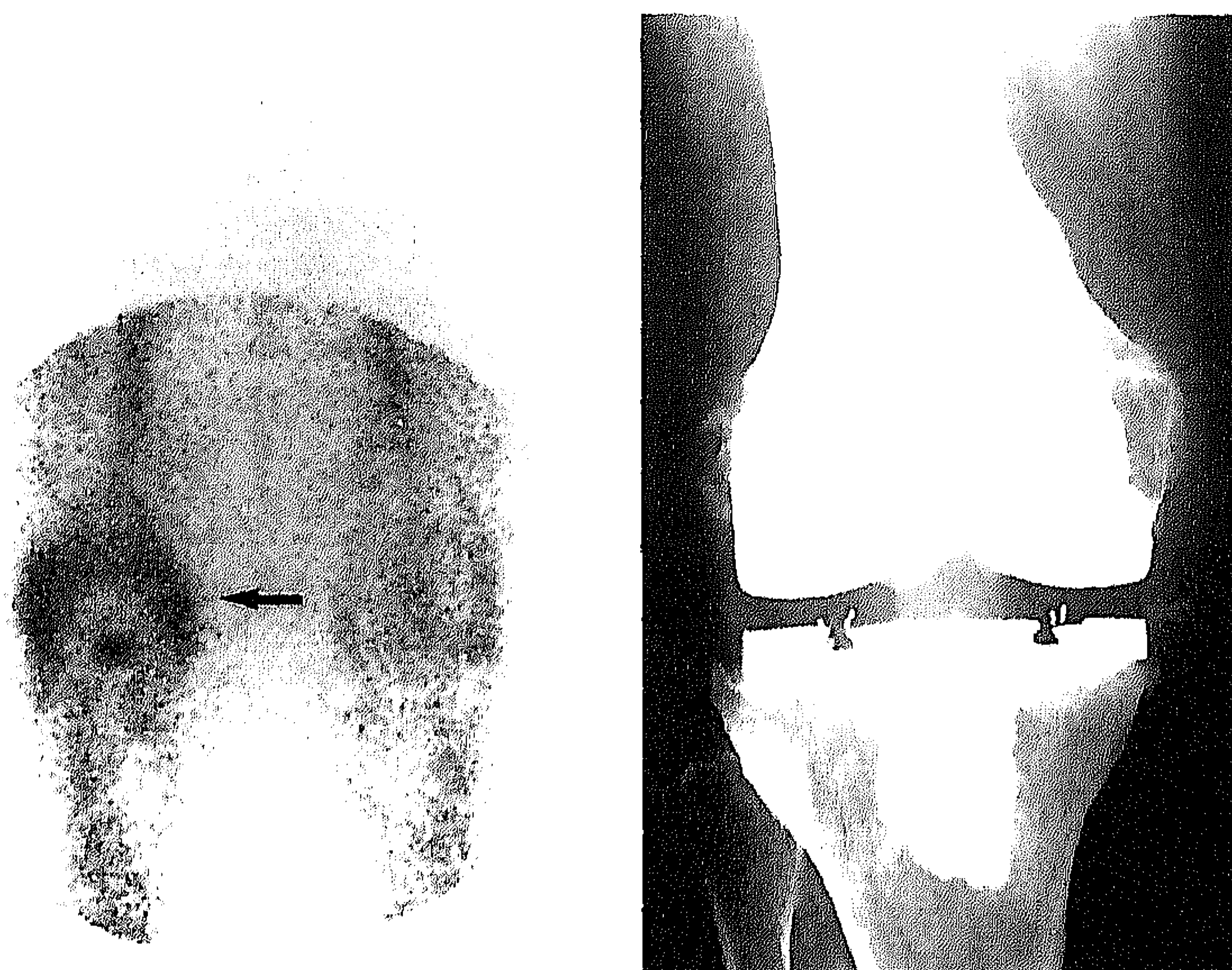

Figure 3. In-111-IgG scintigraphy of 71-year-old woman with a painful swollen right knee, 1 year after total knee arthroplasty. Puncture showed no infection. The focal accumulation of In-111-IgG (arrow) was seen to be located in soft tissues around the arthroplasty and probably caused by aseptic inflammation of soft tissues. Nevertheless, the scintigram was interpreted as false-positive for infection. No radiolucency, only some ossifications laterally in the soft tissues.

Discussion

The sensitivity of In-111-IgG scintigraphy to late infection of hip and knee arthroplasties was high. Since In-111-IgG scintigraphy—like all currently available radiopharmaceuticals—detects inflammation irrespective of the underlying cause (Oyen et al. 1992a, b), the specificity for infection was lower.

Specificity can be increased by taking into account certain pitfalls in image interpretation. We observed that uninfected cementless hip arthroplasties accumulated In-111-IgG much longer postoperatively than cemented hip arthroplasties; increased accumulation was found up to 14 months after implantation. In contrast, cemented hip arthroplasties were true-negative as early as 6 weeks after surgery. This indicates that the value of In-111-IgG scintigraphy is limited within a period of approximately 1 year after cementless hip arthroplasty. Substantial periarticular ossification does not interfere with image interpretation, when the images are read in conjunction with radiographs which clearly visualize the ossifications. A focal inflammatory periprosthetic reaction of soft tissues, e.g., in response to polyethylene wear, may false-positive In-111-IgG results (Oyen et al 1992a). In general, aseptic loosening of an arthroplasty causes increases the uptake of Tc-99m-MDP, but not of In-111-IgG, indicating the usefulness of the latter technique in the differential diagnosis.

Persistent periprosthetic uptake limits the diagnostic value of Tc-99m-MDP bone scintigraphy (Rosenthal et al. 1987). Tc-99m-MDP bone scintigraphy may show increased uptake of no pathologic

significance in cemented arthroplasties for at least 7 months and in uncemented hip prostheses for a period up to 2 years (Utz et al. 1986, Oswald et al. 1989, 1990). Ingrowth of bone and fibrous tissue into the porous coating of the cementless hip arthroplasty may cause focal accumulation of the scintigraphic tracer unrelated to any complication, which might also hold true for In-111-IgG (Wegener and Alavi 1991).

Gallium-67 scintigraphy also lacks specificity in patients with totally replaced joints, since gallium-67 can accumulate in areas of uninfected but increased bone turnover (Elgazzar et al. 1995). Combined bone and gallium-67 scintigraphy increases the specificity of each technique and an accuracy between 60% and 80% has been reported (Palestro 1995).

To increase the specificity of labeled-leukocyte scintigraphy, combined imaging with Tc-99m-labeled sulfur-colloid has been proposed. This method can distinguish between normal and pathologic uptake of labeled leukocytes in marrow and the specificity for inflammation is between 85% and 100% (Palestro et al. 1990, 1991). The disadvantage of using labeled-leukocyte scintigraphy is a decreased sensitivity in chronic infection.

References

- Claessens R A M J, Koenders E B, Boerman O C, Oyen W J G, Borm G F, van der Meer J W M, Corstens F H M. Dissociation of indium from In-111 labeled diethylene triamine penta-acetic acid conjugated nonspecific polyclonal immunoglobulin G in inflammatory foci. *Eur J Nucl Med* 1995; 22: 212-9.

- Elgazzar A H, Abdel-Dayem H M, Clark J D, Maxon H R. Multimodality imaging of osteomyelitis. *Eur J Nucl Med* 1995; 22: 1043-63.
- Oswald S G, Van Nostrand D, Savory C G, Callaghan J J. Three-phase bone and indium white blood cell scintigraphy following porous-coated hip arthroplasty: A prospective study of the prosthetic tip. *J Nucl Med* 1989; 30: 1321-31.
- Oswald S G, Van Nostrand D, Savory C G, Callaghan J J. The acetabulum: a prospective study of three-phase bone and indium white blood scintigraphy following porous-coated hip arthroplasty. *J Nucl Med* 1990; 31: 274-80.
- Oyen W J G, Claessens R A M J, van Horn J R, Slooff T J J H, van der Meer J W M, Corstens F H M. Diagnosing prosthetic joint infections (letter). *J Nucl Med* 1991; 32: 2195-6.
- Oyen W J G, van Horn J R, Claessens R A M, Slooff T J J H, van der Meer J W M, Corstens F H M. Diagnosis of bone, joint, and joint prosthesis infections with In-111-labeled nonspecific human immunoglobulin G scintigraphy. *Radiology* 1992a; 182: 195-9.
- Oyen W J G, Claessens R A M J, van der Meer J W M, Rubin R H, Strauss H W, Corstens F H M. Indium-111-labeled human nonspecific immunoglobulin G: a new radiopharmaceutical for imaging infectious and inflammatory foci. *Clin Infect Dis* 1992b; 14: 1110-8.
- Palestro C J. Radionuclide imaging after skeletal interventional procedures. *Semin Nucl Med* 1995; 25: 3-14.
- Palestro C J, Kim C K, Swyer A J, Capozzi J D, Solomon R W, Goldsmith S J. Total-hip arthroplasty: periprosthetic indium-111-labeled leukocyte activity and complementary technetium-99m-sulfur colloid imaging in suspected infection. *J Nucl Med* 1990; 31: 1950-5.
- Palestro C J, Swyer A J, Kim C K, Goldsmith S J. Infected knee prosthesis: diagnosis with In-111 leukocyte, Tc-99m sulfur colloid, and Tc-99m MDP imaging. *Radiology* 1991; 179: 645-8.
- Rosenthal L, Lepanto L, Raymond F. Radiophosphate uptake in asymptomatic knee arthroplasty. *J Nucl Med* 1987; 28: 1546-9.
- Utz J A, Lull R J, Galvin E G. Asymptomatic total hip prosthesis: natural history determined using Tc-99m MDP bone scans. *Radiology* 1986; 161: 509-12.
- Wegener W A, Alavi A. Diagnostic imaging of musculoskeletal infection: scintigraphy and MRI. *Orthop Clin North Am* 1991; 22: 401-18.