

PDF hosted at the Radboud Repository of the Radboud University Nijmegen

This full text is a publisher's version.

For additional information about this publication click this link.

<http://hdl.handle.net/2066/15118>

Please be advised that this information was generated on 2014-11-11 and may be subject to change.

Evaluation of Infections of the Locomotor System with Indium-111-Labeled Human IgG Scintigraphy

Marc W. Nijhof, Wim J.G. Oyen, Albert van Kampen, Roland A.M.J. Claessens, Jos W.M. van der Meer and Frans H.M. Corstens

University Hospital Nijmegen, Departments of Nuclear Medicine, Orthopedics, and Internal Medicine, Nijmegen, The Netherlands

Indium-111-labeled human nonspecific immunoglobulin G ($^{111}\text{In-IgG}$) is one of the newer agents suggested for scintigraphic evaluation of infection and inflammation. In this study, the utility of this agent was studied in routine clinical practice. **Methods:** A dose of 75 MBq ^{111}In labeled to 2 mg IgG (MacroScint®) was administered intravenously in 226 patients with 232 possible foci of infection or inflammation. Imaging was performed 4, 24 and 48 hr postinjection. The results were verified by culture, obtained either surgically (42%) or via puncture (19%) and long-term clinical and roentgenological follow-up (39%). Follow-up data were used in patients of whom the vast majority had a negative work-up, including negative $^{111}\text{In-IgG}$ scintigraphy. **Results:** All infected total hip (THA) and total knee arthroplasties, focal osteomyelitis, diabetic foot infections, septic arthritis and soft-tissue infections were detected (61 foci). Only one patient with early, low-grade spondylodiscitis was false negative with $^{111}\text{In-IgG}$. Since $^{111}\text{In-IgG}$ scintigraphy does not discriminate between infectious and sterile inflammation, careful interpretation is necessary in cementless THA up to 1 yr after insertion, uptake only around the neck of the femoral component of a THA, recent fractures and pseudarthrosis, in which uptake may be caused by sterile inflammation and not by infection (specificity for inflammation 100%, specificity for infection of 77%). **Conclusion:** Indium-111-IgG scintigraphy is a very sensitive tool for detection of infectious bone and joint disease. Moreover, when uptake patterns of $^{111}\text{In-IgG}$, which are characteristic for sterile inflammation, are excluded, infection can be ruled out with a high degree of certainty.

Key Words: indium-111; spondylodiscitis; arthroplasty; diabetic foot; osteomyelitis

J Nucl Med 1997; 38:1300-1305

Infection and inflammation of the musculoskeletal system is a common condition in clinical practice. Adequate diagnostic modalities are necessary for optimal planning of treatment. In the last decades, a wide variety of procedures have been proposed. Conventional radiography remains the first-step procedure for this group of patients. Radiographs form the basis in the diagnostic work-up, since bone and joint pathology, other than infection, can be identified at relatively low cost without the need for scintigraphic imaging. However, radiographs alone are seldom diagnostic. Therefore, more sophisticated modalities, such as computerized tomography (CT), magnetic resonance imaging (MRI) and nuclear medicine techniques are used. Focusing on the latter, bone scanning with technetium-99m ($^{99\text{m}}\text{Tc}$) diphosphonate is the oldest and most widely used (1). Although these agents have superior sensitivity, specificity is low (1,2). This is caused by high uptake in areas of increased bone turnover of any cause. This is particularly a problem for differential diagnosis in violated bone, for example after arthroplasty or surgery. Similar problems have been reported for

gallium-67 (^{67}Ga) citrate scintigraphy (3). Labeled leukocyte scintigraphy is currently the most commonly used scintigraphic technique for evaluation of infectious and inflammatory diseases, especially when combined with bone marrow seeking tracers in areas where normal bone marrow uptake may be a confusing factor in image interpretation (4). However, preparation of labeled leukocytes is relatively cumbersome and requires the handling of patients' blood. Moreover, sensitivity in areas of low-grade infection may be decreased (5). In view of the problems with ^{67}Ga and labeled leukocytes, many new agents are currently being evaluated in clinical practice. One of those agents is indium-111-labeled nonspecific polyclonal human immunoglobulin G ($^{111}\text{In-IgG}$), a labeled large protein that accumulates in inflammatory tissue by virtue of increased vascular permeability (6). Several studies suggest the utility of $^{111}\text{In-IgG}$ scintigraphy for the detection of various types of focal infection in humans (7,8). In this study, we evaluated the usefulness of $^{111}\text{In-IgG}$ scintigraphy in routine clinical practice.

MATERIALS AND METHODS

Patients

The studies of 243 patients, obtained over a period of 4 yr, were reviewed. Of these 243 patients, 226 (108 male and 118 female; mean age 54.3 yr, with a range of 5-90 yr), suspected of 232 possible foci of infection, were evaluable. Previously published patient data, which were obtained before patients were recruited for this study, were not included (9,10). The patients were categorized on the basis of the suspected focus: total hip arthroplasty (n = 87; 38%), total knee arthroplasty (n = 17; 7%), chronic osteomyelitis (n = 43; 18%), diabetic foot osteomyelitis (n = 22; 9%), pseudarthrosis (n = 11; 5%), septic arthritis (n = 16; 7%), noninfectious arthritis (n = 13; 6%), soft-tissue infection (n = 7; 3%) or spondylodiscitis/vertebral osteomyelitis (n = 16; 7%). Acute osteomyelitis was defined as evidence of infection for one or several days, chronic osteomyelitis as evidence of infection for weeks, months or even years (9).

Radiopharmaceuticals

DTPA-conjugated human nonspecific polyclonal IgG was obtained as a lyophilized kit containing 2 mg IgG per vial (MacroScint, RW Johnson Pharmaceutical Research Institute, Spring House, PA). The kit was radiolabeled with ^{111}In (Indium-111 chloride, Mallinckrodt Medical, Petten, The Netherlands) in a 15-min, one-step procedure according to the manufacturer's instructions. The radiochemical purity as determined by instant thin layer chromatography was always higher than 95%. A dose of approximately 2 mg IgG, labeled with 75 MBq ^{111}In was injected intravenously.

Within 1 mo of the $^{111}\text{In-IgG}$ scintigraphy, two- or three-phase skeletal scintigraphy was performed in 135 patients after intravenous injection of methylene diphosphonate labeled with 600 MBq of $^{99\text{m}}\text{Tc}$. The maximum time interval was only considered in chronic cases and only when no invasive diagnostic or therapeutic

Received Jun. 26, 1996; accepted Oct. 2, 1996.

For correspondence or reprints contact: Wim J.G. Oyen, MD, University Hospital Nijmegen, Department of Nuclear Medicine, P.O. Box 9101, 6500 HB Nijmegen, The Netherlands.

TABLE 1
Results of Indium-111-IgG Scintigraphy for Detection of Infection in Various Patients

	n	TP	FP	TN	FN	Sensitivity	Specificity	PPV	NPV
Total hip arthroplasty	87	21	12	54	0	100	82	64	100
Total knee arthroplasty	17	3	7	7	0	100	50	30	100
Chronic osteomyelitis	43	15	2	26	0	100	93	83	100
Diabetic foot osteomyelitis	22	7	5	10	0	100	67	58	100
Pseudarthrosis	11	2	8	1	0	100	11	20	100
Septic arthritis	16	5	2	9	0	100	82	71	100
Noninfectious arthritis	13	13	0	0	0	100	—	100	—
Soft-tissue infection	7	6	0	1	0	100	100	100	100
Spondylodiscitis/vertebral osteomyelitis	16	2	0	13	1	67	100	100	93
Overall						99	77	67	99

TP = true-positive; FP = false-positive; TN = true-negative; FN = false-negative; PPV = positive predictive value; NPV = negative predictive value.

interventions were performed. In acute cases, the studies were all performed within a few days.

Imaging Procedure and Image Interpretation

Scintigraphic imaging was performed as reported earlier (8). In brief, digital images were obtained with a Siemens Orbiter gamma camera connected to a Scintiview image processor (Siemens Inc., Hoffman Estates, IL). Indium-111-IgG images were acquired at 4, 18–24 and 42–48 hr postinjection.

All images were interpreted by three observers. The observers were not blinded for pretest clinical information. A definite judgment of the scintigraphic images was reached before any of the verification procedures was performed. The ¹¹¹In-IgG images were interpreted with the corresponding bone scintigraphy, when available. A ¹¹¹In-IgG scan was interpreted as positive; if focal, continuously increasing accumulation could be noted over time. Nonvisualization of the lesion detected by bone scan and/or plain radiographs, or failure to show increasing accumulation, was considered to be a negative ¹¹¹In-IgG scintigraphy. A bone scan was considered positive when there was increased activity in at least two phases (blood pool and late phase) in the area of interest.

Verification

The scintigraphic results were verified by culture, obtained surgically (n = 98, 42%) or by puncture (n = 43, 19%) or long-term clinical and roentgenological follow-up of at least 1 yr (n = 91, 39%). The latter was mainly used in patients with negative diagnostic work-up, including negative scintigraphic imaging.

RESULTS

The overall infection prevalence was 27% (62 foci). *Staphylococcus* species were cultured from 17 foci (38%), *Streptococcus* species from 13 foci (29%), *Pseudomonas aeruginosa* from 3 foci (7%) and a variety of other microorganisms or mixed flora from 12 foci (27%).

Nineteen patients received antibiotics before ¹¹¹In-IgG scintigraphy, including β -lactam antibiotics, (n = 17), tetracycline (n = 1) and fluoroquinolone (n = 1). Twelve scintigrams of these patients were scored true-positive, 5 true negative, 1 false-positive and 1 false-negative.

Table 1 summarizes the results of ¹¹¹In-IgG scintigraphy in various patient categories.

Total Hip Arthroplasty (n = 87)

All 21 infected total hip arthroplasties showed increased ¹¹¹In-IgG uptake on scintigraphy (Fig. 1). None of the 54 hip arthroplasties demonstrating normal distribution of ¹¹¹In-IgG were infected. Most (10 of 11) noninfected cementless hip arthroplasties demonstrating normal ¹¹¹In-IgG uptake were

implanted 16 mo or longer before scintigraphy, while cemented hip arthroplasties were recorded as true-negative as early as 6 wk after implantation.

Twelve hip arthroplasties were recorded as false-positive, including nine cementless implants. Six of the latter had been implanted within a 14-mo period before ¹¹¹In-IgG scintigraphy. Other causes of false-positive results included foreign body response after wear of the polyethylene socket (n = 1) and periarticular ossification (n = 1). One patient with increased ¹¹¹In-IgG uptake on scintigraphy 6 mo after hip arthroplasty still had a wound with signs of inflammation (redness, induration) at time of imaging. One month later, however, this patient was free of complaints. In four of seven hip arthroplasties with increased ¹¹¹In-IgG uptake located around the neck of the femoral component, no infection was found.

Histologic specimens were available from six false-positive hip implants. All showed signs of sterile chronic inflammation.

Total Knee Arthroplasties (n = 17)

All three infected knee arthroplasties showed increased ¹¹¹In-IgG uptake on scintigraphy. Seven of 14 noninfected knee arthroplasties were scored false-positive. In one patient, infection was less likely since 1 mo after scintigraphy knee pain decreased, and the sedimentation rate of erythrocytes dropped without specific treatment. The positive ¹¹¹In-IgG scintigraphy in this patient, performed 7 wk after arthroplasty, remained unexplained, other than being caused by the surgical procedure itself. One false-positive scan consisted of increased ¹¹¹In-IgG uptake on scintigraphy 11 mo after total knee arthroplasty, which was caused by calcifications in the knee capsule seen on radiography. Three false-positive results consisted of scintigrams with clear focal ¹¹¹In-IgG accumulation, but the location of this uptake was noted to be probably caused by noninfectious inflammation of soft tissues rather than infection located in bone around the arthroplasty itself.

Five false-positive results were scored based on negative cultures from needle aspirations (n = 4) and arthroscopy (n = 1). However, in all four available histologic specimens, signs of inflammation were seen.

Chronic Osteomyelitis (n = 43)

All 15 patients with proven chronic osteomyelitis showed increased focal accumulation on ¹¹¹In-IgG scintigraphy (Fig. 2). Two of the 28 foci that were proven to be noninfected were scored as false-positives. The first patient suffered from severe decubitus on the lateral side of her right hip. Soft-tissue cultures grew *Escherichia coli* and *Enterococcus faecalis*. Within 1 mo, the wound healed and resection of the head of the hip was not

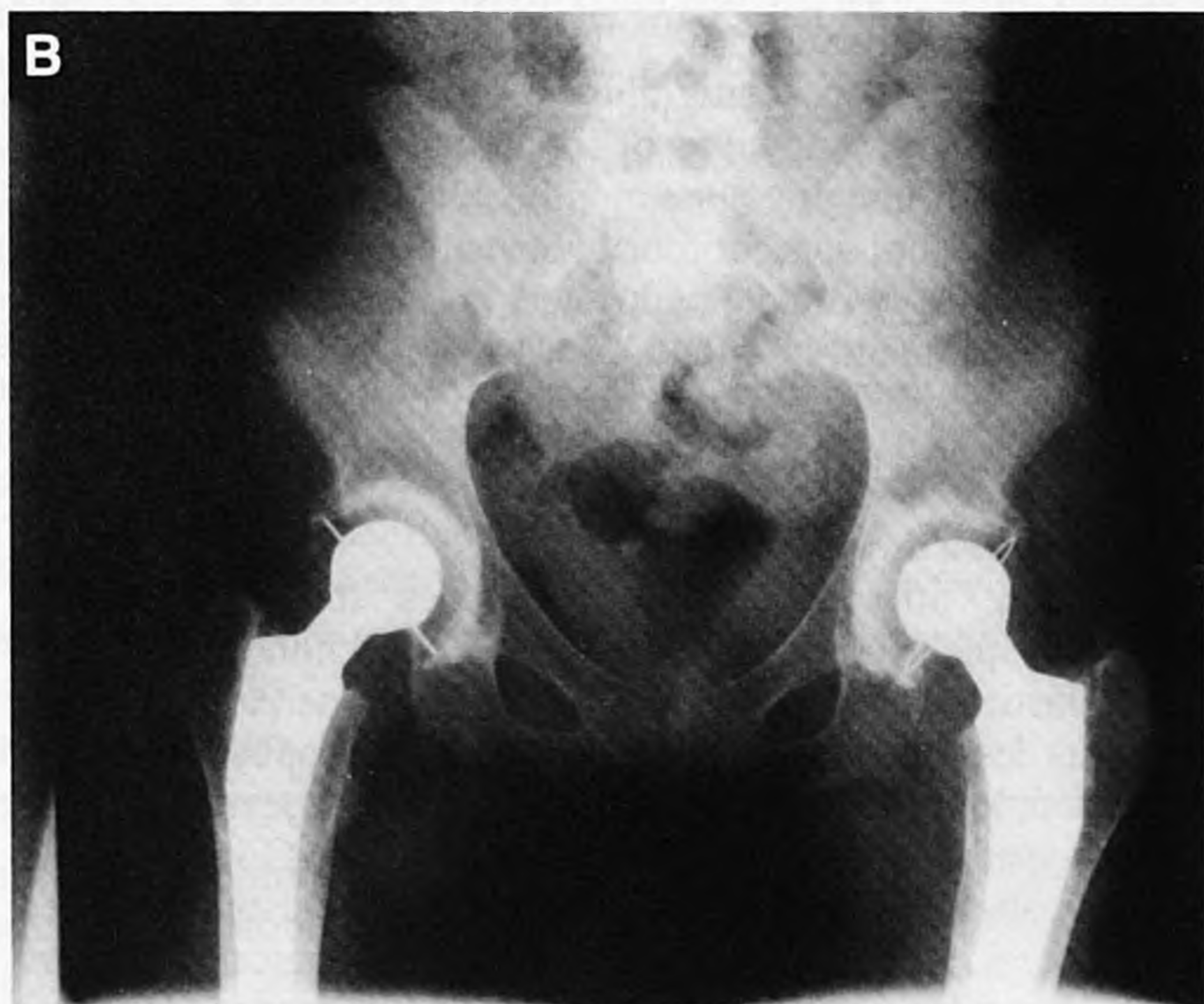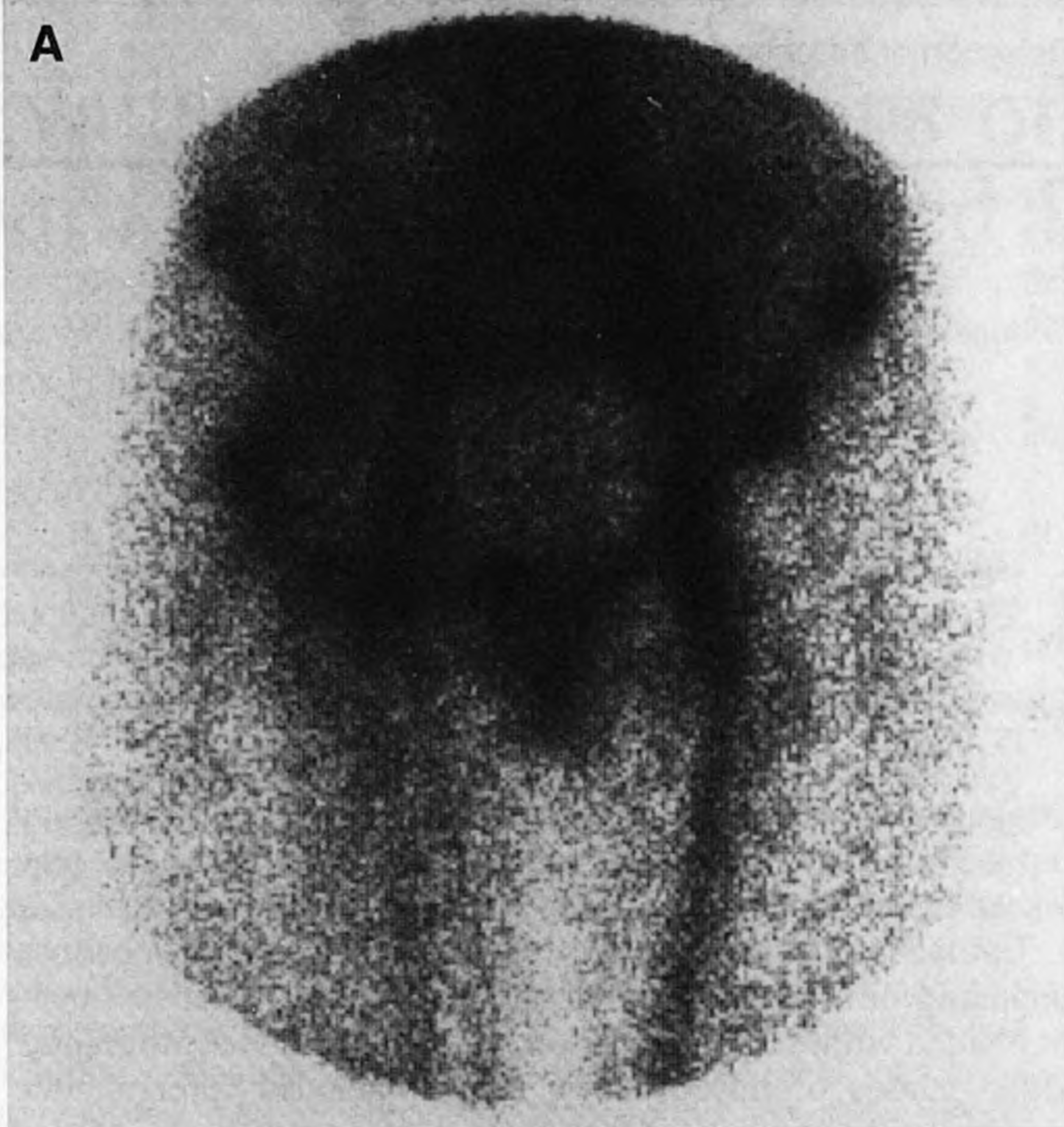


FIGURE 1. Female patient (age 22 yr) with a painful cemented right total hip arthroplasty 4 yr after implantation. Cultures from needle aspirations and blood cultures grew *Staphylococcus aureus*. (A) Indium-111-IgG scintigram showing increased uptake of radionuclide. (B) Plain radiograph showing no signs of infection.

performed. In this patient, it was not possible to differentiate between increased ^{111}In -IgG uptake in soft tissue or bone. In the second patient an above-knee amputation was performed 10 mo before scintigraphy due to a late complication of diabetes mellitus. A fistula at the amputation side existed for several months. Culture of the pus revealed *S. aureus* in low counts. No evident signs of osteomyelitis were seen on plain radiography. Indium-111-IgG scintigraphy was scored as false-positive because the wound healed within 4 wk after scintigraphy, 3 wk after oral antibiotics only (amoxicillin-clavulanic acid).

Diabetic Foot Osteomyelitis (n = 22)

Seventeen foci in patients with a diabetic foot were adequately evaluated with ^{111}In -IgG scintigraphy: 7 osteomyelitis, 10 no osteomyelitis (normal scan or soft-tissue inflammation

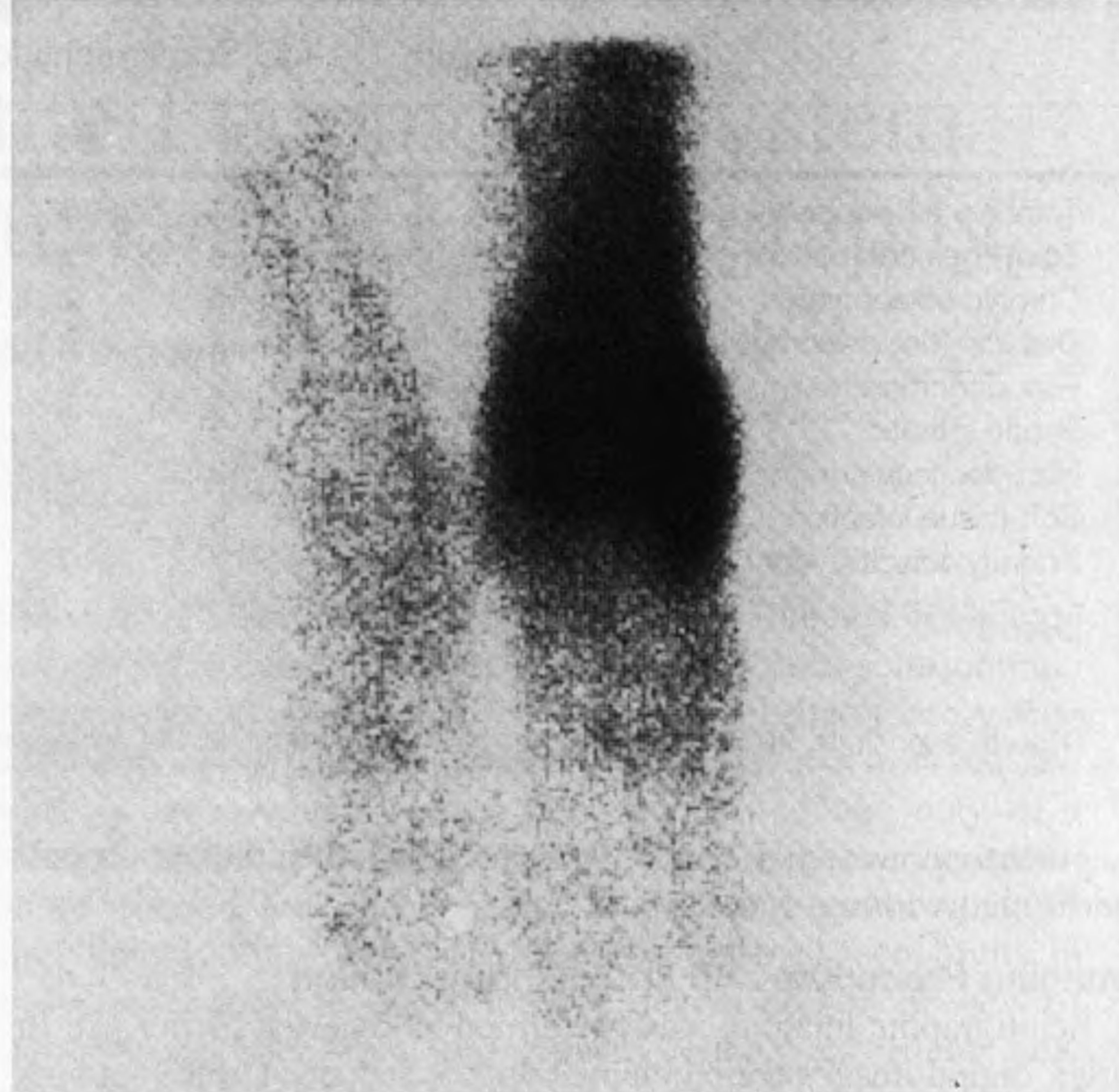


FIGURE 2. Indium-111-IgG scintigram of a male patient (age 23 yr) showing focal accumulation in his distal left tibia, which was painful and swollen for 7 yr. Intraoperative culture proved infection (*S. aureus*), and histologic specimens showed chronic active osteomyelitis.

only). Five foci in patients with a diabetic foot were recorded false-positive. Two of those patients had deep ulcers on the heel, culture revealed *S. aureus* species and *Proteus vulgaris*. In the first patient, histologic specimens from the ulcer showed no signs of osteomyelitis, whereas in the other patient the ulcer was healing rapidly 2 wk after scintigraphy with oral flucloxacillin (4 g/day). Three false-positive results were from patients with Charcot joints with recent fractures, who responded well to conservative treatment.

Pseudarthrosis (n = 11)

In only two patients, a positive ^{111}In -IgG scintigram could be confirmed as positive for infection. Surgically obtained cultures proved infection in one patient with positive ^{111}In -IgG scintigraphy 3 mo after removal of osteosynthesis material from his tibia. In the other patient, infection was evident based on a continuing producing fistula for several months from an internal fixator of the femur, being 1 yr in situ at the time of imaging.

One pseudarthrosis in a tibia with an external fixator placed 16 mo before imaging was true-negative, and subsequently proven by a negative culture.

Eight patients with pseudarthrosis showed false-positive focal accumulation of ^{111}In -IgG on scintigraphy. Surgically obtained cultures were negative and no histologic evidence for infection was found in these patients. Five of eight patients had undergone removal of internal (n = 4) or external (n = 1) fixators from femur (n = 3) or tibia (n = 2) at least 3 mo before scintigraphy. In the remaining three patients the following surgical procedures had been performed: implantation of a dynamic hipscrew 1 yr before imaging, osteotomy of a tibia 5 mo and arthrodesis of an ankle 14 mo before scintigraphy, respectively.

Arthritis (n = 29)

In 13 of 29 patients, the arthritis consisted of noninfectious inflammation in one or more joints. This included gout, severe progressive osteoarthritis, necrosis of the head of the femur, reactive arthritis in response to Crohn's disease and intestinal

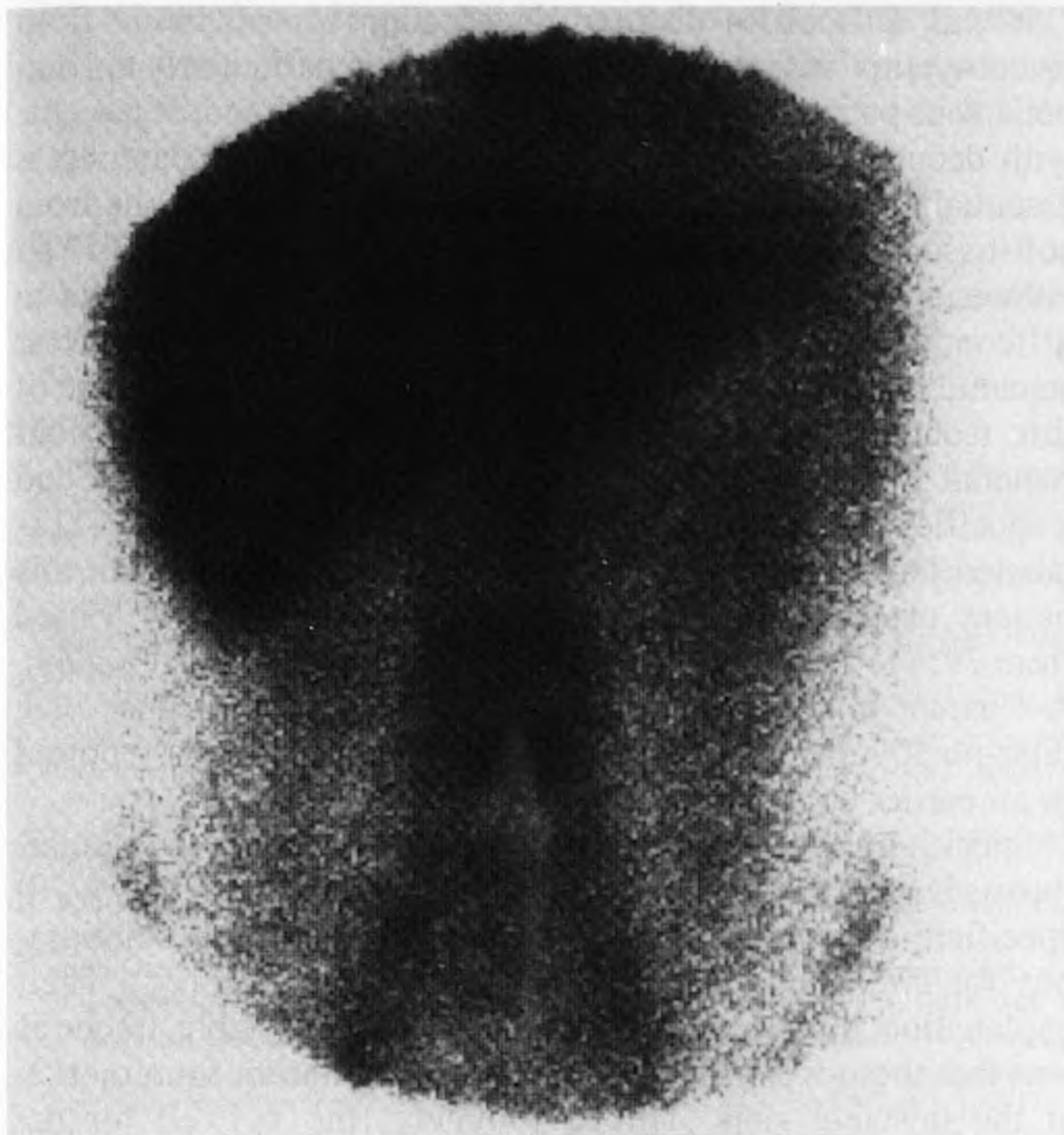

FIGURE 3. Indium-111-IgG scintigram of a 35-yr-old male patient with low back pain. Focal ¹¹¹In-IgG accumulation is seen on the ventral side of the vertebra L3–L4. Biopsy of the vertebra L3–L4 proved infection (*K. denitrificans*).

infection, paraneoplastic polyarthritis and seronegative symmetric polyarthritis. Those joints showed an increased accumulation on ¹¹¹In-IgG scintigraphy but with a different distribution pattern compared with septic arthritis as seen in five other patients. In infectious arthritis, diffuse, intense uptake is seen in the joint, whereas in sterile arthritis typically the synovial lining is visualized.

In two of seven patients with ¹¹¹In-IgG scintigraphy scored positive for infection, and no septic arthritis could be proven (“false-positives”). Histologic specimens from both joints (knee and ankle) showed mild, chronic synovitis. No signs of infection could be detected in all nine patients with normal uptake of ¹¹¹In-IgG in their joints.

Soft-Tissue Infection (n = 7)

The soft-tissue infections consisted of abscess in the psoas muscle region (n = 2), abscess in the thigh (n = 2), abscess in the calf (n = 1) and infection in a Girdlestone hip (n = 2). Six infections were proven by culture and histology and showed increased ¹¹¹In-IgG uptake on scintigraphy, including two

patients with acquired immunodeficiency syndrome and one patient with leukopenia due to chemotherapy. One Girdlestone hip with a negative ¹¹¹In-IgG scintigram was proven to be noninfected by surgically obtained culture.

Spondylodiscitis/Vertebral Osteomyelitis (n = 16)

Spondylodiscitis was proven twice by puncture (lumbar spine), culture revealed *Kingella denitrificans* and *kingae* (Fig. 3). Both patients showed focal ¹¹¹In-IgG accumulation on scintigraphy. In 13 patients with negative ¹¹¹In-IgG scintigraphy no spondylodiscitis was detected by long-term follow-up. In one patient blood cultures revealed *Brucella* species, after which antibiotic therapy was started, 4 days before scintigraphy. Indium-111-IgG scintigraphy showed no increased uptake. MRI showed at this time only early epiduritis, no spondylitis, while on CT no signs of infection were seen. Lumbar puncture revealed an acute infection of the central nervous system. Doxycycline (1 dd 200 mg) and rifampicin (1 dd 100 mg) was continued for 4 mo. Two and 5 wk later MRI showed both epiduritis and spondylitis at L3–L4. Indium-111-IgG scintigraphy was scored as false-negative.

Technetium-99m-MDP Bone Scintigraphy

The results of ^{99m}Tc-MDP bone scintigraphy are summarized in Table 2. In all but one patient category, this imaging technique showed an excellent sensitivity. In the patient with false-negative ¹¹¹In-IgG scintigraphy for spondylitis the ^{99m}Tc-MDP bone scintigraphy also was false-negative. Specificity of ^{99m}Tc-MDP bone scintigraphy for osteomyelitis is considerably lower than sensitivity.

DISCUSSION

This study shows that ¹¹¹In-IgG scintigraphy is a very sensitive imaging technique for evaluating infection of the locomotor system. In most patient categories the sensitivity for infection was optimal, only one patient with spondylitis in the lumbar spine did not show increased ¹¹¹In-IgG accumulation on scintigraphy. Specificity varies between different patient categories. Specificity is high in patients with total hip arthroplasty, chronic osteomyelitis, arthritis, soft-tissue infection and spondylodiscitis (82%, 93%, 82%, 100% and 100%, respectively), moderate in patients with total knee arthroplasty and diabetic foot pathology (50% and 67%) and low in patients with pseudarthrosis (11%). The high negative predictive value is important for planning, e.g., in prosthesis revision, given the significant extra time and costs of adequate infection treatment. In all foci, scored as false-positive with ¹¹¹In-IgG scintigraphy, signs of sterile inflammation were present. This confirms the present concepts of the mechanism of ¹¹¹In-IgG accumulation being not specific for infection but occurring in any inflamma-

TABLE 2
Results of Technetium-99m-MDP Bone Scintigraphy for Detection of Infection in Various Patients

	n	TP	FP	TN	FN	Sensitivity	Specificity	PPV	NPV
Total hip arthroplasty	60	13	40	7	0	100	15	25	100
Total knee arthroplasty	7	2	4	1	0	100	20	33	100
Chronic osteomyelitis	26	9	11	6	0	100	35	45	100
Diabetic foot osteomyelitis	21	7	13	1	0	100	7	35	100
Pseudarthrosis	5	1	4	0	0	100	0	20	—
Septic arthritis	9	1	7	1	0	100	13	13	100
Soft-tissue infection	2	1	0	1	0	100	100	100	100
Spondylodiscitis/vertebral osteomyelitis	5	2	2	0	1	67	0	50	—

TP = true-positive; FP = false-positive; TN = true-negative; FN = false-negative; PPV = positive predictive value; NPV = negative predictive value.

tory focus (8,10). In all categories, though, specificity of ^{111}In -IgG scintigraphy is higher compared with $^{99\text{m}}\text{Tc}$ -MDP scintigraphy. Indium-111-IgG does not, like $^{99\text{m}}\text{Tc}$ -MDP, accumulate in metabolic active bone. Therefore, previous pathologic changes of the bones, like arthroplasty and chronic osteomyelitis, compromise image interpretation of ^{111}In -IgG scintigraphy less than $^{99\text{m}}\text{Tc}$ -MDP scintigraphy.

Comparing cemented with cementless total hip arthroplasties shows that the period for ^{111}In -IgG scintigraphy to become negative after arthroplasty is considerably longer for cementless total hip arthroplasty. Noninfected cemented total hip arthroplasties showed no increased ^{111}In -IgG uptake scintigraphy from 6 wk after implantation, whereas all but one noninfected cementless total hip arthroplasty showed false-positive ^{111}In -IgG accumulation on scintigraphy when recorded within a 14-mo period after arthroplasty. Therefore, differentiation between cemented and cementless total hip arthroplasty is important for image interpretation of ^{111}In -IgG scintigraphy in the first year after arthroplasty. Persisting accumulation around uncemented prostheses also holds true for ^{111}In -labeled leukocyte scintigraphy, as shown by Oswald et al. (11). Their study showed increased ^{111}In -labeled leukocyte uptake on scintigraphy up to 2 yr after implantation of cementless total hip arthroplasties. Wegener and Alavi hypothesized that ingrowth of bone and fibrous tissue in the porous coating of the cementless prosthesis caused this prolonged uptake of the tracer on scintigraphy (1).

Periarticular ossification and debris formed by polyethylene socket wear, both clearly visualized on plain radiography, are other causes of sterile inflammation after total hip arthroplasty and focal-increased ^{111}In -IgG uptake on scintigraphy (10). However, in most cases, image interpretation does not need to be impaired when the ^{111}In -IgG images are read in conjunction with radiographs. Despite our impression that nonbone-marrow uptake of ^{111}In -IgG around the neck of the femoral component of a hip arthroplasty (outside the osseous structures) could be caused by such noninfectious reaction after socket wear, the scintigraphy was scored positive, since uptake was clearly elevated. Only 3 of 7 total hip arthroplasties proved to be infected when this pattern of ^{111}In -IgG uptake was seen.

Due to the high prevalence of noninfectious inflammation after total knee arthroplasty, the specificity of ^{111}In -IgG scintigraphy is relatively low in this patient category. It seems possible to increase this specificity to 71% by differentiating between increased ^{111}In -IgG uptake on scintigraphy around the knee arthroplasty due to noninfectious inflammation of soft tissues (horseshoe shaped, mild uptake in the suprapatellar bursa above the prosthesis) and uptake due to infection of the knee arthroplasty itself (diffuse uptake, also located in bone). Persistent periprosthetic $^{99\text{m}}\text{Tc}$ -MDP uptake for several years like in total hip arthroplasties limits the role of this scintigraphic technique in total knee arthroplasties even more (12). Little has been reported on other scintigraphic imaging techniques of knee arthroplasty. One study reported a 95% accuracy of combined leukocytes and sulfur colloid imaging in these patients (13).

These results are in accordance with a previous study that showed that ^{111}In -IgG scintigraphy is very accurate for evaluating chronic osteomyelitis (10). Controversy exists about the usefulness of leukocyte (neutrophil)-labeled scintigraphy in diagnosing chronic osteomyelitis, with predominant infiltration of mononuclear cells (2,14). As stated above, previous pathologic changes of bone-like chronic osteomyelitis do not reduce specificity of ^{111}In -IgG scintigraphy. Not surprisingly, specificity of $^{99\text{m}}\text{Tc}$ -MDP scintigraphy is considerably lower in this group of patients (55% versus 93%).

It was difficult to distinguish infection in soft tissue from osteomyelitis with ^{111}In -IgG scintigraphy, particularly in diabetic foot patients with deep ulcers on the heel and in patients with decubitus and a deep fistula. Although bone scanning is essential for localizing osseous structures, separating bone from soft-tissue infection was not possible in these patients. As indicated by Ezuddin et al., SPECT imaging may be helpful to differentiate these two conditions (15). The ability of MRI to separate bone from soft-tissue infection is a major advantage of this technique for diagnosing osteomyelitis in diabetic foot patients. Yuh et al., in a study of 24 diabetic foot patients, found a specificity 100% of MRI for osteomyelitis (16). Indium-111-labeled leukocyte studies as well reported good results in this patient category, although sensitivity and specificity varied from 79% to 100% and from 68% to 95%, respectively (17–19). A Charcot joint with a recent fracture can be the cause of a false-positive result of ^{111}In -IgG scintigraphy, as was reported in an earlier study of 16 diabetic foot patients (20).

Specificity of ^{111}In -IgG scintigraphy for infection in pseudarthrosis is very low (11%). Nepola et al. reported an 82% (59/70) specificity of combined labeled leukocyte and bone scintigraphy for infections of delayed unions or nonunions (21). Their explanation for the false-positive results in unstable fractures was that these were caused by continued irritation from motion at the unstable sites. This is probably true as well for the nonspecific ^{111}In -IgG uptake on scintigraphy in pseudarthrosis.

Indium-111-IgG scintigraphy visualizes septic arthritis as well as noninfectious inflammatory pathology of the joints, such as metabolic, reactive and autoimmune arthritis. As indicated above, in most patients, the pattern of ^{111}In -IgG uptake on scintigraphy is different for septic and noninfectious inflammatory arthritis. Detailed clinical information is helpful for a correct image interpretation of ^{111}In -IgG scintigraphy of these patients. An advantage of the use of this and other radiopharmaceuticals in the detection of (poly-)arthritis activity is that it allows direct imaging of joints by means of whole-body scintigraphy and of joints that are difficult to assess clinically or radiographically (22).

The true-positive-scored ^{111}In -IgG scintigraphy in this study of three immunocompromised patients (AIDS and leukopenia due to chemotherapy) with soft-tissue infections confirm that it is possible to detect infections in these patients with this imaging technique (6,23). Because these patients are very susceptible to infection and infection often presents atypically in these patients, reliable diagnostic techniques are needed. Some disagreement exists over whether labeled leukocyte scintigraphy is sensitive enough for this purpose (14,24).

The only case of bone infection missed by ^{111}In -IgG scintigraphy in this study concerned a patient with early, low-grade spondylodiscitis. Lower sensitivity for osteomyelitis of the spine has been reported in studies using other scintigraphic techniques as well, including labeled leukocyte and $^{99\text{m}}\text{Tc}$ -IgG scintigraphy (25–28). Modic et al. reported a 96% sensitivity using MRI to detect vertebral osteomyelitis (29). MRI is more useful than CT scanning in this group of patients because it provides better anatomic detail and can differentiate between vertebral and soft-tissue infections (30,31).

CONCLUSION

Indium-111-IgG imaging is a sensitive technique for evaluation of infections and inflammatory bone and joint disease. Specificity is increased over $^{99\text{m}}\text{Tc}$ -MDP bone scintigraphy, which in most cases is the first procedure performed on these patients except for those with recently violated bone. Specificity of ^{111}In -IgG scintigraphy for infection can be increased even

more when considering particular patterns of increased uptake that are frequently caused by sterile inflammatory processes (e.g., uptake around the neck of a total hip prosthesis or uptake in the synovial lining only).

ACKNOWLEDGMENTS

We thank Mr. Antoi Meeuwis and his staff and Mr. Emile Koenders for their help in performing the study.

REFERENCES

1. Wegener WA, Alavi A. Diagnostic imaging of musculoskeletal infection. Roentgenography; gallium, indium-labeled white blood cell, gammaglobulin, bone scintigraphy; and MRI. *Orthop Clin North Am* 1991;22:401-418.
2. Elgazzar AH, Abdel-Dayem HM, Clark JD, Maxon HR. Multimodality imaging of osteomyelitis. *Eur J Nucl Med* 1995;22:1043-1063.
3. Palestro CJ. The current role of gallium imaging in infection. *Semin Nucl Med* 1994;24:128-141.
4. Palestro CJ, Kim CK, Swyer AJ, Capozzi JD, Solomon RW, Goldsmith SJ. Total-hip arthroplasty: periprosthetic indium-111-labeled leukocyte activity and complementary technetium-99m-sulfur colloid imaging in suspected infection. *J Nucl Med* 1990;31:1950-1955.
5. Schauwecker DS. Osteomyelitis: diagnosis with In-111-labeled leukocytes. *Radiology* 1989;171:141-146.
6. Rubin RH, Fischman AJ. The use of radiolabeled nonspecific immunoglobulin in the detection of focal inflammation. *Semin Nucl Med* 1994;14:1110-1118.
7. Rubin RH, Fischman AJ, Callahan RJ, et al. In-111-labeled nonspecific immunoglobulin scanning in the detection of focal infection. *N Engl J Med* 1989;321:935-940.
8. Oyen WJG, Claessens RAMJ, van der Meer JWM, Rubin RH, Strauss HW, Corstens FHM. Indium-111-labeled human nonspecific immunoglobulin G: a new radiopharmaceutical for imaging infectious and inflammatory foci. *Clin Infect Dis* 1992;14:1110-1118.
9. Oyen WJG, Claessens RAMJ, van Horn JR, van der Meer JWM, Corstens FHM. Scintigraphic detection of bone and joint infections with indium-111-labeled nonspecific polyclonal human immunoglobulin G. *J Nucl Med* 1990;31:403-412.
10. Oyen WJG, van Horn JR, Claessens RAMJ, Slooff TJJH, van der Meer JWM, Corstens FHM. Diagnosis of bone, joint and joint prosthesis infections with indium-111-labeled nonspecific human immunoglobulin G scintigraphy. *Radiology* 1992;182:195-199.
11. Oswald SG, van Nostrand D, Savory CG, Callaghan JJ. Three-phase bone and indium white blood cell scintigraphy following porous-coated hip arthroplasty. *J Nucl Med* 1990;30:274-280.
12. Rosenthal L, Lepanto L, Raymond F. Radiophosphate uptake in asymptomatic knee arthroplasty. *J Nucl Med* 1987;28:1546-1549.
13. Palestro CJ, Swyer AJ, Kim SK, Goldsmith SJ. Infected knee prosthesis: diagnosis with In-111 leukocyte, Tc-99m sulfur colloid and Tc-99m MDP imaging. *Radiology* 1991;179:645-648.
14. Datz FL. Indium-111-labeled leukocytes for the detection of infection: current status. *Semin Nucl Med* 1994;24:169-179.
15. Ezuddin S, Yuille D, Spiegelhoff D. The role of dual bone and WBC scan imaging in the evaluation of osteomyelitis and cellulitis using both planar and SPECT imaging. *J Nucl Med* 1992;33:839.
16. Yuh WTC, Corson JD, Baraniewsky HM, et al. Osteomyelitis of the foot in diabetic patients: evaluation with plain film, Tc-99m bone scintigraphy and MR imaging. *Am J Roentgenol* 1989;152:795-800.
17. Keenan AM, Tindel NL, Alavi A. Diagnosis of pedal osteomyelitis in diabetic patients using current scintigraphic techniques. *Arch Intern Med* 1989;149:2262-2266.
18. Larcos G, Brown ML, Sutton RT. Diagnosis of osteomyelitis of the foot in diabetic patients: value of In-111 leukocyte scintigraphy. *Am J Roentgenol* 1991;157:527-531.
19. Kolindou A, Liu Y, Ozker K, et al. Indium-111 WBC imaging of osteomyelitis in patients with underlying bone scan abnormalities. *Clin Nucl Med* 1996;21:183-191.
20. Oyen WJG, Netten PM, Lemmens JA, et al. Evaluation of infectious diabetic foot complications with indium-111-labeled human nonspecific immunoglobulin G. *J Nucl Med* 1992;33:1330-1336.
21. Nepola JV, Seabold JE, Marsh JL, Kirchner PT, El-Khoury GY. Diagnosis of infection in ununited fractures: combined imaging with indium-111-labeled leukocytes and technetium-99m methylene diphosphonate. *J Bone Jt Surg Am Vol* 1993;75:1816-1822.
22. de Bois MHW, Pauwels EKJ, Breedveld FC. New agents for scintigraphy in rheumatoid arthritis. *Eur J Nucl Med* 1995;22:1339-1346.
23. Oyen WJG, Claessens RAMJ, Raemaekers JMM, de Pauw BE, van der Meer JWM, Corstens FHM. Diagnosing infection in febrile granulocytopenic patients with indium-111-labeled human IgG. *J Clin Oncol* 1992;10:61-68.
24. Datz FL, Morton KA. Radionuclide detection of occult infection: current strategies. *Cancer Invest* 1991;9:691-698.
25. Whalen JL, Brown ML, McLeod R, et al. Limitations of indium leukocyte imaging for the diagnosis of spine infections. *Spine* 1991;16:193-197.
26. Palestro CJ, Kim CK, Swyer AJ, Vallabhajosula, Goldsmith SJ. Radionuclide diagnosis of vertebral osteomyelitis: indium-111-leukocyte and technetium-99m-methylene diphosphonate bone scintigraphy. *J Nucl Med* 1991;32:1861-1865.
27. Sciuk J, Brandau W, Vollet B, et al. Comparison of technetium-99m polyclonal human immunoglobulin and technetium-99m monoclonal antibodies for imaging chronic osteomyelitis: first clinical results. *Eur J Nucl Med* 1991;8:401-407.
28. Goh ASW, Aw SE, Sundram FX, Ang ES, Goh SK, Leong KH. Imaging of focal inflammation with ^{99m}Tc-labeled human polyclonal immunoglobulin G. *Nucl Med Commun* 1990;11:843-856.
29. Modic M, Feiglin DH, Piraino DW, et al. Vertebral osteomyelitis: assessment using MR. *Radiology* 1985;157:157-166.
30. Unger E, Moldofsky P, Gatenby R, Hartz W, Broder G. Diagnosing osteomyelitis by MR imaging. *Am J Roentgenol* 1988;150:605-610.
31. Totty WG. Radiographic evaluation of osteomyelitis using magnetic resonance imaging. *Orthop Rev* 1989;18:587-592.

Imaging of the Pancreas and Related Diseases with PET Carbon-11-Acetate

Paul D. Shreve and Milton D. Gross

Department of Nuclear Medicine, Ann Arbor Veterans Affairs Medical Center and Department of Internal Medicine, Division of Nuclear Medicine, University of Michigan Medical Center, Ann Arbor, Michigan

The purpose of this study was to evaluate [1-¹¹C]-acetate as a tracer for functional imaging of the pancreas and related diseases using positron emission tomography (PET). **Methods:** Thirty-three patients underwent 30 min of dynamic attenuation-corrected PET after intravenous administration of 740 MBq (20 mCi) of [1-¹¹C]-acetate. **Results:** The normal pancreas demonstrates prompt uptake of [1-¹¹C]-acetate and is visualized as early as 2 min post-injection, with maximal activity achieved by 5 min. Subsequent clearance of tracer from the pancreas is slow relative to adjacent organs and background, such that by 10 min post-injection the pancreas is the most prominent organ in the imaging field of view. Pancreatic uptake of [1-¹¹C]-acetate was unaffected by pancreatic endocrine insufficiency, but is absent in chronic pancreatitis complicated by exocrine insufficiency. Moderately reduced [1-¹¹C]-acetate uptake was ob-

served in acute uncomplicated pancreatitis. The level of tracer accumulation was substantially reduced in phlegmatous masses complicating pancreatitis and in chronic mass forming pancreatitis. Adenocarcinoma of the pancreas likewise demonstrated no significant uptake of [1-¹¹C]-acetate. **Conclusions:** Accumulation of [1-¹¹C]-acetate by the pancreas allows rapid metabolic imaging using PET, and may be a useful metabolic probe for the study of pancreatic physiology and disease.

Key Words: pancreas; PET; acetate; neoplasm; pancreatitis

J Nucl Med 1997; 38:1305-1310

Imaging diagnosis of pancreatic disease has been primarily based on descriptions of anatomic pathology. Despite improvements in cross-sectional structural imaging, many important pancreatic diseases remain inadequately characterized by anatomic criteria alone. For example, the severity of acute pancreatitis can only be inferred by nonspecific morphologic alterations in the pancreas itself and in adjacent tissues, attendant to

Received Apr. 26, 1996; revision accepted Oct. 30, 1996.

For correspondence or reprints contact: Paul D. Shreve, MD, Division of Nuclear Medicine, University of Michigan Medical Center, 1500 E. Medical Center Drive, Box 0028, Ann Arbor, MI 48109-0028.