

## PDF hosted at the Radboud Repository of the Radboud University Nijmegen

This full text is a publisher's version.

For additional information about this publication click this link.

<http://hdl.handle.net/2066/14888>

Please be advised that this information was generated on 2014-11-11 and may be subject to change.



PAIN 02369

## Reflex sympathetic dystrophy of the hand: an excessive inflammatory response?

Wim J.G. Oyen <sup>a,\*</sup>, Ivo E. Arntz <sup>b</sup>, Roland A.M.J. Claessens <sup>a</sup>, Jos W.M. Van der Meer <sup>c</sup>,  
Frans H.M. Corstens <sup>a</sup> and R. Jan A. Goris <sup>b</sup>

Departments of <sup>a</sup> Nuclear Medicine, <sup>b</sup> Surgery and <sup>c</sup> Internal Medicine, University Hospital Nijmegen, Nijmegen (Netherlands)

(Received 13 August 1992, revision received 18 March 1993, accepted 16 April 1993)

**Summary** In 23 patients with reflex sympathetic dystrophy (RSD) of the hand, scintigraphy with indium-111 labeled human non-specific polyclonal immunoglobulin G (In-111-IgG) was performed to investigate whether inflammatory characteristics are present in RSD. Both blood flow and accumulation over 48 h were assessed. Nineteen patients had increased flow to the affected hand, and 3 had decreased flow. One patient had bilateral RSD. Exercise provoked aggravation of complaints and signs in all patients. The affected/non-affected hand ratio (target-to-background, T/B) immediately before and after exercise did not change significantly. The T/B ratios 48 h after In-111-IgG injection were significantly higher in patients with RSD less than 5 months than in patients with RSD existing 5 months or longer. The T/B ratios 24 and 48 h after In-111-IgG injection were not correlated with the flow T/B ratios. In fact, 2 of the 3 patients with a decreased flow showed excess accumulation on the late images. Significantly more patients with early RSD, existing less than 5 months, had a positive In-111-IgG scintigraphy (14 of 17) than the patients with late RSD (1 of 6). Increased vascular permeability for macromolecules, an important characteristic of inflammation, appears to play a role in the development of RSD. This phenomenon is not flow-dependent.

**Key words:** Reflex sympathetic dystrophy; Indium-111 labeled immunoglobulin G; Radionuclide imaging; Scintigraphy

### Introduction

Reflex sympathetic dystrophy (RSD) is a disabling complication that may occur after extremity injury and in the course of myocardial infarction, neurologic and rheumatologic diseases (Kozin et al. 1981; Greyson and Tepperman 1984; Procacci and Maresca 1987; Goris et al. 1990). RSD can be induced by fracture, surgery or even minimal trauma to an extremity, such as a sprain or a contusion. In some patients, no cause can be identified. Although RSD may resolve without special treatment, therapy-resistant pain and severely limited function of the affected extremity may ensue.

In the literature, there is no consensus on the pathophysiologic mechanism of RSD. It has been postulated that RSD is a disorder of the sympathetic nervous system, a vascular tone abnormality or that it is of psychogenic origin (Kozin et al. 1976a; Poplawski et al. 1983). Recently, Hannington-Kiff (1991) hypothesized that failed natural opioid modulation in regional sympathetic ganglia may cause RSD. Sudeck's (1942, 1900) original theory that RSD is an excessive inflammatory reaction found little support. However, in the acute phase of RSD, all classical signs and symptoms of inflammation – rubor, calor, dolor, tumor and functio laesa of the affected extremity – are present (Goris et al. 1987, 1990). This hypothesis is further supported by the therapeutic effect of corticosteroids in some patients (Christensen et al. 1982).

In previous studies, it has been reported that indium-111 labeled human non-specific polyclonal im-

\* Corresponding author: Wim J.G. Oyen, M.D., Department of Nuclear Medicine, University Hospital Nijmegen, P.O. Box 9101, 6500 HB Nijmegen, Netherlands. Tel.: (31-80) 61-4510; FAX: (31-80) 54-0576.



munoglobulin G (In-111-IgG) accumulates in infectious and inflammatory lesions (Fischman et al. 1988; La-Muraglia et al. 1989; Rubin et al. 1989; Oyen et al. 1990, 1991, 1992a,b). Accumulation of In-111-IgG has been shown to result from increased vascular permeability in these foci (Morrel et al. 1989; Oyen et al. 1992c). In RSD, it has been suggested that toxic oxygen radicals cause an inflammatory reaction (Goris et al. 1987). The aim of this study was to evaluate such a possible inflammatory component in RSD in patients with clinical evidence of early RSD of the upper limb using this new scintigraphic technique rather than to establish the diagnostic value of this method.

## Patients and methods

### *Clinical assessment*

Since there is no clear definition for the clinical assessment of RSD, patients were scored for signs and symptoms indicative for RSD. Of the following 6 symptoms, at least 5 should be present in an area larger than the primary injury: unexplained diffuse pain, abnormal skin temperature, abnormal skin color, diffuse edema, unexplained limitation of the range of motion, and increase of these signs and symptoms after exercise (Hanna and Peat 1989; Atkins et al. 1990; Goris et al. 1990).

The duration of RSD was classified according to the hemodynamic phases identified by Demangeat et al. (1988): stage I, 0–5 months after onset; stage II, 5–14 months after onset; stage III, patients (duration: > 14 months) were not studied in this series.

### *Patients*

Twenty-three patients were studied (7 male, 16 female; mean age: 46.9 years; range: 20–71 years). In 5 patients, RSD was the consequence of a Colles' fracture, in 5 of a fracture of one or more of the metacarpals, in 6 of finger tendon or carpal tunnel surgery, and in 5 of distorsion or contusion of the hand. In 2 patients, no cause for the development of RSD could be identified. One of them suffered from bilateral RSD of unknown origin. None of the patients received treatment for RSD prior to scintigraphy.

The mean duration of RSD when In-111-IgG scintigraphy was performed was 2.6 months (range: 0.5–6 months). Seventeen patients were classified as stage I and 6 as stage II.

### *Radiopharmaceutical*

Human non-specific polyclonal immunoglobulin G (Sandoglobulin, Sandoz AG, Nuremberg, Germany) was conjugated to diethylenetriaminepentaacetic bicyclic anhydride (bicyclic DTPA) according to the method described by Hnatowich et al. (1983) and labeled with In-111 (indium chloride, Amersham International Ltd., Buckinghamshire, UK). Labeling efficiency was always higher than 95%. A dose of approximately 1 mg of IgG labeled with 75 MBq In-111 was administered intravenously as a bolus injection in the cubital vein of the non-affected arm.

### *Imaging protocol*

Both hands were placed with the palms down on the gamma camera (Siemens Orbiter connected to a Scintiview image processor, Siemens Inc., Hoffman Estate, IL, USA), equipped with a medium-energy collimator. After intravenous administration of In-111-IgG, dynamic images were obtained (12 images, 5 sec/image). Thereafter, static images of the hands were made 5 and 20 min, and 4, 24 and 48

h after injection. The images 5 min postinjection were acquired for a preset time of 5 min, all other images for a preset time of 10 min.

Since exercise is known to trigger or aggravate the signs and symptoms of RSD, the patients were asked to inflate a blood pressure manometer 10 times to 200 mm Hg after the 5 min postinjection image was obtained. The affected hand was stressed first, followed by the normal hand. When maximal exertion could not be achieved with the affected hand, patients were encouraged to stress the hand as much as possible.

### *Image interpretation*

Quantitative analysis of the images was performed using the regions of interest (ROI) technique. ROI were drawn over the affected and the normal hand. On the dynamic images, a ROI was drawn over of both the affected and the non-affected hand. The ratio of activity uptake of the affected and the normal hand (target to background = T/B) ratio was calculated for the arterial phase (0–20 sec postinjection) and the venous phase (20–60 sec postinjection)

For the static images, a ROI was drawn on the 48 h image over the area with increased uptake in the affected hand and over the corresponding area in the contralateral hand. This region was then projected on the static images obtained at earlier time points. T/B ratios were calculated for each time point. The image obtained 5 min postinjection was considered to be the 'baseline' for the T/B ratios. An In-111-IgG scintigraphy was interpreted as positive, if on the static images accumulation of activity in the affected hand increased with time, compared to the non-affected hand (Oyen et al. 1990). When no increasing activity over time was noted on the static images, the In-111-IgG scintigraphy was considered to be negative. For the patient with bilateral RSD, of course, T/B ratios could not be calculated.

Four patterns, describing the evolution of T/B ratios over time in individual patients, could be distinguished: (pattern A): increased activity in the flow phase, a slightly elevated T/B ratio at the early static images, followed by a steady increase of the T/B ratio up to 48 h; (pattern B): increased activity in the flow phase, a slightly elevated T/B ratio at the early static images, not followed by an increase of the T/B ratio at the later images; (pattern C): decreased activity in the flow phase, followed by a steady increase to a maximum T/B ratio at 48 h; (pattern D): decreased activity in the flow phase, followed by symmetrical uptake on the static images.

### *Statistical analysis*

All mean values are expressed  $\pm$  S.D. The results of scintigraphy were analyzed using the  $\chi^2$  test, Spearman's rank correlation test, Student's *t* test and Wilcoxon's signed rank test.

## Results

Table I presents the clinical data of the patients. Although all patients meet the designated clinical criteria for RSD, a clinically significant difference between stages I and II is the degree of atrophy and dystrophy of the affected hand, being more explicit in stage II. In Table II, the T/B ratios of the individual patients are given.

### *Dynamic images*

Nineteen patients showed an increased flow in the affected hand (mean T/B ratio:  $1.64 \pm 0.63$ ). In 3 patients, the flow was decreased (mean T/B ratio:  $0.70 \pm 0.10$ ). For the patients with a decreased arterial



flow, the T/B in the venous phase was  $0.79 \pm 0.14$ , for the other patients  $1.23 \pm 0.16$ .

### Static images

Fig. 1 is a typical example of the static In-111-IgG images obtained in a patient with RSD.

Visually, 8 patients had a negative In-111-IgG scintigraphy. In these patients, T/B ratios after 48 h were 1.20 or less with no or only minimal relative increase over time. In 14 patients, a focal and with time increasing accumulation was noted in the affected hand (positive In-111-IgG scintigraphy). These 14 patients had a T/B ratio after 48 h ranging from 1.28 to 1.87. On the static images, no patient had an activity uptake that decreased with time. The patient with

TABLE I  
ETIOLOGY AND DURATION OF RSD AND CLINICAL ASSESSMENT OF THE INDIVIDUAL PATIENTS

MF = fracture of metacarpal(s); CF = Colles' fracture; TS = tendon surgery; CTS = carpal tunnel surgery; D/C = distortion or contusion; ? = no cause identified.

Patient no.	Etiology	Duration (months)	Symptoms of RSD <sup>1,2</sup>					
			Pain	Temp.	Color	Edema	RoM	Exerc.
1	TS	0.5	+	↑	B	+	↓	↑
2	CF	1	±	↑	B	±	N	↑
3	D/C	1	+	↑	B	+	↓	↑
4	MF	1	-	↓	B	±	↓	↑
5	D/C	1	+	↓	B	+	↓	↑
6	CF	1	±	↑	B	+	↓	↑
7	CF	1	+	↑	B	+	↓	↑
8	MF	2	±	↑	R	±	↓	↑
9	CF	2	±	↑	R	+	↓	↑
10	D/C	2	+	↑	R	+	N	↑
11	MF	2	±	↓	R	+	↓	↑
12L	?	2	+	↑	R	+	↓	↑
12R	?	2	+	↑	R	+	↓	↑
13	CF	2	+	↓	B	+	↓	↑
14	CTS	3	+	↑	R	+	↓	N
15	TS	3	+	↓	B	-	↓	↑
16	CTS	3	+	↑	R	+	↓	↑
17	TS	4	±	↓	R	+	↓	↑
18	MF	5	+	↑	N	±	↓	↑
19	CTS	5	+	↑	R	+	↓	↑
20	?	5	+	↑	R	+	↓	↑
21	MF	5	±	↓	B	+	↓	↑
22	D/C	5	+	↑	R	±	↓	↑
23	D/C	6	±	↓	B	-	↓	↑

<sup>1</sup> Pain: +, severe; ±, moderate; -, none; Temp.: skin temperature (N, normal; ↓, decreased, ↑, increased); Edema: +, clearly present; ±, mild edema; -, absent; Color: skin color (N, normal; B, blue discoloration; R, red discoloration); RoM: range of motion (N, normal; ↓, limited); and Exerc.: effect of exercise (N, no effect; ↑, increase of signs and symptoms).

<sup>2</sup> All patients also had moderate or severe hyperalgesia as well as allodynia in the affected area.

TABLE II  
RATIOS OF In-111-IgG UPTAKE IN THE ABNORMAL AND NORMAL HANDS IN THE INDIVIDUAL PATIENTS AT THE VARIOUS TIME POINTS

inc. = increased, no exact data available; n.d., not done.

Patient no.	Time postinjection						
	0-20 sec	20-60 sec	5 min	20 min	4 h	24 h	48 h
Stage I							
1	0.79	0.95	1.12	1.09	1.24	1.26	1.35
2	1.13	1.14	1.34	1.35	1.41	1.50	1.59
3	inc.	inc.	1.00	0.93	1.03	1.04	1.04
4	0.59	0.71	1.23	1.23	1.32	1.66	1.73
5	n.d.	n.d.	n.d.	n.d.	1.21	1.44	1.44
6	1.34	1.33	1.26	1.28	1.50	1.60	1.71
7	1.54	1.29	1.27	1.23	1.25	1.63	1.70
8	2.00	1.25	1.12	1.15	1.07	1.25	1.28
9	3.26	1.61	1.46	1.42	1.50	1.79	1.82
10	1.67	1.22	1.06	1.07	1.05	1.13	1.20
11	1.83	1.43	1.37	1.40	1.48	1.78	1.87
12	Bilateral abnormalities						
13	1.11	1.09	1.37	1.31	1.44	1.80	1.77
14	1.24	1.14	1.07	1.07	1.24	1.31	1.37
15	2.60	1.18	1.09	1.06	0.97	1.12	1.12
16	1.14	1.11	1.19	1.16	1.15	1.26	1.35
17	2.47	1.53	1.24	1.29	1.43	1.64	1.76
Stage II							
18	1.11	1.05	1.00	0.95	1.05	1.07	1.11
19	1.33	1.13	1.10	1.09	1.14	1.13	1.12
20	1.68	1.25	1.05	1.05	1.08	1.08	1.06
21	1.24	1.15	1.11	1.12	1.19	1.24	1.26
22	1.10	1.03	1.00	0.97	0.99	1.02	1.06
23	0.73	0.71	0.92	0.86	0.96	0.95	0.99

bilateral RSD showed an elevated, over time increasing activity in both hands on the scintigraphic images. Two of the 3 patients with diminished activity in the flow phases had a positive In-111-IgG scintigraphy (T/B ratios after 48 h 1.35 and 1.73, respectively), the other patient showed symmetrical activity uptake after 48 h.

Although exercise provoked aggravation of symptoms in all patients, the T/B ratios did not change from the 5 min image to the 20 min image (Wilcoxon's signed rank test,  $P > 0.10$ ).

The T/B ratios after 24 and 48 h were not significantly correlated with the arterial and venous phase T/B ratios (Spearman's rank correlation test,  $P > 0.10$ ).

### T/B patterns

In 11 stage I patients and 1 stage II patient, pattern A was observed. Three stage I patients and 4 stage II patients showed pattern B. In only 3 patients, the flow to affected hand was relatively lower than the flow to normal hand. Of these 3 patients, 2 patients (both stage I) showed pattern C and 1 patient (stage II) showed pattern D.



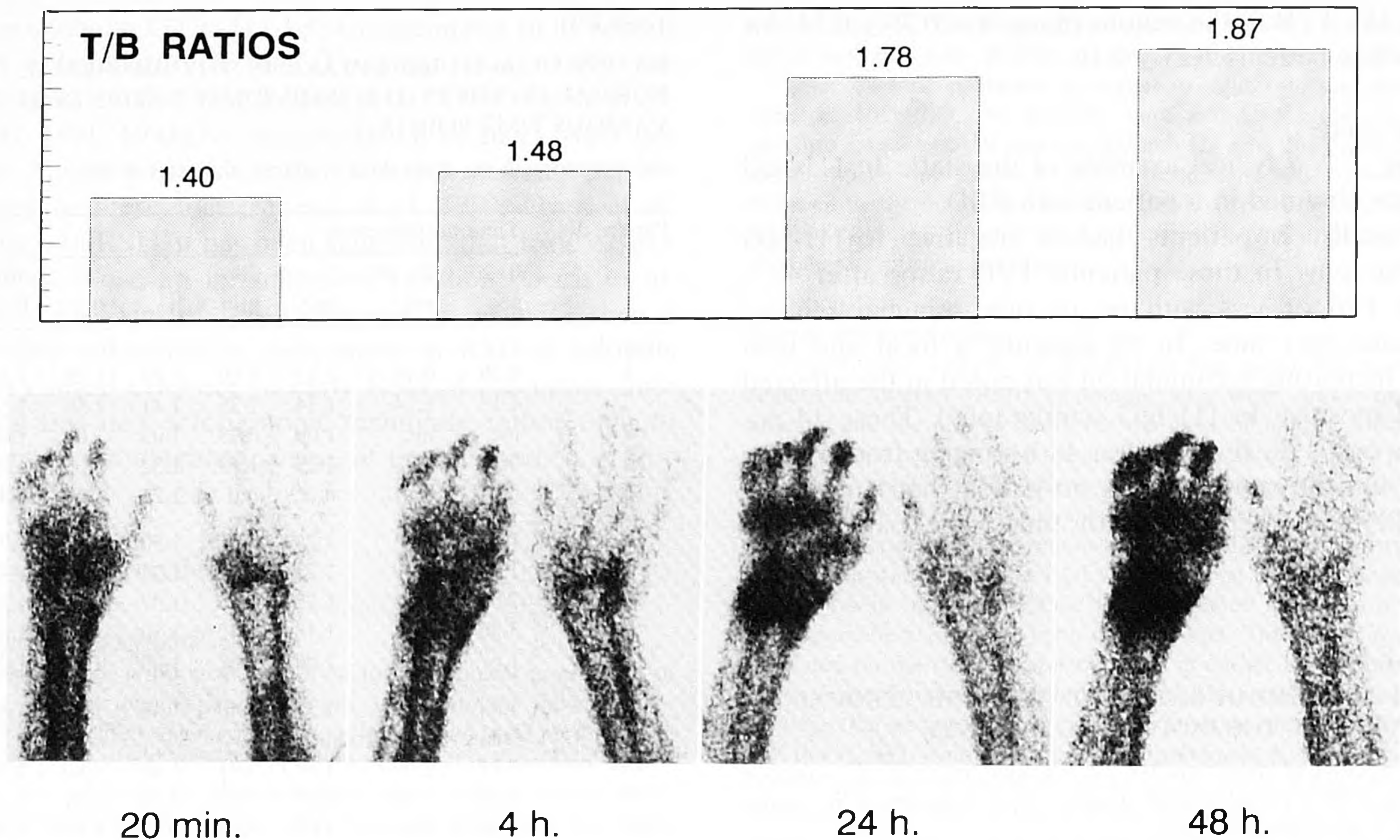


Fig. 1. In-111-IgG scintigraphy of a 34-year-old female patient (no. 11 in the table), who sustained fractures of metacarpals II–IV of the right hand 2 months prior to scintigraphy. She developed a painful, swollen right hand with loss of function. Maximal exercise of the right hand: 5 times inflation of the manometer to 150 mm Hg. From left to right: images and T/B ratios after 20 min, 4, 24, and 48 h. Note the relative increase of activity over time in the affected right hand.

#### Correlation with duration of RSD

The arterial and venous phase T/B ratios were not significantly different for stage I and II RSD. The arterial phase T/B ratios were  $1.61 \pm 0.75$  (range: 0.59–3.26) and  $1.20 \pm 0.31$  (range: 0.73–1.68), respectively (Student's *t* test,  $P > 0.05$ ). The venous phase T/B ratios were  $1.22 \pm 0.24$  (range: 0.71–1.61) and  $1.05 \pm 0.19$  (range: 0.71–1.25), respectively (Student's *t* test,  $P > 0.05$ ).

The T/B ratios after 48 h for stage I RSD were

significantly higher compared to those of stage II RSD:  $1.51 \pm 0.26$  and  $1.09 \pm 0.09$  for stages I and stage II, respectively (Student's *t* test,  $P < 0.05$ ). Fig. 2 represents the T/B ratio after 48 h correlated with the duration of RSD.

Of the 17 patients with stage I RSD (including the patient with bilateral RSD), 14 showed an over time increasing activity uptake in the affected hand, while only 1 of 6 patients with stage II RSD had a positive In-111-IgG scintigraphy ( $\chi^2 = 8.44$ ,  $P < 0.005$ ).

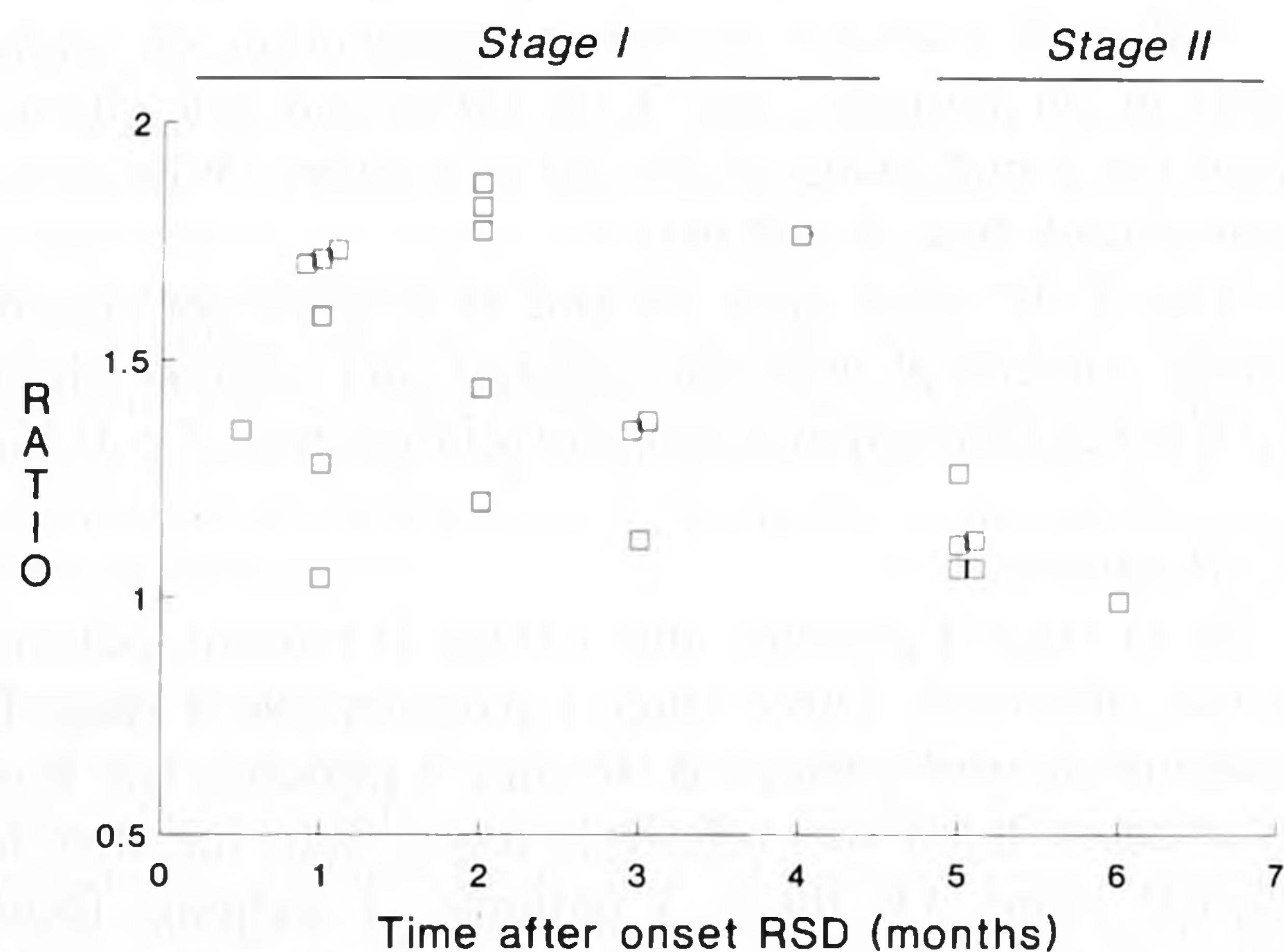


Fig. 2. Correlation between the T/B ratio after 48 h and the duration of RSD.

#### Discussion

In this study, we have found evidence of extravasation of In-111-IgG in early RSD. This extravasation increased with time. We and others have demonstrated previously that In-111-IgG accumulates with time in infectious and non-infectious inflammatory foci (Fischman et al. 1988; LaMuraglia et al. 1989; Rubin et al. 1989; Oyen et al. 1990, 1991, 1992a,b). This accumulation is most probably due to increased permeability for macromolecules (Morrel et al. 1989; Oyen et al. 1992c). The steadily increasing activity of In-111-IgG over 48 h in 15 of our patients therefore strongly suggests an inflammatory reaction in early RSD. Increased vascular permeability can not be fully explained by either



increased activity of the sympathetic nervous system, abnormalities in vasomotor activity or psychogenic disorders. An inflammatory process not only explains the objective clinical findings such as edema, swelling, erythema and impaired function, but may also be involved in development of pain (tissue ischemia, increased tissue pressure etc.) However, an inflammatory component does not preclude a role of the sympathetic nervous system as a factor involved in the whole array of abnormalities in RSD. The nervous system is not only involved in modulation of processing of pain stimuli in the spinal cord (Wall and Melzack 1984), but also in the spread of nociceptor excitation due to release of vasoactive substances (so-called neurogenic inflammation) (Foreman and Jordan 1984). The latter can be the cause, an aggravating factor or a factor responsible for the further spread of the inflammatory reaction in the affected extremity. This also might explain the success of sympathetic blocks in some patients by interrupting the vicious circle between periphery and central nervous system (Procacci and Maresca 1987). However, not all patients with clear clinical symptoms respond well to this type of therapy. It has been reported that aggravation of pain may occur after regional guanethidine block in acute RSD, indicating that local factors are involved (Driessen et al. 1983). Moreover, the identification of an inflammatory component in RSD may prove relevant for therapeutic interventions aiming at adequate cessation of pain and at limitation of persisting disabilities: therapy targetted at the harmful consequences of inflammation, such as free radical production, or at least limitation of its effects may prove to be advantageous (Goris 1985; Goris et al. 1987; Langendijk et al. 1993).

Since the flow phase T/B ratios – when In-111-IgG was in the intravascular space – and the T/B ratios after 24 and 48 h – when a portion of the In-111-IgG was in the extravascular space – were not correlated, it appears that 2 separate phenomena are involved in RSD: firstly, an abnormality in the bloodflow to the affected hand and secondly, increased permeability for large proteins, such as In-111-IgG. The presence of 2 phenomena was further exemplified by the 2 patients with a diminished flow that clearly showed increasing activity in the affected hand on the late static images.

All patients showed abnormalities in the arterial or venous phase of the In-111-IgG scintigraphy. Increased flow has also been noted by other authors, who used the bone scanning agent technetium-99m (Tc-99m) diphosphonate (Kozin et al. 1976b; Kozin et al. 1981; Maurer et al. 1983; Greyson and Tepperman 1984; Demangeat et al. 1988). This has been explained by altered sympathetic nervous activity, resulting in abnormalities of the vasomotor tone. Blockx and Driessens (1991) imaged patients up to 20 min, using Tc-99m labeled human serum albumin (HSA). In the majority

of patients with early RSD, an increased flow was found, followed by a decrease of T/B ratios. This pattern was very similar to the pattern observed for the flow phases and early images of In-111-IgG: increased flow, followed by a decrease of the T/B ratios (In-111-IgG patterns A and B). Blockx et al. hypothesized that the relative decrease in the first 20 min was caused by a fall in vascular resistance due to opening of arteriovenous shunts. They considered the images after 10 min to be a steady state. Unfortunately, they did not perform imaging beyond 20 min, so evidence of extravasation of Tc-99m-HSA beyond these relatively early images was not available.

Greyson and Tepperman (1984) found in 8 of 21 patients with early RSD after a cerebrovascular accident decreased flow with increased uptake on the late diphosphonate bone scan images. They speculated that this was due to a decreased flow to the soft tissues, while bone blood flow was relatively increased. Their data were confirmed by the results of Demangeat et al. (1988) who found decreased arterial flow in 8% of their cases. An inflammatory response could also explain the scintigraphic findings after administration of a bone scanning agent in RSD patients. On top of increased uptake in bone due to increased flow, an even larger portion of the Tc-99m-diphosphonate dose would be available for binding to bone when vascular permeability is increased.

Despite persisting abnormalities in the arterial and venous phase, 5 of 6 patients with stage II RSD had a negative In-111-IgG scintigraphy with regard to the static images. This indicates that the increased permeability for macromolecules decreases after approximately 5 months. This suggests, that the inflammatory response subsides with time, when atrophy and dystrophy become more apparent. Demangeat et al. (1988) observed normalization of the bone scan pattern in stage II in 32% of their patients.

The scarce histological findings in the literature are in agreement with our findings. Kozin et al. (1976a) noted inflammatory changes in 2 patients with early RSD. Two other patients, who showed no histologic evidence of inflammation, had RSD for as long as 1 year. Since 2 of 4 patients had late RSD, the time point for demonstrating inflammation in RSD might have been less optimal in their small group of patients. Therefore, one might question the validity of their conclusion that histologically no frank inflammation is involved in RSD. In skeletal muscle biopsies, taken from patients with RSD, evidence of pathologic muscle alterations due to oxidative stress was observed (Tilman et al. 1990). Our present data are also in agreement with previous clinical studies that suggested the tissue damage in RSD was due to an inflammatory response, caused by free oxygen radicals (Goris et al. 1987, 1990).



In conclusion, the present data support the hypothesis that a flow-independent, inflammatory component is present in RSD. It can be observed especially in early RSD and may subside in the course of the disease. Our findings do not support the current consensus that altered sympathetic activity and subsequent vasomotor tone changes are the sole somatic factors responsible for the development of RSD.

From a pathophysiologic point of view, a multi-phase In-111-IgG scintigraphy appears to be better suited for the assessment of RSD than conventional 3-phase bone scintigraphy, since both flow phenomena and late, flow-independent In-111-IgG accumulation can be evaluated. The evolution of the scintigraphic pattern after therapy and a possible correlation between scintigraphy and the outcome of therapy will be the object of further studies.

### Acknowledgement

The authors express their gratitude to D.J. Immerzeel for technical assistance.

### References

- Atkins, R.M.A., Duckworth, K., Karnes, J.A., Features of algodystrophy after Colles' fracture, *J. Bone Joint Surg.*, 72 (1990) 105-110.
- Blockx, P. and Driessens, M., The use of Tc-99m-HSA dynamic vascular examination in the staging and therapy monitoring of reflex sympathetic dystrophy, *Nucl. Med. Comm.*, 12 (1991) 725-731.
- Christensen, K., Jensen, E.M. and Noer, I., The reflex dystrophy syndrome. Response to treatment with corticosteroids, *Acta Chir. Scand.*, 148 (1982) 653-655.
- Demangeat, J.L., Constantinesco, A., Brunot, B., Foucher, G. and Farcot, J.M., Three-phase bone scanning in reflex sympathetic dystrophy of the hand, *J. Nucl. Med.*, 29 (1988) 26-32.
- Driessen, J.J., Van der Werken, Ch., Nicolai, J.P.A. and Crul, J.F., Clinical effects of regional intravenous guanethidine in reflex sympathetic dystrophy, *Acta Anaesthesiol. Scand.*, 27 (1983) 505-509.
- Fischman, A.J., Rubin, R.H., Khaw, B.A. et al., Detection of acute inflammation with indium-111 labeled nonspecific polyclonal IgG, *Sem. Nucl. Med.*, 18 (1988) 335-344.
- Foreman, J.C. and Jordan, C.C., Neurogenic inflammation, *Trends Pharmacol. Sci.*, (1984) 116-119.
- Goris, R.J.A., Treatment of reflex sympathetic dystrophy with hydroxyl-radical scavengers, *Unfallchirurg*, 88 (1985) 1-3.
- Goris, R.J.A., Dongen, L.M.V. and Winters, H.A.H., Are toxic oxygen radicals involved in the pathogenesis of reflex sympathetic dystrophy?, *Free Rad. Res. Comm.*, 3 (1987) 13-18.
- Goris, R.J.A., Reynen, J.A.M. and Veldman, P., De klinische verschijnselen bij posttraumatische dystrofie, *Ned. Tijdschr. Geneesk.*, 134 (1990) 2138-2141.
- Greyson, N.D. and Tepperman, P.S., Three-phase bone studies in hemiplegia with reflex sympathetic dystrophy and the effect of disuse, *J. Nucl. Med.*, 25 (1984) 423-429.
- Hanna, M.H. and Peat, S.J., Ketanserin in reflex sympathetic dystrophy. A double-blind controlled cross-over trial, *Pain*, 38 (1989) 145-150.
- Hannington-Kiff, J.G., Does failed natural opioid modulation in regional sympathetic ganglia cause reflex sympathetic dystrophy?, *Lancet*, 338 (1991) 1125-1127.
- Hnatowich, D.J., Childs, R.L., Lantaigne, D. and Najafi, A., The preparation of DTPA-coupled antibodies radiolabeled with metallic radionuclides: an improved method, *J. Immunol. Meth.*, 65 (1983) 147-157.
- Kozin, F., McCarty, D.J., Sims, J. and Genant, H., The reflex sympathetic dystrophy syndrome. I. Clinical and histologic studies: evidence for bilaterality, response to corticosteroids and articular involvement, *Am. J. Med.*, 60 (1976a) 321-331.
- Kozin, F., Genant, H.K., Bekerman, C. and McCarty, D.J., The reflex sympathetic dystrophy syndrome. II. Roentgenological and scintigraphic evidence of bilaterality and of periarticular accentuation, *Am. J. Med.*, 60 (1976b) 332-338.
- Kozin, F., Ryan, L.M., Carrera, G.F. and Soin, J.S., The reflex sympathetic dystrophy syndrome. III. Scintigraphic studies, further evidence for the therapeutic efficacy of systemic corticosteroids, and proposed diagnostic criteria, *Am. J. Med.*, 70 (1981) 23-30.
- LaMuraglia, G.M., Fischman, A.J., Strauss, H.W. et al., Utility of indium-111 labeled human immunoglobulin G scan for the detection of focal vascular graft infection, *J. Vasc. Surg.*, 10 (1989) 20-28.
- Langendijk, P.N.J., Zuurmond, W.W.A., Van Apeldoorn, H.A.C., Van Loenen, A.C. and de Lange J.J., Goede resultaten van behandeling van acute reflectoïr-sympathische dystrofie met een 50%-dimethylsulfoxide-crème, *Ned. Tijdschr. Geneesk.*, 137 (1993) 500-505.
- Maurer, A.H., Holder, L.E., Espinola, D.A., Rupani, H.D. and Shaw Wilgis, E.F., Three-phase radionuclide scintigraphy of the hand, *Radiology*, 146 (1983) 761-775.
- Morrel, E.M., Tompkins, R.G., Fischman, A.J. et al., Autoradiographic method for quantitation of radiolabeled proteins in tissues using indium-111, *J. Nucl. Med.*, 30 (1989) 1538-1545.
- Oyen, W.J.G., Claessens, R.A.M.J., Van Horn, J.R., Van der Meer, J.W.M. and Corstens, F.H.M., Scintigraphic detection of bone and joint infections with indium-111 labeled nonspecific polyclonal human immunoglobulin G, *J. Nucl. Med.*, 31 (1990) 403-412.
- Oyen, W.J.G., Claessens, R.A.M.J., Van der Meer, J.W.M. and Corstens, F.H.M., Detection of subacute infectious foci with indium-111 labeled autologous leukocytes and with indium-111 labeled human nonspecific immunoglobulin G: a prospective comparative study, *J. Nucl. Med.*, 32 (1991) 1854-1860.
- Oyen, W.J.G., Claessens, R.A.M.J., Raemaekers, J.M.M., de Pauw, B.E., Van der Meer, J.W.M. and Corstens, F.H.M., Diagnosing infection in febrile granulocytopenic patients with indium-111 labeled human IgG, *J. Clin. Oncol.*, 10 (1992a) 61-68.
- Oyen, W.J.G., Van Horn, J.R., Claessens, R.A.M.J., Slooff, T.J.J.H., Van der Meer, J.W.M. and Corstens, F.H.M., Diagnosis of bone, joint and joint prosthesis infections with indium-111 labeled nonspecific human immunoglobulin G scintigraphy, *Radiology*, 182 (1992b) 195-199.
- Oyen, W.J.G., Claessens, R.A.M.J., Van der Meer, J.W.M. and Corstens, F.H.M., Biodistribution and kinetics of radiolabeled proteins in rats with focal infection, *J. Nucl. Med.*, 33 (1992c) 388-394.
- Poplawski, Z.J., Wiley, A.M., Murray, J.F. et al., Posttraumatic dystrophy of the extremities, *J. Bone Joint Surg.*, 65 (1983) 642-655.
- Price, D.D., Long, S. and Huitt, C., Sensory testing of pathophysiological mechanisms of pain in patients with reflex sympathetic dystrophy, *Pain*, 49 (1992) 163-173.



Procacci, P. and Maresca, M., Reflex sympathetic dystrophies and algodystrophies: historical and pathogenetic considerations, Pain, 31 (1987) 137-146.

Rubin, R.H., Fischman, A.J., Callahan, R.J. et al., In-111 labeled nonspecific immunoglobulin scanning in the detection of focal infection, N. Engl. J. Med., 321 (1989) 935-940.

Sudeck, P., Die sogenannte Knochenatrophie als Entzündungsvorgang, Der Chirurg., 15 (1942) 449-457.

Sudeck, P., Über die akute entzündliche Knochenatrophie, Arch. Klin. Chir., 62 (1900) 147-156.

Tilman, P.B.J., Stadhouders, A.M., Jap, P.H.K. and Goris, R.J.A., Histopathologic findings in skeletal muscle tissue of patients suffering from reflex sympathetic dystrophy, Micron Microscop. Acta, 21 (1990) 271-272.

Wall, P.D. and Melzack, R., Textbook of Pain, Churchill-Livingstone, Edinburgh, 1984.