

## PDF hosted at the Radboud Repository of the Radboud University Nijmegen

This full text is a publisher's version.

For additional information about this publication click this link.

<http://hdl.handle.net/2066/14886>

Please be advised that this information was generated on 2014-11-11 and may be subject to change.

# Indium-111-Labeled Polyclonal Human Immunoglobulin: Identifying Focal Infection in Patients Positive for Human Immunodeficiency Virus

John R. Buscombe, Wim J.G. Oyen, Alison Grant, Roland A.M.J. Claessens, Jos van der Meer, Frans H.M. Corstens, Peter J. Ell and Robert F. Miller

*Institute of Nuclear Medicine and Department of Medicine, University College London School of Medicine, London, England; the Departments of Nuclear Medicine and Internal Medicine, University Hospital, Nijmegen, The Netherlands*

Pooled human immunoglobulin labeled with indium-111 ( $^{111}\text{In}$ -HlgG) was used to identify the presence and extent of infection in patients positive for human immunodeficiency virus (HIV), presenting with either symptoms and/or signs of acute chest infection or with pyrexia without localizing signs or symptoms. Fifty-five studies were performed in 51 patients with suspected chest infection or pyrexia without localizing signs. Of these,  $^{111}\text{In}$ -HlgG identified intrapulmonary accumulation in 17 patients with *Pneumocystis carinii* pneumonia, eight with bacterial pneumonia, five with cytomegalovirus pneumonia, three with pulmonary *Mycobacterium avium intracellulare* infection and one with a fungal pneumonia. There was no intrapulmonary accumulation of  $^{111}\text{In}$ -HlgG in five patients with bronchopulmonary Kaposi's sarcoma and in three patients with intrathoracic lymphoma. Quantification of lung/heart activity was significantly increased ( $p < 0.05$ ) in patients with active chest infection compared with those with intrapulmonary tumor or no active lung pathology. Indium-111-HlgG scintigraphy also localized at 14 sites of extrapulmonary infection, including six patients with colitis. There were no false-negative studies but false-positive uptake was seen in four studies. These results confirm that  $^{111}\text{In}$ -HlgG correctly identifies the presence and extent of infection in patients positive for HIV antibody.

**J Nucl Med 1993; 34:1621-1625**

**T**he diagnosis of infection in patients with human immunodeficiency virus (HIV) infection and those with acquired immunodeficiency syndrome (AIDS) is frequently hampered by the nonspecific nature of presenting symptoms and signs. Conventional imaging techniques such as chest radiographs and x-ray-computed tomography (CT), al-

though sensitive, may fail to demonstrate abnormalities in the presence of active infection (1-3). Conventional imaging may not distinguish changes due to infection from those secondary to Kaposi's sarcoma.

Functional imaging with  $^{67}\text{Ga}$ -citrate has proven useful in the investigation of HIV-positive patients with focal and diffuse infections. The technique is at its most useful in distinguishing *Pneumocystis carinii* pneumonia (PCP) from bronchopulmonary Kaposi's sarcoma (4,5). Intrapulmonary accumulation of  $^{67}\text{Ga}$ -citrate is not specific for PCP and uptake is also seen in several other pathologies including lymphoma (6). The presence of physiological bowel uptake, which may be increased in patients with AIDS, further reduces the utility of  $^{67}\text{Ga}$ -citrate in identifying intraabdominal sepsis or colonic infection (7).

Pooled human immunoglobulin (HlgG) labeled with  $^{111}\text{In}$  or  $^{99\text{m}}\text{Tc}$  has been shown to have a high sensitivity and specificity in localizing infection in immune competent patients (8-10). Like  $^{67}\text{Ga}$ -citrate it has the advantage of simple intravenous injection, in contrast to labeled autologous white cells in which extensive handling of blood products is required. Unlike  $^{67}\text{Ga}$ -citrate there is only minimal physiological bowel uptake of  $^{111}\text{In}$ -HlgG. In steroid-immunosuppressed rats with PCP imaging with  $^{111}\text{In}$ -HlgG demonstrated higher sensitivity than imaging with  $^{67}\text{Ga}$ -citrate (11).

The aim of this study was to determine the efficacy of  $^{111}\text{In}$ -HlgG in identifying the presence and extent of infection in HIV-positive patients presenting with either symptoms and/or signs of acute chest infection or pyrexia without localizing symptoms or signs.

## METHODS AND MATERIALS

We prospectively studied consecutive HIV-positive patients presenting with suspected infection. Patients were included in the trial if they: (1) had signs or symptoms suggestive of chest infection in which initial investigations, including chest radiology,

Received Jan. 15, 1993; revision accepted June 17, 1993.  
For correspondence and reprints contact: John R. Buscombe, MD, Institute of Nuclear Medicine, University College London School of Medicine, Mortimer Street, London W1N 8AA, England.

blood chemistry, full blood count, blood and sputum cultures, had failed to provide a diagnosis; and (2) had pyrexia for at least four days without localizing signs or symptoms, and simple investigations such as radiology, ultrasound, blood chemistry, full blood count and culture of blood, sputum, urine or feces were nondiagnostic.

All patients gave informed written consent for participation in the study, and the protocol was approved by the Clinical Investigation Committee of the Middlesex Hospital and the Administration of Radioactive Substances Advisory Committee (ARSAC). Fifty-five studies were performed in 51 patients (50 males); mean age was 32 (range 18–57) yr. Two patients had a second study performed after intervals of 2 and 5 mo, and one patient had three studies over a 7-mo period. These repeat studies were carried out because the patients presented with new symptoms or a recurrence of old symptoms. Thirty-eight studies were performed for suspected chest infection and 17 for pyrexia without localizing features.

### Radiopharmaceutical

Pooled nonspecific human polyclonal immunoglobulin G (Sandoz globulin, Sandoz AG, Nurnberg, Germany), which was negative for HIV and Hepatitis B surface antigen was conjugated with diethylenetriamine pentacetic acid (DTPA). The conjugated solution was sterilized by gel filtration and aliquots of 0.5 ml and stored at  $-20^{\circ}\text{C}$  in sterile glass vials until used. For each study, a vial was allowed to thaw and conjugated with  $^{111}\text{In}$  chloride (Mallinckrodt Medical, Petten, The Netherlands) (12). A dose of 0.25–0.5 mg of human immunoglobulin labeled with 1 mCi (37 MBq) of  $^{111}\text{In}$  in a volume of 0.3–0.5 ml was used for each study and injected intravenously into the antecubital vein of the non-dominant arm.

### Imaging Protocol

Using an IGE 400AC Starcam gamma camera and computer (IGE International, Radlett, Berkshire UK) anterior and posterior planar images of the abdomen, pelvis and chest were obtained at 4, 24 and 48 hr after injection of  $^{111}\text{In}$ -HIgG. The camera was fitted with a medium-energy parallel-hole collimator. Images were collected in digital form into a  $128 \times 128$  matrix. Two photopeaks, 173 and 247 keV, each with 20% windows, were used. Each image was acquired for 600k counts and formatted onto x-ray film for reporting. Each image was obtained in about 4–6 min.

### Qualitative Analysis of Studies

The 4, 24 and 48-hr images from each study were reported independently by two observers who were blind to patient clinical diagnosis and laboratory results. A study was considered positive if both observers agreed there was diffuse or focal accumulation of  $^{111}\text{In}$ -HIgG in the lungs equal or greater than surrounding bone marrow or surrounding soft tissue activity in neck or shoulder (intrapulmonary). If bone marrow activity was absent, comparison was made to soft tissue alone. A study was also considered positive if both observers agreed there was focal accumulation at any site in the chest outside the lungs, abdomen or pelvis greater than surrounding soft tissue (extrapulmonary). If there was disagreement between the two observers, the study was considered negative.

Results of  $^{111}\text{In}$ -HIgG scans were compared in all studies with the final diagnosis obtained by microbiological and histological investigations of blood, urine and sputum, including expressed sputums, bronchoalveolar lavage fluid and feces. Results of each study also were compared to information obtained by other in-

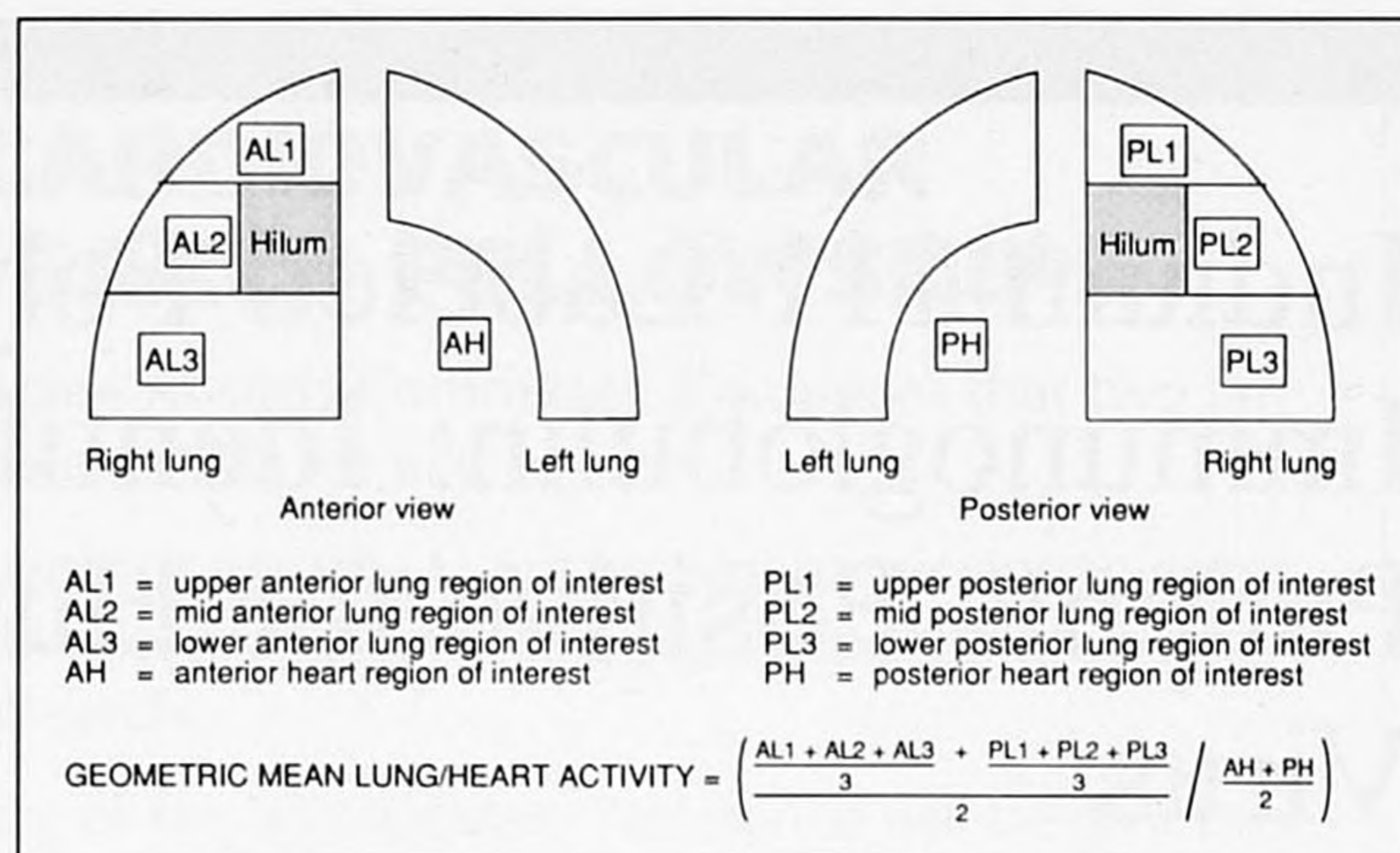


FIGURE 1. Regions of interest used to calculate the geometric mean of the lung-to-heart ratio of  $^{111}\text{In}$ -HIgG activity.

vestigations, including upper gastrointestinal endoscopy, colonoscopy, open biopsy and CT-guided percutaneous biopsy. All patients had undergone chest x-ray in the 48 hr before or after initiation of the  $^{111}\text{In}$ -HIgG study.

Only histological or microbiological data were used for comparison with  $^{111}\text{In}$ -HIgG images.

### Quantitative Analysis

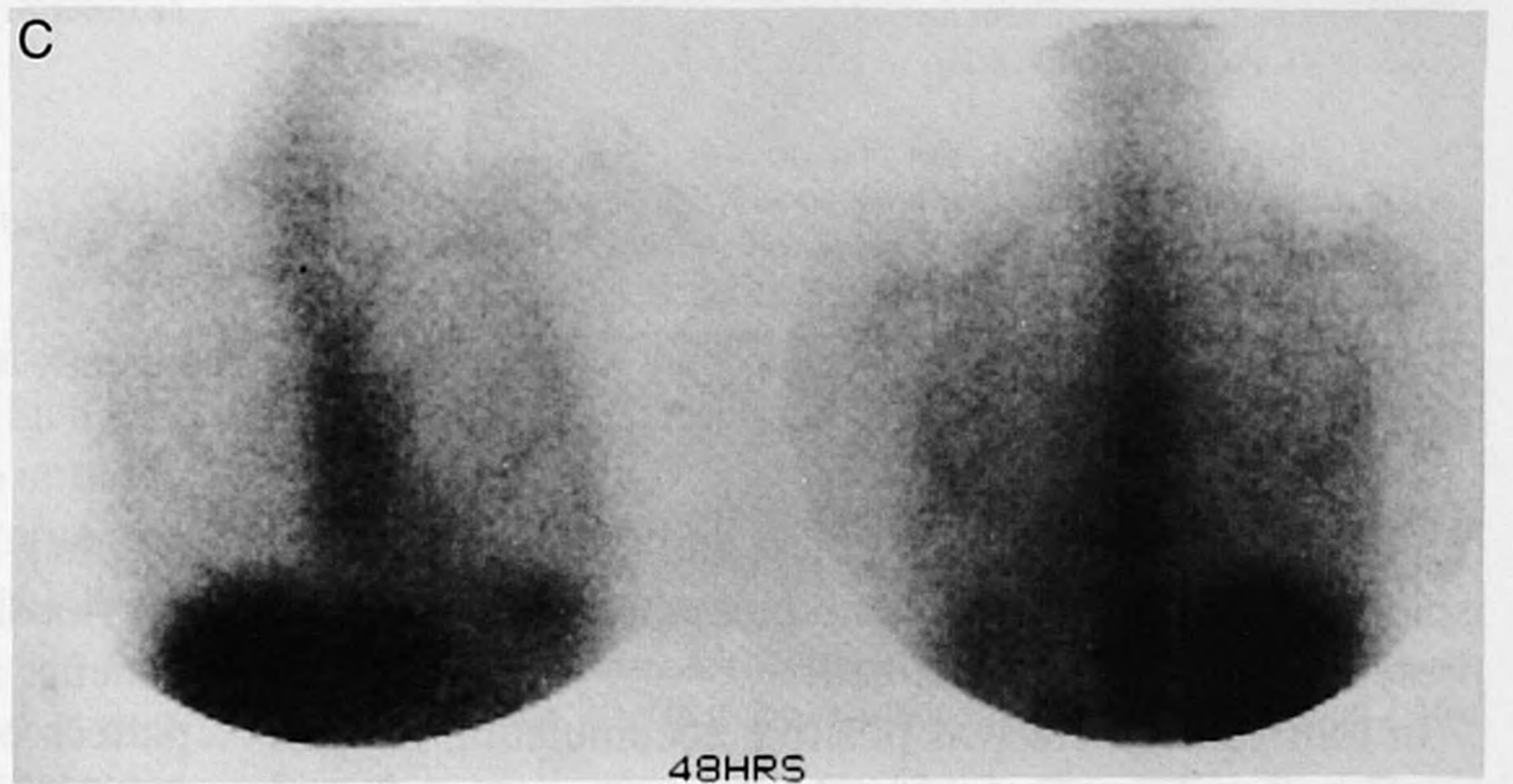
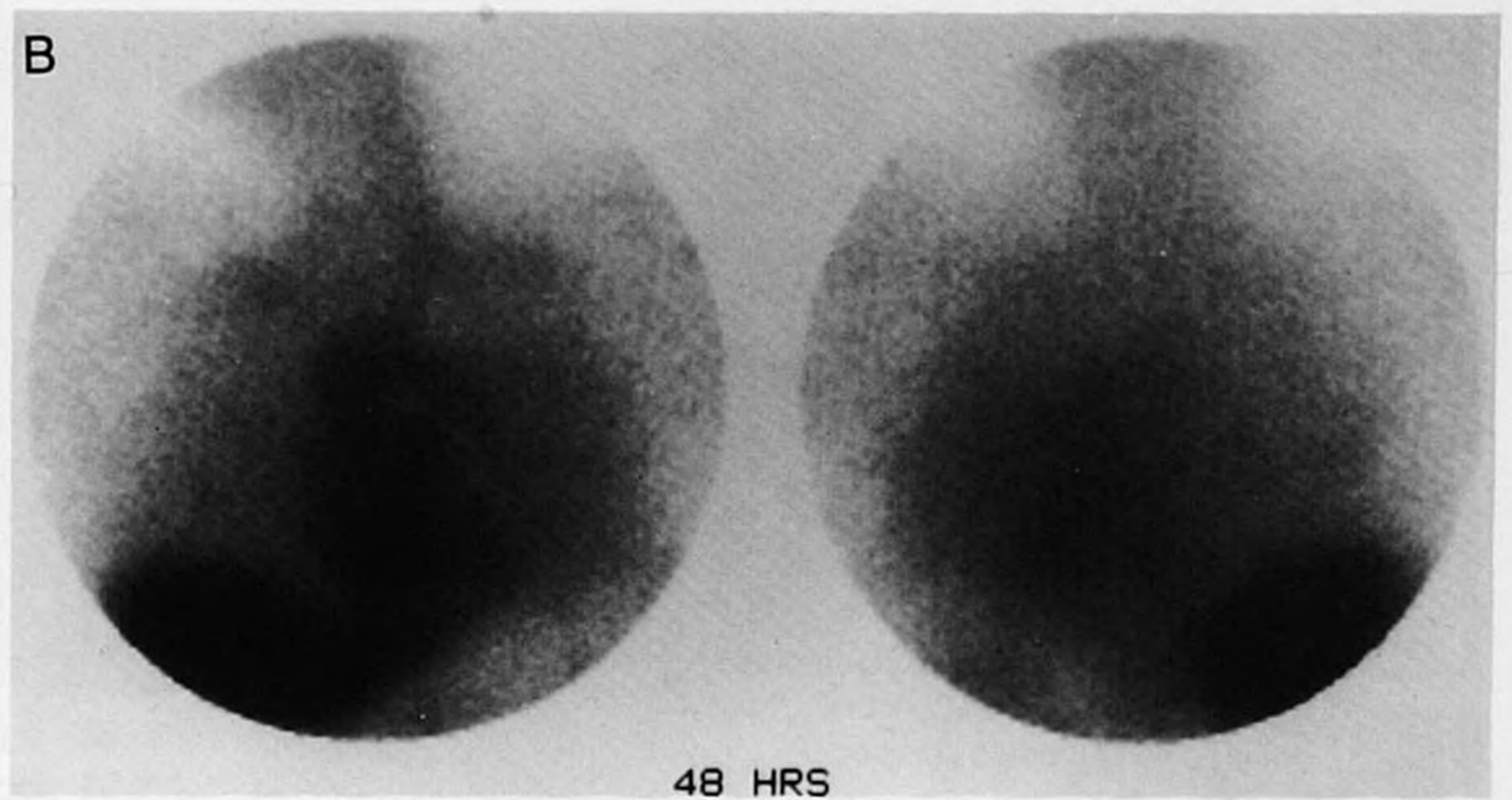
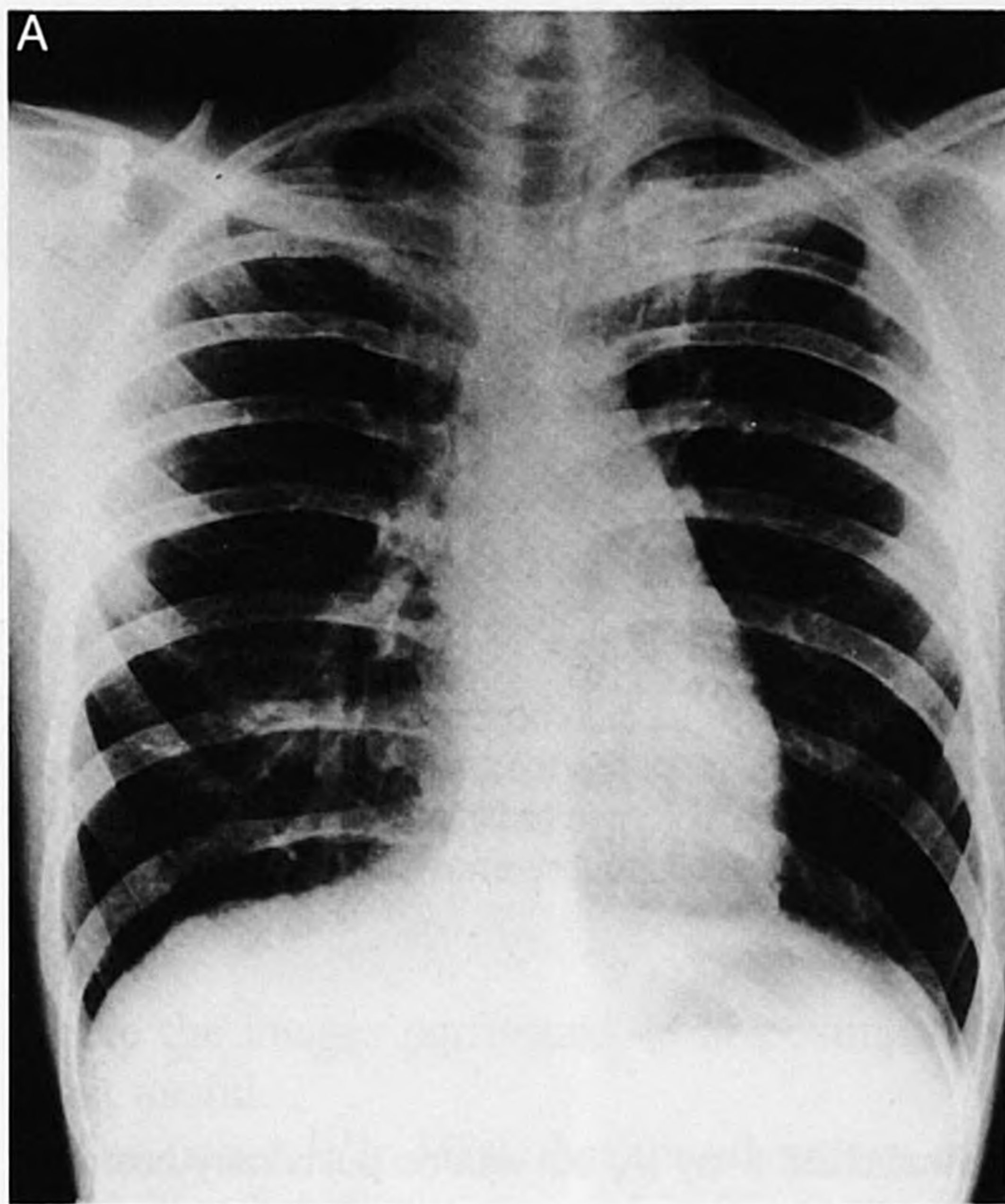
Instead of a subjective grading of lung uptake, a quantitative analysis of intrapulmonary accumulation of  $^{111}\text{In}$ -HIgG was calculated using the 48-hr images in all studies. This was done using the geometric mean of lung activity obtained by using a  $10 \times 10$  pixel ( $31.2 \text{ mm} \times 31.2 \text{ mm}$ ) region of interest (ROI), placed in the upper, middle (avoiding the hilum) and lower thirds of the right lung on both the anterior and posterior images of the chest (Fig. 1). The left lung was not used to quantify lung activity as it was impossible to draw ROIs in the lower third of the lung that did not include activity in the heart. The mean-lung activity was normalized to blood-pool activity by dividing the geometric mean of lung activity by the geometric mean of activity in the left ventricle (derived by using a  $10 \times 10$  pixel ROI drawn over the heart in both anterior and posterior images).

The resulting lung-to-heart ratio was calculated for the different groups of studies; those in patients with PCP, those with pulmonary infection due to other causes, those with intrapulmonary tumor and studies of patients with no acute chest disease. The mean lung-to-heart ratio at 48 hr in those patients with PCP and those with infection due to other causes was compared with the mean lung-to-heart ratio of the normal studies using an unpaired Student t-test.

## RESULTS

### Intrapulmonary Disease

Seventeen cases of PCP were confirmed, in which all patients had abnormal pulmonary uptake of  $^{111}\text{In}$ -HIgG (Fig. 2, Table 1). Positive pulmonary uptake of  $^{111}\text{In}$ -HIgG was also found in 20 cases of pulmonary infection due to other causes, including bacterial infection (eight studies), pulmonary *Mycobacterium avium intracellulare* (MAI) (six studies) cytomegalovirus (five studies) and fungal infection (one study). Images taken 48 hr postinjection provided the most positive images of infection, although 24-hr images were scored positive in all studies. Images at 4 hr postinjection were not helpful.



**FIGURE 2.** Patient with *Pneumocystis carinii* pneumonia and a normal chest x-ray (A) but with diffuse intrapulmonary accumulation of  $^{111}\text{In-HlgG}$  seen (B) 48 hr postinjection. This is compared with a 48-hr anterior chest image in a patient with no pulmonary disease (C).

Eight studies, including five in patients with bronchopulmonary Kaposi's sarcoma and three in patients with extensive intrapulmonary B-cell lymphoma, had no coexistent pulmonary infection. In all studies there was no elevated uptake of  $^{111}\text{In-HlgG}$  in the lungs (Fig. 3). Of the ten patients in whom no intrapulmonary disease was confirmed, only one patient, who had endstage renal failure, had diffuse pulmonary accumulation of  $^{111}\text{In-HlgG}$ .

In the 17 cases of PCP, there was evidence of diffuse pulmonary accumulation of  $^{111}\text{In-HlgG}$  in 14 cases, as opposed to evidence on x-ray of diffuse changes in only six of

14 cases, focal abnormalities in two of the cases, and normal readings in the remaining six. In the other three of 17 cases, both  $^{111}\text{In-HlgG}$  and chest x-ray revealed focal abnormalities. In four cases of pulmonary infection due to other causes,  $^{111}\text{In-HlgG}$  showed diffuse intrapulmonary uptake while chest x-rays were normal. In these four cases the organisms of infection were MAI (two cases), *Haemophilus influenzae* (one case) and cytomegalovirus (one case).

#### Quantitative Analysis

Quantitative analysis of lung/heart activity confirms the qualitative data and demonstrates a significantly increased lung-to-heart ratio of  $^{111}\text{In-HlgG}$  at 48 hr postinjection in patients with chest infection due to both PCP and other causes, compared with patients in whom there was no intrapulmonary disease (Table 2). There was no significant difference in the lung-to-heart ratio of  $^{111}\text{In-HlgG}$  in patients with intrapulmonary neoplasia such as Kaposi's sarcoma and B-cell lymphoma and in patients with no intrapulmonary disease.

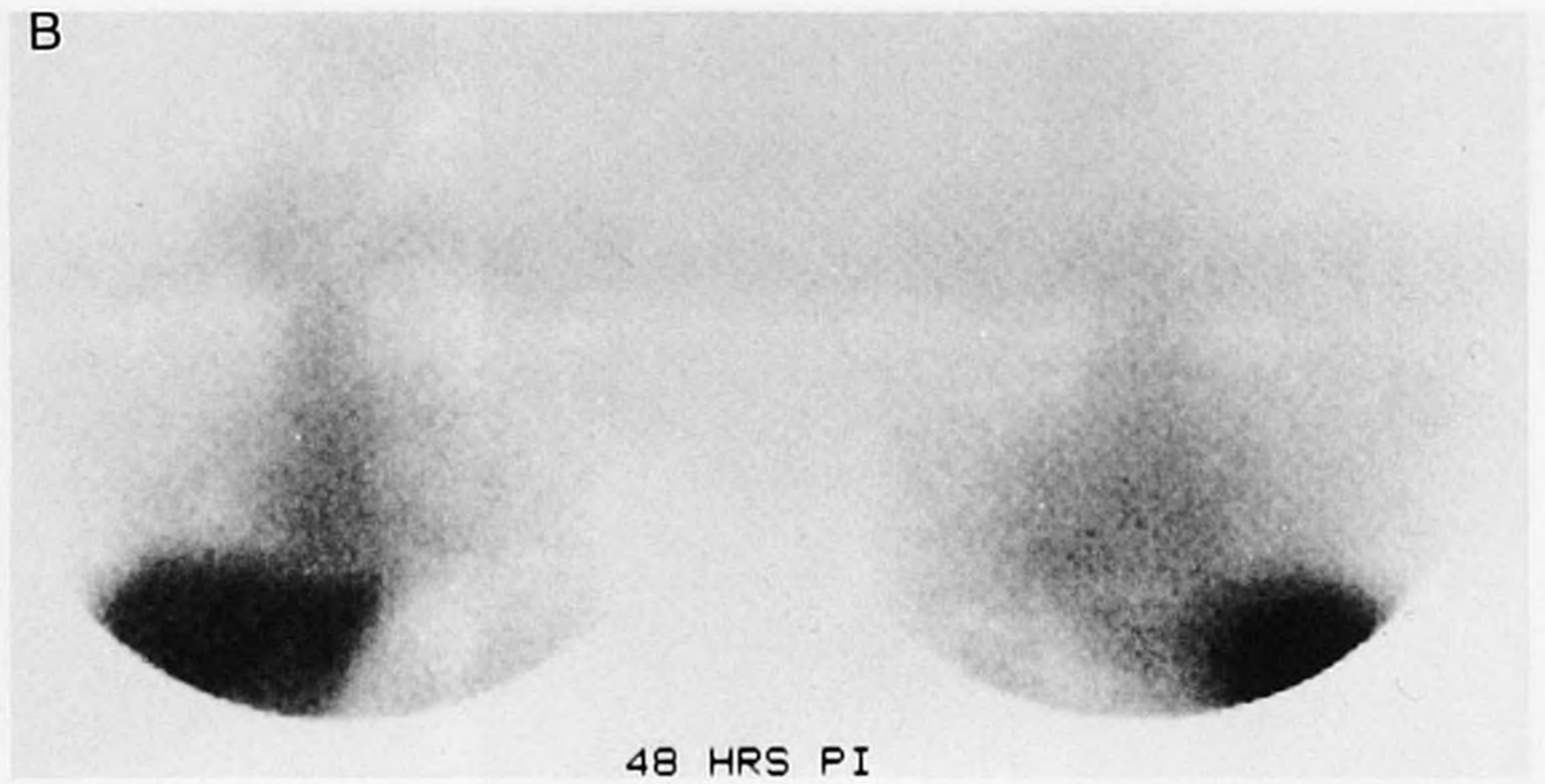
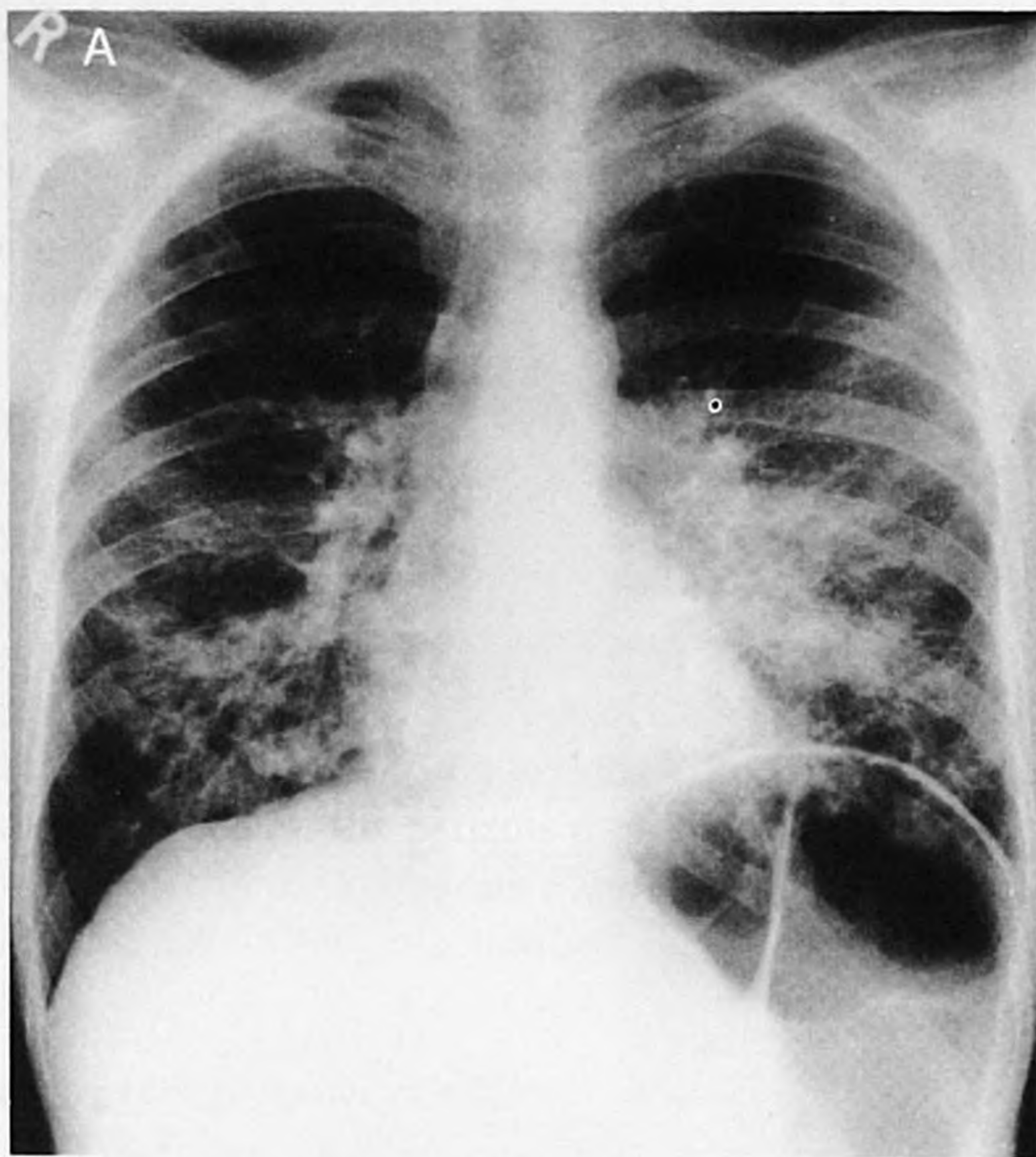#### Extrapulmonary Disease

Uptake of  $^{111}\text{In-HlgG}$  outside the lungs (extrapulmonary) was seen in 13 cases (Table 3). Colitis/proctitis was correctly identified in all six cases in which it was confirmed histologically. One patient had bacterial pericarditis, one had sinusitis and one had an unsuspected ischioanal abscess; all were correctly identified by  $^{111}\text{In-HlgG}$

**TABLE 1**  
Intrapulmonary Accumulation of  $^{111}\text{In-HlgG}$  in 55 Studies

Diagnosis	$^{111}\text{In-HlgG}$ study result	
	Positive	Negative
Intrapulmonary disease		
<i>Pneumocystis carinii</i> pneumonia	17	0
Bacterial pneumonia*	8	0
<i>Mycobacterium avium intracellulare</i>	6	0
Cytomegalovirus	5	0
Fungal pneumonia ( <i>Aspergillus sp</i> )	1	0
Bronchopulmonary Kaposi's sarcoma	0	5
Intrapulmonary lymphoma sarcoma	0	3
No pulmonary disease	1	9

\*Causative agents were *Haemophilus influenzae* (n = 4), *Streptococcus pneumoniae* (n = 3) and *Cryptococcus neoformans* (n = 1).



**FIGURE 3.** Patient with bronchopulmonary Kaposi's sarcoma and a grossly abnormal chest x-ray (A) but with no pulmonary accumulation of  $^{111}\text{In-HlgG}$  (B) seen 48 hr postinjection.

(Fig. 4). In one patient with colitis and in the patient with ischioanal abscess, coexistent pulmonary infection was present and correctly identified.

In four cases there was positive accumulation of  $^{111}\text{In-HlgG}$  in the absence of infection. In the patient with end-stage renal disease who had diffuse lung accumulation of  $^{111}\text{In-HlgG}$ , diffuse abdominal accumulation of  $^{111}\text{In-HlgG}$  also occurred. In two patients with B-cell lymphoma, there was colonic accumulation of  $^{111}\text{In-HlgG}$  but no histological evidence of colon involvement by either infection or tumor. In the fourth case,  $^{111}\text{In-HlgG}$  accumulated at the site of a sterile hematoma secondary to a stab wound.

## DISCUSSION

Results demonstrate that  $^{111}\text{In-HlgG}$  can identify a wide range of infection in HIV-positive patients, including bacteria, fungi and viruses. The sensitivity of  $^{111}\text{In-HlgG}$  was high (100%) in the chest with no false-negative studies. It is known that  $^{67}\text{Ga-citrate}$  has a sensitivity greater than 90% in localizing chest infection in HIV-positive patients

(4,5,13) and these results are therefore comparable. As previously reported in a small number of HIV-negative patients and in immunosuppressed rats, the predominant pattern of  $^{111}\text{In-HlgG}$  seen with PCP was diffuse intrapulmonary activity (DIPA) (8,11). This distribution, seen in 14 of 17 patients with PCP is similar to that reported using  $^{67}\text{Ga-citrate}$  in this disease (4,5).

The use of  $^{111}\text{In}$  as the radiolabel allows longer imaging times than other radiolabels such as  $^{99\text{m}}\text{Tc}$ . This may explain why the 100% sensitivity for identifying pulmonary infection obtained in this series was higher than the 33% obtained in a previous study that used  $^{99\text{m}}\text{Tc}$  to label HlgG (14). It is known that  $^{111}\text{In-HlgG}$  will accumulate in sites of infection in HIV-negative patients but not in immunocompromised patients (15) and imaging is required beyond the 24-hr limit set by the short physical half-life of  $^{99\text{m}}\text{Tc}$ . This is probably because significant blood-pool activity, obscuring any infection is still present in the chest at 24 hr postinjection but clears by 48 hr. This was confirmed in our study

**TABLE 2**  
Lung-to-Heart Ratios of  $^{111}\text{In-HlgG}$  at 48 Hours Postinjection

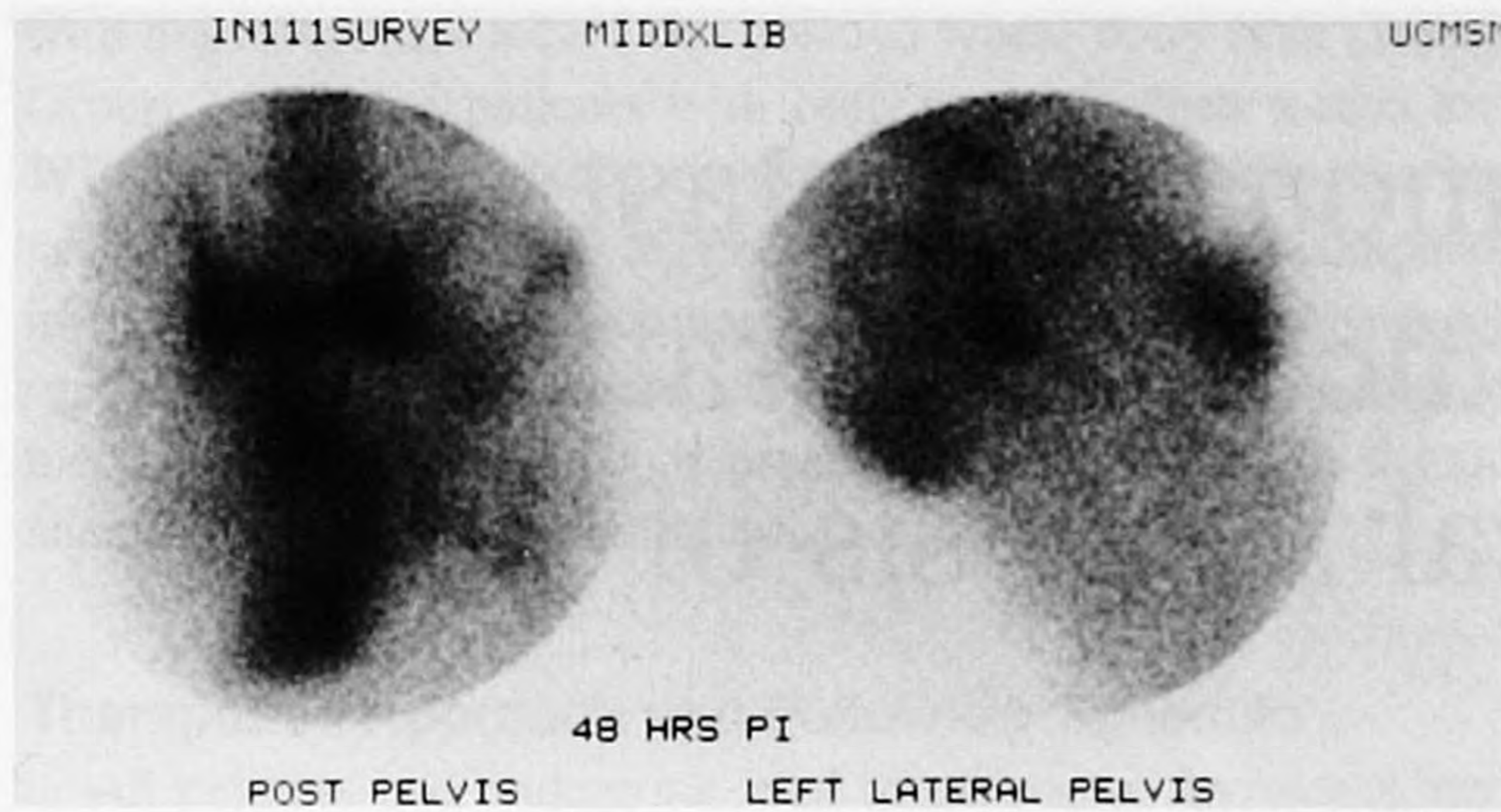
Patient group	n	Lung-to-heart ratios
<i>Pneumocystis carinii pneumonia</i>	17	0.66 (0.05)*
All other causes of pulmonary infection	20	0.59 (0.09)*
No pulmonary disease	10	0.51 (0.04)
Pulmonary tumor	8	0.51 (0.07)†

Data displayed as mean ( $\pm$  s.d.). Using student's t-test difference in lung/heart activity in these groups compared with those studies in which no intrapulmonary disease was present was \* significant ( $p < 0.05$ ) or † not significant.

**TABLE 3**  
Extrapulmonary Accumulation of  $^{111}\text{In-HlgG}$  in 55 Studies

Diagnosis	$^{111}\text{In-HlgG}$ study result	
	Positive	Negative
Extrapulmonary disease		
Colitis/proctitis	6	0
Ischioanal abscess	1	0
Infected axillary lymph node	1	0
Bacterial pericarditis	1	0
Sinusitis	1	0
No extrapulmonary infection	4*	41

\*One patient with renal failure, one with noninfected hematoma and two with lymphoma had unexplained colonic activity in the absence of colonic disease.



**FIGURE 4.** Intense accumulation of  $^{111}\text{In}$ -HIgG seen 48 hr postinjection, extending from the rectum into the right buttock. At the time of scanning only minimal symptoms had developed at site but over 1 liter of pus was removed at operation 24 hr later.

where the images performed 48 hr postinjection were the most useful.

The tracer  $^{111}\text{In}$ -HIgG has an advantage over  $^{67}\text{Ga}$  citrate in that it does not accumulate in lymphoma, which was present in three of our patients. This has also been noted in previous studies on HIV-negative patients with lymphoma (8,15). Like  $^{67}\text{Ga}$ -citrate, the presence of  $^{111}\text{In}$ -HIgG in the chest of a patient with bronchopulmonary Kaposi's sarcoma is indicative of superimposed infection, and is particularly useful when chest x-ray is abnormal and therefore limited in its use diagnostically. Tracer  $^{111}\text{In}$ -HIgG activity at sites of noninfected inflammation have been reported and occurred in one of our patients with splenic-bed hematoma (8). Two patients with lymphoma had colonic  $^{111}\text{In}$ -HIgG activity but no evidence of lymphoma or of infection in the colon on biopsy. The cause is unknown but has been reported in patients with neutropenia after administration of  $^{111}\text{In}$ -HIgG and  $^{99\text{m}}\text{Tc}$ -HIgG in patients with lymphoma (14) and may be due to protein leakage in the lumen of these patients (15).

The ability to image intrapulmonary infection at 48 hr postinjection, confirmed by significantly increased lung-to-heart ratio of  $^{111}\text{In}$ -HIgG activity, may offer advantages over  $^{67}\text{Ga}$ -citrate where images at 72 hr postinjection may be needed to confirm presence of chest infection (1,14). Furthermore, the estimated radiation burden to patients from  $^{111}\text{In}$ -HIgG is less than that from  $^{67}\text{Ga}$ -citrate (16,17). However, before  $^{111}\text{In}$ -HIgG can replace  $^{67}\text{Ga}$ -citrate as the agent of choice in identifying infection in HIV-positive patients, a more direct comparison of the two agents is required.

This study demonstrates that  $^{111}\text{In}$ -HIgG, which has

proven diagnostic utility in neutropenic patients, can accurately identify infection from a wide range of pathogens within and outside the lungs in HIV-positive patients and patients with AIDS who present with respiratory symptoms or pyrexia of undetermined origin. If subsequent studies confirm these findings,  $^{111}\text{In}$ -HIgG may replace  $^{67}\text{Ga}$ -citrate as the scintigraphic method of choice in these patients.

## REFERENCES

1. Miller RF. Nuclear medicine and AIDS. *Eur J Nucl Med* 1990;16:103-118.
2. Miller RF, Millar AB, Shaw P, Semple SJG. Computed tomographic scans of lungs help to distinguish pneumocystis carinii pneumonia from Kaposi's sarcoma. *Thorax* 1990;45:304.
3. Moskovic E, Miller RF, Pearson M. High resolution computed tomography of pneumocystis carinii pneumonia in AIDS. *Clin Radiology* 1990;42:239-243.
4. Bitran J, Beckerman C, Weinstein R, Bennet C, Ryo U, Pinsky S. Patterns of gallium-67 scintigraphy in patients with acquired immune deficiency syndrome and AIDS related complex. *J Nucl Med* 1987;28:1103-1106.
5. Kramer EL, Sanger JJ, Garay SM, et al. Gallium-67 scans of the chest of patients with acquired immunodeficiency. *J Nucl Med* 1987;28:1107-1114.
6. Lavender JP, Lowe J, Baker JR, Burn JJ, Chaudri MA. Gallium-67 citrate scanning in neoplastic and inflammatory lesions. *Br J Radiology* 1971;44:361-366.
7. Fineman DS, Palestro CJ, Kim CK, et al. Detection of abnormalities in febrile AIDS patients with In-111-labeled leukocyte and Ga-67 scintigraphy. *Radiology* 1989;170:677-780.
8. Rubin RH, Fischman AJ, Callahan RJ, et al.  $^{111}\text{In}$ -labeled non-specific immunoglobulin scanning in the detection of focal infection. *N Engl J Med* 1989;321:935-940.
9. Oyen WJG, Claessens RAMJ, van der Meer JWM, Corstens FHM. Detection of subacute infectious foci with indium-111 autologous leukocytes and indium-111 human nonspecific immunoglobulin G: a prospective comparative study. *J Nucl Med* 1991;32:1854-1860.
10. Buscombe JR, Lui D, Ensing G, de Jong R, Ell PJ.  $^{99\text{m}}\text{Tc}$ -human immunoglobulin (HIgG): first results of a new agent for the localization of infection and inflammation. *Eur J Nucl Med* 1990;16:649-655.
11. Fishman JA, Strauss HW, Fishman AJ, et al. Imaging of pneumocystis carinii infection with  $^{111}\text{In}$ -labelled non-specific polyclonal IgG: an experimental study with rats. *Nucl Med Commun* 1991;12:175-187.
12. Hnatowich DJ, Childs RL, Lanteigne D, Najafi A. The preparation of DTPA coupled radiolabeled with metallic radionuclides: an improved method. *J Immunol Methodology* 1983;65:147-157.
13. Woolfenden JM, Carasquillo JA, Larson SM, et al. Acquired immunodeficiency syndrome: Ga-67 citrate imaging. *Radiology* 1989;179:667-680.
14. Buscombe JR, Miller RF, Lui D, Ell PJ. Combined  $^{67}\text{Ga}$  citrate and  $^{99\text{m}}\text{Tc}$ -human immunoglobulin imaging in human immunodeficiency virus-positive patients with fever of undetermined origin. *Nucl Med Commun* 1991;12:583-592.
15. Oyen WJG, Claessens RAMJ, Raemaekers JMM, De Pauw BE, Van der Meer JWM, Corstens FHM. Diagnosing infection in febrile granulocytopenic patients with indium-111 labeled human immunoglobulin. *J Clin Oncol* 1992;10:61-68.
16. Buijs WCAM, Oyen WJG, Claessens RAMJ, Koenders EB, Meeuwis APW, Corstens FHM. Biodistribution and radiation dosimetry of indium-111 labeled immunoglobulin G [Abstract]. *Eur J Nucl Med* 1990;16:433.
17. Administration of Radioactive Substances Advisory Committee. *Notes on Guidance on the administration of radioactive substances to persons for the purposes of diagnosis and treatment*. London: Department of Health. 1988; 22.