

PDF hosted at the Radboud Repository of the Radboud University Nijmegen

The following full text is a publisher's version.

For additional information about this publication click this link.

<http://hdl.handle.net/2066/14877>

Please be advised that this information was generated on 2017-12-05 and may be subject to change.

trol measures must be maintained and strengthened when sporadic cases are reported. Serological tests proven to be specific and reliable, such as EIA and Western blot, could be useful for investigating outbreaks of anthrax.

References

1. **Brachmann PS:** Anthrax. In: Warren KS, Mahmoud AAF (ed): Tropical and geographical medicine. McGraw Hill, New York, 1990, p. 877-881.
2. **World Health Organization:** Anthrax. Human cutaneous anthrax—a case report. Weekly Epidemiological Record 1991, 34: 254-255.
3. **Whitford HW:** Incidence of anthrax in the USA: 1945-1988. Salisbury Medical Bulletin 1990, 68, Supplement: 5-7.
4. **Turnbull PCB, Stuart FA, Barrett NJ, Melling J:** Anthrax in the UK. Salisbury Medical Bulletin 1990, 68, Supplement: 4-5.
5. **Harrison LH, Ezzell JW, Abshire TG, Kidds S, Kaufmann AF:** Evaluation of serologic tests for diagnosis of anthrax after an outbreak of cutaneous anthrax in Paraguay. Journal of Infectious Diseases 1989, 164: 706-710.
6. **Kleine-Albers C, Honicke E, Bohm R, Pfisterer RM:** The detection of antibodies against the protective antigen of *Bacillus anthracis* in infected persons by enzyme immunoassay. Salisbury Medical Bulletin 1990, 68, Supplement: 75-76.
7. **Sirisanthana T, Nelson KE, Ezzell JW, Abshire TG:** Serological studies of patients with cutaneous and oropharyngeal anthrax from northern Thailand. American Journal of Tropical Medicine and Hygiene 1988, 39: 575-581.
8. **Dogany M, Aydn N:** Antimicrobial susceptibility of *Bacillus anthracis*. Scandinavian Journal of Infectious Diseases 1991, 23: 333-335.
9. **Lightfoot NF, Scott RJD, Turnbull PCB:** Antimicrobial susceptibility of *Bacillus anthracis*. Salisbury Medical Bulletin 1990, 68, Supplement: 95-98.
10. **Kaufmann AF:** Observation on the occurrence of anthrax as related to soil type and rainfall. Salisbury Medical Bulletin 1990, 68, Supplement: 16-17.

Erysipelas-Like Skin Lesions Associated with *Campylobacter jejuni* Septicemia in Patients with Hypogammaglobulinemia

P.J.S.M. Kerstens^{1*}, H.P. Endtz⁵,
J.F.G.M. Meis², W.J.G. Oyen³,
R.J.I. Koopman⁴, P.J. van den Broek⁶,
J.W.M. van der Meer¹

Three cases are reported of hypogammaglobulinemic males with recurrent *Campylobacter jejuni* septicemia and erysipelas-like cellulitis without diarrhoea. In one patient *Campylobacter jejuni* grew from skin biopsy specimens. The findings in another patient were strongly suggestive of osteomyelitis caused by *Campylobacter jejuni*. Since the susceptibility of hypogammaglobulinemic patients to infection with *Campylobacter jejuni* is probably related to a lack of serum bactericidal activity against *Campylobacter jejuni* due to lack of IgM, two patients in whom previous antimicrobial treatment failed were treated with plasma infusions. This regimen supplemented with imipenem resulted in cure of these relapsing infections. *Campylobacter jejuni* septicemia must be considered in hypogammaglobulinemic patients who present with periodic fever and cellulitis.

Campylobacter jejuni subspecies *jejuni* (*Campylobacter jejuni*) is a common cause of gastroenteritis (1), which is a self-limiting disease in most patients. However, *Campylobacter jejuni* can induce protracted diarrhoea (2, 3) and a prolonged carrier state (4, 5) in patients with hypogammaglobulinemia. Recurrent septicemia due to *Campylobacter jejuni* has also been reported in these patients (6-9). Until now only three cases of cellulitis during a period of septicemia with *Campylobacter jejuni* have been

¹Department of General Internal Medicine, ²Department of Medical Microbiology, ³Department of Nuclear Medicine, and ⁴Department of Dermatology, University Hospital Nijmegen, PO Box 9101, 6500 HB Nijmegen, The Netherlands.

⁵Department of Medical Microbiology, and ⁶Department of Infectious Diseases, University Hospital Leiden, The Netherlands.

reported (9, 10). Attempts to isolate *Campylobacter jejuni* from the skin lesions were unsuccessful (9).

We report on three cases of hypogammaglobulinemic males with recurrent *Campylobacter jejuni* septicemia and erysipelas-like skin lesions.

Case Reports. *Patient A*, a 26-year-old male with X-linked hypogammaglobulinemia (Table 1) treated with subcutaneous gammaglobulin substitution (50 mg/kg/week) (16), was admitted to hospital in August 1989 with fever and cellulitis of his right hand. At the age of eight years he had developed lymphoedema of his right hand for which no explanation was found. Over the past eight years he had suffered from recurrent skin lesions on his legs and right hand which were diagnosed as erysipelas. There was no clear response to treatment with penicillin, flucloxacillin, ampicillin and cephalosporins.

During a camping trip shortly before admission he became febrile, started coughing and developed skin lesions on his right hand. On physical examination a tender, warm, ill-defined area of erythema was seen on the back of the right hand. The chest x-ray showed a pulmonary infiltrate of the left lower lobe and sputum cultures grew *Haemophilus influenzae*. Administration of amoxicillin intravenously (4 x 1 g) and immunoglobulin G intravenously (6 g) resulted in rapid resolution of the pulmonary infection, but low grade fever persisted. The skin lesion extended and became more indurated (Figure 1). Because of the phlegmonous appearance, flucloxacillin was given without success. During antibiotic treatment, similar skin lesions appeared on the patient's shins. In the meantime cultures of blood and stool specimens obtained at admission grew *Campylobacter jejuni* biotype I, serogroup LAU 15. Biopsy specimens of affected skin were taken at the margin of the lesions on both the right hand and leg and processed directly for routine histopathological examination, electron microscopy and culture. The cultures yielded *Campylobacter jejuni* biotype I, serogroup LAU 15. The strains isolated from the skin biopsies were susceptible to erythromycin (MIC < 1 mg/l), and those isolated from stools were erythromycin resistant (MIC > 64 mg/l), whereas one of the two strains isolated from blood cultures was erythromycin susceptible, the other being resistant. All strains were resistant to ciprofloxacin (MIC > 16 mg/l). Histopathological studies, including silver-staining, of the skin biopsies revealed no microor-

ganisms, but electron microscopy showed deep dermal inflammation with fibrin deposits and few bacteria. Erythromycin given orally in a dosage of 2 g daily had no effect on either the fever or skin lesions. When intravenous gentamicin (5 mg/kg per day) was added to the regimen, both fever and skin lesions rapidly disappeared. However, within two weeks after cessation of treatment similar new skin lesions developed on the lower legs accompanied by low grade fever. Again stool and blood cultures grew *Campylobacter jejuni* of the same type; all strains were erythromycin and ciprofloxacin resistant. Cultures of skin biopsies remained sterile this time. On questioning and physical examination as well as on scintigraphy with indium-111 labelled human polyclonal non-specific immunoglobulin G (In-111-IgG) (17-19), no evidence of focal infection could be found. Treatment was given with imipenem administered intravenously (4 x 500 mg) and plasma infusions (500 ml twice weekly) for two weeks. This regimen resulted in rapid resolution of skin lesions and fever. Over a follow-up period of more than 2.5 years all stool cultures remained negative for *Campylobacter jejuni*, and neither skin lesions nor fever recurred.

Patient B, a 20-year-old hypogammaglobulinemic male (Table 1), experienced septicemia caused by *Campylobacter jejuni* biotype II, serogroup LAU 5/15 in 1986, which relapsed after therapy with erythromycin but responded to ciprofloxacin. In November 1989 he presented with an erysipelas-like skin lesion on his left leg and fever, which did not respond to penicillin. Blood and stool cultures grew *Campylobacter jejuni* biotype II, serogroup LAU 5/15. Initially, a response to therapy with erythromycin was recorded, but shortly after cessation of therapy relapse of the septicemia was seen. Skin lesions did not recur. A six-week course of erythromycin was given and the patient recovered. More than one year later there were no signs of *Campylobacter jejuni* infection having recurred.

Patient C, a 24-year-old male with X-linked hypogammaglobulinemia and chronic hepatitis with mild cirrhosis due to hepatitis B virus, suffered recurrent bouts of fever over a period of several years. The fever episodes were originally attributed to respiratory tract infections. Gammaglobulin substitution was given by slow subcutaneous infusions (16), resulting in satisfactory serum IgG concentrations (Table 1). In August 1985 he presented with fever and an erysipelas-like skin lesion on his left lower leg, which had not responded to amoxicillin and flucloxacillin.

Table 1: Serum immunoglobulin levels in three patients with hypogammaglobulinemia suffering from recurrent systemic *Campylobacter jejuni* infections before and during plasma infusion therapy.

	Immunoglobulin levels (g/l) ^a		
	Patient A	Patient B ^b	Patient C
Before treatment			
IgA	undetectable	undetectable	undetectable
IgG	4.18	4.60	4.60
IgM	undetectable	undetectable	undetectable
During treatment			
IgA	0.56		0.42
IgG	5.08		2.91
IgM	0.48		undetectable

^a Normal values \pm SD: IgA: 2.0 ± 0.6 g/l; IgG: 12.5 ± 2.1 g/l; IgM: 1.1 ± 0.4 g/l.

^b Patient B was not treated with imipenem and plasma infusions (see text).

Blood and stool cultures yielded *Campylobacter jejuni* biotype III, serogroup LAU 3, and treatment with erythromycin resulted in rapid resolution of both fever and skin lesions. Stool cultures became negative for *Campylobacter jejuni*. One year later a similar skin lesion occurred on the patient's left lower leg. Although he was afebrile, blood cultures again yielded *Campylobacter jejuni* biotype III, serogroup LAU 3. The patient responded to oral erythromycin in a dosage of 2 g daily. In February 1990 he developed bouts of fever again, and somewhat looser stools than normal. The frequency of fever episodes increased from once weekly to every other day in March 1990. Fever was self-limiting and preceded by chills and rigors. During fever periods he also experienced pain in the lower legs, predominantly on the right side. No skin lesions occurred during this episode. Again blood and stool cultures grew *Campylobacter jejuni* biotype III, serogroup LAU 3 which was sensitive to erythromycin (MIC < 0.5 mg/l), ciprofloxacin (MIC < 0.25 mg/l) and imipenem (MIC < 0.125 mg/l). A seven-day course of erythromycin (2 g) given orally caused no relief of symptoms. On physical examination no infectious focus was detected. However, In-111-IgG scintigraphy (17–19) showed increased uptake in the proximal tibia of the right leg and, to a lesser extent, in the proximal tibia of the left leg. On technetium-99m-methylene diphosphonate (Tc-99m-MDP) scintigraphy areas of increased uptake were seen at the corresponding sites. Neither plain radiographs nor CT scans of the lower legs showed abnormalities. No specimens were taken for repeat cultures before treatment with intravenous imipenem (4 x 500 mg) and plasma infusions (500 ml twice weekly) were started.

Within a few days after starting treatment fever subsided and the patient's condition improved. Pain in the lower legs did not recur. Plasma infusions were given for four weeks, and imipenem was continued for a total of six weeks. At the end of that time a follow-up In-111-IgG scintigraphy was negative. Treatment was subsequently stopped. *Campylobacter jejuni* infection did not recur, and repeated cultures remained negative, despite the fact that the patient underwent cancer chemotherapy 1.5 years later due to carcinoma of the colon with metastases. He died in December 1991. No autopsy was performed.

Methods. All strains isolated from blood were grown on blood agar plates containing sheep blood at 37 °C in an atmosphere of 5 % O₂, 10 % CO₂ and 85 % N₂. The strains from stool specimens were isolated on blood agar plates with Skirrow's supplement (11). The skin biopsy specimen was cut in half and both cut edges were streaked on blood and campylobacter agar plates; the remainder of the specimen was inoculated into brain heart infusion broth supplemented with horse serum, V factor and defibrinated sheep blood. Cultures were incubated for two days at 37 °C and 42 °C under microaerobic conditions of 5 % O₂, 10 % CO₂ and 85 % N₂.

All *Campylobacter jejuni* cultures showed abundant growth at 42 °C but not at 25 °C. They were catalase and oxidase positive and resistant to cephalothin. Hippurate hydrolysis, DNA hydrolysis and a rapid H₂S test were performed according to Lior and Patel (12, 13). The biotypes and serotypes were determined as described previously (12, 14).

Antimicrobial susceptibility patterns were determined by an agar dilution method (15). Strains were tested in Mueller-Hinton agar supplemented with 5 % lysed horse blood and incubated for 48 hours in an atmosphere of 5 % O₂, 10 % CO₂ and 85 % N₂.

Discussion. In this paper three hypogammaglobulinemic males with recurrent *Campylobacter jejuni* septicemia and cellulitis are described. None of the patients complained of diarrhoea related to the episodes of *Campylobacter jejuni* septicemia. Fever was usually present during septicemia, varying between self-limiting bouts and persistent low grade fever type. In patient C an afebrile episode of bacteremia was recorded.

The incidence of *Campylobacter jejuni* septicemia in hypogammaglobulinemic patients is probably underestimated. In a review of infections in 96 hypogammaglobulinemic patients, *Campylobacter* septicemia was reported to have occurred only once (20). In this case *Campylobacter fetus* was probably the causative organism (21). However, among 41 hypogammaglobu-

linemic patients under the care of our team, five patients have experienced at least one episode of documented *Campylobacter jejuni* septicemia.

Skin lesions due to *Campylobacter jejuni* have been reported before (9, 10). However, an attempt to isolate *Campylobacter jejuni* from a skin aspirate was unsuccessful (9). In patient A we cultured *Campylobacter jejuni* from biopsy specimens, and bacteria were seen on electron microscopy. These observations strongly suggest metastatic cellulitis, although microaspiration of blood with the biopsy cannot be fully excluded. Since our morphological findings indicated that the number of *Campylobacter jejuni* in these skin lesions was low, the pathogenesis may also have been toxin-mediated.

The association of fever, pain localized to the lower legs, scintigraphy findings and *Campylobacter jejuni* septicemia in one patient suggests that this microorganism may cause osteomyelitis. The rapid response of the patient to treatment directed against *Campylobacter jejuni*, including normalisation of the findings on In-111-IgG scintigraphy, which in our experience is a sensitive and specific method for detection of bone inflammation (18, 19), is in accordance with this. Because of the rapid response to therapy no biopsy was performed to confirm the diagnosis of osteomyelitis. To the best of our knowledge osteomyelitis probably caused by *Campylobacter jejuni* has been reported only once before (22). In that case report no mention was made of serum immunoglobulin concentrations.

The results of typing of *Campylobacter jejuni* isolates in our patients indicate endogenous relapses rather than exogenous reinfections. It would appear to be difficult to eradicate *Campylobacter jejuni* in hypogammaglobulinemic patients. The susceptibility of hypogammaglobulinemic patients to infection with *Campylobacter jejuni* is probably related to a lack of bactericidal activity of hypogammaglobulinemic serum against *Campylobacter jejuni* (6, 7, 23, 24), which is not restored by administration of IgG preparations (7, 24). The importance of humoral immunity in the response to *Campylobacter jejuni* infections has also been recognised in patients with AIDS presenting with persistent *Campylobacter jejuni* septicemia (25). The results of in vitro studies strongly suggest that serum sensitivity of *Campylobacter jejuni* is complement and IgM dependent (23). Previously we have found that plasma substitution therapy restores the bactericidal activity, indicating a role of IgM (24). We decided to

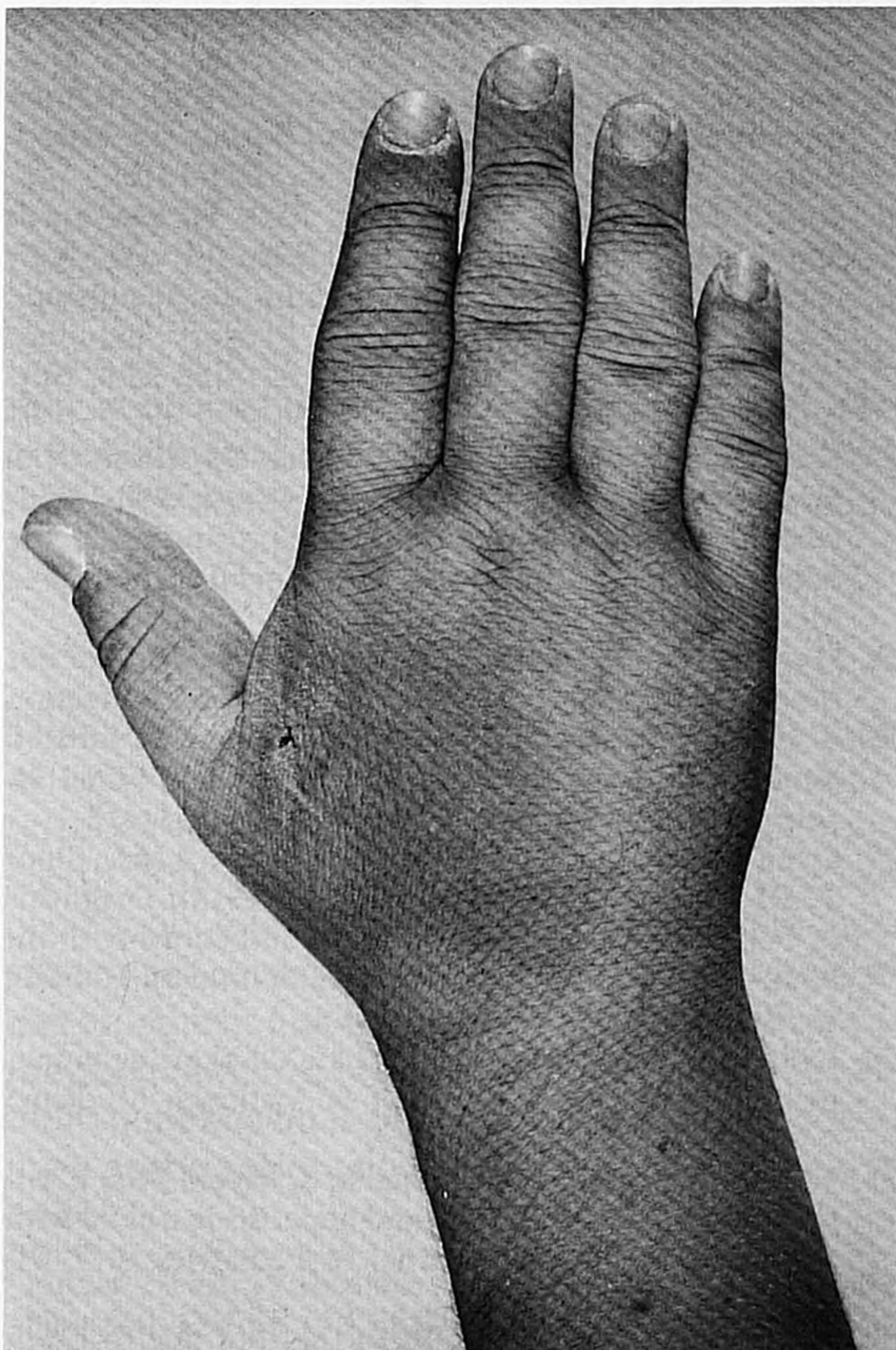


Figure 1: Skin lesion on the right hand of patient A.

treat patients A and C with plasma infusions. A rise in the IgM level was noted in patient A (Table 1); neither before nor during plasma infusion therapy were detectable levels of IgM found in patient C (Table 1). A high rate of IgM turnover at the infectious foci in this patient could explain this observation.

Imipenem was chosen for therapy in patients A and C for several reasons. In patient A we had seen failure of erythromycin which may have been caused by rapid development of resistance. Development of ciprofloxacin resistance in *Campylobacter jejuni* has also been reported (24, 26). Furthermore, treatment with imipenem, to which *Campylobacter jejuni* is highly sensitive (MIC 90 < 0.125 mg/l), and plasma was the only treatment which was successful in a previously reported patient who suffered from a longstanding *Campylobacter jejuni* infection (24). Several treatment attempts had failed in that patient but after treatment with imipenem and plasma the patient has been free of *Campylobacter jejuni* for more than four years now. Although the follow-up period in patients A and C is rather short, their rapid and good response to treatment with imipenem and plasma infusions emphasises the value of this regimen when previous antibiotic treatment is without success.

We conclude that the diagnosis of *Campylobacter jejuni* septicemia should be considered in hypogammaglobulinemic patients with recurrent fever, especially when erysipelas-like skin lesions occur. In patients not rapidly responding to erythromycin, combination therapy with imipenem and plasma infusions should be considered in view of the success of this therapy in our patients.

References

1. **Blaser MJ, Reller LB:** *Campylobacter enteritis*. New England Journal of Medicine 1981, 305: 1444–1452.
2. **Ahnen DJ, Brown WR:** *Campylobacter enteritis* in immunodeficient patients. Annals of Internal Medicine 1982, 96: 187–189.
3. **Pönkä A, Tilvis R, Kosunen TU:** Prolonged *Campylobacter gastroenteritis* in a patient with hypogammaglobulinaemia. Acta Medica Scandinavica 1983, 213: 159–160.
4. **Lever AML, Dolby JM, Webster ADB, Price AB:** Chronic *Campylobacter colitis* and uveitis in a patient with hypogammaglobulinaemia. British Medical Journal 1984, 288: 531.
5. **Melamed I, Bujanover U, Igra YS, Schwartz D, Zakerth V, Spierer Z:** *Campylobacter enteritis* in normal and immunodeficient children. American Journal of Diseases of Children 1983, 137: 752–753.
6. **Johnson RJ, Nolan C, Wang SP, Shelton WR, Blaser MJ:** Persistent *Campylobacter jejuni* infection in an immunocompromised patient. Annals of Internal Medicine 1984, 100: 832–834.
7. **van der Meer JWM, Mouton RP, Daha MR, Schuurman RKB:** *Campylobacter jejuni* bacteraemia as a cause of recurrent fever in a patient with hypogammaglobulinaemia. Journal of Infection 1986, 12: 235–239.
8. **Chusid MJ, Coleman CM, Dunne MW:** Chronic asymptomatic *Campylobacter bacteraemia* in a boy with X-linked hypogammaglobulinaemia. Pediatric Infectious Disease Journal 1987, 6: 943–944.
9. **Spelman DW, Davidson N, Buckmaster ND, Spicer WI, Ryan P:** *Campylobacter bacteraemia*: a report of 10 cases. Medical Journal of Australia 1986, 145: 503–505.
10. **LeBar WD, Menard RR, Check FE:** Hypogammaglobulinemia and recurrent *Campylobacter jejuni* infection. Journal of Infectious Disease 1985, 152: 1099–1100.
11. **Skirrow MB:** *Campylobacter enteritis*. A "new" disease. British Medical Journal 1977, ii: 9–11.
12. **Lior H:** New, extended biotyping scheme for *Campylobacter jejuni*, *Campylobacter coli* and *Campylobacter lariidis*. Journal of Clinical Microbiology 1984, 20: 636–640.
13. **Lior H, Patel A:** Improved toluidine blue-DNA agar for detection of DNA hydrolysis by *Campylobacters*. Journal of Clinical Microbiology 1987, 25: 2030–2031.
14. **Lauwers S, Vlaes L, Butzler JP:** *Campylobacter* serotyping and epidemiology. Lancet 1981, i: 158–159.
15. **Sahm DF, Washington JA:** Antibacterial susceptibility tests: dilution methods. In: Balow A, Hausler WJ, Hermann KL, Isenberg HD, Shadomy HJ (ed): Manual of clinical microbiology. American Society for Microbiology, Washington, DC, 1991, p. 1105–1116.
16. **Roord JJ, van der Meer JWM, Kuis W, van Furth R:** Treatment of antibody deficiency with subcutaneous infusion of gammaglobulin. In: Wedgwood RJ, Rosen FS, Paul NW (ed): Primary immunodeficiency diseases. Birth defects. Alan R. Liss, New York, 1983, p. 217–221.
17. **Rubin RH, Fischman AJ, Callahan RJ, Khaw BA, Keech F, Ahmad M, Wilkinson R, Strauss HW:** 111In-labeled nonspecific immunoglobulin scanning in the detection of focal infection. New England Journal of Medicine 1989, 321: 935–940.
18. **Oyen WJG, Claessens RAMJ, van Horn JR, van der Meer JWM, Corstens FHM:** Scintigraphic detection of bone and joint infections with indium-111 labeled nonspecific polyclonal human immunoglobulin G. Journal of Nuclear Medicine 1990, 31: 403–412.
19. **Oyen WJG, van Horn JR, Claessens AMJ, Sloof TJJH, van der Meer JWM, Corstens FHM:** Diagnosis of bone, joint and joint prosthesis infections with indium-111 labeled nonspecific human immunoglobulin G. Radiology 1992, 182: 195–199.
20. **Lederman HM, Winkelstein JA:** X-linked agammaglobulinaemia: an analysis of 96 patients. Medicine 1985, 64: 145–156.
21. **Wyatt RA, Younoszai K, Anuras S, Myers MG:** *Campylobacter fetus* septicemia and hepatitis in a child with agammaglobulinemia. Journal of Pediatrics 1977, 91: 441–442.
22. **Pedler SJ, Bint AJ:** Osteitis of the foot due to *Campylobacter jejuni*. Journal of Infection 1984, 8: 84–85.

23. Blaser MJ, Smith PF, Kohler PF: Susceptibility of *Campylobacter* isolates to the bactericidal activity of human serum. *Journal of Infectious Diseases* 1985, 151: 227-235.
24. Endtz HP, van der Meer JWM, Mouton RP: *Campylobacter jejuni* bacteraemia in hypogammaglobulinaemia: emergence of ciprofloxacin resistance and results of serum bactericidal assays. In: Kaijser B, Falsen E (ed): *Proceedings of the Fourth International Workshop on Campylobacter Infections*. University of Göteborg, Kungälv, Sweden, 1988, p. 150-151.
25. Perlman DM, Ampel NM, Schiffman RB, Cohn DL, Patton CM, Aguirre ML, Wang WL, Blaser MJ: Persistent *Campylobacter jejuni* infections in patients infected with human immunodeficiency virus (HIV). *Annals of Internal Medicine* 1988, 108: 540-546.
26. Endtz HP, Mouton RP, van der Reyden T, Ruijs GJ, Biever M, van Klingerden B: Fluoroquinolone resistance in *Campylobacter* spp. isolated from human stools and poultry products. *Lancet* 1990, 335: 787.

Prosthetic Joint Infection due to *Candida parapsilosis* in the UK: Case Report and Literature Review

J. Paul¹, S.H. White², K.M. Nicholls¹,
D.W. Crook^{1*}

Candida infection of joint replacements is a rare but increasingly reported phenomenon. A case of *Candida parapsilosis* prosthetic knee joint infection occurring in the UK is described. Cure followed removal of the prosthesis and treatment, first with a combination of amphotericin and 5-fluorocytosine, then ketoconazole.

The overwhelming majority of cases of infection of total joint arthroplasties are ascribed to bacterial pathogens (1). However, there is a growing North American literature referring to cases of prosthetic joint candidosis. A favourable outcome of these infections is seen after removal of the prosthesis and administration of specific anti-fungal treatment. However, such successful treatment depends on isolating *Candida* and recognising it as the aetiologic agent. We describe a case in

the UK of infection of a total knee arthroplasty with *Candida parapsilosis* where our culture-based diagnosis was supported by histological and serological evidence, and where serial serological tests for candida allowed monitoring of the therapeutic response. The literature on candida joint infection, its diagnosis and treatment is reviewed.

Case Report. A 63-year-old man underwent a bicompartamental Oxford knee replacement for severe osteoarthritis. Continued pain led to revision to an Insall Burstein total condylar replacement 20 months later. Loosening of the prosthesis but no evidence of infection was noted at the time of the revision. Three months after revision, the joint became hot and red suggesting infection. Exploration showed inflamed granulations, but routine microbiological cultures were negative. Four months later persistent pain resulted in removal of all foreign material and the knee was fused using compressive biplanar external fixation. Tissue was taken for histological and microbiological investigation.

Culture of debrided cancellous bone, joint capsule and periarticular tissue revealed *Candida parapsilosis* in pure growth. Histological examination of debrided bone showed yeasts and chronic, non-specific inflammatory changes. Sera taken 8 and 105 days before the time of removal of the prosthesis were sent to the Central Public Health Laboratory, London, UK, to test for the presence of candidal precipitins and agglutinins. The results proved to be highly supportive of a diagnosis of infection with *Candida parapsilosis*. A culture of the organism sent to the Central Public Health Laboratory, London, was found to be sensitive to amphotericin, 5-fluorocytosine and ketoconazole and the identification was confirmed as *Candida parapsilosis*. One week after removal of the prosthesis, treatment with intravenous amphotericin, 50 mg daily, and 5-fluorocytosine, 2500 mg 6-hourly, was started. This regimen was well tolerated and continued for 40 days, and was followed by treatment for 24 days with ketoconazole, 200 mg 12-hourly. The knee became painless and results of serial serological tests for candida indicated a therapeutic response. At follow-up two years after removal of the prosthesis, the patient's fused knee was trouble-free and serological tests for candida were negative.

Discussion. Fourteen cases of prosthetic joint candidosis including our own case have been reported in the world literature. Apart from the

¹Public Health Laboratory, Levels 6/7, John Radcliffe Hospital, Oxford OX3 9DU, UK.

²Nuffield Orthopaedic Centre, Windmill Road, Headington, Oxford OX3 7LD, UK.