

## PDF hosted at the Radboud Repository of the Radboud University Nijmegen

This full text is a publisher's version.

For additional information about this publication click this link.

<http://hdl.handle.net/2066/14857>

Please be advised that this information was generated on 2014-11-11 and may be subject to change.

## REVIEW ARTICLES

## Tuberculosis Cutis Miliaris Disseminata as a Manifestation of Miliary Tuberculosis: Literature Review and Report of a Case of Recurrent Skin Lesions

R. C. Rietbroek, R. P. M. Dahlmans, F. Smedts,  
P. J. Frantzen, R. J. J. Koopman,  
and J. W. M. van der Meer

*From the Departments of Medicine, Pathology, and Dermatology, Division of General Internal Medicine, University Hospital Nijmegen, Nijmegen; and the Asthma Centre and Clinic for Chronic Respiratory Diseases, Hornerheide, Horn, The Netherlands*

The development of severe adverse reactions to antituberculous drugs in a patient with miliary tuberculosis led to unorthodox, suboptimal antituberculous therapy. The patient's failure to respond to therapy was discovered when acid-fast bacilli were detected in new skin lesions. Such lesions have been described in the literature as tuberculosis cutis miliaris disseminata; 24 cases (in addition to that described herein) have been reported thus far. The patient eventually recovered completely after detection and drainage of a large retrofascial tuberculous abscess. This case illustrates the importance of careful examination of the skin in clinical medicine, as tuberculosis cutis miliaris disseminata is an easily overlooked sign of miliary tuberculosis.

We recently treated a patient in whom severe adverse reactions to antituberculous drugs led to unorthodox, suboptimal antituberculous therapy. The failure of therapy was discovered when acid-fast bacilli were detected in new skin lesions. Such lesions, which are a rare manifestation of miliary tuberculosis [1], have been described in the literature as tuberculosis cutis miliaris disseminata. This form of disease is usually associated with a poor prognosis and was seen more often before antituberculous drugs became available [1].

### Case Report

A 64-year-old woman had had systemic sclerosis and polymyositis since 1985, for which she received prednisone (25 mg/d) and azathioprine (150 mg/d). In July 1988 she had been admitted to another hospital with high fever, rigors, and fatigue. She had no history of dyspnea or tuberculosis. On physical examination she was found to be ill, with no abnormalities except acrosclerosis.

Laboratory investigation revealed an erythrocyte sedimentation rate of 46 mm (Westergren; normal rate, <12 mm after 1 hour) and normal hepatic and renal function. Radiography of the chest showed diffuse reticulonodular infiltrates in both lungs. The reaction to purified protein derivative (PPD, 10 U

given intracutaneously) was negative. Bronchoalveolar lavage yielded acid-fast bacilli.

The diagnosis of miliary tuberculosis was made. Therapy was started with rifampin, pyrazinamide, isoniazid, and pyridoxine. On day 10 the administration of these drugs was stopped because of disturbances of hepatic function. The level of serum aminotransferases was more than four times the normal value. Treatment with ethambutol and streptomycin was started. On day 15 flucloxacillin and gentamicin were administered because of blood cultures positive for *Staphylococcus aureus*; these findings were related to the presence of an intravenous catheter. Three days later gentamicin treatment was stopped, and, because of persistent fever, ceftazidime and amikacin were added to the regimen. In retrospect, it is clear that the attending physician paid too little attention to the cumulative toxicity of the aminoglycosides used during this period.

On day 17 the patient developed disseminated erythematous macules and papules (diameter, 5–10 mm) on her legs, arms, and trunk. There were more lesions on the lower half of the body. A skin biopsy showed a deep dermal infiltrate composed of granulocytes and lymphocytes intermingled with histiocytes and a protein-rich exudate. Ziehl-Neelsen staining revealed dispersed acid-fast bacilli. No caseation necrosis or vasculitis was present, and there were no tuberculous granulomas. Biopsied skin tissue was not cultured.

A subsequent bone marrow biopsy showed a granulomatous inflammation. However, no caseation necrosis or vasculitis was evident, and Ziehl-Neelsen staining gave negative results. Cultures of urine and feces were negative. Because of the skin lesions, therapy with isoniazid was restarted at a dose of 300 mg/d.

Three days later the patient's level of consciousness declined

Received 8 February 1990; revised 21 May 1990.

Reprints and correspondence: Dr. R. C. Rietbroek, Department of Medicine, Division of General Internal Medicine, University Hospital Nijmegen, Postbox 9101, 6500 HB Nijmegen, The Netherlands.

Reviews of Infectious Diseases 1991;13:265-9

© 1991 by The University of Chicago. All rights reserved.  
0162-0886/91/1302-0011\$02.00

progressively. Results of cerebral computed tomography and lumbar puncture were within normal ranges, and electroencephalography yielded findings consistent with a metabolic encephalopathy. Renal insufficiency was diagnosed (estimated creatinine clearance rate, 6 mL/min), and amikacin treatment was stopped.

On day 28 the still-comatose patient was admitted to our ward. Because isoniazid was considered to be the most likely cause of the coma, all medication except prednisone (25 mg/d) was stopped. Pyridoxine (125 mg) was given intravenously. Over the course of several days, the patient regained consciousness; on day 33 therapy with rifampin, ethambutol, and streptomycin was recommenced, with doses adjusted to renal function. When it became apparent that there was a hearing loss consistent with aminoglycoside toxicity, streptomycin treatment was stopped.

Culture of bronchoalveolar lavage fluid yielded a strain of *Mycobacterium tuberculosis* sensitive to all antituberculous drugs.

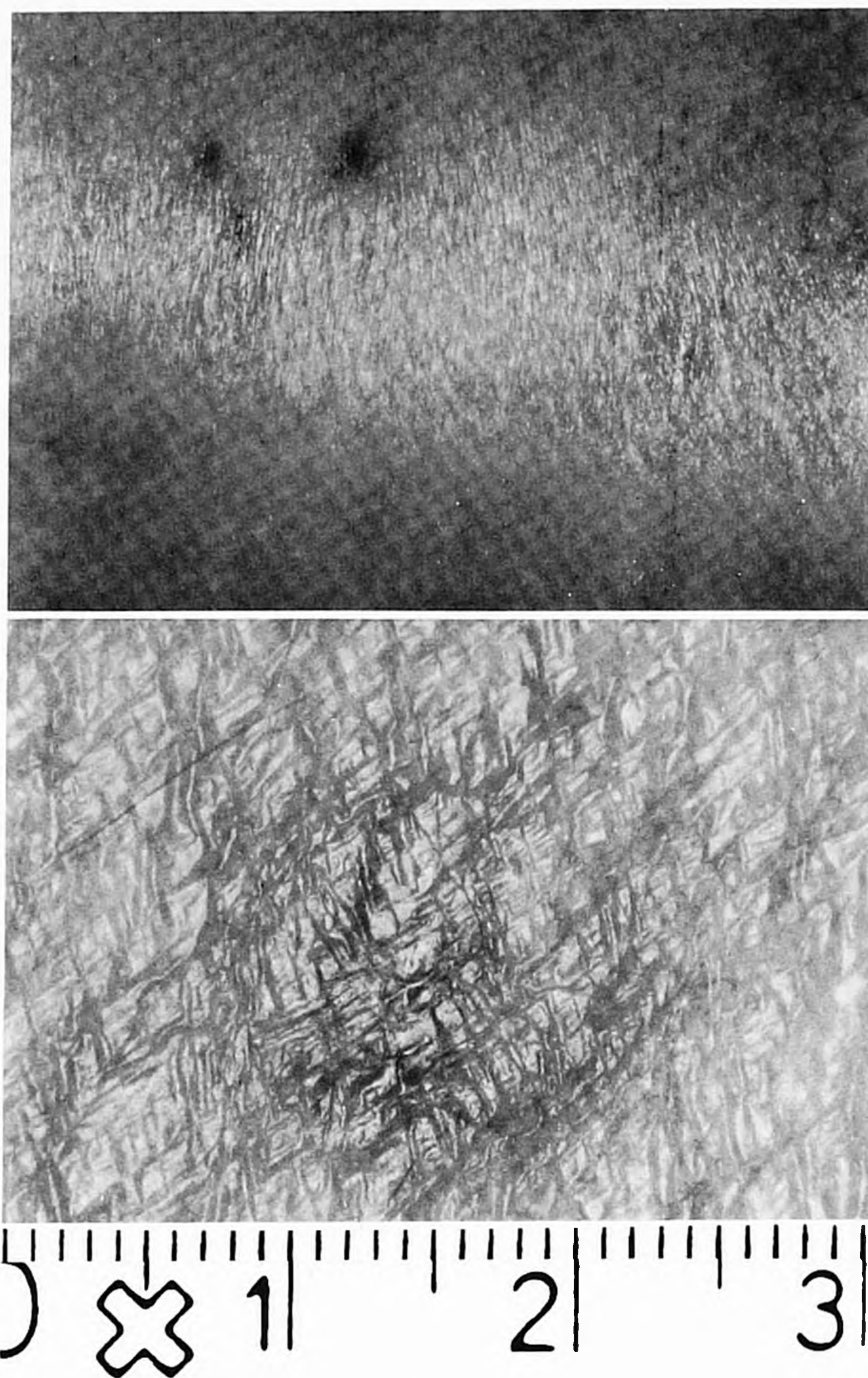
Although the chest radiograph clearly improved and the skin lesions gradually disappeared, the patient remained febrile. For this reason a third antituberculous drug was thought to be necessary, and ciprofloxacin was given in a dose of 500 mg/d.

On day 70 a small group of erythematous and purpuric papules (5–10 mm in diameter) appeared on the upper part of both thighs (figure 1). A careful examination of the skin revealed no other lesions. Biopsies yielded results the same as those obtained initially; panniculitis without granulomas and with many tubercle bacilli was noted (figure 2). The culture of the biopsy specimen remained negative. Because of these findings, isoniazid (300 mg every 48 hours) was restarted; 3 weeks later, when renal function had improved, the drug was given once a day. Ethambutol administration was stopped.

On day 124 the patient was transferred to a clinic for chronic respiratory diseases. Her medication at this point consisted of prednisone, isoniazid, rifampin, and ciprofloxacin. The chest radiograph was almost normal, and the skin lesions were regressing. The remaining problem was fever (maximum, 39.7°C) that occurred at irregular intervals (approximately two or three times a week).

Because of the possibility of drug fever, the use of isoniazid and rifampin was stopped for several days, but this change had no apparent effect. The only new sign during this period was a nonhealing ulcer—thought to be decubital—on the left buttock. Nevertheless, skin obtained at biopsy of this lesion on day 132 showed a dermal granulomatous inflammation with acid-fast bacilli. A culture was negative. Therapy remained unchanged; on day 157, after 3 months, ciprofloxacin treatment was stopped.

Beginning on day 163, the patient complained of pain in the left popliteal fossa. She gradually developed a swelling there, which expanded when she was standing and disappeared when she was lying down. The swelling was not warm or red.



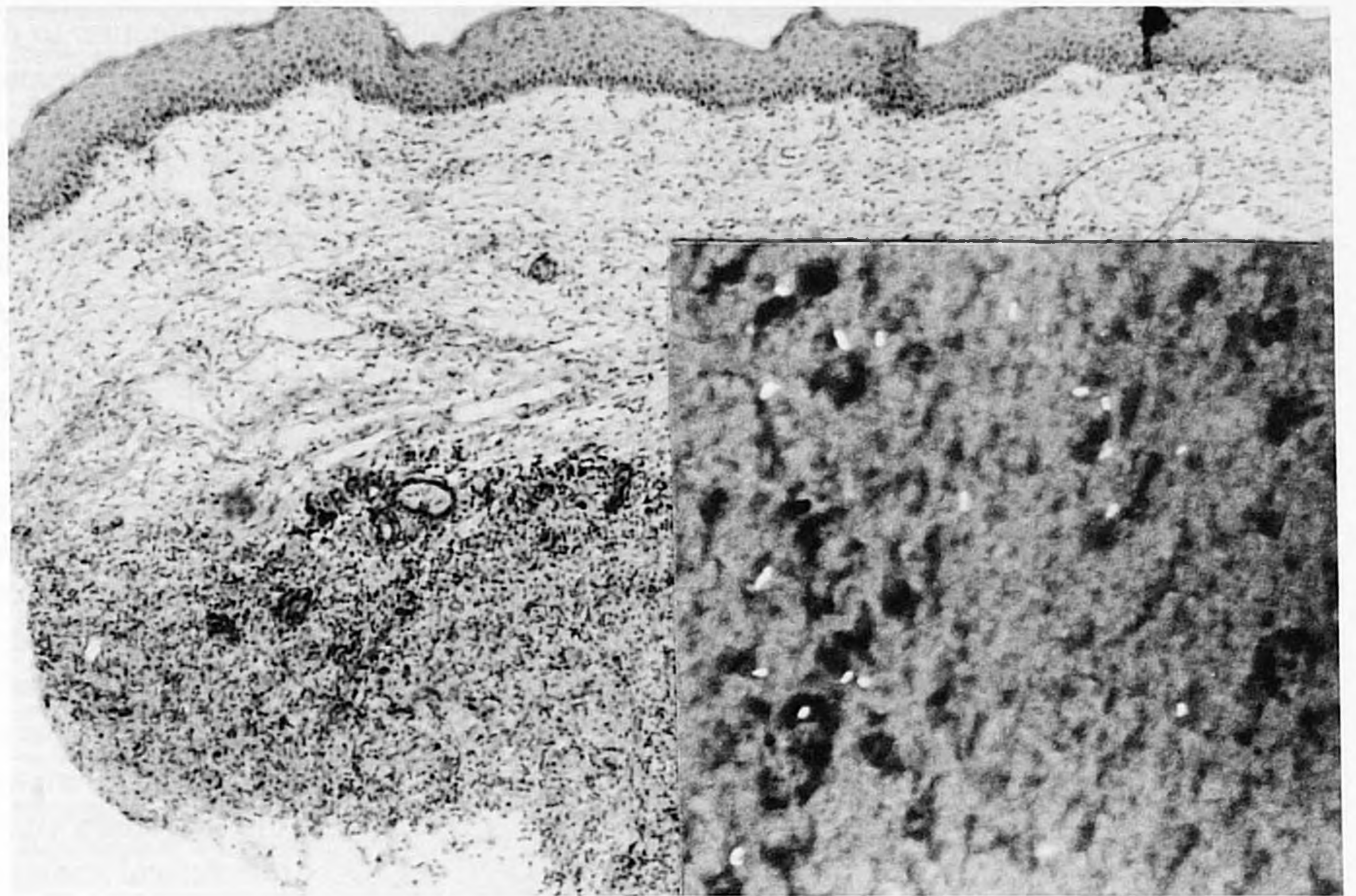
**Figure 1.** *Top:* Erythematous and purpuric papules on right upper thigh, a manifestation of tuberculosis cutis miliaris disseminata. *Bottom:* Detail of papule, with size in centimeters.

Radiography of the legs and pelvis showed no signs of osteomyelitis. Computed tomography on day 197 showed a large retrofascial abscess originating in the gluteal muscles and descending along the musculus biceps femoris to the left popliteal fossa (figure 3). There were no abscesses in the abdomen or retroperitoneum. No osseous destruction was seen. It could not be ascertained whether previous intramuscular injections of streptomycin had contributed to the formation of this cold abscess.

On day 202 the abscess was incised, yielding 1,400 mL of debris with acid-fast bacilli. Cultures remained negative, including those for aerobic and anaerobic bacilli. Ethambutol (800 mg/d) was added to the regimen on day 204. After incision of the abscess, the fever disappeared.

On day 246 the patient was discharged in good condition without skin lesions. Her medication at discharge consisted of rifampin, isoniazid, ethambutol, pyridoxine, and prednisone.

**Figure 2.** Punch biopsy specimen from a skin lesion. The epidermis is intact. In the deeper dermis, there is an infiltrate of granulocytes and lymphocytes intermingled with histiocytes and protein-rich exudate (hematoxylin and eosin; magnification,  $\times 25$ ). *Inset:* Many fluorescent tubercle bacilli can be seen (auramine stain, fluorescent technique; magnification,  $\times 100$ ).



## Discussion

In the case of miliary tuberculosis reported herein, skin manifestations typical of tuberculosis cutis miliaris disseminata were seen. As described in the literature and observed in this case, these lesions are discrete, dull, erythematous macules and papules that are initially the size of a pinhead. They may become capped by tiny vesicles that, after rupturing, leave papules with a central crust. Removal of this crust reveals a minute but sharply defined umbilication or dell. In this case no vesicles were observed. The lesions are most frequently localized on thighs, buttocks, genitalia, and extremities. Their number is usually no more than 20–30. Pustules and nodules have also been described in some instances [1–3].

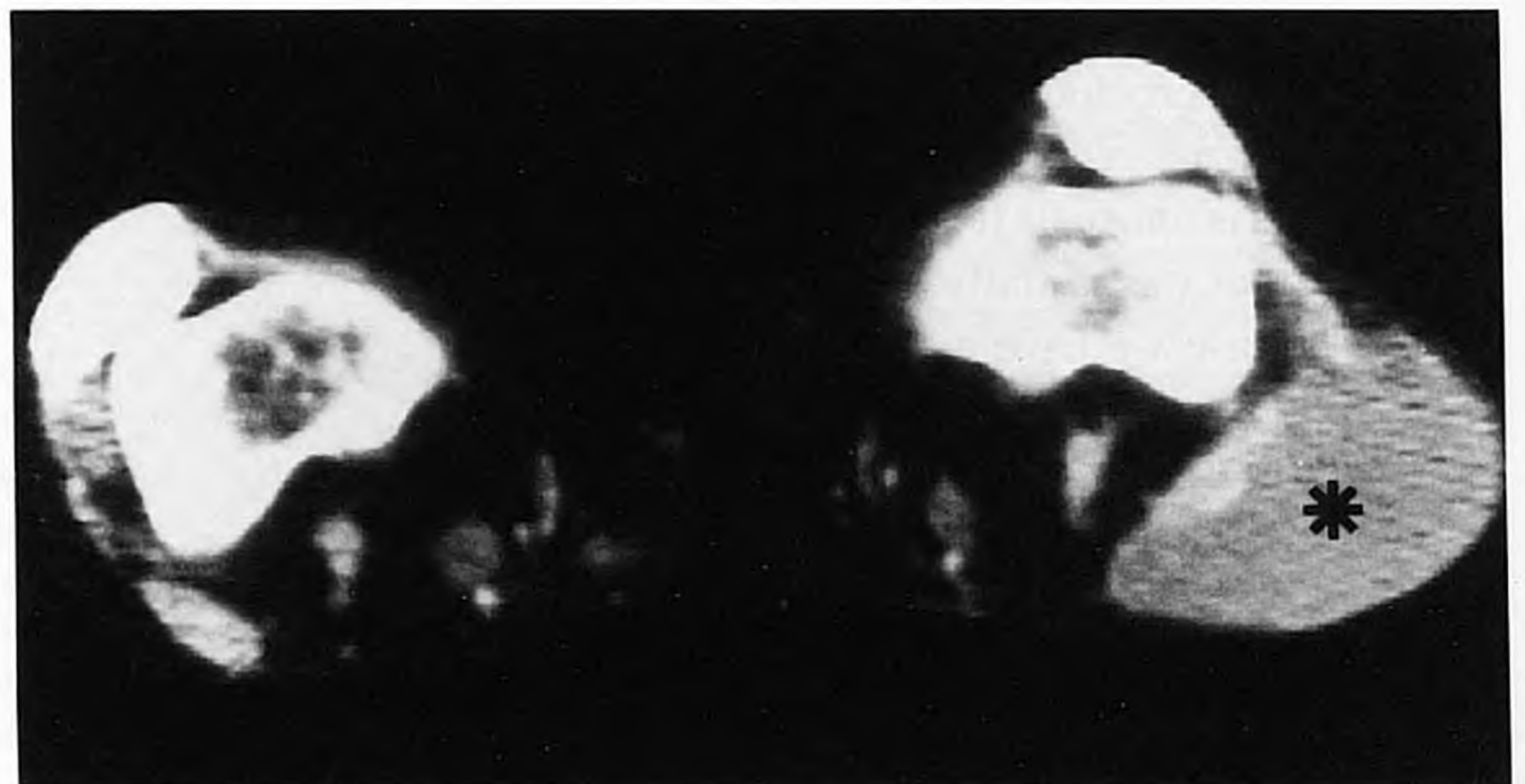
These lesions are caused by the hematogenous dissemination of tubercle bacilli as a cutaneous manifestation of generalized miliary visceral tuberculosis [1–3]. Histologic examination shows a nonspecific dermal infiltrate of lymphocytes and

plasma cells, with focal areas of necrosis and abscess (usually without granuloma formation) in which acid-fast bacilli are found [1–14]. Granuloma formation seems to be dependent on the presence of vascular thrombi with acid-fast bacilli, which interrupt the local blood supply. Blockage of the circulation seems to cause necrosis, thereby rendering a specific tuberculoid reaction impossible [1].

A negative PPD reaction is a typical finding in tuberculosis cutis miliaris disseminata, in contrast to other forms of cutaneous tuberculosis and tuberculids, which are associated with a positive skin reaction [1–3].

Through a computer search of the literature (Medlars), we found reports on 24 cases of tuberculosis cutis miliaris disseminata [1, 2, 4–14]. The characteristics of these cases are given in table 1. In two cases (10 and 21) no biopsies were performed, and in five cases (7, 11, 12, 23, and 24) no acid-fast bacilli were demonstrated; thus a meaningful evaluation of these seven cases is impossible.

**Figure 3.** Computed tomography of the upper legs. In the left upper leg (seen on the right here) is an abscess (\*) extending along the musculus biceps femoris. This is an extension from a large retrofascial abscess in the gluteal muscles on the left side.



**Table 1.** Reported cases of tuberculosis cutis miliaris disseminata in patients >15 years old.

Patient	Age/sex	AFB	PPD reaction	Anti-tuberculous drugs	Healing skin	Fatal outcome	Reference
1	22/M	+	NS	No	No	Yes	1
2	29/M	+	NS	No	No	Yes	4
3	35/F	+	NS	No	No	Yes	4
4	29/M	+	NS	No	No	Yes	1
5	36/M	+	NS	No	No	Yes	1
6	63/F	+	NS	No	No	Yes	5
7	46/F	-	NS	No	No	Yes	6
8	37/M	+	-	No	No	Yes	7
9	29/F	+	NS	No	No	Yes	8
10	50/M	NS	NS	S	No	Yes	9
11	20/M	-	NS	P/S/I	Yes	No	9
12	69/M	-	NS	S/P	No	Yes	9
13	71/F	+	NS	No	No	Yes	9
14	21/M	+	NS	P/S-I*	Yes	No	9
15	57/M	+	-	No	No	Yes	9
16	16/M	+	-	S/P	Yes	No	9
17	18/M	+	-	S/P	Yes	No	9
18	30/M	+	-	P/S/I	Yes	Yes	1
19	31/F	+/-	NS	R/E/I	Yes	No	2
20	20/F	+	+	R/S/I	Yes	No	10
21	36/F	NS	-	E/S/I	Yes	No	11
22	67/M	+	-	R/E/I	Yes	No	12
23	58/M	-	+	R/E/I/PY	Yes	No	13
24	32/M	-	-	R/E/I	No	Yes	14

NOTE. Abbreviations: AFB = acid-fast bacilli; + = positive; - = negative; +/- = indeterminate; NS = not stated; S = streptomycin; P = *p*-aminosalicylic acid; I = isoniazid; R = rifampin; E = ethambutol; PY = pyrazinamide.

\* The therapeutic agent was changed from P/S to I.

A positive PPD reaction was reported in two cases (20 and 23) and a negative PPD reaction in eight cases; no PPD data were given for the remaining 14 cases. Healing of the cutaneous lesions usually occurred at 4–6 weeks (range, 2 weeks to 10 months).

Recurrences were not described, with the possible exceptions of cases 14 and 17 [1, 2, 9–13]. In case 14 new lesions appeared every few weeks despite repeated courses of streptomycin and *p*-aminosalicylic acid; after 2 years, isoniazid was given, and no additional lesions developed subsequently. In case 17 new lesions appeared in the first month after initiation of antituberculous therapy.

Therefore, the recurrence of skin lesions in this form of tuberculosis is unusual. It is interesting that the reappearance of skin lesions was initially the only sign of insufficient therapy in the case we have described herein.

In the reported cases, major underlying illnesses were virtually absent. In case 21 there was a history of alcohol abuse, and in cases 9 and 23 there was a history of previous tuberculous infection [8, 11, 13]. No other reports of tuberculosis cutis miliaris disseminata in immunocompromised patients were found in the literature, although dissemination of tuber-

culous infection to the skin would theoretically be expected to occur more frequently in such patients. In our patient the use of glucocorticosteroids and azathioprine seems to have been a major factor in the failure to control mycobacterial infection.

The tuberculous ulcer on the left buttock of our patient can be interpreted as a manifestation of tuberculosis cutis miliaris disseminata. It can also be accounted for, however, by local spread of bacilli from the underlying abscess, a scenario described elsewhere as tuberculosis cutis colliquativa [1–3].

The cold tuberculous abscess in our patient was unusual in two respects. First, it was located behind the fascia in the gluteal folds, with extension downward to the popliteal fossa. Usually, spontaneous drainage occurs more proximally, toward the insertion of the glutei on the greater trochanter or at the posterior aspect of the proximal part of the femoral shaft [15]. Second, there was no infection of the sacrum, the ilium, or the sacroiliac joint, which are the most common sources of retrofascial abscess [15, 16]. A retroperitoneal source was also excluded. Hematogenous dissemination of acid-fast bacilli to the gluteal region is probably the best explanation.

The most likely reason for the failure of therapy in this patient with recurrent skin lesions is a combination of suboptimal regimens [17, 18] and the presence of a tuberculous abscess—a source of recurrent bacteremia. We were greatly limited in our choice of drugs by hepatotoxicity, nephrotoxicity, ototoxicity, and CNS toxicity in this patient. After the partial restoration of renal function, we were able to use isoniazid, rifampin, and ciprofloxacin, and skin lesions subsequently improved. Only after the detection of the large abscess and surgical therapy was complete recovery possible. This case illustrates the risk of ototoxicity and nephrotoxicity when different aminoglycosides are given simultaneously.

The cause of coma in this case remains speculative. Isoniazid metabolites, which accumulated during the period of renal insufficiency [18], were probably responsible.

This case illustrates the importance of careful examination of the skin in clinical medicine, since tuberculosis cutis miliaris disseminata is an easily overlooked sign of miliary tuberculosis.

## References

1. Schermer DR, Simpson CG, Haserick JR, van Ordstrand HS. Tuberculosis cutis miliaris acuta generalisata. Report of a case in an adult and review of the literature. *Arch Dermatol* 1969;99:64–9
2. Brown FS, Anderson RH, Burnett JW. Cutaneous tuberculosis. *J Am Acad Dermatol* 1982;6:101–6
3. Harahap M. Tuberculosis of the skin. *Int J Dermatol* 1983;22:542–5
4. Naegeli O. Ueber haematogene Hauttuberkulose. *Münchener Medizinische Wochenschrift* 1898;15:450–1
5. Bruusgaard E. Beitrag zu den tuberkulösen Hauteruptionen. Erythroderma universalis tuberculosa. *Arch Derm Syph* 1903;67:227–37
6. Hedinger E. Miliartuberkulose der Haut bei Tuberkulose der Aorta abdominalis. *Frankfurter Zeitschrift für Pathologie* 1909;2:121–4

7. Melik W. Tuberculosis miliaris cutis bei einem Erwachsenen. *Dermatologische Zeitschrift* 1927;50:199-204
8. Leibowitz S. Tuberculous sepsis with a myeloblastic blood picture. *Arch Pathol* 1938;25:365-75
9. Lees AW, Munro IB. Skin lesions and deafness in disseminated tuberculosis. *BMJ* 1954;1:496-9
10. Kennedy C, Knowles GK. Miliary tuberculosis presenting with skin lesions. *BMJ* 1975;3:356
11. Fisher JR. Miliary tuberculosis with unusual cutaneous manifestations. *JAMA* 1977;238:241-2
12. Bateman DE, Makepeace W, Lesna M. Miliary tuberculosis in association with chronic cutaneous tuberculosis. *Br J Dermatol* 1980;103:557-60
13. Neukam FW, Lubach D, Becker J. Tuberculosis miliaris ulcerosa mucosae et cutis bei offener Lungentuberkulose und Lupus vulgaris. *Deutsch Zeitschrift Mund Kiefer Gesichts Chirurgie* 1986;10:287-90
14. Dimitrowa J, Obreschkova E, Kirjakowa N. Tuberculosis cutis miliaris acuta generalisata. *Z Hautkr* 1986;61:1549-53
15. Simons GW, Sty JR, Starshak RJ. Retroperitoneal and retrofascial abscesses. *J Bone Joint Surg [Am]* 1983;65A:1041-58
16. Gorse GJ, Pais MJ, Kusske JA, Cesario TC. Tuberculous spondylitis: report of six cases and a review of the literature. *Medicine (Baltimore)* 1983;62: 178-93
17. American Thoracic Society. Treatment of tuberculosis and tuberculosis infection in adults and children. *Am Rev Respir Dis* 1986;134:355-63
18. Harding SM, Bailey WC. Chemotherapy of tuberculosis. In: Schlossberg D, ed. *Tuberculosis*. 2nd ed. New York: Springer-Verlag, 1987: 39-53