

PDF hosted at the Radboud Repository of the Radboud University Nijmegen

This full text is a publisher's version.

For additional information about this publication click this link.

<http://hdl.handle.net/2066/14845>

Please be advised that this information was generated on 2014-11-11 and may be subject to change.

CASE REPORT

Treatment of invasive aspergillosis with itraconazole in a patient with chronic granulomatous disease

Jan W. van 't Wout,*§ Ernest J. M. Raven†
and Jos W. M. van der Meer*‡

* Department of Infectious Diseases, University Hospital, Leiden, The Netherlands, and † Department of Paediatrics, Hospital De Goddelijke Voorzienigheid, Sittard, The Netherlands

Accepted for publication 9 September 1989

Summary

An 18-year-old boy with X-linked chronic granulomatous disease (CGD) developed *Aspergillus fumigatus* pneumonia and multifocal osteomyelitis. Treatment with amphotericin B resulted in only moderate improvement of the lesions and was accompanied by considerable toxicity. In contrast, administration of the new triazole drug itraconazole led to complete disappearance of all signs of infection. We conclude that itraconazole may be a valuable new drug for treating invasive aspergillosis in patients with CGD, although the duration of treatment remains to be established.

Introduction

Chronic granulomatous disease (CGD) is a rare disorder which usually becomes manifest early in childhood and is characterised by recurrent infections.¹ The most common causative agents are *Staphylococcus aureus*, Enterobacteriaceae and fungi. In a review of 245 patients with CGD, the incidence of fungal infections was 20.5%, most being caused by species of *Aspergillus*.² Since mortality from bacterial infections can be largely prevented by the prophylactic administration of co-trimoxazole, *Aspergillus* infections now form the most important cause of death for patients with CGD.³ Amphotericin B, a widely used antifungal drug for treating these infections, has several well-known side-effects, such as fever, chills, nephrotoxicity, hypokalaemia, anaemia and thrombophlebitis.

Itraconazole is a new oral triazole antifungal drug that is effective against *Aspergillus* spp. *in vitro*, in experimental animal models and in patients.⁴⁻⁶ The mode of action of itraconazole, like that of the azoles, is inhibition of ergosterol synthesis in the fungal cell membrane through binding to the cytochrome P-450.⁷ In this report we describe a patient with CGD who developed invasive aspergillosis which persisted despite treatment with amphotericin B; the patient later responded favourably to itraconazole.

‡ Present address: Department of Internal Medicine, University Hospital, Nijmegen, The Netherlands.

§ Address correspondence to: Dr J. W. van 't Wout, Department of Infectious Diseases, University Hospital, Building 1, C5-P, P.O. Box 9600, 2300 RC Leiden, The Netherlands.

Case report

An 18-year-old boy was referred to the Leiden University Hospital in April 1986. In 1977 and 1978, the patient was treated for pleural empyema as well as subphrenic and liver abscesses caused by *Staphylococcus aureus*. A diagnosis of X-linked chronic granulomatous disease (CGD) was made. This was based on the defective killing of *S. aureus* by the patient's granulocytes and deficient production of hydrogen peroxide by these cells. Similar defects were demonstrated in respect of his mother and his maternal grandmother.

In 1979, the patient was put on maintenance therapy with co-trimoxazole without further bacterial infections. In December 1985, he developed pain in the right shoulder and a non-productive cough. A chest X-ray showed an infiltration in the right lower lobe. The dose of co-trimoxazole was increased to four tablets daily. Three months later the patient's condition deteriorated with fever, loss of weight, abdominal pain and progressive coughing. There was obvious extension of the pulmonary lesions in the right lower lobe. *Aspergillus fumigatus* was cultured on several occasions from purulent discharge from an old scar on the right chest wall. There were multiple bone lesions in the ribs as well as the left humerus. A biopsy from the left humerus also yielded *Aspergillus fumigatus*.

The patient was treated with amphotericin B intravenously (total cumulative dose 20 mg/kg) and flucytosine (160 mg/kg daily) for a period of 6 weeks. Treatment with amphotericin B, which was complicated by recurrent chills, high fever and thrombophlebitis, resulted in only moderate clinical improvement. On 30 April 1986, the patient was transferred to the University Hospital of Leiden for further treatment. Physical examination revealed a pale, ill, cachectic boy, temperature 37.4 °C, body weight 48 kg. Apart from healed skin lesions on the right chest wall, the abdominal wall and the right upper arm no abnormalities were found on clinical examination. The ESR was 75 mm/h, haemoglobin 7.8 g/dl, leucocyte count $16.1 \times 10^9/l$, serum creatinine 71 $\mu\text{mol/l}$ and serum potassium 2.8 mmol/l. A chest X-ray still showed extensive infiltration in the right lower lobe [Plate 1(a)]. Treatment with 150 mg itraconazole twice daily was started. After a transfusion of 2 units of packed erythrocytes, the patient was discharged from hospital. Three weeks of treatment with itraconazole at home resulted in marked clinical improvement. Four months after the start of treatment with itraconazole, all clinical signs of infection had disappeared and a chest X-ray showed almost complete resolution of the infiltrate [Plate 1(b)]. The ESR was 16 mm/h, haemoglobin 12.3 g/dl, leucocyte count $5.9 \times 10^9/l$. No serious side-effects of itraconazole or abnormalities in laboratory tests were encountered. The patient did, however, experience a short episode of moderate loss of hair.

Plasma concentrations of itraconazole on the second day of treatment (determined by high-pressure liquid chromatography) were 378 ng/ml before the dose, 442 ng/ml at 2 h, 665 ng/ml at 4 h, and 555 ng/ml at 6 h after the dose. After 3 weeks of treatment, the plasma concentration of itraconazole was 1820 ng/ml 2 h after a dose of 150 mg. The patient has since been taking a maintenance dose of itraconazole of 100 mg twice daily for 3 years without any signs of recurrence of the fungal infection. In this period, the bone lesions have completely resolved.

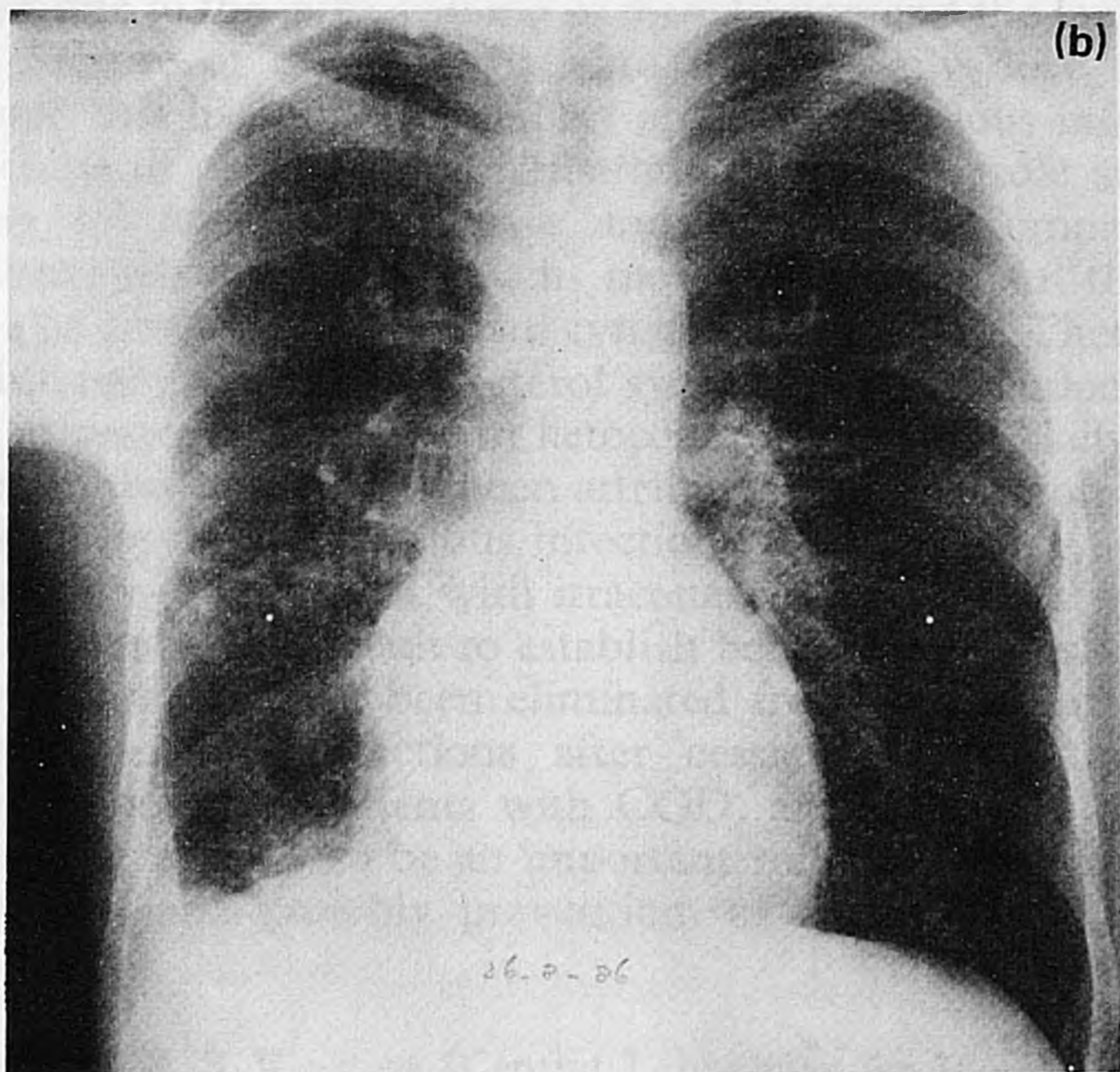
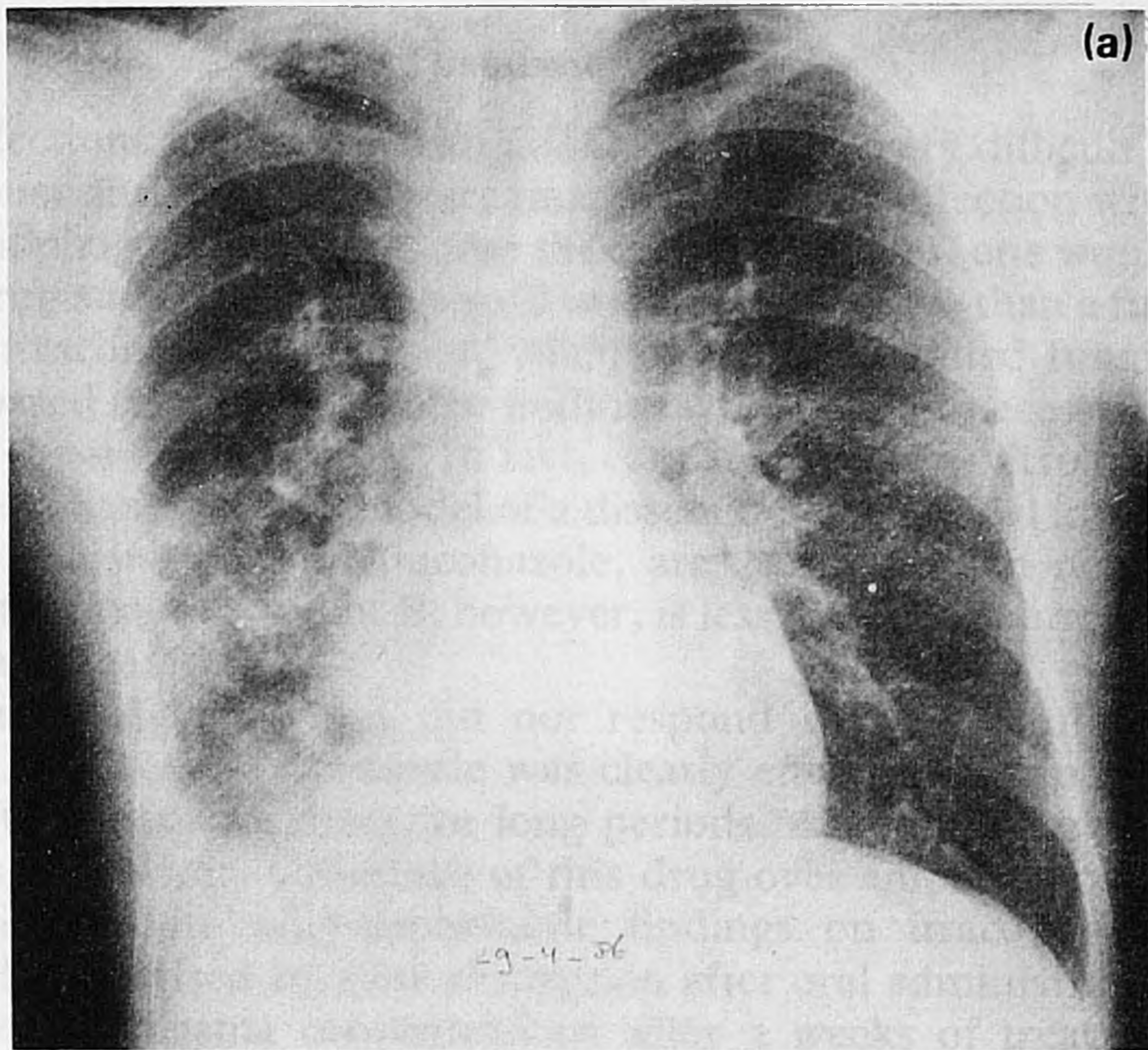


Plate 1. Chest X-rays of a patient with CGD and aspergillosis at the start of treatment with itraconazole (a) and 4 months later (b).

Discussion

Aspergillus infections in patients with CGD are usually very difficult to treat,² probably because antifungal drugs are unable to cure the infection without the contribution of phagocytic cells. Under these circumstances, one would expect a fungicidal drug such as amphotericin B to be more effective than a fungistatic drug such as itraconazole. However, whether a drug is called fungistatic or fungicidal is based mainly on in-vitro findings which do not necessarily reflect the efficacy of these drugs *in vivo*.⁸ In fact, contrary to the in-vitro findings we have shown in an experimental model of a disseminated candidal infection that the triazoles, itraconazole and fluconazole, are as effective in normal as in neutropenic mice. Amphotericin B, however, is less active in neutropenic mice than in normal mice.⁹

In our patient, the infection did not respond well to a full course of amphotericin B whereas itraconazole was clearly effective. For patients with CGD, who often need treatment for long periods, the oral administration of itraconazole is an obvious advantage of this drug over amphotericin B. As in healthy volunteers, the pharmacokinetic findings on itraconazole in our patient were characterised by slow absorption after oral administration of the drug and a rise in plasma concentrations after 3 weeks of treatment. The latter is probably due to the large volume of distribution and the long half-life of the drug.¹⁰ Because of this long half-life, a once-daily dose should be effective, although this has not been widely applied for serious infections so far. The side effects of prolonged administration of itraconazole are usually mild, consisting of nausea, dyspepsia and dizziness.⁵ Compared with ketoconazole, itraconazole binds much more selectively to the fungal cytochrome P-450 than to the human cytochrome P-450.⁷ There is not, therefore, any interference with cholesterol synthesis so that endocrine side-effects, as seen in patients treated with ketoconazole, are less likely. Loss of hair, as was seen in our patient, has been attributed to itraconazole¹¹ but can also arise during recovery from serious infections.

The exact duration of treatment with itraconazole for patients with CGD and *Aspergillus* infections is difficult to establish because it remains uncertain whether all the organisms have been eliminated from the site of infection. Recurrences of *Aspergillus* infections after cessation of treatment with amphotericin B, common in patients with CGD, are often very difficult to treat.² Therefore, there seems to be an important role for itraconazole in the long-term treatment, and possibly prevention, of *Aspergillus* infections in these patients.

(We wish to thank Dr R. S. Weening (Central Laboratory for Blood Transfusion, Amsterdam, the Netherlands) for performing the functional and biochemical granulocyte studies; Janssen Pharmaceutics (Beerse, Belgium) for determining itraconazole plasma concentrations and Professor Dr R. van Furth for his critical reading of the manuscript.)

References

1. Tauber AI, Borregaard N, Simons E, Wright J. Chronic granulomatous disease: a syndrome of phagocyte oxidase deficiencies. *Medicine* 1983; **62**: 286-309.

2. Cohen MS, Isturiz RE, Malech HL *et al.* Fungal infection in chronic granulomatous disease. *Am J Med* 1981; **71**: 59-66.
3. Weening RS, Kabel P, Pijlman P, Roos D. Continuous therapy with sulfamethoxazole-trimethoprim in patients with chronic granulomatous disease. *J Pediatr* 1983; **103**: 127-129.
4. Dismukes WE. Azole antifungal drugs: old and new. *Ann Intern Med* 1988; **109**: 177-179.
5. De Beule K, De Doncker P, Cauwenbergh G *et al.* The treatment of aspergillosis and aspergilloma with itraconazole, clinical results of an open international study (1982-1987). *Mycoses* 1988; **31**: 476-485.
6. Viviani MA, Tortorano AM, Langer M *et al.* Experience with itraconazole in cryptococcosis and aspergillosis. *J Infect* 1989; **18**: 151-165.
7. Vanden Bossche H. Itraconazole: a selective inhibitor of the cytochrome P-450 dependent ergosterol synthesis. In: Fromtling RA, Ed. *Recent trends in the discovery, development and evaluation of antifungal agents*. Barcelona: JR Prous Publishers, 1987; 207-221.
8. Speller DCE, Warnock DW. Sensitivity and resistance to antifungals. *J Antimicrob Chemother* 1986; **17**: 514-516.
9. Van 't Wout JW, Mattie H, Van Furth R. A comparison of the efficacies of amphotericin B, fluconazole and itraconazole against a systemic *Candida albicans* infection in normal and neutropenic mice. *Antimicrob Agents Chemother* 1989; **33**: 147-151.
10. Hardin TC, Graybill JR, Fetchick R, Woestenborghs R, Rinaldi MG, Kuhn JG. Pharmacokinetics of itraconazole following oral administration to normal volunteers. *Antimicrob Agents Chemother* 1988; **32**: 1310-1313.
11. Moller Heilesen A. Hair loss during itraconazole treatment (letter). *Br Med J* 1986; **293**: 823.