

## PDF hosted at the Radboud Repository of the Radboud University Nijmegen

This full text is a publisher's version.

For additional information about this publication click this link.

<http://hdl.handle.net/2066/14815>

Please be advised that this information was generated on 2014-11-11 and may be subject to change.

## CASE REPORT

### Failure to diagnose fatal disseminated toxoplasmosis in a bone marrow transplant recipient: the possible significance of declining antibody titres

A. H. M. Heurkens,\* I. A. Koelma,† M. M. de Planque,‡  
A. M. Polderman§ and J. W. M. van der Meer||

\* Departments of Rheumatology, † Pathology, ‡ Immunohaematology and Bloodbank, § Parasitology and || Infectious Diseases, University Hospital Leiden, The Netherlands

Accepted for publication 11 October 1988

#### Summary

A 46-year-old patient with acute myelogenous leukaemia developed lethal disseminated toxoplasmosis 8 weeks after allogeneic bone marrow transplantation. Clinical features included pulmonary infiltrates, respiratory insufficiency and neurological signs.

Post-transplantation toxoplasma serological tests were characterised by declining IgG titres and failure to detect IgM, whereas titres of IgG against the various herpes viruses remained constant and even increased over the same period. Circulating toxoplasma antigen could not be detected. *Post mortem*, specific immune complexes were identified in serum. Autopsy revealed widely disseminated toxoplasmosis with several foci in the brain, lungs and various other organs as well as concomitant infection with cytomegalovirus.

#### Introduction

Patients who undergo allogeneic bone marrow transplantation for acute myelogenous leukaemia<sup>1</sup> become severely immunocompromised for prolonged periods of time and are at risk of opportunistic infections.<sup>2</sup>

To date, up to 20 cases of toxoplasmosis in bone marrow allotransplant recipients have been reported.<sup>3-11</sup> Because of non-specific symptomatology and the equivocal results of serological tests, the diagnosis was often not established until autopsy.

#### Case report

A 46-year-old man with acute myelogenous leukaemia (M5A) achieved complete remission after treatment with daunorubicin, vincristine and cytarabine. After consolidation therapy with the same drugs as well as an intensive course of cyclophosphamide and total body irradiation, allogeneic bone marrow transplantation (BMT) was performed. To prevent graft-versus-host disease (GVHD) cyclosporin A was given.

Haemopoiesis recovered within 4 weeks and the patient was discharged from hospital on the 27th day after BMT. At that time, prednisone (120 mg)

was prescribed because of grade I GVHD of the skin and probably the intestine. Doses of prednisone and cyclosporin A were tapered off during the next few days. On day 37 after BMT, the patient was readmitted because of severe GVHD of the skin (Grade III, proven by biopsy) and probably of the gut (diarrhoea) and liver (rise in the serum concentration of bilirubin). Treatment consisted of intravenous methylprednisolone, immunoglobulins, plasma, human albumin and total parenteral nutrition.

The selective anti-microbial modulation regimen (oral polymyxin B, neomycin, nalidixic acid and amphotericin B) was replaced by intravenous co-trimoxazole.<sup>2</sup> Surveillance cultures did not reveal growth of micro-organisms. A temporary improvement was seen within a few days.

Two weeks later, the patient suddenly became dyspnoeic and expectorated foamy sputum. On physical examination of the lungs, râles were heard. An X-ray of the chest revealed areas of alveolar consolidation in the lower fields of both lungs. Within several hours respiratory insufficiency developed and the patient became unconscious.

Intubation and artificial respiration with extra oxygen and positive end-expiratory pressure resulted in good arterial oxygenation. Nevertheless, coma persisted and a right-sided hemiparesis developed with deviation of the eyes to the right. The patient suffered generalised seizures, starting in the right hand, which could not be controlled. Four successive blood cultures remained sterile. Because of the severely prolonged bleeding time, a lumbar puncture was not performed. Computed tomographic scanning of the brain (without contrast) did not show any abnormalities. The final clinical course was characterised by high fever, shock and renal insufficiency. On day 57 after BMT, within 3 days of the sudden onset of the above-mentioned signs, the patient died.

### Pathological findings

At autopsy, performed within 5 h of death, a mild degree of jaundice was observed; the brain (1350 g) contained a small lesion in the parietal region of the left cerebral hemisphere. Microscopical studies revealed necrotic foci that contained several pseudocysts of *Toxoplasma gondii* surrounded by single tachyzoites (Plate 1). Pseudocysts and single tachyzoites of *T. gondii* were also found in the heart, lungs, adrenals, liver and bone marrow. In the oedematous lungs (2500 g) necrotic foci of pneumonia also contained the parasite. In addition, cytomegalic cells were identified in the lungs (Plate 2) and the adrenal glands. The liver (1850 g) exhibited steatosis, cholestasis and some pericentral necrosis but was without evidence of GVHD. GVHD was demonstrated in the skin and the colon. The bone marrow was cellular without evidence of leukaemia. Epithelial cells of the renal tubules were vacuolated but histological features of cyclosporin intoxication were absent.

Post-mortem cultures of the lungs, liver and spleen grew enterococci; *Staphylococcus epidermidis* was isolated from the lungs. Probably neither of these bacterial species is of clinical significance in view of the sterile blood cultures *ante-mortem*. Viral culture of the lungs yielded cytomegalovirus (CMV).

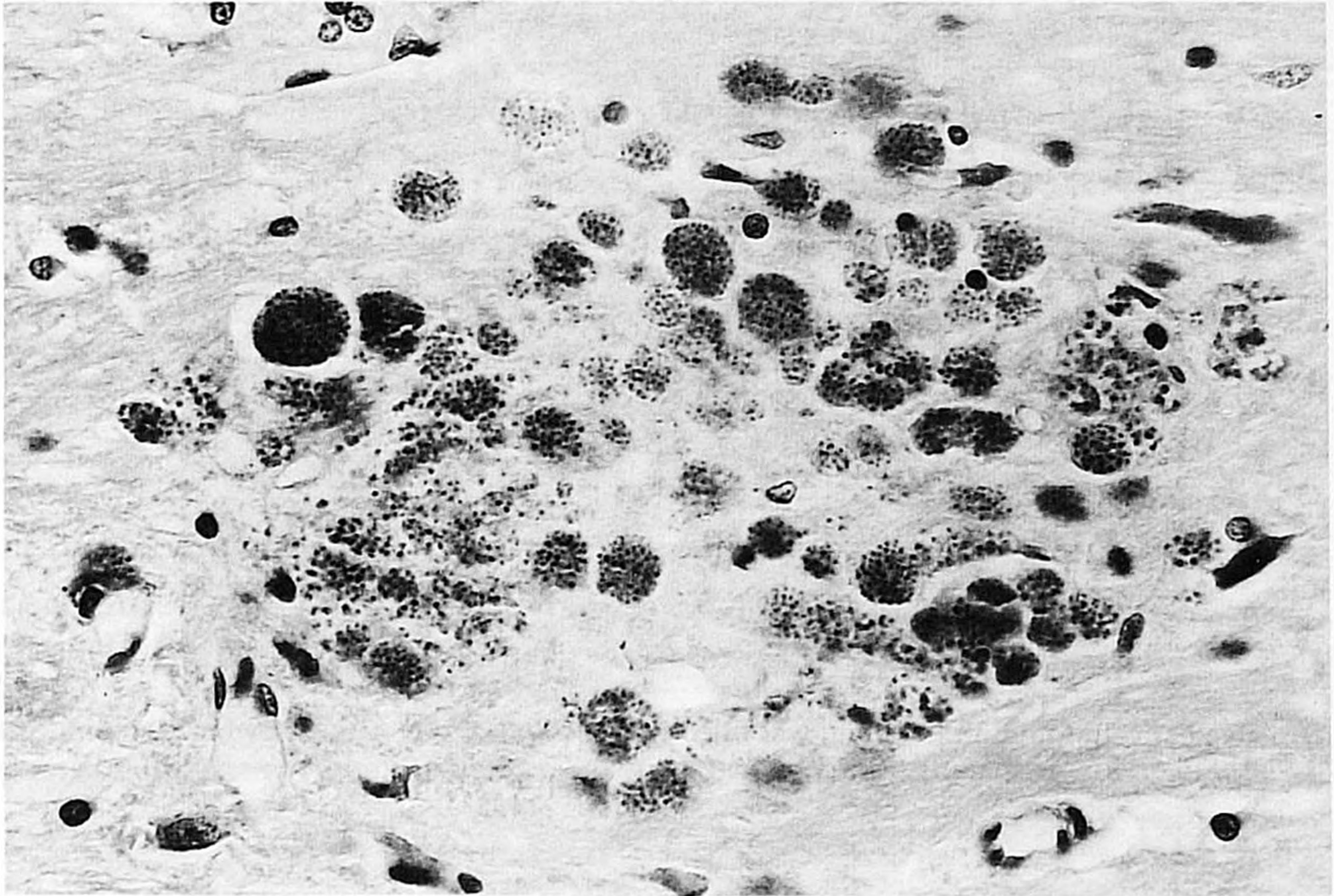


Plate I. Pseudocysts and single tachyzoites of *Toxoplasma gondii* in a section of brain. Haematoxylin and eosin.  $\times 400$ .

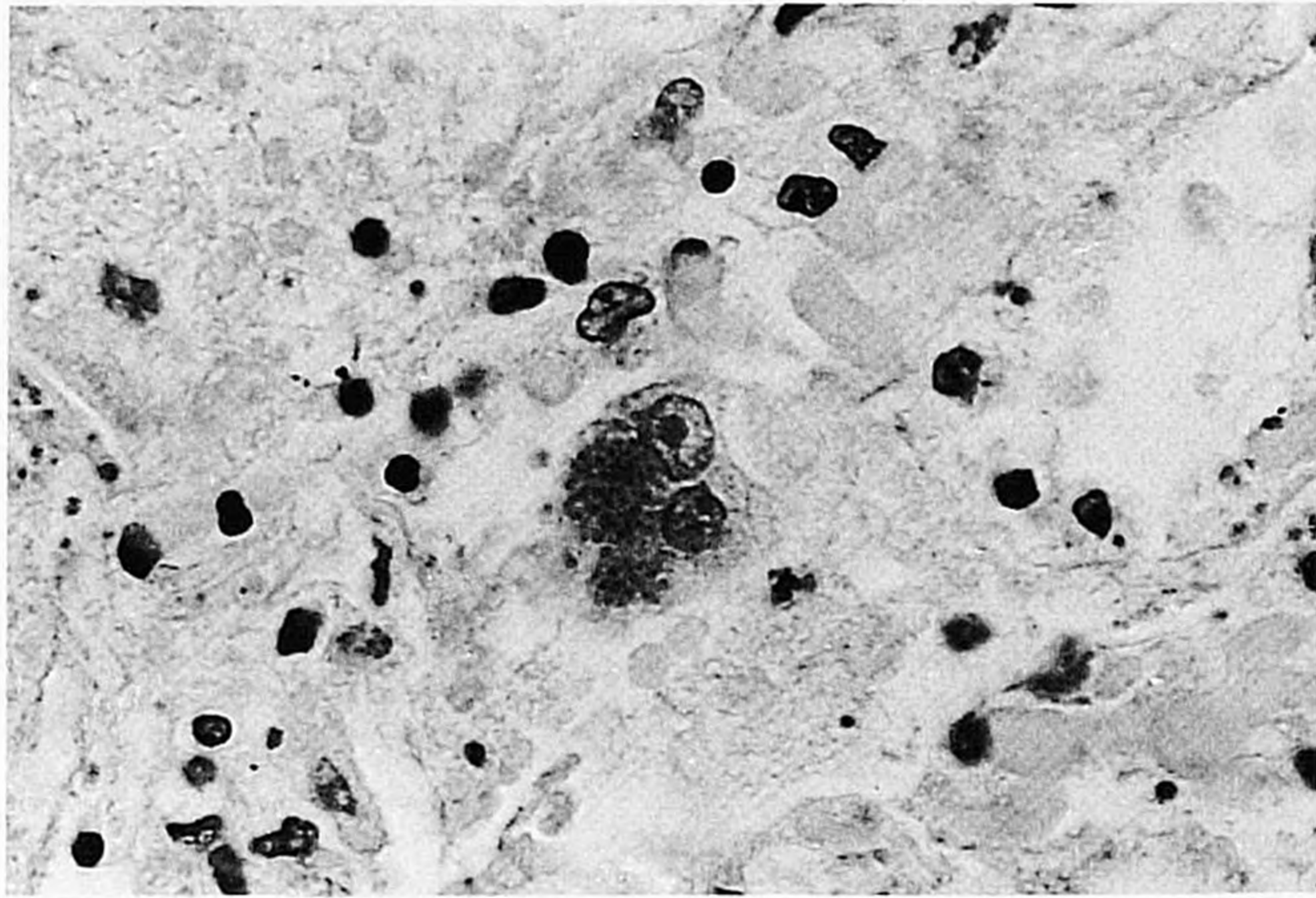


Plate 2. An alveolar cell, found in the lung, was filled with *Toxoplasma gondii*. Elsewhere, cytomegalic cells were seen. Haematoxylin and eosin.  $\times 400$ .

Table I Results of toxoplasma serological tests

Timing	IgG titre*	IgM†	Circulating antigen‡
4 weeks before BMT	160	Negative	Negative
1 week before BMT	160	Negative	Negative
4 weeks after BMT	80	Negative	Negative
7 weeks after BMT	20	Negative	Negative

\* An IgG titre  $\geq 80$  is considered to be specific in the test-system used.

† Tests performed by three methods: ELISA, antibody capture ELISA and Western blot technique.

‡ Sought by dot-immunobinding technique.

BMT = Bone marrow transplant; ELISA = enzyme-linked immunosorbent assay.

### Serological findings

An indirect enzyme-linked immunosorbent assay (ELISA) for detecting toxoplasma-specific IgG and IgM<sup>12</sup> as well as an antibody-capture ELISA that included the use of peroxidase-labelled antigen in anti-human-IgM-coated trays (also for detecting specific IgM) were performed.<sup>13</sup>

In addition, the IgM-specific response to separate *T. gondii* antigens was analysed by the Western blot technique. The presence of IgM antibodies reactive with the 6 kDa antigen was used as the criterion for positivity.<sup>14</sup> An attempt was made to detect circulating *T. gondii* antigens by use of a dot-immunobinding technique.<sup>15</sup>

Results of the tests, done on four different serum samples, are summarised in Table I. The IgG titre of 160 is compatible with past infection with *T. gondii*. Serological evidence could not be found for reactivation of the old infection (declining IgG titres, lack of detectable IgM and detectable circulating antigen). Post mortem studies of two samples of serum (one obtained before and one after BMT) revealed the presence of circulating IgG complexes containing *T. gondii* antigen (tests kindly performed by Dr van Knapen, National Institute of Public Health and Environmental Hygiene, Bilthoven, the Netherlands).<sup>16</sup> Extensive quantitative serological analysis of these same samples yielded titres for IgG antibodies against CMV (ELISA for early antigens) ranging between 1600 and 800. Similarly, immunofluorescence tests for IgG against varicella-zoster virus and Epstein-Barr virus showed constant titres (ranging between 128 and 256 and 256 and 512, respectively). Anti-herpes simplex virus (HSV) IgG titres had increased significantly (64 to 256) (Table II).

Table II *Serum titres of IgG antibodies against Toxoplasma gondii and herpes-type viruses*

Timing	Toxoplasma	CMV		HSV	VSV	EBV
	IgG	ELISA IgG	IFA IgM	IFA-IgG	IFA-IgG	IFA-IgG
4 weeks before BMT	160	1600	Negative	64	128	256
1 week before BMT	160	1600	Negative	64	128	512
4 weeks after BMT	80	1600	Negative	256	256	512
7 weeks after BMT	20	800	Negative	256	128	256

ELISA = Enzyme-linked immunosorbent assay; IFA = indirect immunofluorescence assay; CMV = cytomegalovirus; HSV = herpes simplex virus; VZV = varicella-zoster virus; EBV = Epstein-Barr virus; BMT = bone marrow transplant

### Discussion

Bone marrow transplant patients are extremely susceptible to opportunistic infections because of their immunocompromised state,<sup>2</sup> which is induced by chemotherapy, irradiation, immunosuppressive drugs and GVHD.<sup>2,17</sup> Moreover, cytomegalovirus infection, as in our patient, has been shown to produce further immune suppression.<sup>18</sup> Our patient developed rapidly fatal disseminated toxoplasmosis with CMV infection. The fatal toxoplasma infection arose in spite of treatment with co-trimoxazole (400 mg sulfamethoxazole and 80 mg trimethoprim, twice daily, intravenously). The efficacy of co-trimoxazole in toxoplasmosis has not been established in human beings although there is some evidence for activity in animal models.<sup>19</sup> The association of viral, bacterial or protozoal infections with disseminated toxoplasmosis has been described before.<sup>6,20-23</sup> As a rule the concomitant infection is a DNA-virus (CMV, HSV).<sup>22,23</sup> The diagnosis of toxoplasmosis in severely immunocompromised hosts is notoriously difficult because the clinical and radiological features are non-specific<sup>4,21,22,25</sup> and serological tests are of little help.<sup>4,5</sup> Because of the relatively high incidence of cerebral toxoplasmosis among patients with AIDS,<sup>26</sup> (in a recent study from the University Medical Centre in Amsterdam cerebral toxoplasmosis was diagnosed in 12% of these patients; personal communication P. Portegies) many clinicians nowadays start treatment for toxoplasmosis whenever clinical evidence and the cerebral computed tomographic images are compatible with this diagnosis. Such an approach is not warranted in BMT patients because of the rarity of toxoplasmosis among these patients.

In our patient, reactivation of an old *T. gondii* infection, which led to extensive proliferation of the parasite in various organs, was accompanied not by a rise in antibody titre but by a decreasing titre. In retrospect, this decrease

in IgG titre was selective, since none of the viral titres sought decreased at the same time. The decreasing titre can probably be explained by the short half-life of the specific antibodies during active infection and the fact that the rate of production of these antibodies was presumably not yet optimal. Also, the antibodies may not have been detectable because they were contained in immune complexes, which were in fact detected *post mortem*. Decreasing specific antibody titres have been reported in fatal CMV infections in BMT patients.<sup>27</sup>

Failure to detect *T. gondii* antigen, despite massive proliferation of the parasite, has also been reported by others. Brooks *et al.*<sup>15</sup> could detect circulating antigens in only two of six congenitally infected infants. The negative results of this test are consistent with several explanations: poor sensitivity of the test, containment of antigen within immune complexes or intermittent antigenaemia, as have been suggested by Araujo and Remington.<sup>28</sup> In conclusion, there is a great need for reliable diagnostic tests for suspected disseminated toxoplasmosis in severely immunocompromised patients. The antigen detection test includes the use of a polyvalent toxoplasma antiserum. Monoclonal antibodies directed specifically against circulating antigen might possibly improve both specificity and sensitivity of the test. More experience is needed to validate the detection of these antibodies in immune complexes. For the time being, our experience suggests that toxoplasmosis should be suspected when the specific antibody titres falls while others remain constant.

(The authors would like to thank Dr F. Knapen for critically reading the manuscript and Ms J. Ravensbergen and A. A. J. P. Postma for their secretarial assistance.)

### References

1. Klingeman HG, Storb R, Fefer A *et al.* Bone marrow transplantation in patients aged 45 years and older. *Blood* 1986; **67**: 770-776.
2. Van der Meer JWM, Guiot HFL, Van den Broek PJ, Van Furth R. Infections in bone marrow transplant recipients. *Semin Hematol* 1984; **21**: 123-140.
3. Emerson RG, Jardine DS, Milvenan ES. Toxoplasmosis: a treatable neurologic disease in the immunologically compromised patients. *Paediatrics* 1981; **67**: 653-655.
4. Löwenberg B, Van Gijn J, Polderman AM. Fatal cerebral toxoplasmosis in a bone marrow transplant recipient with leukemia. *Transplantation* 1983; **35**: 30-34.
5. Hirsch R, Burke BA, Kersy JH. Toxoplasmosis in bone marrow transplant recipients. *J Pediatr* 1984; September; **105**: 426-428.
6. Tang TT, Harb JM, Dunne WM *et al.* Cerebral toxoplasmosis in an immunocompromised host. A precise and rapid diagnosis by electron microscopy. *Am J Clin Pathol* 1986; **85**: 104-110.
7. Jehn U, Fink M, Gundlack P *et al.* Lethal cardiac and cerebral toxoplasmosis in a patient with acute myeloid leukemia after successful allogenic bone marrow transplantation. *Transplantation* 1984; **38**: 430-433.
8. Beelen DW, Mahmond HK, Mlynek ML *et al.* Toxoplasmosis nach Knochenmarktransplantation. *Immun Infekt* 1986; **14**: 183-187.
9. Ackerman ZVI, Reuven OR, Maayan S. Cerebral toxoplasmosis complicating bone marrow transplantation. *Isr J Med Sci* 1986; **22**: 582-586.
10. Fisher MA, Levy J, Helfrich M *et al.* Detection of *Toxoplasma gondii* in the spinal fluid of a bone marrow transplant recipient. *Pediatr Infect Dis* 1987; **6**: 81-83.
11. Candolfi E, Derouin I, Kien T. Detection of circulating antigens in immunocompromised patients during reactivation of chronic toxoplasmosis. *Eur J Clin Microbiol* 1987; **6**: 44-48.



12. Knapen van F, Panggabean SO, Leusden van J. Evaluation of laboratory diagnosis of toxoplasmosis by means of an ELISA-triple test. *Antonie van Leeuwenhoek* 1986; **52**: 5-13.
13. Van Loon AM, Van der Logt JTM, Heessen FWA, Van der Veen J. Enzyme-linked immunosorbent assay that uses labeled antigen for detection of immunoglobulin M and A antibodies in toxoplasmosis: comparison with indirect immunofluorescence and double-sandwich enzyme-linked immunosorbent assay. *J Clin Microbiol* 1983; **17**: 997-1004.
14. Sharma SD, Mullenax J, Araujo FG, Erhlich HA, Remington JS. Western blot analysis of the antigens of *Toxoplasma gondii* recognized by human IgM and IgG antibodies. *J Immunol* 1983; **131**: 977-983.
15. Brooks RG, Sharma SD, Remington JS. Detection of *Toxoplasma gondii* antigens by a dot-immunobinding technique. *J Clin Microbiol* 1985; **21**: 113-116.
16. Knapen van F, Panggabean SO, Leusden van J. Demonstration of toxoplasma antigen containing complexes in active toxoplasmosis. *J Clin Microbiol* 1985; **22**: 645-650.
17. Witherspoon RP, Storb R, Ochs H *et al.* Recovery of antibody production in human allogeneic marrow graft recipients: influence of time post-transplantation, the presence or absence of chronic graft-versus-host-disease, and antithymocyte globulin treatment. *Blood* 1981; **58**: 360-368.
18. Hirsch S. In: Rubin RH and Young LS, Eds. *Clinical approach to infection in the compromised host*. New York: Plenum; 1981.
19. Nguyen BT, Stadtsbaeder S. Comparative effects of cotrimoxazole (trimethoprim-sulphamethoxazole) and spiramycin in pregnant mice infected with *Toxoplasma gondii* (Beverly strain). *Br J Pharmacol* 1985; **3**: 713-716.
20. Remington JS, Gentry LO. Acquired toxoplasmosis: infection versus disease. *Ann NY Acad Sci* 1970; **174**: 1006-1017.
21. Luna MA, Lichtiger B. Disseminated toxoplasmosis and cytomegalovirus infection complicating Hodgkin's disease. *Am J Clin Pathol* 1971; **55**: 499-505.
22. Gleason TH, Hamlin WB. Disseminated toxoplasmosis in the compromised host. A report of five cases. *Arch Intern Med* 1974; **134**: 1059-1062.
23. Ruskin J, Remington JS. Toxoplasmosis in the compromised host. *Ann Intern Med* 1976; **84**: 193-199.
24. Hakes Th B, Armstrong C. Toxoplasmosis: Problems in diagnosis and treatment. *Cancer* 1983; **52**: 1535-1540.
25. Elkin Ch M, Leon E, Grenell SL, Leeds NE. Intracranial lesion in the acquired immunodeficiency syndrome. Radiologica (computed tomographic) features. *JAMA* 1985; **253**: 393-396.
26. Holliman RE. Toxoplasmosis and the acquired immune deficiency syndrome. *J Infect* 1988; **16**: 121-128.
27. Gratama JW, Middeldorp JM, Sinnige LGF *et al.* Cytomegalovirus immunity in allogeneic marrow grafting. *Transplantation* 1985; **40**: 510-515.
28. Araujo FG, Remington JS. Antigenemia in recently acquired acute toxoplasmosis. *J Infect Dis* 1980; **141**: 144-150.