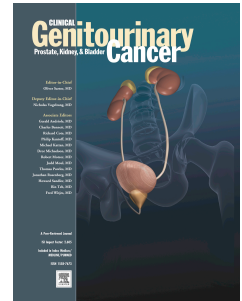


Accepted Manuscript

Acquired Haemophilia Caused by Ureteral Tumour

Csaba Berczi, M.D., Ph.D, Katalin Razso, M.D., Peter Osvath, M.D., Zoltan Boda, M.D.,Ph.D., Tibor Flasko, M.D., Ph.D.



PII: S1558-7673(15)00120-2

DOI: [10.1016/j.clgc.2015.05.006](https://doi.org/10.1016/j.clgc.2015.05.006)

Reference: CLGC 417

To appear in: *Clinical Genitourinary Cancer*

Received Date: 30 March 2015

Revised Date: 21 May 2015

Accepted Date: 29 May 2015

Please cite this article as: Berczi C, Razso K, Osvath P, Boda Z, Flasko T, Acquired Haemophilia Caused by Ureteral Tumour, *Clinical Genitourinary Cancer* (2015), doi: 10.1016/j.clgc.2015.05.006.

This is a PDF file of an unedited manuscript that has been accepted for publication. As a service to our customers we are providing this early version of the manuscript. The manuscript will undergo copyediting, typesetting, and review of the resulting proof before it is published in its final form. Please note that during the production process errors may be discovered which could affect the content, and all legal disclaimers that apply to the journal pertain.

Acquired Haemophilia Caused by Ureteral Tumour

Csaba Berczi M.D., Ph.D.¹, Katalin Razso M.D.², Peter Osvath M.D.¹, Zoltan Boda
M.D., Ph.D.², Tibor Flasko M.D., Ph.D.¹

¹Department of Urology, University of Debrecen, Hungary,

²Department of Medicine, University of Debrecen, Hungary

Corresponding author: Csaba Berczi M.D., Ph.D.

Department of Urology, University of Debrecen

Nagyerdei str. 98, Debrecen, Hungary, H-4032

E-mail: berczi@med.unideb.hu

Fax: + 36 52 255256

Clinical Practice Points

The acquired haemophilia is a rather rare and life-threatening disease. In some cases the acquired haemophilia develops as a paraneoplastic syndrome of different malignancies. Acquired haemophilia caused by ureteral tumour has not been reported previously.

The treatment of acquired haemophilia has two main goals. First, to achieve haemostasis during the bleeding period, and second, to decrease the risk of bleeding by eradication of the inhibitor.

Our patient had haematuria caused by ureteral tumour. Nephroureterectomy was performed, but following the operation continuous bleeding was observed. Due to this we administered blood transfusions and performed reoperations, but we couldn't stop the bleeding.

Later we realised that the prolonged activated partial thromboplastin time was caused by the low activity of factor VIII (2%), which proved acquired haemophilia.

For this reason we administered activated prothrombin complex concentrate and recombinant activated factor VII. Three months after the initial operation, an immune-tolerance induction treatment was administered, after which the activity of factor VIII reverted normal.

Key words: ureteral tumour, acquired haemophilia, factor VIII deficiency

Introduction

Acquired (anti-body) haemophilia is a rather rare and often lethal illness. The main feature of the clinical picture is that anti-bodies are formed against one of the coagulation factors, most often against factor VIII, which neutralizes the function of the clotting factors¹⁻³.

The incidence of acquired haemophilia is 0.2-1.48 cases/ million/year. The mortality rate of the disease is high and varies between 8 and 44%^{2,4-6}. Death generally occurs within a few weeks due to bleeding.

In this publication we report the case of acquired factor VIII haemophilia caused by ureteral tumour and review the literature. To the best of our knowledge acquired haemophilia caused by ureteral tumour has not been published previously.

Case report

Our 54-year-old female patient's case history includes appendectomy, tonsillectomy and conization. She was not a known haemophiliac and had no family history of haemophilia.

The patient had renal pain on the right side, and recurrent hematuria, which started 2 months earlier. Urological examinations revealed an ureteral tumour in the right ureter, which caused stasis in the kidney. Based on these results an ureteronephrectomy was performed on the right side using the transperitoneal approach. The histology showed urothelial papillary carcinoma pT1 Grade II.

Before the operation the patient's Hb level was 9.4 g/dl, activated partial thromboplastin time (APTT): 64.9 s. A blood test showed a platelet count 397 G/L, an INR of 0.93, a prothrombin time of 7.8 seconds, and a thrombin time of 17.4 seconds. As a result of her bleeding tumour she was given multiple blood transfusions and fresh frozen plasma before the operation.

After the operation, the patient continued bleeding profusely from the wounds, and consequently received blood transfusions and fresh frozen plasma on several occasions.

By the 5th post-operative day the patient's hemoglobin level had dropped to 6.9 g/dl, and ultrasound showed an 8x3 cm sized haematoma in the kidney bed and some free fluid in the Douglas cavity. For this reason an urgent surgical exploration was done, with no source of bleeding found, however a diffuse bloody leakage was observed in the abdomen.

Between the initial operation and the 2nd reoperation she was given 8 units of blood transfusion and 4 units of fresh frozen plasma.

Due to the continuous bleeding and the isolated APTT extension a mixing test was performed, but the APTT was still prolonged. Thereafter we ruled out the presence of lupus anticoagulant and determined the activity of the coagulation factors. The result, by the 6th postoperative day showed acquired haemophilia. Factor VIII activity was 2 % (normal value: 60-150 %).

Consequently activated prothrombin complex concentrate (Factor VIII inhibitor bypassing activity agent – FEIBA - 100 Unit/kg every 12 hours) was administered. As a result of this treatment bleeding from the wound practically ceased. Her haemoglobin level varied between 10.2 to 12.4 g/dl. However, on the 12th postoperative day the patient suddenly developed shock for which treatment was given. The patient`s hemoglobin level decreased to 7.9 g/dl, while ultrasound showed free abdominal fluid and haematomas.

Urgent reoperation was again performed on the same day. During the operation a significant quantity of blood was found in the abdomen and removed. The source of bleeding had no surgical origin.

As a result, the patient received a treatment of recombinant activated factor VII (dose: 90 ug/kg/2 hours). She became stable with no further bleeding tendencies.

One month after the nephroureterectomy APTT was 87.9 s and factor VIII activity was under 1 %.

Three months after the nephroureterectomy the patient received an immune-tolerance induction treatment for her acquired anti-body haemophilia, in accordance with the Budapest Protocol (consisting of human factor VIII concentrate, cyclophosphamide and methylprednisolone)⁷ .

A month later, the laboratory control tests showed APTT at 38.4 s and factor VIII activity at 71% (normal range: 60-150%). The administered immune-tolerance induction treatment to

eradicate the anti-body proved effective, as the involved clotting factor activity became normal.

ACCEPTED MANUSCRIPT

Discussion

Acquired haemophilia is a very rare illness associated with a high mortality rate due to the life-threatening bleeding condition which does not respond to conventional treatment.

In approximately 10% of the cases there is a tumour in the background of acquired haemophilia. These malignancies can be both haematological and solid tumours^{1-3,8-10}.

Amongst acquired haemophilia related to solid tumours the most common ones are lung and prostate cancers, which are each present in 25% of the cases^{2,3}.

To the best of our knowledge, acquired haemophilia caused by ureteral tumour has not been reported in the literature.

Acquired haemophilia can occur either before the diagnosis of tumor or after the surgery².

During the diagnosis of the most common acquired haemophilia, when anti-body is produced against factor VIII, a rise in the activated partial thromboplastin time (APTT) isolated expansion can be detected, which cannot be corrected by giving fresh frozen plasma.

A mixing test combining the patient's plasma with a normal plasma will show whether the prolonged APTT is the result of an intrinsic factor deficiency or an inhibitor (Figure 1). If a clotting factor inhibitor is suspected, the sample mixture should be incubated at 37 °C for at least one hour, since inhibitors are generally dependent on both time and temperature.

If the APTT normalized during the mixing test, an deficiency of clotting factor is the cause. If the APTT shows failure to correct, first the role of lupus anticoagulant has to be excluded, thereafter the FVIII activity and the inhibitor titer should be determined.

Our patient had a normal prothrombin time, and thrombin time, with the platelet level being in the normal range. Her factor VIII activity is low.

The treatment of acquired haemophilia has two main goals. First, to achieve haemostasis during the bleeding period, and second, to reduce the risk of bleeding by eradication of the inhibitor^{1,2,6,8,9}.

To achieve the required haemostasis we can either increase the level of factor VIII or use an agent that bypasses the intrinsic coagulation pathway.

The routinely administered bypassing agents are activated prothrombin complex concentrate (FEIBA) and recombinant factor VIIa.

Due to the fact that bleeding can occur at any time while the antibodies are present, it is generally accepted that eradication of the inhibitors is necessary in acquired haemophilia.

To eradicate the anti-body immunosuppressive drugs (prednisolone, cyclophosphamide, cyclosporine, immunoglobulin, vincristin, mycophenolate, azathioprin) can be used, in addition to applying monoclonal antibody, plasmapheresis, immunadsorption, and immune-tolerance therapy⁹.

Conclusion

In the present case, the acquired antibody haemophilia caused by ureteral tumour was diagnosed in a the postoperative period. The patient suffered from serious, lethal bleeding, necessitating management with blood transfusions, fresh frozen plasma, and including two reoperations. After the diagnosis of acquired haemophilia, activated prothrombin complex concentrate and recombinant factor VIIa treatment were applied, which helped achieve

appropriate haemostasis. Acquired haemophilia due to ureteral tumour has not been reported previously.

In conclusion, acquired haemophilia caused by malignancies is very rare but life-threatening. Based on this case, when the patient has bleeding which does not respond to conventional treatment and the APTT shows isolated extension we have to think of acquired haemophilia.

Legend for Figure

Figure 1. Algorithm for the diagnosis and treatment of acquired haemophilia

BC: blood count, APTT: activated partial thromboplastin time, PT: prothrombin time, TT: thrombin time

Disclosure

The authors have no relevant conflict of interest to disclose.

References

1. Escobar MA. Bleeding in the patient with a malignancy: is it an acquired factor VIII inhibitor? *Cancer*. 2012;118:312-20.
2. Reeves BN, Key NS. Acquired hemophilia in malignancy. *Thromb Res*. 2012;129 Suppl 1:S66-8.
3. Sallah S, Wan JY. Inhibitors against factor VIII in patients with cancer. Analysis of 41 patients. *Cancer*. 2001;91:1067-74.
4. Ichikawa S, Kohata K, Okitsu Y, Suzuki M, Nakajima S, Yamada MF, Onishi Y, Yamamoto J, Suzuki S, Ishizawa K, Kameoka J, Harigae H. Acquired hemophilia A with sigmoid colon cancer: successful treatment with rituximab followed by sigmoidectomy. *Int J Hematol*. 2009;90:33-6.
5. Murray NP, Moncada JC, Moran M. Duodenal tumor presenting as acquired hemophilia in an 88-year-old woman: a clinical case and review of the literature. *Case Rep Gastrointest Med*. 2012;2012:203801.
6. Shetty S, Bhawe M, Ghosh K. Acquired hemophilia a: diagnosis, aetiology, clinical spectrum and treatment options. *Autoimmun Rev*. 2011;10:311-6.
7. Nemes L, Pitlik E. New protocol for immune tolerance induction in acquired hemophilia. *Haematologica* 2000;85 (10 Suppl) 64-8.

8. Ferre A, Arlet JB, Darnige L, Dupeux S, Pouchot J. Acquired hemophilia as the presenting manifestation of neoplasia: diagnostic workup and monitoring. *Rev Med Interne*. 2009;30:630-3.
9. Franchini M, Targher G, Manzato F, Lippi G. Acquired factor VIII inhibitors in oncohematology: a systematic review. *Crit Rev Oncol Hematol*. 2008;66:194-9.
10. Kremyanskaya M, Aledort L. Acquired hemophilia: we now see it with myeloproliferative neoplasms. *Am J Hematol*. 2001;86:329-30.

Figure 1. Algorithm for the diagnosis and treatment of acquired haemophilia

