

Accepted Manuscript

Phenotype and Genotype in 103 patients with Tricho-Rhino-Phalangeal Syndrome

Saskia M. Maas, Adam C. Shaw, Hennie Bikker, Hermann-Josef Lüdecke, Karin van der Tuin, Magdalena Badura-Stronka, Elga Belligni, Maria Teresa Bonati, Daniel R. Carvalho, JanMaarten Cobben, Stella A. de Man, Nicolette S. Den Hollander, Nataliya Di Donato, Livia Garavelli, Sabine Grønberg, Johanna C. Herkert, A. Jeannette M. Hoogeboom, Aleksander Jamsheer, Anna Latos-Bielenska, Anneke Maat-Kievit, Cinzia Magnani, Carlo Marcelis, Inge B. Mathijssen, Maartje Nielsen, Ellen Otten, Lilian B. Ousager, Jacek Pilch, Astrid Plomp, Gemma Poke, Anna Poluha, Renata Posmyk, Claudine Rieubland, Margarita Silengo, Marleen Simon, Elisabeth Steichen, Connie Stumpel, Katalin Szakszon, Jenneke van den Ende, Antony van der Steen, Ton van Essen, Arie van Haeringen, Johanna M. van Hagen, Joke B.G.M. Verheij, Marcel M. Mannens, Dr Raoul C. Hennekam



PII: S1769-7212(15)00059-2

DOI: [10.1016/j.ejmg.2015.03.002](https://doi.org/10.1016/j.ejmg.2015.03.002)

Reference: EJMG 3032

To appear in: *European Journal of Medical Genetics*

Received Date: 4 February 2015

Accepted Date: 8 March 2015

Please cite this article as: S.M. Maas, A.C. Shaw, H. Bikker, H.-J. Lüdecke, K. van der Tuin, M. Badura-Stronka, E. Belligni, M.T. Bonati, D.R. Carvalho, J. Cobben, S.A. de Man, N.S. Den Hollander, N. Di Donato, L. Garavelli, S. Grønberg, J.C. Herkert, A.J.M. Hoogeboom, A. Jamsheer, A. Latos-Bielenska, A. Maat-Kievit, C. Magnani, C. Marcelis, I.B. Mathijssen, M. Nielsen, E. Otten, L.B. Ousager, J. Pilch, A. Plomp, G. Poke, A. Poluha, R. Posmyk, C. Rieubland, M. Silengo, M. Simon, E. Steichen, C. Stumpel, K. Szakszon, J. van den Ende, A. van der Steen, T. van Essen, A. van Haeringen, J.M. van Hagen, J.B.G.M. Verheij, M.M. Mannens, R.C. Hennekam, Phenotype and Genotype in 103 patients with Tricho-Rhino-Phalangeal Syndrome, *European Journal of Medical Genetics* (2015), doi: 10.1016/j.ejmg.2015.03.002.

This is a PDF file of an unedited manuscript that has been accepted for publication. As a service to our customers we are providing this early version of the manuscript. The manuscript will undergo

copyediting, typesetting, and review of the resulting proof before it is published in its final form. Please note that during the production process errors may be discovered which could affect the content, and all legal disclaimers that apply to the journal pertain.

Phenotype and Genotype in 103 patients with Tricho-Rhino-Phalangeal Syndrome

Saskia M. Maas¹, Adam C. Shaw², Hennie Bikker³, Hermann-Josef Lüdecke⁴, Karin van der Tuin⁵, Magdalena Badura-Stronka⁶, Elga Belligni⁷, Maria Teresa Bonati⁸, Daniel R Carvalho⁹, JanMaarten Cobben¹, Stella A. de Man¹⁰, Nicolette S. Den Hollander⁵, Nataliya Di Donato¹¹, Livia Garavelli¹², Sabine Grønberg¹³, Johanna C. Herkert¹⁴, A. Jeannette M. Hoozeboom¹⁵, Aleksander Jamsheer⁶, Anna Latos-Bielenska⁶, Anneke Maat-Kievit¹⁵, Cinzia Magnani¹⁶, Carlo Marcelis¹⁷, Inge B. Mathijssen³, Maartje Nielsen⁵, Ellen Otten¹⁴, Lilian B Ousager¹⁸, Jacek Pilch¹⁹, Astrid Plomp³, Gemma Poke²⁰, Anna Poluha²¹, Renata Posmyk²², Claudine Rieubland²³, Margarita Silengo⁷, Marleen Simon¹⁵, Elisabeth Steichen²⁴, Connie Stumpel²⁵, Katalin Szakszon²⁶, Jenneke van den Ende²⁷, Antony van der Steen²⁸, Ton van Essen¹⁴, Arie van Haeringen⁵, Johanna M. van Hagen²⁹, Joke B.G.M. Verheij¹⁴, Marcel M. Mannens³, Raoul C. Hennekam^{1,3}

¹ Department of Paediatrics, Academic Medical Centre, Amsterdam, Netherlands

² Department of Clinical Genetics, Guy's & St Thomas' Hospitals, London, United Kingdom

³ Department of Clinical Genetics, Academic Medical Centre Amsterdam, The Netherlands

⁴ Institut für Humangenetik, Universitätsklinikum, Essen, Germany

⁵ Department of Clinical Genetics, Leiden University Medical Centre, Leiden, The Netherlands

⁶ Department of Medical Genetics, Poznan University of Medical Genetics, and NZOZ Centre for Medical Genetics GENESIS, Poznań, Poland

⁷ Università di Torino, Dipartimento di Scienze della Sanità Pubblica e Pediatriche, Torino, Italy

⁸ Istituto Auxologico Italiano, IRCCS, Milano, Italy

⁹ Genetic Unit, SARA Network of Rehabilitation Hospitals, Brasilia, Brazil.

¹⁰ Department of Paediatrics, Amphia Hospital, Breda, The Netherlands

¹¹ Institut für Klinische Genetik, TU Dresden, Dresden, Germany

¹² Clinical Genetics Unit, Obstetric and Paediatric Department, IRCCS, Arcispedale Santa Maria Nuova, Reggio Emilia, Italy

¹³ Department of Clinical Genetics, Centre for Rare Diseases, Juliane Marie Centre, Copenhagen University Hospital Rigshospitalet, Denmark

¹⁴ University of Groningen, University Medical Centre Groningen, Department of Genetics, Groningen, The Netherlands

¹⁵ Department of Clinical Genetics, Erasmus MC, University Medical Centre Rotterdam, The Netherlands

- ¹⁶ Neonatal Intensive Care Unit, Obstetric and Paediatric Department, University Hospital, Parma, Italy
- ¹⁷ Department of Genetics Radboud University Medical Centre, Nijmegen, the Netherlands
- ¹⁸ Department of Clinical Genetics, Odense University Hospital, Odense, Denmark
- ¹⁹ Department of Paediatrics and Developmental Age Neurology, School of Medicine in Katowice, Medical University of Silesia, Katowice, Poland
- ²⁰ Genetic Health Service NZ, Wellington, New Zealand
- ²¹ Department of Medical Genetics, Lublin, Poland
- ²² Podlaskie Centre of Clinical Genetics, Bialystok and Department of Perinatology, Medical University in Bialystok, Bialystok, Poland
- ²³ Division of Human Genetics, Department of Paediatrics, Inselspital, University of Bern, Bern, Switzerland
- ²⁴ Department of Paediatrics, Medical University of Innsbruck, Innsbruck, Austria
- ²⁵ Department of Clinical Genetics and School for Oncology and Developmental Biology (GROW), Maastricht UMC+, Maastricht, the Netherlands
- ²⁶ Department of Paediatrics, Faculty of Medicine, University of Debrecen, Debrecen, Hungary
- ²⁷ Centre of Medical Genetics, University Hospital Antwerp, Antwerp, Belgium
- ²⁸ Maritime Medical Genetics Service, Halifax, Nova Scotia, Canada
- ²⁹ Department of Clinical Genetics, VU University Medical Centre, Amsterdam, The Netherlands

Running title: Overview of TRP

Correspondence to: Dr RC Hennekam, Department of Paediatrics, Room H7-236, AMC, Meibergdreef 9, 1105 AZ Amsterdam, Netherlands. Phone +31 20 566 8844. E-mail r.c.hennekam@amc.uva.nl

Tricho-rhino-phalangeal syndrome (TRPS) is characterized by craniofacial and skeletal abnormalities, and subdivided in TRPS I, caused by mutations in *TRPS1*, and TRPS II, caused by a contiguous gene deletion affecting (amongst others) *TRPS1* and *EXT1*. We performed a collaborative international study to delineate phenotype, natural history, variability, and genotype - phenotype correlations in more detail.

We gathered information on 103 cytogenetically or molecularly confirmed affected individuals. TRPS I was present in 85 individuals (22 missense mutations, 62 other mutations), TRPS II in 14, and in 5 it remained uncertain whether *TRPS1* was partially or completely deleted.

Main features defining the facial phenotype include fine and sparse hair, thick and broad eyebrows, especially the medial portion, a broad nasal ridge and tip, underdeveloped nasal alae, and a broad columella. The facial manifestations in patients with TRPS I and TRPS II do not show a significant difference. In the limbs the main findings are short hands and feet, hypermobility, and a tendency for isolated metacarpals and metatarsals to be shortened. Nails of fingers and toes are typically thin and dystrophic. The radiological hallmark are the cone-shaped epiphyses and in TRPS II multiple exostoses. Osteopenia is common in both, as is reduced linear growth, both prenatally and postnatally.

Variability for all findings, also within a single family, can be marked.

Morbidity mostly concerns joint problems, manifesting in increased or decreased mobility, pain and in a minority an increased fracture rate. The hips can be markedly affected at a (very) young age.

Intellectual disability is uncommon in TRPS I and, if present, usually mild. In TRPS II intellectual disability is present in most but not all, and again typically mild to moderate in severity.

Missense mutations are located exclusively in exon 6 and 7 of *TRPS1*. Other mutations are located anywhere in exons 4-7. Whole gene deletions are common but have variable breakpoints. Most of the phenotype in patients with TRPS II is explained by the deletion of *TRPS1* and *EXT1*, but haploinsufficiency of *RAD21* is also likely to contribute. Genotype-phenotype studies showed that mutations located in exon 6 may have somewhat more pronounced facial characteristics and more marked shortening of hands and feet compared to mutations located elsewhere in *TRPS1*, but numbers are too small to allow firm conclusions.

Keywords: tricho-rhino-phalangeal syndrome; TRPS; Langer-Giedion syndrome; *TRPS1*; multiple exostoses; *EXT1*; *RAD21*; natural history; genotype; phenotype; review

INTRODUCTION

The first description of individuals with sparse hair, an unusual face predominantly in the shape of the nose, and anomalies of the distal limbs was published by the Dutch physician Van der Werff ten Bosch in 1959 [Van der Werff ten Bosch 1959]. Other early possible descriptions may have been those of Keizer and Schilder [1951], Klingmüller [1956], and Alé and Caló [1961]. In 1966 Andres Giedion reported several individuals with this constellation of manifestations of whom one male had in addition, multiple exostoses and intellectual disability [Giedion, 1966]. He suggested naming the entity tricho-rhino-phalangeal syndrome (TRPS). Leonard Langer [Langer, 1969] described almost simultaneously with Robert Gorlin and co-workers [Gorlin et al., 1969] affected individuals who also had developmental delay and multiple exostoses. Hall and co-workers [Hall et al., 1974] suggested subdivision of TRPS into TRPS I (OMIM 190350) for individuals with normal development and absent exostoses, and TRPS II or Langer-Giedion syndrome (OMIM 150230) for those with intellectual disability and exostoses.

The identification of an interstitial deletion involving chromosome 8q24 in an individual with TRPS II [Bühler et al., 1984] and subsequently a balanced translocation involving 8q24.1 in two individuals with TRPS I [Marchau et al., 1993] were the first steps in the localisation of the entities. In 2000 mutations in the zinc finger transcription factor *TRPS1* were described in TRPS I [Momeni et al., 2000]. TRPS II was proposed as a contiguous gene deletion syndrome involving both *TRPS1* and the gene for multiple hereditary exostoses *EXT1* [Bühler et al, 1987; Lüdecke et al., 1995]. The rare recurrences of TRPS in sibs of healthy parents [Hussels 1971; Jüngst and Spranger, 1976; Van Neste and Dumortier, 1982] is most likely explained by germ-line or somatic mosaicism.

Some authors have proposed another subtype, TRPS III (OMIM 190351), associated with more marked growth impairment and shortening of fingers and toes [Niikawa and Kamei, 1986]. The differences between TRPS I and TRPS III are small, and may merely represent a spectrum of severity with some evidence of a genotype-phenotype correlation for specific mutations in *TRPS1* [Lüdecke et al., 2001].

There are only limited data available on genotype – phenotype correlations. The study by Lüdecke and co-workers on 51 unrelated TRPS patients in which they were able to detect 35 different mutations in 44 patients is the most informative one [Lüdecke et al., 2001]. A recent review of the (sparse) literature on adults with this syndrome, including one of the first patients described by Giedion, is also very useful [Schinzel et al., 2013]. Here we report on a series of 103 individuals with TRPS gathered through an international collaborative study. We present data on the major clinical

manifestations, natural history, interfamilial and intra-familial variability, and genotype - phenotype correlations.

PATIENTS AND METHODS

Acquisition and Phenotype

We asked all physicians attending the 2013 European Course on Dysmorphology, and their local colleagues, to send us clinical information of all TRPS patients known to them. We used a dedicated questionnaire to retrieve data. To these data we added the data from an earlier study of all individuals with TRPS known to the UK TRPS Support group, performed 2007-2010 by two of us (ACS; RCH). Available clinical pictures and X-rays of all affected individuals were obtained. These were scored independently by the first (SMM) and senior author (RCH). In case of discrepancies the differences were discussed until consensus was reached. In case a clinical feature could not be scored reliably from available pictures it was not scored at all. Data were stored in Excel.

Genotype

The genotype was obtained either from literature if patients had been published [Rocha Carvalho et al., 2011; Schinzel et al., 2013; Chen et al., 2013; Plaza-Benhumea et al., 2014], or the referring clinician. In the majority of patients, DNA had been analysed at the University Hospital in Essen, Germany (HJL). A number of laboratories and various techniques had been used including FISH (single probe or series of probes), MLPA and Sanger sequencing. Due to the variable methodologies used, the annotation of the breakpoints of some deletions remain approximate. If the genotype was unknown, *TRPS1* was analysed by the molecular genetics diagnostic laboratory of the Academic Medical Centre in Amsterdam (HB) using standard Sanger sequencing. Annotation was according to reference sequence NM_014112.4. We grouped mutations into three categories: those with deletions encompassing *TRPS1* completely, those with missense mutations, and those with other mutations such as frameshift mutations, nonsense mutations, and intragenic deletions. In 5 individuals a deletion was proven but the size of the deletion remained uncertain and it could not be excluded the whole gene was deleted. In the tabulations and discussions these were not included in one of the subgroups but were included in the total group.

RESULTS

We present the results of studies in 103 patients including ninety-six patients that have not been published before, and seven that have been published [Rocha Carvalho et al., 2011; Schinzel et al., 2013; Chen et al., 2013; Plaza-Benhumea et al., 2014]. The clinical data are presented in Tables I-IV and illustrated in Figs. 1-9 and 11. The genotypes are summarized in Table V and illustrated in Fig.10. We provide figures both for the TRPS I patients with missense mutations, those with all other causes of TRPS I, TRPS II patients with whole gene deletions, and all TRPS cases together. In the text we mention only these data that are not presented in the tables or figures .

Phenotype

The general phenotype is easily recognisable from Table III and Figs. 1-8. An unusually blond hair colour, mentioned several times in the literature, is difficult to validate as data on familiar hair colour were not collected. The broadening and sometimes also thickening of the eyebrows is typically limited to the median one-third. In some the median part of the eyebrows is normally formed while the middle and distal part are underdeveloped. Four patients have a broad chin with a horizontal crease.

Growth, development, and natural history

Linear growth is decreased in almost all patients, both prenatally and postnatally, and falls below the third centile in half of the adult patients. The percentage of TRPS I individuals with intellectual disability is similar to that in the general population, but mild to moderate intellectual disability occurs in two-third of the TRPS II patients. Delay in motor development is usually associated with hip dysplasia and therefore likely to be secondary.

Seizures are uncommon, and consist of febrile convulsions in childhood and grand mal seizures in a small number of adult TRPS II patients. Myopia is by far the most frequent vision disturbance in all groups but in total visual disturbances are not common. Infrequently, hypermetropia, astigmatism, optic disc atrophy and strabismus are reported. In one patient stenosis of the lacrimal ducts needed surgery.

Hearing impairment is common but mild in all patients, and is frequently secondary to serous otitis media. Dental overcrowding is commonly reported, and a small number of patients report delayed eruption of the primary dentition. Microdontia is also reported albeit infrequently.

Cardiac abnormalities are more common than in the general population, are variable in all groups of TRPS patients, and range from minor anomalies such as persistent ductus arteriosus, persistent

foramen ovale, bicuspid aortic valve, and mitral valve prolapse/regurgitation, to more significant problems such as aortic stenosis, anomalous pulmonary venous return and left heart insufficiency. A single TRPS I patient reports WPW syndrome, another TRPS I patient grade 2 AV block, and a TRPS II patient has a dilated aortic root. Respiratory problems consist mainly of recurrent upper and lower airway infections in the TRPS II patients. In TRPS I patients, both with missense mutations and other genotypes, the most frequent complaint is asthmatic bronchitis, occurring in 12 patients. There is one child and one adult with obstructive sleep apnoea. Infections in TRPS II patients are limited to the airways, and in TRPS I patients also recurrent cystitis is noted in 7 patients. No patient reports include data on investigations for immunological disturbances. Gastro-oesophageal reflux is more commonly described in TRPS II patients and is also present in adults. Renal problems are uncommon, and if present consist of hydronephrosis, unilateral underdeveloped kidney, and vesico-ureteral reflux. One patient developed nephrolithiasis. In the present group one patient has a history of imperforate hymen and severe vaginal stenosis, another has bicornuate uterus.

The most significant morbidity in the present cohort is related to the joints, including increased or decreased mobility, joint pain and an increased fracture rate in some. Pain most commonly affects hips and distal extremities, but other joints are affected at lower frequencies. Complaints led to joint replacement (shoulder, knees, finger) in 4 individuals. Hip dysplasia is documented in childhood in some, but puberty or early adulthood is more common. Hip replacement had been done as early as 33 years of age. Joint hypermobility is not only frequent but can also be marked. Indeed several patients were referred because of the hypermobility. All reported fractures occur after puberty. One TRPS II patient has hemivertebrae, another has a large cystic-like lucency affecting one humerus. A single case has a duplicated thumb. Dislocation of the patella is reported, but in only one individual the patella is considered small. Radial and/or ulnar deviation of fingers is very common. A single patient has cutaneous syndactyly between the first and second toe, and in two patients there is cutaneous syndactyly between the second and third toe. The X-ray findings mirror these clinical findings. Four patients have pectus carinatum, three have pectus excavatum, and four have an umbilical hernia. The cone-shaped epiphyses are mostly detected in the medial phalanx of the second finger, and next in the medial phalanx of the fifth finger. However, the variation, also within a family, is significant and cone-shape epiphyses may also be confined to the proximal phalanges. They are much more common in finger phalanges compared to toe phalanges. Likely due to the dysplasia of the epiphyses the length of the phalanges and metacarpals/metatarsals can change considerably. Exostoses occur exclusively in TRPS II

patients (Fig. 9). Numbers vary from a few to >200, and localisation is as typically seen in multiple exostoses (OMIM #133700).

Three patients have a past history of cancer (thyroid cancer in one, mamma carcinoma in another, unspecified in the third). Hyperthyroidism is reported in two individuals. In three patients an unusually deep voice is noted. A single patient has a history bipolar affective disorder, and another an anxiety disorder. In a single TRPS II patient polymicrogyria was detected at MRI of the brain with associated delayed myelination, small callosal body, and dilated ventricles. A single patient has lymphedema, another growth hormone deficiency necessitating replacement therapy, one has dyspraxia, one a spinal cord injury leading to spastic paresis of the lower limbs, one an arterio-venous malformation of the left middle cerebral artery, one a epidermoid cyst of a buttock, one cyclic vomiting starting in early infancy, and two have systemic lupus erythematosus. In 10 patients across all TRPS types, an apparent premature aging of the skin is reported.

Genotype

Most of the mutations are nonsense and frameshift mutations which can be located anywhere in exons 4-7 of the gene (Table V; Fig. 10). The size of the deletions vary considerably and there are no common breakpoints. Missense mutations occur exclusively in exons 6 and 7 with the vast majority in exon 6. The number of recurrent mutations is very low (Table V).

We evaluated whether the sites of mutations within the gene correlates with the main findings of TRPS, by comparing the frequency of signs and symptoms and the exon involved. There is no difference in frequency or degree of intellectual disability depending on the site of the mutation, and also growth and joint involvement is similar across the various mutation sites. There is a tendency for facial manifestations, especially eyebrow signs, to be more marked in mutations located in exon 6 compared to mutations located elsewhere, and also shortening of metacarpal and metatarsal bones is somewhat more pronounced when a mutation is located in exon 6. This is irrespective of the type of mutation. Data have to be evaluated with care however as numbers were small and no statistically significant conclusions could be drawn. Apparent associations may in fact only be coincidence as well.

DISCUSSION

The summary of the clinical data of this cohort and exact figures for signs and symptoms of TRPSI and II are presented in the Tables. These data are summarised below to provide a description of the general features of TRPS in the present series.

We do stress here that patient acquisition was through physicians who provided data on TRPS individuals referred to them because of complaints. It is likely this has caused a bias towards individuals with more marked manifestations of TRPS. It may well be that a population survey would allow recognition of TRPS in individuals with much less marked symptomatology. Therefore the summary below may not be valid for the total group of individuals with TRPS. Still we hope it will provide some information to affected individuals, their families, and caregivers regarding manifestations and natural history of TRPS, and provides initial guidance for optimal care.

Growth

Impaired growth is common in TRPS, especially in the deletion patients, but it is not universally expressed. It is more marked postnatally than prenatally. Adult patients with nonsense/frameshift mutations are slightly smaller than those with missense mutations but neither group are as small as patients with TRPSII deletions who all fall below the -2SD. It has been hypothesized that this is related to the role of TRPS1 as regulator of histone deacetylation. Indeed, loss of *trps1* in mice leads to an increased proportion of cells arrested in mitosis [Wuelling et al., 2014]. Body weight is usually normal in relation to height. Head circumference is typically normal throughout life, except for those with a genomic deletion in whom in one-third head circumference falls below the 3rd percentile. Growth hormone studies have yielded variable results, as was the reaction in growth of growth hormone therapy [Merjaneh et al., 2014].

Development

If all TRPS individuals are taken together cognition is mentioned to be mild to moderately delayed in ~15%. In the group of individuals with missense mutations the frequency is similar to that in the general population, in the group of other mutations it seems slightly elevated. There may be a bias however, in favour of reporting a developmental delay or learning difficulty, and so cognitive ability in TRPS I could be normal. A single member of the cohort with TRPS I has severe developmental delay, but there were additional environmental factors unrelated to TRPS I to explain this. In the deletion group there is a clear increased rate of intellectual disability. This is mirrored in the age at which motor milestones are reached

and first words are spoken. The developmental delay in TRPS II does not correlate with the size of the deleted segment in the present study group, as has been reported before [Schinzel et al., 2013].

Natural history

The main long-term morbidity associated with TRPS are the early osteoarthritis-like changes affecting the large joints, especially the hips, leading to pain and decreased mobility from adolescence or early adulthood. Radiological features include joint dysplasia, sclerotic bone and reduced joint space. Not infrequently a hip prosthesis is implanted as early as at 30 years of age. Such prostheses will require revision (possibly more than once) due to their limited lifespan. Obtaining functional improvement through prosthetic joint surgery can be challenging due to longstanding adaptation and disordered anatomy elsewhere. Mobility problems in the small joints, especially hands, occur typically at a somewhat later age, usually evident in decreased mobility and pain. Due to location and nature of the complaints they can be mistaken for rheumatoid arthritis. Cardiac and respiratory problems are not common, although asthmatic bronchitis may be more frequent than expected. Problems with other internal organs are occasionally seen. Vision and hearing disturbances are not more frequently disturbed than in the general population.

Face

The facial characteristics in TRPS I and II are very similar. There are slight differences between the various groups in Table 2 but these become mainly clear in the relative frequency of manifestations: in an individual patient it will usually be impossible to make a distinction based on facial characteristics only. The most characteristic facial sign in TRPS is the shape and size of the nose (Fig. 3): it is large, with a somewhat broad ridge but especially a broad tip, underdeveloped alae, and in some a very broad septum that is hardly seen in the general population or other disorders. The philtrum is long and featureless. Patients with missense mutations seem to have a long philtrum less often. The thin upper vermilion becomes especially evident when the patient smiles: there is typically a horizontal smile, reported in the majority of the patients, and resembling the smile in Floating-Harbor syndrome (Nikkel et al., 2013). The resemblance with the latter becomes even more marked as the shape of the nose between these two syndromes look alike. Micrognathia is not common. Large and prominent ears can be present but most presently reported individuals had a normal ear shape (Fig. 5).

Hair and nails

Almost all patients have fine hair that is also sparse from young age on (Fig. 1). Especially the fronto-temporal areas become early sparsely implanted or completely bald. The hair can also be brittle and grows slowly. One-third of male patients lose their hair completely or almost completely at or soon after puberty. There are also TRPS individuals with only mild sparseness and hair growth and implantation can also improve with time. In women sparseness is typically less marked. Main manifestation in adult females is a high frontal hairline. Hair colour is frequently light but the present data cannot confirm whether this is more frequent than expected. The eyebrows are typically densely implanted (thick) and broad (Fig. 2). Broad eyebrows are more common in individuals with TRPS II compared to the other TRPS groups. There can be a marked difference within the various parts of an eyebrow: the medial part is almost invariably more densely implanted and broader than the middle or lateral parts. This difference in density and broadness is present when the middle and lateral part seem normally formed but also when these are more sparse and thin.

Nails are thin and dystrophic in about half of all TRPS individuals. This is typically more frequent in the nails of the toes compared to the finger nails.

Limbs

Short hands and feet are common in all types of TRPS (Figs. 6-7). In the present groups the brachydactyly and shortening of the metacarpals and metatarsals was more common in the TRPS I individuals with a missense mutation. The shortening can be either of single metacarpal or metatarsal, which most commonly are the 4th and 5th but also not infrequently the 2nd rays, but also all metacarpals and metatarsals can be involved. The variation within a family can be significant (Fig. 11). Indeed the marked shortening of all metacarpals and metatarsals, earlier reported to constitute a separate type of TRPS [Niikawa and Kamei, 1986] can be seen in one family member while another has only mild shortening of some metacarpals and metatarsals, confirming the earlier suggestion that the so-called TRPS III in fact is a marked form of TRPS I [Lüdecke et al., 2001].

In the present series one published patient [Carvalho et al., 2011] has TRPS II and tibial hemimelia caused by a deletion of 8q23.1q24.12. Two other patients with TRPS II and tibial hemimelia have been published [Stevens and Moore, 1999; Turleau et al., 1982]. It has been suggested that a gene causing tibial hemimelia may be located near *TRPS1*, and *EXT1*, which is sustained that limb anomalies consisting of tibial hemimelia and other abnormalities is located on the mouse homologous chromosome region of 9A1-A4 [Stevens and Moore, 1999].

Radiologic findings

Almost all patients have cone-shaped epiphyses, which can be detected also at an early age when epiphyses are just being formed. They are most frequently present in the middle phalanges but also in the proximal phalanges but to a lesser extent in the distal phalanges (Fig. 8). They can be symmetrical or asymmetrical on both sides, and there is not necessarily a correlation between the existence of cone-shaped epiphyses in the hands and feet. Due to the abnormal shape of the epiphyses the more distal bone parts can be in an abnormal position, which causes the radiological (and clinical) deviation to the ulnar or radial side.

Osteopenia may be present in all TRPS types, but is likely more common in TRPS II individuals. TRPS1 has been shown to bind through a GATA binding sequence in the proximal promoter of the osteocalcin gene, suggesting a role in osteoblast differentiation and possibly a mechanism leading to osteopenia in TRPS individuals [Piscopo et al., 2009].

As can be expected exostoses are only present in individuals with a deletion that extends to *EXT1* (Fig. 9). They can be present from the first month of life but some patients may not present the first exostosis until six years of age. The problems caused by exostoses are the same as in isolated inherited multiple exostoses [Hennekam 1991]. Joint dysplasia can be found at almost any joint but is by far most common in the hips and fingers. Clinical differentiation of the findings from rheumatoid arthritis can be difficult.

Variability within families

It is well known that TRPS can vary within families, even between MZ twins [Giedion et al., 1973; Naselli et al., 1998; Schinzel et al., 2013]. In the present series there are several families with multiple affected family members in whom this variability is mirrored (Fig. 11). The variability is present in all findings, both with respect to face morphology, ectodermal signs, growth, and clinical and radiological limb findings. In some family members recognition of TRPS may have been difficult if the proband or other affected family members would not have been available for comparison. Intra-familial variability as described here and in the literature [Giedion et al., 1973; Schinzel et al., 2013] forms further evidence that TRPS III represents one extreme of the clinical spectrum of TRPS I. In the present series no individual has been recognized to harbour a mutation in *TRPS1* without showing any sign. As not all relatives of individuals with TRPS have been evaluated systematically for the presence of the mutation in the proband we cannot be sure non-penetrance does not occur at all, but present data indicate it must at least be low.

Genotypes

The variation in *TRPS1* mutations causing TRPS I is considerable. The location of missense mutations is limited to mainly exon 6 and sometimes exon 7 and of all other mutations to exon 4 to 7. A clear genotype – phenotype correlation was not present except for the obvious difference in occurrence of multiple exostoses and more marked intellectual disability in individuals with TRPS II. It may be that the more marked intellectual disability can be explained by the deletion of *RAD21* in these patients. If the facial characteristics of such TRPS II individuals are compared to the characteristics of the Cornelia de Lange –like syndrome that can be caused by mutations in *RAD21*, a resemblance is often clear. The possible more marked facial and distal limb manifestations in individuals with mutations in exon 6 compared to other exons remains uncertain at present.

In literature several patients have been published as having TRPS II but without deletion of *TRPS1* [Pereza et al., 2012; McBrien et al., 2008, Wuyts et al., 2002]. We re-evaluated the findings in these patients and question the diagnosis TRPS in all of these. It seems more likely the phenotype in these patients is explained by deletion of both *EXT1* and *RAD21* (located between *TRPS1* and *EXT1*), which gives rise to a phenotype that resembles Cornelia de Lange syndrome [Deardorff et al., 2012; Chen et al., 2013; Ansari et al., 2014].

Conclusions

This study presents the data of the largest group of individuals with TRPS published to date. The cardinal characteristics of TRPS are present in both patients with intragenic mutations and those with deletions of the whole gene. Differences between these two groups are limited except for the presence of multiple exostoses and level of cognitive functioning. The most notable diagnostic features are fine and/or sparse hair, the thickness and broadness of the medial part of the eyebrows compared to the remaining parts, the thickening of the columella, and the markedly variable shortening of metacarpal and metatarsal bones. Radiologically the cone-shaped epiphyses remain a hallmark. The natural history is dominated by the joint problems consisting of hypermobility and of the consequences of early osteoarthritis, mostly of the hips, but also of other large joints and the hands, and causing significant pain, disability and decreased mobility. Intellectual disability is not common and only mild to moderate if present, except in the individuals with TRPS II where it is much more common but not universal. No clear genotype-phenotype correlation was detectable in this cohort except for the exostoses and intellectual disability frequency in individuals with whole gene deletions. TRPS can vary within a family for all clinical findings.

REFERENCES

Alé G, Caló S. On a case of peripheral dysostosis associated with multiple osteogenic exostoses, dysuniform and dysharmonic hyposomia] (original in Italian). *Ann Radiol Diagn (Bologna)* 1961;34:376-385.

Ansari M, Poke G, Ferry Q, Williamson K, Aldridge R, Meynert AM, Bengani H, Chan CY, Kayserili H, Avci S, Hennekam RC, Lampe AK, Redeker E, Homfray T, Ross A, Falkenberg Smeland M, Mansour S, Parker MJ, Cook JA, Splitt M, Fisher RB, Fryer A, Magee AC, Wilkie A, Barnicoat A, Brady AF, Cooper NS, Mercer C, Deshpande C, Bennett CP, Pilz DT, Ruddy D, Cilliers D, Johnson DS, Josifova D, Rosser E, Thompson EM, Wakeling E, Kinning E, Stewart F, Flinter F, Girisha KM, Cox H, Firth HV, Kingston H, Wee JS, Hurst JA, Clayton-Smith J, Tolmie J, Vogt J, Tatton-Brown K, Chandler K, Prescott K, Wilson L, Behnam M, McEntagart M, Davidson R, Lynch SA, Sisodiya S, Mehta SG, McKee SA, Mohammed S, Holden S, Park SM, Holder SE, Harrison V, McConnell V, Lam WK, Green AJ, Donnai D, Bitner-Glindzicz M, Donnelly DE, Nellåker C, Taylor MS, FitzPatrick DR. Genetic heterogeneity in Cornelia de Lange syndrome (CdLS) and CdLS-like phenotypes with observed and predicted levels of mosaicism. *J Med Genet* 2014;51:659-668.

Bühler EM, Malik NJ. The tricho-rhino-phalangeal syndrome(s): Chromosome 8 long arm deletion: Is there a shortest region of overlap between reported cases? TRP I and TRP II syndromes: Are they separate entities? *Am J Med Genet* 1984;19:113-119.

Bühler EM, Bühler UK, Beutler C, Fessler R. A final word on the tricho-rhino-phalangeal syndromes. *Clin Genet* 1987;31:273-275.

Carvalho DR, Santos SC, Oliveira MD, Speck-Martins CE. Tibial hemimelia in Langer-Giedion syndrome with 8q23.1-q24.12 interstitial deletion. *Am J Med Genet* 2011;155A:2784-2787.

Chen CP, Lin SP, Liu YP, Chern SR, Wu PS, Su JW, Chen YT, Lee CC, Wang W. An interstitial deletion of 8q23.3-q24.22 associated with Langer-Giedion syndrome, Cornelia de Lange syndrome and epilepsy. *Gene* 2013;529:176-180.

Deardorff MA, Wilde JJ, Albrecht M, Dickinson E, Tennstedt S, Braunholz D, Mönnich M, Yan Y, Xu W, Gil-Rodríguez MC, Clark D, Hakonarson H, Halbach S, Michelis LD, Rampuria A, Rossier E, Spranger S, Van Maldergem L, Lynch SA, Gillessen-Kaesbach G, Lüdecke HJ, Ramsay RG, McKay MJ, Krantz ID, Xu H, Horsfield JA, Kaiser FJ. RAD21 mutations cause a human cohesinopathy. *Am J Hum Genet* 2012;90:1014-1027.

Giedion A. Das tricho-rhino-phalangeale Syndrom. *Helv Paediatr Acta* 1966;21:475-485.

Giedion A, Burdea M, Fruchter Z, Meloni T, Trosc V. Autosomal dominant transmission of the tricho-rhino-phalangeal syndrome. Report of 4 unrelated families, review of 60 cases. *Helv Paediatr Acta* 1973;28:249-259.

Gorlin RJ, Cohen MM Jr, Wolfson J. Tricho-rhino-phalangeal syndrome. *Am J Dis Child* 1969;118:595-599.

Hall BD, Langer LO, Giedion A, Smith DW, Cohen MM jr, Beals RK, Brandner M. Langer-Giedion syndrome. *Birth Defects OAS* 1974;10(12): 147-164.

Hennekam RC. Hereditary multiple exostoses. *J Med Genet* 1991;28:262-266.

Hussels I. Trichorhinophalangeal syndrome in two sibs. *Birth Defects OAS* 1971;7:301-302.

Jüngst BK, Spranger J. Ballonierende Mitralklappe bei Tricho-rhino-phalangealem Syndrom. *Monatsschr Kinderheilkd* 1976;124:538-541.

Keizer DP, Schilder JH. Ectodermal dysplasia, achondroplasia, and congenital morbus cordis. *Am J Dis Child* 1951;82:341-344.

Klingmüller G. Über eigentümliche Konstitutions-Anomalien der zwei Schwestern und ihre Beziehungen zu neueren Entwicklungspathologischen Befunden. *Hautarzt* 1956;7:105-113.

Langer LO Jr. The thoracic-pelvic-phalangeal dystrophy. *Birth Defects OAS* 1969;5(4):55-64.

Lüdecke HJ, Wagner MJ, Nardmann J, La Pillo B, Parrish JE, Willens PJ, Huan EA, Frydman M, Hamers GJH, Wells DE, Horsthemke B. Localization of the genes involved in the Langer-Giedion syndrome. *Hum Mol Genet* 1995;4:31-36.

Lüdecke HJ, Schaper J, Meinecke P, Momeni P, Gross S, von Holtum D, Hirche H, Abramowicz MJ, Albrecht B, Apacik C, Christern HJ, Claussen U, Devriendt K, Fastnacht E, Forderer A, Friedrich U, Goodship THJ, Greiwe M, Hamm H, Hennekam RCM, Hinkel GK, Hoeltzenbein M, Kayserli H, Majewski F, Mathieu M, McLeod R, Midro AT, Moog U, Nagai T, Niikawa N, Ørstavik KH, Plöchl E, Seitz C, Schmidtke J, Tranebjaerg L, Tsukahara M, Wittwer B, Zabel B, Gillessen-Kaesbach G, Horsthemke B. Genotypic and phenotypic spectrum in tricho-rhino-phalangeal syndrome types I and III. *Am J Hum Genet* 2001;68:81-91.

Marchau FE, van Roy BC, Parizel PM, Lambert JR, DeCanck I, Leroy JG, Gevaert CM, Willems PJ, Dumon JE. Tricho-rhino-phalangeal syndrome type I (TRPS I) due to an apparently balanced translocation involving 8q24. *Am J Med Genet* 1993;45:450-455.

McBrien J, Crolla JA, Huang S, Kelleher J, Gleeson J, Lynch SA. Further case of microdeletion of 8q24 with phenotype overlapping Langer-Giedion without TRPS1 deletion. *Am J Med Genet* 2008;146A:1587-1592.

Merjaneh L, Parks JS, Muir AB, Fadoju D. A novel TRPS1 gene mutation causing trichorhinophalangeal syndrome with growth hormone responsive short stature: a case report and review of the literature. *Int J Pediatr Endocrinol* 2014;1:16.

Momeni P, Glöckner G, Schmidt O, von Holtum D, Albrecht B, Gillessen-Kaesbach G, Hennekam R, Meinecke P, Zabel B, Rosenthal A, Horsthemke B, Lüdecke H-J. Mutations in a new gene, encoding a zinc-finger protein, cause tricho-rhino-phalangeal syndrome type I. *Nat Genet* 2000;24:71-74.

Naselli A, Vignolo M, Di Battista E, Papale V, Aicardi G, Becchetti S, Tomà P. Trichorhinophalangeal syndrome type I in monozygotic twins discordant for hip pathology. Report on the morphological evolution of cone-shaped epiphysis and the unusual pattern of skeletal maturation. *Pediatr Radiol* 1998;28:851-855.

Niikawa N, Kamei T. The Sugio-Kajii syndrome, proposed tricho-rhino-phalangeal syndrome type III. *Am J Med Genet* 1986;24:759-760.

Nikkel SM, Dauber A, de Munnik S, Connolly M, Hood RL, Caluseriu O, Hurst J, Kini U, Nowaczyk MJ, Afenjar A, Albrecht B, Allanson JE, Balestri P, Ben-Omran T, Brancati F, Cordeiro I, da Cunha BS, Delaney LA, Destrée A, Fitzpatrick D, Forzano F, Ghali N, Gillies G, Harwood K, Hendriks YM, Héron D, Hoischen A, Honey EM, Hoefsloot LH, Ibrahim J, Jacob CM, Kant SG, Kim CA, Kirk EP, Knoers NV, Lacombe D, Lee C, Lo IF, Lucas LS, Mari F, Mericq V, Moilanen JS, Møller ST, Moortgat S, Pilz DT, Pope K, Price S, Renieri A, Sá J, Schoots J, Silveira EL, Simon ME, Slavotinek A, Temple IK, van der Burgt I, de Vries BB, Weisfeld-Adams JD, Whiteford ML, Wierczorek D, Wit JM, Yee CF, Beaulieu CL; FORGE Canada Consortium, White SM, Bulman DE, Bongers E, Brunner H, Feingold M, Boycott KM. The phenotype of Floating-Harbor syndrome: clinical characterization of 52 individuals with mutations in exon 34 of SRCAP. *Orphanet J Rare Dis* 2013;8:63.

Plaza-Benhumea L, Valdes-Miranda JM, Toral-López J, Pérez-Cabrera A, Cuevas-Covarubias S. Trichorhinophalangeal syndrome type II due to a novel 8q23.3-q24.12 deletion associated with imperforate hymen and vaginal stenosis. *Br J Dermatol* 2014;171:1581-1583.

Pereza N, Severinski S, Ostojic S, Volk M, Maver A, Dekanic KB, Kapovic M, Peterlin B. Third case of 8q23.3-q24.13 deletion in a patient with Langer-Giedion syndrome phenotype without TRPS1 gene deletion. *Am J Med Genet* 2012;158A:659-663.

Piscopo DM, Johansen EB, Derynck R. Identification of the GATA factor TRPS1 as a repressor of the osteocalcin promoter. *J Biol Chem* 2009;284:31690-31703.

Rocha Carvalho D, Lima Santos SC, Oliviera MDV, Speck-Martins CE. Tibial hemimelia in Langer-Giedion syndrome with 8q23.1-q24.12 interstitial deletion. *Am J Med Genet* 2011;155A:2784-2787.

Schinzel A, Riegel M, Baumer A, Superti-Furga A, Moreira LMA, Santo LDE, Schiper PP, Dantas Carvalho JH, Giedion A. Long-term follow-up of four patients with Langer-Giedion syndrome: Clinical course and complications. *Am J Med Genet* 2013;161A: 2216-2225.

Stevens CA, Moore CA. Tibial hemimelia in Langer-Giedion syndrome—possible gene location for tibial hemimelia at 8q. *Am J Med Genet* 1999;85:409-412.

Turleau C, Chavin-Colin F, de Grouchy J, Maroteaux P, Rivera H. Langer-Giedion syndrome with and without del 8q. Assignment of critical region to 8q23. *Hum Genet* 1982;62:183-187.

Van der Werff ten Bosch JJ. The syndrome of brachymetacarpal dwarfism [“pseudo-pseudo-hypoparathyroidism”] with and without gonadal dysgenesis. *Lancet* 1959;1:69-71.

Van Neste D, Dumortier M. Tricho-rhino-phalangeal syndrome. Disturbed geometric relationship between hair matrix and dermal papilla in scalp hair bulbs. *Dermatologica* 1982;165:16-23.

Wuelling M, Pasdziernik M, Moll CN, Thiesen AM, Schneider S, Johannes C, Vortkamp A. The multi zinc-finger protein TRPS1 acts as a regulator of histone deacetylation during mitosis. *Cell Cycle* 2013;12:2219-2232.

Wuyts W, Roland D, Lüdecke HJ, Wauters J, Foulon M, Van Heul W, Van Maldergem L. Multiple exostoses, mental retardation, and brain abnormalities in a boy with a de novo 8q24 submicroscopic interstitial deletion. *Am J Med Genet* 2002;113:326-32.

Legends

Table I. Table I. Growth and development in 103 patients with TRPS.

Table II. Somatic problems in 103 patients with TRPS.

Table III. Phenotype in 103 patients with TRPS.

Table IV. Radiological findings in 103 patients with TRPS.

Table V. Genotype in 103 patients with TRPS.

Fig. 1. Phenotype in TRPS. Hair. A. Children. Note the variation in fine and sparsely implanted hair, and high anterior hair line. B. Adults. Note the fine hair, alopecia in some individuals (mainly males) but decrease in sparseness of hair in others (mainly females). The anterior hairline is invariably high.

Fig. 2. Phenotype in TRPS. Eyebrow. Note the sometimes marked broadening of eyebrows, with sparse implantation in some but dense implantation in others. Except in the latter individuals there is a difference between the median one-third of the eyebrows compared to the latter two-third.

Fig. 3. Phenotype in TRPS. Nose. Note the broad nasal tip and in some also abroad nasal ridge, but absence of broadening of the nasal bridge. The alae nasi are invariably underdeveloped which seems more marked in some individuals who have a low hanging columella as well. The columella can be extremely wide. The philtrum is long and indistinct.

Fig. 4. Phenotype in TRPS. Dentition. Note irregular implantation of usually normally shaped and sized teeth, but retained primary teeth and abnormal shape in others.

Fig. 5. Phenotype in TRPS. Ear. The ears are frequently large, and vary from normally shaped to overfolded helices to more marked malformed ears.

Fig. 6. Phenotype in TRPS. Hand. Note variability in shortening of the metacarpal bones, also between the hands of a single individual. Also individual metacarpals can be much more shortened than the others. Fingers can be ulnar and radially deviated.

Fig. 7. Phenotype in TRPS. Foot. Note variably shortening of metatarsals, which can be limited to a single tarsal bone. Some of the depicted nails are dystrophic.

Fig. 8. Phenotype in TRPS. Radiology of the distal limbs. Note cone-shaped epiphyses that are most common in the middle phalanx of the second digit, but can be present everywhere. Some radiographs show marked osteopenia.

Fig. 9. Phenotype in TRPS. Multiple exostoses. Note that locations of visible exostoses are as in isolated multiple exostoses, i.e. mainly at sites with little tissue between bone and skin. Radiological characteristics are also similar to isolated multiple exostoses.

Fig. 10. Genotype in 103 individuals with TRPS. Mutations occurring in more than a single individual are shown only once. Frameshift mutations are in blue, splice site mutations in brown, and missense mutations in black. The extension of the whole gene deletions to either site is not indicated as exact data were frequently lacking. Annotation according to reference sequence NM_014112.4.

Fig. 11. Phenotype in TRPS. Intra-familial variability in three generations.

Table I. Growth and development in 103 patients with TRPS.

	All	TRPSI missense mutations	TRPSI other mutations	TRPSII deletions whole gene
	n = 103*	n = 22	n = 62	n = 14
<i>Gender (M : F)</i>	37/66	8/14	20/42	9/5
Mean age at last clinical evaluation	22.4 (1-74)	24.6 (1-73)	22.2 (1.5-67)	19.2 (4-65)
Mean paternal age at birth (n=30)	28.4 (19-44)	29 (19-38)	28 (21-44)	29.6 (21-41)
Mean maternal age at birth (n=30)	27.1 (20-37)	31 (27-35)	26,9 (20-37)	26.7 (20-32)
<i>Growth at birth</i> ^{1,2}				
Length (cm)	48.8/49 (40.5-54)	49.9/50 (48-52)	47.5/49 (40.5-53)	48/45.8 (44-54)
Length at birth <-2SD	8/34	0/8	4/16	4/7
Length at birth >+2SD	2/34	0/8	0/16	2/7
Weight (g) ¹	3162/3280 (2440-4500)	3385/3290 (2800-4500)	3269/3316 (2500-4000)	3051/3100 (2440-3840)
Weight <-2SD (%)	8/68 (11)	0/15	7/43	1/7
Head circumference (cm)	34 / 33.5 (32-37)	34.4 / 34.5 (32-36.5)	35.3 / 35 (34-37)	33.6 / 33.3 (32-36)
Head circumference <-2SD	1/19	0/4	0/7	1/6
<i>Postnatal Growth</i> ¹				
Stature <-2SD adult male	15/22	4/6	6/11	5/5
Height (cm) adult male	158.3/158.9(138.5-173)	161.4/159,8 (153-171)	159.4/164.5 (139-173)	148.4/146.5 (138.5-157)
Stature <-2 SD adult female	22/44	10/10	10/31	2/2
Height (cm) adult female	153.4/155 (142-167)	151/151.5 (142-157)	155.2/155.8 (145-167)	149.5-149.5 (149-150)
Weight <-2SD (adults)	6/63	0/12	3/34	3/13
Head circumference adult male (cm)	56.1/56 (49-59)	57.5/57.5 (56-59)	56.3/55.3 (54-59)	54.5/55 (49-59)
Head circumference adult female (cm)	54.3/54.5 (48-57.5)	54.6/55 (52-57)	55/54.7 (52-57.5)	50/50 (48-52)
Head circumference <-2SD	6/69	2/14	0/47	3/6
<i>Development</i>				
Sitting age (months) ¹	8.9/8 (4-24)	8.6/8 (6-13)	9.1/8 (4-24)	9.3/9 (6-12)
Walking age (months) ¹	17.7/16 (9-72)	17.3/16,5 (8.5-24)	16.8/15 (9-42)	26.5/21 (14-72)
First words (months) ¹	16/13.5 (5-36)	19.5/19 (7-36)	14,9/12 (7-26)	16.8/15.5 (12-28)
Speech therapy	7/25	2/6	3/17	2/4
ID-mild vs moderate vs severe ³	11-2-1 (85)	1-0-0 (17)	5-0-1 (54)	5-2-0 (11)

* includes five patients in whom exact nature of the mutations could not be determined and were not categorised in the three groups

¹ mean / median; between brackets range

² Only neonates born between 38-42 weeks were considered: weight: n= 28; length n=11; head circumference n=3

³ Mild : IQ 50-69; moderate: IQ 35-49; Severe IQ <35 (IQ levels are estimates as formal testing has often not been performed); numbers between brackets: number of individuals with reliable data on cognitive functioning

Table II. Somatic problems in 103 patients with TRPS.

	All	TRPSI missense mutations	TRPSI other mutations	TRPSII deletions whole gene
	n = 103 (%) [*]	n = 22	n = 62	n = 14
Somatic problems				
Seizures	8/94 (9)	1/18	2/56	4/13
Vision impairment	34/88 (39)	8/16	20/53	3/12
Hearing impairment	10/89 (11)	1/15	4/54	4/13
Dental overcrowding	48/71 (68)	11/14	26/40	6/10
Congenital cardiac anomaly	14/91 (15)	3/18	7/53	4/13
Respiratory problems	23/87 (26)	6/17	13/56	4/9
Frequent infections	37/88 (42)	6/18	23/52	5/11
Gastro-Oesophageal Reflux	11/83 (13)	3/15	2/53	4/9
Constipation	8/86 (9)	4/18	2/52	1/10
Renal anomaly	9/80 (11)	2/15	4/49	1/9
Menorrhagia ¹	6/33 (18)	2/8	3/21	0/1
Metrorrhagia ¹	1/20 (5)	0/4	0/13	0/1
Cryptorchidism	6/30 (20)	2/5	2/19	2/7
Fractures (range in number)	20/87 (23)	5/18 (1-3)	13/51 (1-more>5)	2/10 (both 1)
Mobility joints abnormal	38/63 (60)	7/11	21/38	8/9
Joint pains	22/34 (65)	7/9	12/20	3/5
Mobility (meters unaided); restricted	6/23 (26)	3/4	1/15	2/3
Hip surgery	7/65 (11)	2/15	2/35	2/10
Other joint/tendon surgery	18/93 (19)	3/18	10/59	3/11
Cancer	3/90 (3)	1/17	2/53	0/14
Premature aging	10/25 (40)	1/4	6/17	1/2

* includes five patients in whom exact nature of the mutations could not be determined and were not categorised in the three groups

¹ only females >16 years of age

Table III. Phenotype in 103 patients with TRPS.

	All	TRPSI missense mutations	TRPSI other mutations	TRPSII deletions whole gene
	n = 103 (%)*	n = 22	n = 62	n = 14
Craniofacial				
Fine hair	90/96 (94)	20/21	55/58	12/13
Sparse hair	84/100 (84)	19/22	51/59	9/14
Depigmented hair	24/87 (28)	7/20	13/52	2/10
Eyebrows thick	27/93 (29)	7/20	13/57	7/13
Eyebrows broad	62/96 (65)	14/21	30/58	14/14
Large nose	82/97 (85)	20/22	50/58	8/13
Broad nasal septum	90/94 (96)	19/20	56/58	11/11
Broad nasal tip	99/102 (97)	21/22	59/61	14/14
Underdeveloped nasal alae	86/95 (91)	20/21	50/56	12/13
Long philtrum	92/102 (90)	15/22	59/61	13/13
Deep philtrum	18/95 (19)	2/21	7/55	6/14
Thin upper vermillion	80/99 (81)	16/21	51/59	10/14
Horizontal smile	64/76 (84)	14/16	38/43	7/10
Narrow palate	44/62 (71)	9/17	24/30	7/10
Micrognathia	23/100 (23)	3/21	11/61	7/14
Large ears	27/95 (28)	5/20	11/57	9/14
Prominent ears	31/96 (32)	5/20	14/59	10/13
Limbs				
Short metacarpals	58/93 (62)	20/21	28/56	7/12
Brachydactyly	65/99 (66)	22/22	33/61	7/12
Polydactyly	1/99 (1)	0/22	0/61	1/12
Dislocated patellae	9/64 (14)	2/15	3/37	1/8
Short feet	38/65 (58)	13/17	19/36	6/11
Short metatarsals	34/58 (59)	13/16	19/37	2/5
Dystrophic nails				
fingers	36/92 (39)	15/22	14/57	5/10
toes	41/71 (58)	14/18	19/43	6/8
Leg length discrepancy	10/45 (22)	1/10	4/28	5/6
Trunk				
Winged scapulae	17/58 (32)	4/14	6/33	4/8
Scoliosis	30/93 (32)	7/20	13/55	7/13
Small mammae	4/15 (36)	0/6	1/6	1/1

* includes five patients in whom exact nature of the mutations could not be determined and were not categorised in the three groups

Table IV. Radiological findings in 103 patients with TRPS.

	All	TRPSI missense mutations	TRPSI other mutations	TRPSII deletions whole gene
	n = 103 (%) [*]	n = 22	n = 62	n = 14
Cone shaped epiphysis	58/60 (97)	14/14	30/30	9/11
Fingers	37	10	23	3
Toes	15	5	9	1
Osteopenia	11/44 (25)	2/9	4/25	5/8
Exostoses	12/85 (14)	0/15	0/52	11/14
Exostoses, first noticed (months) ¹	33/28 (1-72)			27/36 (1-72)
Coxa plana	8/15 (53)	1/3	3/7	3/4
Hip dysplasia (u/b) ²	18/38 (47)	4/5 (1/1)	6/21 (1/2)	7/8 (1/2)
Other joint dysplasia	9/28 (32)	4/9	5/15	0/3

* includes five patients in whom exact nature of the mutations could not be determined and were not categorised in the three groups

¹ mean / median; between brackets range

² u=unilateral; b=bilateral

Table V. Genotype in 103 patients with TRPS#.

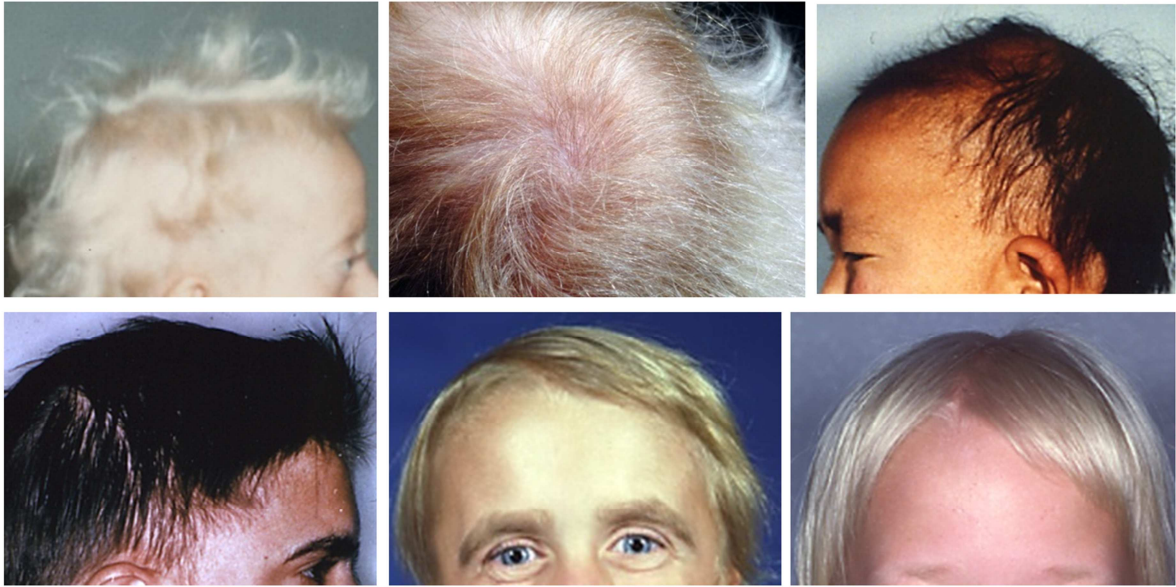<i>Exon</i>	<i>deletion EXT1</i>	<i>nucleotide change</i>	<i>amino acid change</i>	<i>type of mutation</i>	<i>number of index patients</i>
2- 6	-	c.1-?_c.2700+?	-	deletion	1
4	-	c.1010_1014dup	p.(Cys339Glnfs*27	frameshift	1
4	-	c.1093C>T	p.(Gln365*)	nonsense	1
4	-	c.1105C>T	p.(Gln369*)	nonsense	1
4	-	c.1176dup	p.(Asn393*)	nonsense	3
4	-	c.1231dup	p.(Gln411Profs*11)	frameshift	1
4	-	c.1460del	p.Lys487Serfs*13	frameshift	1
4	-	c.1630C>T	p.(Arg544*)	nonsense	3
4	-	c.1870C>T	p.(Arg624*)	nonsense	2
4	-	c.1882C>T	p.(Gln628*)	nonsense	1
4	-	c.2094C>A	p.(Tyr698*)	nonsense	1
5	-	c.2097-?_c.2700+?dup	?	?	1
5	-	c.2097-?_c.2700+?del	?	?	2
5	-	c.2179_2180del	p.(Val727Serfs*29)	frameshift	1
5	-	c.2355_2356del	p.(Lys786Glyfs*14)	frameshift	1
5	-	c.2394dup	p.(Ser799Glnfs2)	frameshift	1
5	-	c.2557C>T	p.(Arg853*)	nonsense	1
6+7	-	c.2701-?_3885+?del	?	?	2
6	-	c.2731A>T	p.(Asn911Tyr)	missense	1
6	-	c.2732A>G	p.(Asn911Ser)	missense	1
6	-	c.2756T>C	p.(Leu919Pro)	missense	1
6	-	c.2761 C>T	p.(Arg921*)	nonsense	2
6	-	c.2762G>C	p.(Arg921Pro)	missense	3
6	-	c.2762G>A	p.(Arg921Gln)	missense	2
6	-	c.2783_2784insC	p.(Val929Cysfs*22)	frameshift	1
6	-	c.2794G>A	p.(Ala932Thr)	missense	2
6	-	c.2795C>T	p.(Ala932Val)	missense	2
6	-	c.2801G>T	p.(Gly934Val)	missense	1
intron 6	-	c.2823+1G>T	?	?	1
intron 6	-	c.2824-23T>G	?	?	1
7+?	-	c.2824-?_3885+?del	?	?	1
7	-	c.2852_2859dup	p.(Gly954Lysfs*43)	frameshift	1
7	-	c.2942-2945del	p.(Glu994Glyfs*7)	frameshift	1
7	-	c.2893C>T	p.(Arg965Cys)	missense	2
7	-	c.2894G>A	p.(Arg965His)	missense	1
7	-	c.3077del	p.(Ser1026Thrfs*27)	frameshift	1
7	-	c.3140del	p.(Pro1047Leufs*6)	frameshift	1
7	-	c.3424del	p.(Ser1142Valfs*36)	frameshift	1
?	-	inv(8)(q13q24.1)	?	?	1
?	-	inv(8)(q21.1q24.1)	?	?	1

deletion 1-7	-	deletion 8q23.1-q23.3 (7.52 Mb)	1
deletion 1-7	-	deletion 8q23.1-q23.3 (109,381,001-117,488,105)(hg18)	1
deletion 1-7	(-)*	"Whole TRPS1 deletion"	1
deletion 1-7	(+)**	detected by FISH analysis	1
deletion 1-7	(-)*	detected by FISH analysis	1
deletion	(+)**	deletion of one probe for LGS in MLPA P245	2
deletion 1-7	+	deletion chr 8:108,448,738-121,747,270 (hg19)	1
deletion 1-7	+	deletion chr8:108,700,000-120,800,000 (hg19)	1
deletion 1-7	+	deletion chr8:113,858,753-119,323,017 (hg19)	1
deletion 1-7	+	deletion chr8:114,255,657-134,634,824 (hg19)	1
deletion 1-7	+	deletion 8q23.3-q24.1 (6.16 Mb)	2
deletion 1-7	+	deletion 8q23.3-q24.12 (7.7 Mb)	1
deletion 1-7	+	deletion chr8:116,002,879-121,241,253 (6,43Mb) (hg19)	1
deletion 1-7	+	deletion chr8:116,493,571-120,223,875 (3,7 Mb) (hg19)	1

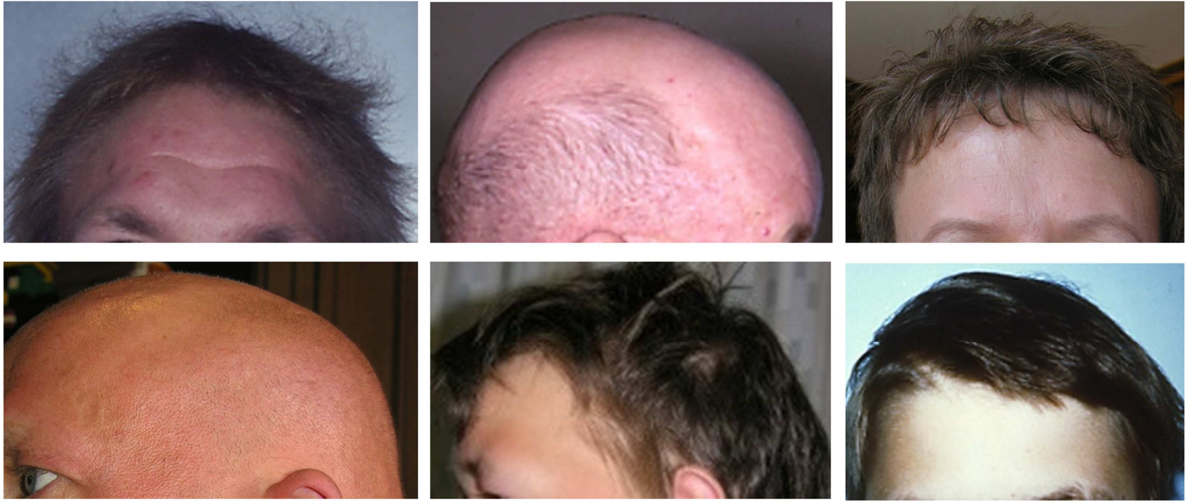Annotation according to reference sequence NM_014112.4

* insufficient molecular information but clinically no exostoses

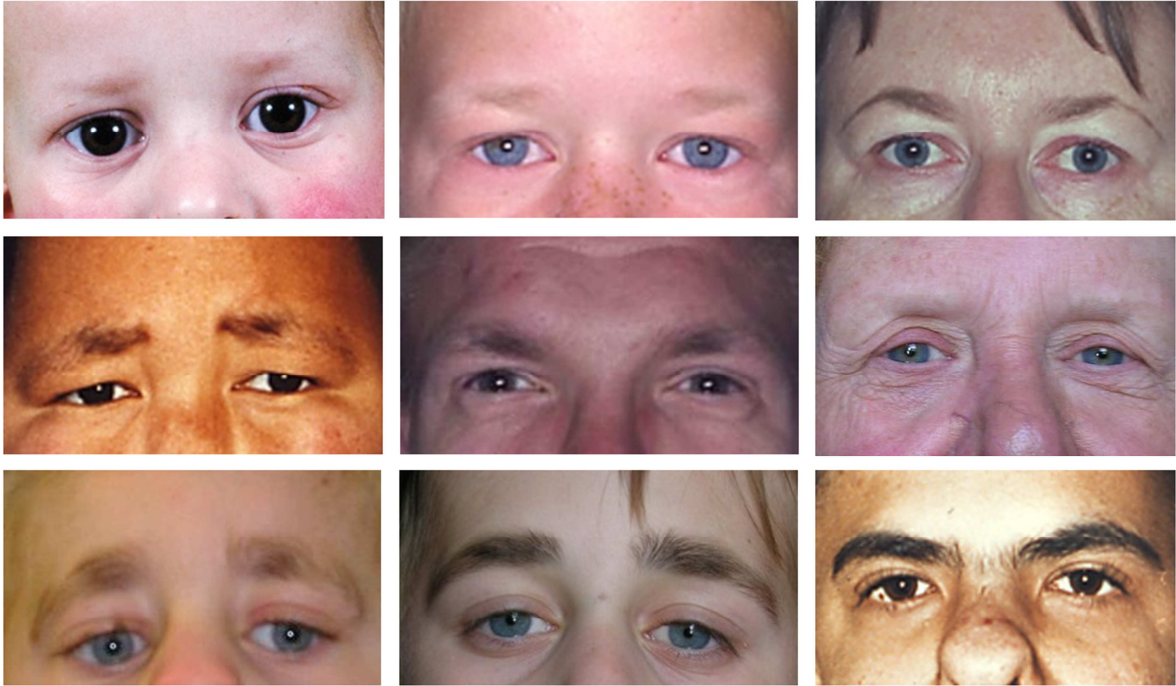** insufficient molecular information but clinically multiple exostoses



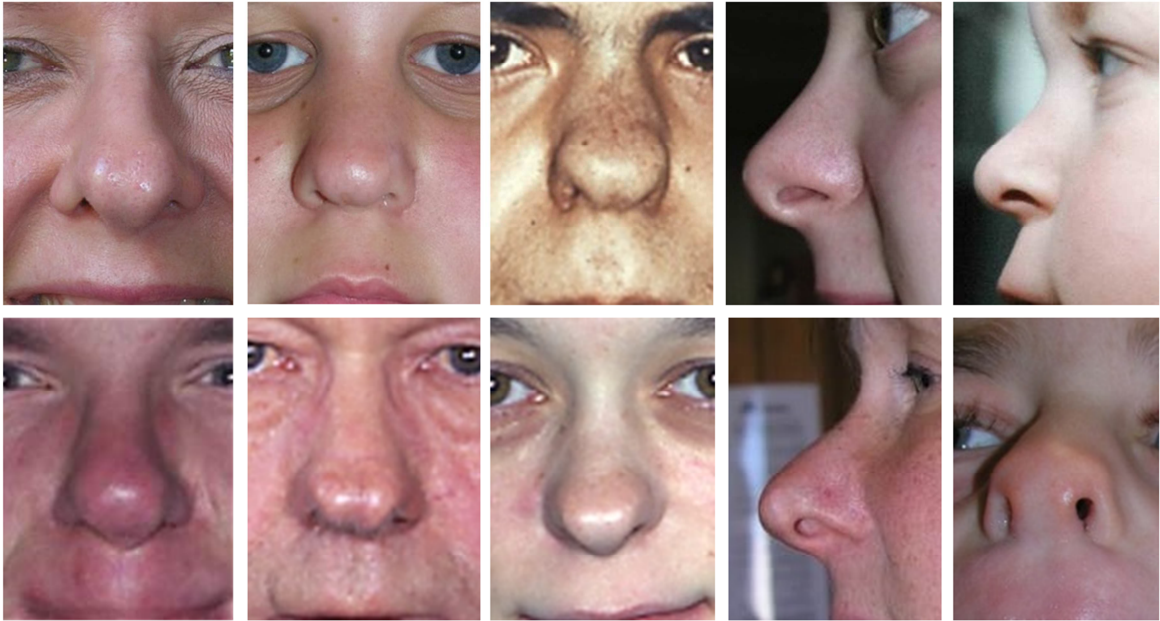ACCEPTED MANUSCRIPT



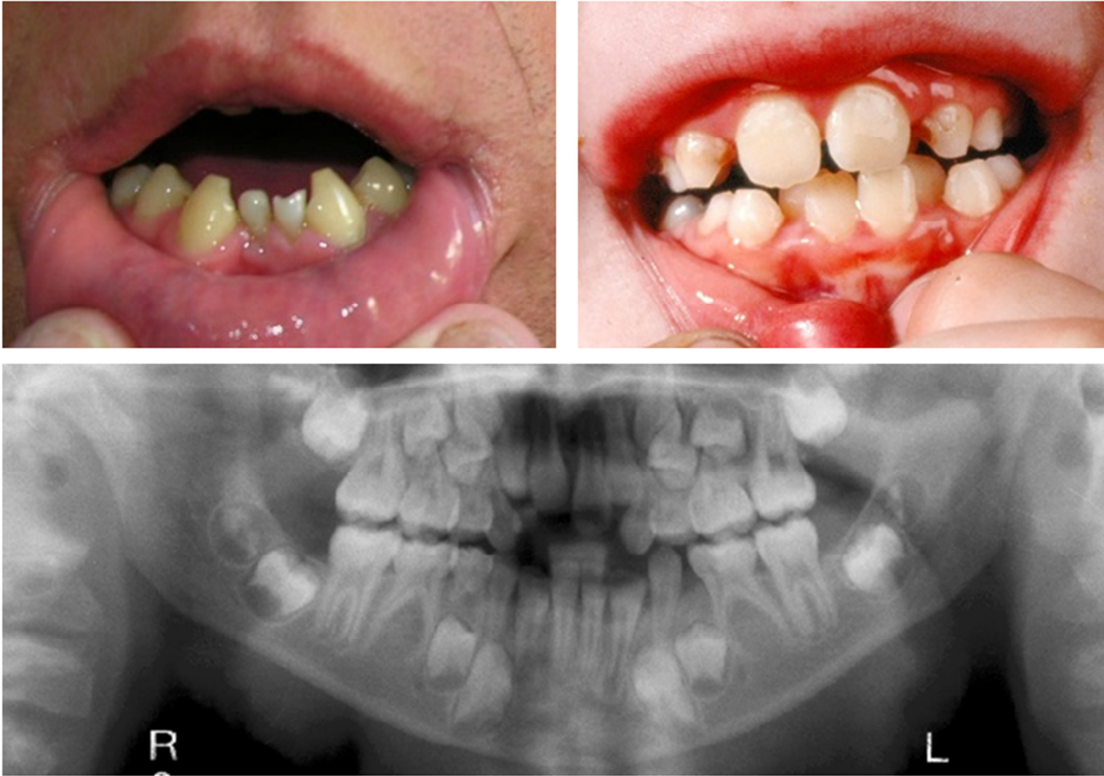
ACCEPTED MANUSCRIPT



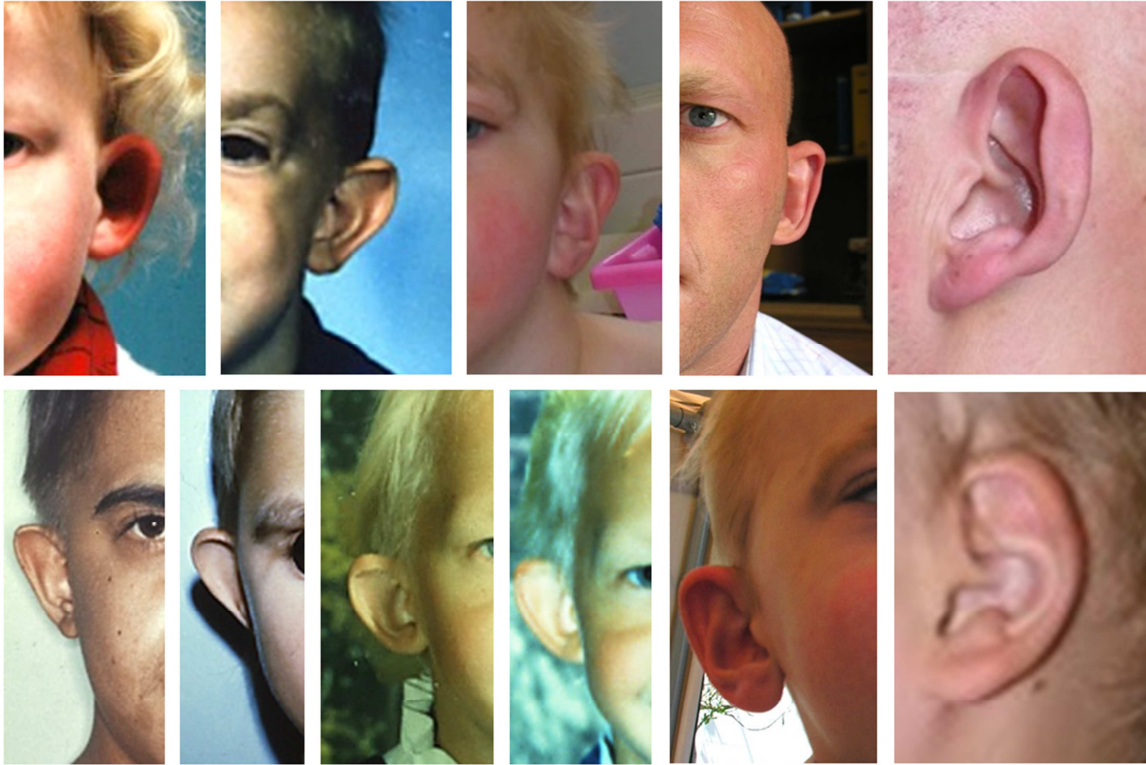
ACCEPTED MANUSCRIPT



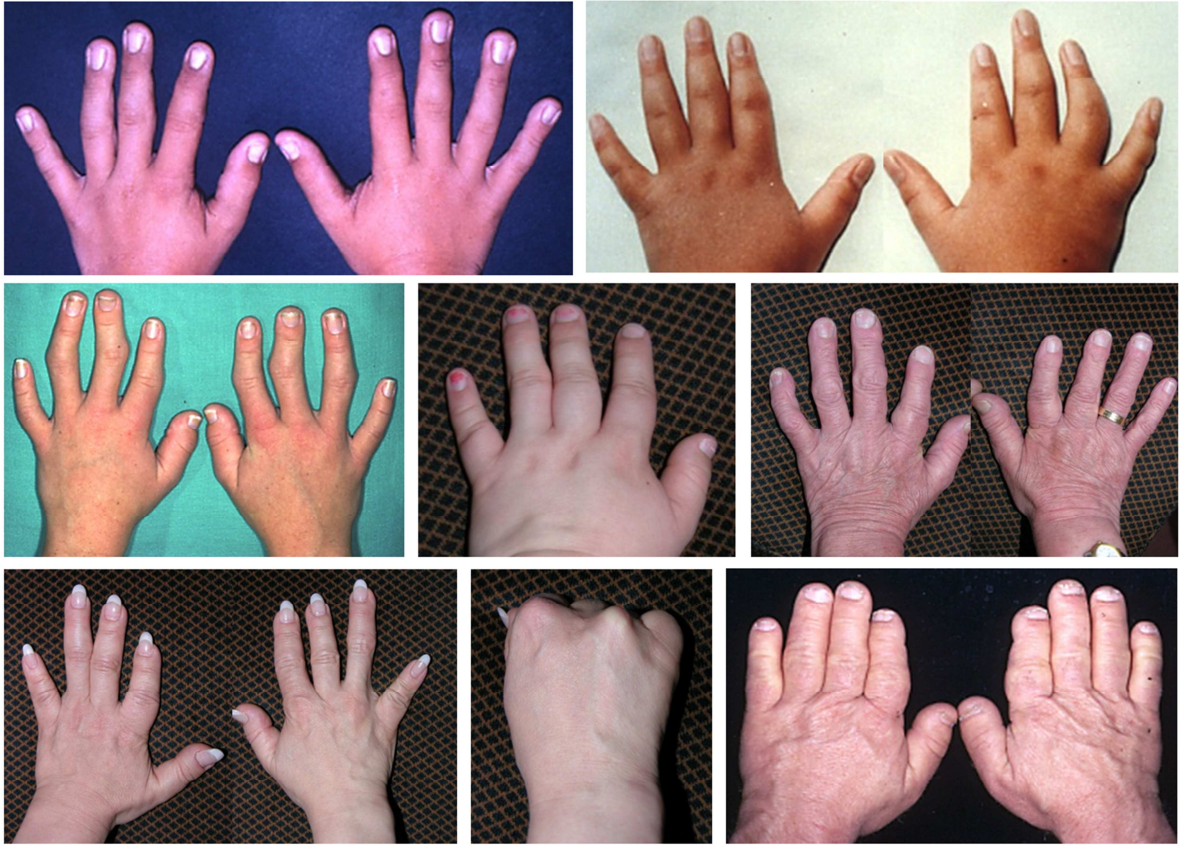ACCEPTED MANUSCRIPT



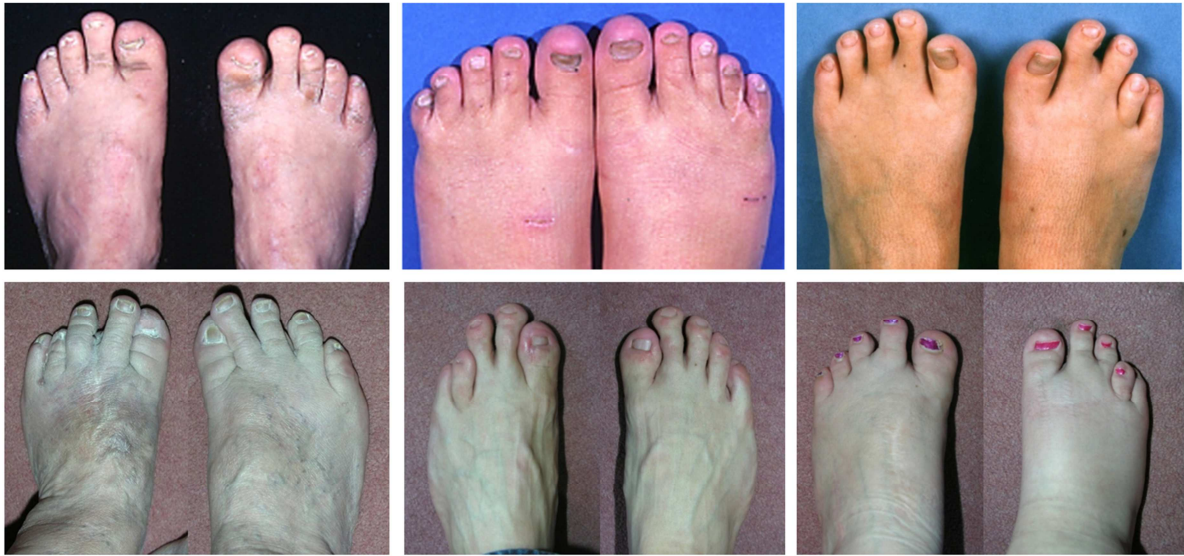
ACCEPTED MANUSCRIPT



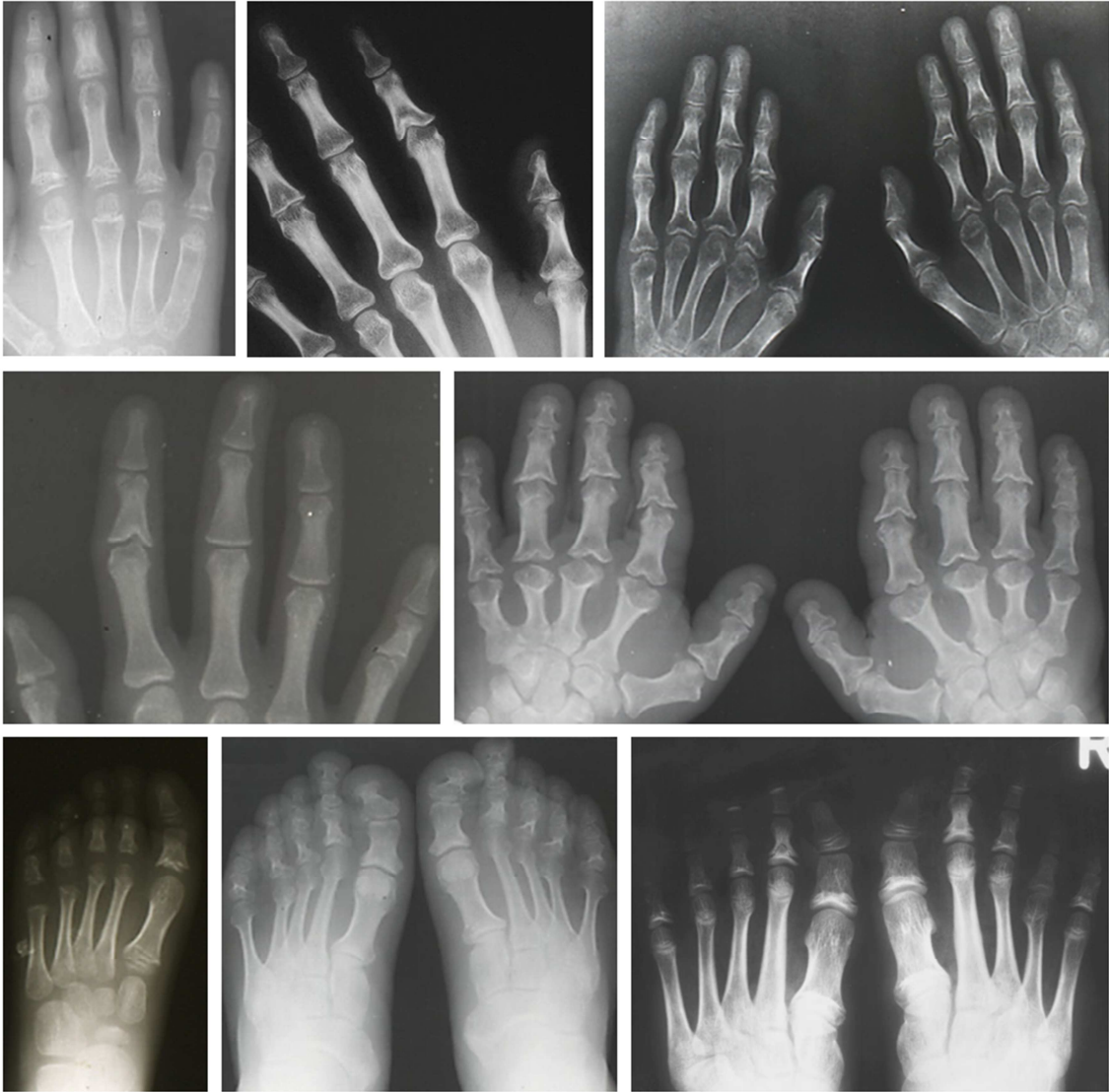ACCEPTED MANUSCRIPT



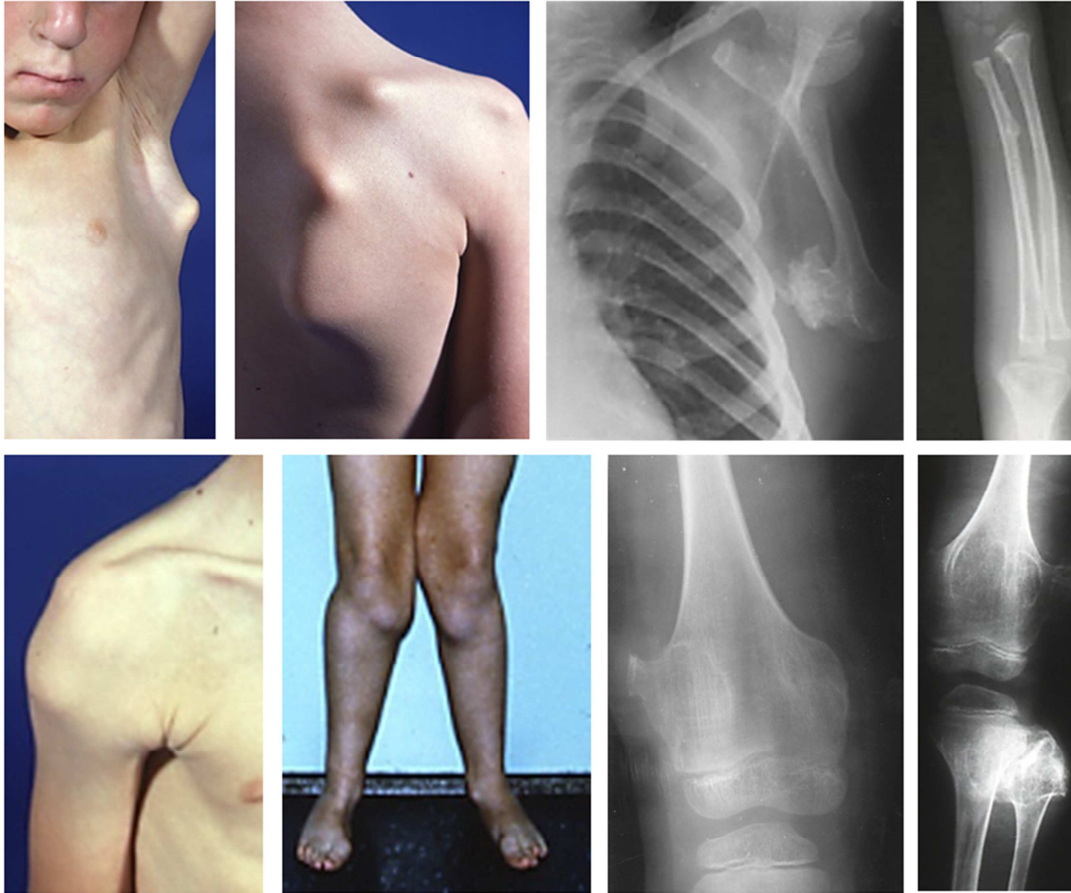
ACCEPTED M



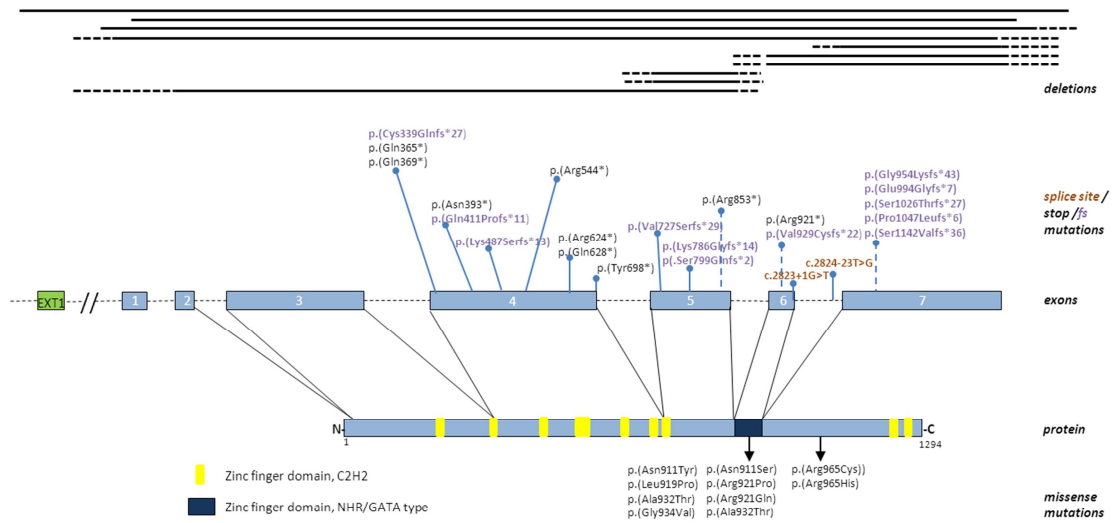
ACCEPTED MANUSCRIPT

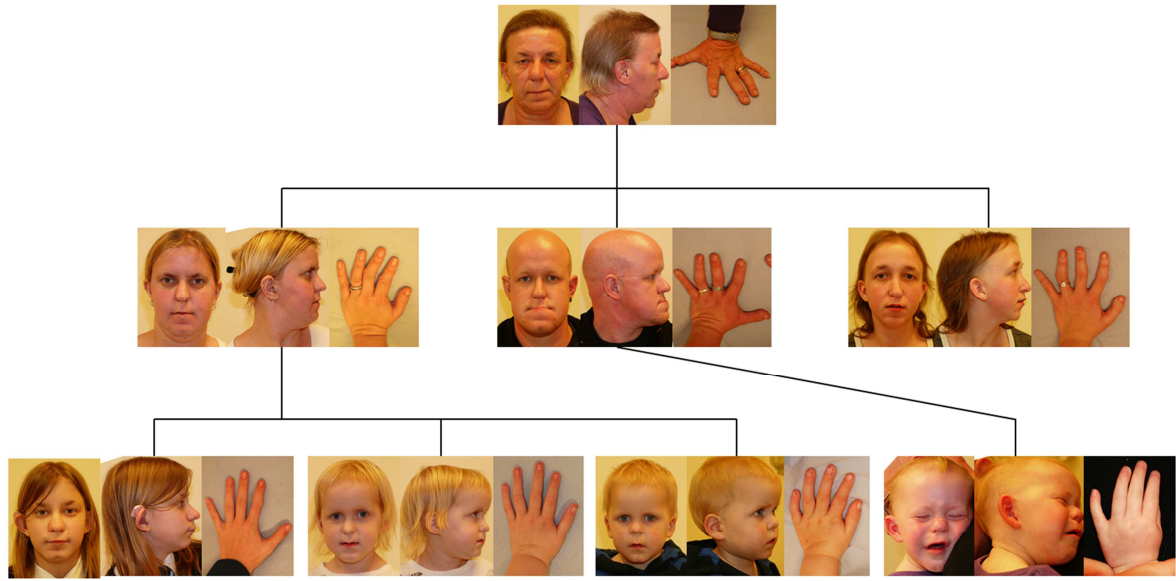


ACCEPTED



ACCEPTED





ACCEPTED MANUSCRIPT