



Acute aortic dissection with sporadic aortic calcifications during chemotherapy with sunitinib

著者	Adachi Toru, Sato Akira, Hanaoka Daisuke, Aonuma Kazutaka
journal or publication title	Journal of Vascular Surgery Cases and Innovative Techniques
volume	4
number	2
page range	147
year	2018-06
権利	(C) 2018 The Author(s). Published by Elsevier Inc. on behalf of Society for Vascular Surgery. This is an open access article under the CC BY-NC-ND license (http://creativecommons.org/licenses/by-nc-nd/4.0/)
URL	http://hdl.handle.net/2241/00153117

doi: 10.1016/j.jvscit.2018.02.003



Acute aortic dissection with sporadic aortic calcifications during chemotherapy with sunitinib

Toru Adachi, MD,^{a,b} Akira Sato, MD,^b Daisuke Hanaoka, MD,^a and Kazutaka Aonuma, MD,^b
Kamisu and Tsukuba, Japan

Keywords: Aortic dissection; Calcification; Hypertension; Sunitinib; Vascular fragility

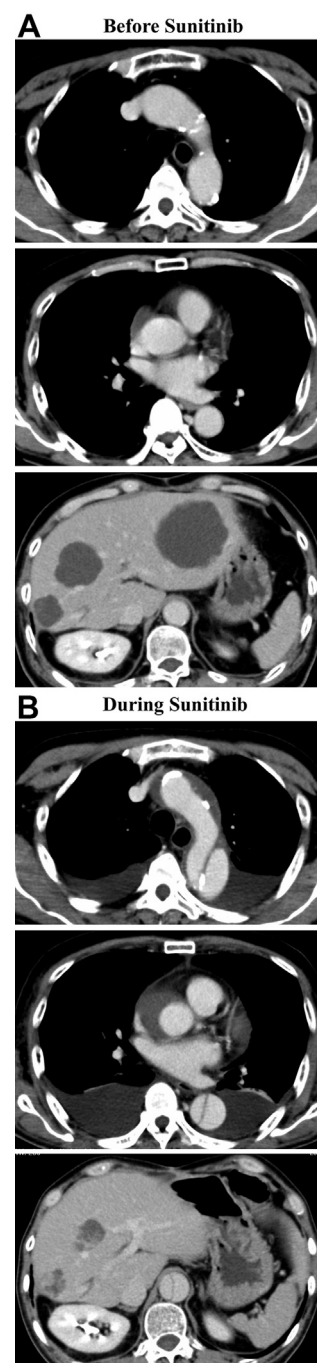
A 66-year-old man with imatinib-resistant metastatic liver tumors of gastrointestinal stromal tumor started chemotherapy with sunitinib. Baseline computed tomography showed sporadic aortic calcifications and liver tumors (A). His systolic blood pressure increased to 160 mm Hg during chemotherapy¹ and decreased to 130 mm Hg with administration of antihypertensive medication. During his sixth cycle of chemotherapy, he developed an acute aortic dissection (AAD, Stanford A) with thrombosed false lumen of the ascending aorta despite good control of blood pressure and reduction of the liver tumors (B). The entry site of the AAD was already calcified before chemotherapy as in A.

The presumable mechanism of the onset of AAD during chemotherapy with sunitinib is interruption of vascular endothelial growth factor function, which could be related to vascular stability.² In this case, the AAD was considered to have developed on the basis of simultaneous hypertension due to sunitinib and vascular fragility due to both calcification and sunitinib presence. In daily practice, careful attention should be paid to the onset of AAD in patients with sporadic aortic calcifications during chemotherapy with sunitinib.

REFERENCES

1. Azizi M, Chedid A, Oudard S. Home blood-pressure monitoring in patients receiving sunitinib. *N Engl J Med* 2008;358:95-7.
2. Edeline J, Laguerre B, Rolland Y, Patard JJ. Aortic dissection in a patient treated by sunitinib for metastatic renal cell carcinoma. *Ann Oncol* 2010;21:186-7.

Submitted Feb 7, 2018; accepted Feb 20, 2018.



From the Department of Internal Medicine, Kamisu Saiseikai Hospital, Kamisu^a, and the Department of Cardiology, Faculty of Medicine, University of Tsukuba, Tsukuba.^b

Author conflict of interest: none.

E-mail: adachi-hki@umin.ac.jp.

The editors and reviewers of this article have no relevant financial relationships to disclose per the Journal policy that requires reviewers to decline review of any manuscript for which they may have a conflict of interest.

J Vasc Surg Cases and Innovative Techniques 2018;4:147

2468-4287

© 2018 The Author(s). Published by Elsevier Inc. on behalf of Society for Vascular Surgery. This is an open access article under the CC BY-NC-ND license (<http://creativecommons.org/licenses/by-nc-nd/4.0/>).

<https://doi.org/10.1016/j.jvscit.2018.02.003>