

Original paper

Comparison of conservative treatment versus transcatheter arterial embolisation for the treatment of spontaneously ruptured hepatocellular carcinoma

Kohei Shinmura^{1A,D,E,F}, Young Ho Choi^{2B}, Masashi Shimohira^{3B}, Yasutaka Baba^{4A,B,E}, Shunichiro Ikeda^{1A,B}, Sadao Hayashi^{1B}, Yuta Shibamoto^{3B}, Chihaya Koriyama^{5C}, Takashi Yoshiura^{1A,E}

¹Department of Radiology, Graduate School of Medical and Dental Sciences, Kagoshima University, Kagoshima, Japan

²Department of Radiology, The SMG-SNU Boramae Medical Centre, Seoul, Korea

³Department of Radiology, Nagoya City University Hospital, Nagoya, Japan

⁴Yasutaka Baba, Department of Radiology, Hiroshima University Hospital, Hiroshima, Japan

⁵Department of Epidemiology and Preventive Medicine, Kagoshima University, Kagoshima, Japan

Abstract

Purpose: To elucidate the prognostic factors in the spontaneous rupture of hepatocellular carcinoma (HCC) and to determine whether transcatheter arterial embolisation (TAE) is associated with better prognosis compared to conservative treatment.

Material and methods: A retrospective multicentre study was conducted involving 71 patients with spontaneous rupture of HCC. A conservative treatment group (Cons T group) included 20 patients, while a transcatheter arterial embolisation group (TAE group) included 51 patients.

Results: The median survival time (MST) in the Cons T group was only 16 days and the survival rate was 39% at one month, whereas the MST in the TAE group was 28 days and the one month survival rate was 63%. However, there is no statistically significant difference in the overall survival between Cons T and TAE groups ($p = 0.213$). Multivariable analysis identified only the presence of distant metastasis as an independent prognostic factor ($p = 0.023$). A subanalysis including patients without distant metastasis showed that the presence of portal vein tumour thrombosis was a significant prognostic factor ($p = 0.015$).

Conclusions: Distant metastasis appears to be a prognostic factor in spontaneous rupture of HCC. In cases without distant metastasis, portal vein tumour thrombosis could influence the prognosis. Our data failed to prove any benefit of TAE as the primary management.

Key words: hepatocellular carcinoma, rupture, prognosis, transcatheter arterial embolization (TAE).

Introduction

The spontaneous rupture of hepatocellular carcinoma (HCC) is a rare but life-threatening presentation of this disease and cause of death in 6.4% of such cases in Japan [1]. The affected patients frequently have poor liver function

due to liver cirrhosis and advanced tumour stage, and previous reports showed that the one-month mortality rate ranged from 28% to 71% with a median survival period of 4 to 32 weeks [2-8]. The spontaneous rupture of HCC has been treated with several different methods such as conservative treatment (Cons T) and transcatheter arterial

Correspondence address:

Kohei Shinmura, Department of Radiology, Graduate School of Medical and Dental Sciences, Kagoshima University 8-35-1 Sakuragaoka, Kagoshima, 890-8544 Japan, phone: +81-99-275-5417, fax: +81-99-265-1106, e-mail: k2406593@kadai.jp

Authors' contribution:

A Study design · B Data collection · C Statistical analysis · D Data interpretation · E Manuscript preparation · F Literature search · G Funds collection

embolisation (TAE). However, due to its relative rarity and difficulty in conducting prospective comparisons, there is little consensus on the appropriate management and prognostic factors. Therefore, we introduced a multi-centre retrospective study to elucidate the prognostic factors in the spontaneous rupture of HCC and to determine whether TAE is associated with better prognosis than Cons T.

Material and methods

Study population and clinical data

This multicentre retrospective study was approved by the Institutional Review Board of each participating institution, and the need for informed consent acquisition was waived.

We retrospectively analysed pooled data obtained from the clinical and radiological records of 71 consecutive patients (56 males and 15 females; age range 32–86 years, mean 65.1 years) with spontaneous rupture of HCC, who were treated between October 1989 and December 2011 in three different sites in two countries: hospital A (15 patients), B (43 patients), and C (13 patients). Cause of liver damage (hepatitis type), Child-Pugh classification (A, B, or C), presence/absence of hepatic encephalopathy, ascites, shock vital (systolic blood pressure < 80 mmHg), portal vein tumour thrombosis, distant metastasis, and past history of HCC treatment, tumour size (maximum diameter on axial CT image), tumour morphology (massive or diffuse), serum α -fetoprotein (AFP), blood chemistry data (serum albumin, total bilirubin, aspartate aminotransferase [AST], alanine transaminase [ALT], blood urea nitrogen [BUN], and creatinine), haemoglobin, prothrombin time, primary management (TAE or conservative), and secondary management (TAE or surgery or none) were recorded.

Treatment methods

Attending physician assessed patients' states and conducted the treatment method (TAE or Cons T) and obtained consent from the patient or patient's family. TAE was approached from femoral artery with the Seldinger technique. Angiographic catheter was inserted in the hepatic artery and contrast agent was injected, so that branches of bleeding hepatic artery were identified. As an embolic material, gelatin sponge that was cut into small cubes of approximately 1–2 mm³ in size was injected into bleeding arteries. The embolic procedure was finished because we could confirm the stopping of bleeding by angiography. In conservative treatment, a haemostatic agent and/or pain relief drug was intravenously infused.

Statistical analyses

The χ^2 test for independence or the Fisher exact test was used for comparison of the two groups. To determine

factors influencing overall survival, a univariate analysis was performed using the Kaplan-Meier method and a log-rank test. The survival period was defined as the length of time from the onset of the spontaneous rupture of HCC until death. Subsequently, to identify independent prognostic factors, multivariable analysis was performed using the Cox proportional hazard model from which hazard ratios with their confidence intervals and *p* values were reported. *P* < 0.05 was considered statically significant for all analyses. All statistical analyses were performed using StatView; SAS software.

Results

The patients' characteristics are shown in Table 1. Cause of liver damage was alcoholic in seven patients (10%), hepatitis B in 28 patients (39%), hepatitis C in 18 patients (25%), and non-B non-C in six patients (8%). Eight patients (11%) were in Child-Pugh A class, 34 (48%) in B class, and 22 (31%) in C class. Five patients (7%) had hepatic encephalopathy. Fifty-nine patients (83%) had ascites. Ten patients (16%) had shock vital at the time of admission. Mean tumour size of HCCs was 7.5 cm. Forty-two patients (59%) had past history of HCC treatment. Mean follow-up period was 106.8 days (range 0–2972 days).

Conservative treatment (Cons T group) was employed as the primary management in 20 patients (28%), while transcatheter arterial embolisation (TAE group) was performed in the remaining 51 patients (72%). Hepatic encephalopathy was more frequent in the Cons T group than in the TAE group (*p* = 0.001). In addition, serum total bilirubin was significantly higher (*p* = 0.012) and prothrombin time was significantly shorter (*p* = 0.003) in the Cons T group than in the TAE group. No significant difference was found in the other variables between the two groups.

The median survival time (MST) was 22 days, and one-month mortality rate was 56% in all patients. MST in the Cons T group was 16 days and the survival rate was poor: 75% at seven days, 60% at 14 days, 39% at one month, and 22% at three months. On the other hand, MST in TAE group was 28 days and the survival rate was 83% at seven days, 73% at 14 days, 63% at one month, 27% at three months, 18% at 12 months, and 18% at 24 months. However, there was no statistically significant difference in the survival rate between the Cons T and TAE groups (*p* = 0.213) (Table 2, Figure 1). Factors associated with significantly lower overall survival included being female (*p* = 0.006), higher Child-Pugh grade (*p* = 0.012), presence of hepatic encephalopathy (*p* < 0.001), presence of portal vein tumor thrombosis (*p* < 0.001), presence of distant metastasis (*p* = 0.005), presence of past history of HCC (*p* = 0.049), lower serum albumin (*p* = 0.018), higher total bilirubin (*p* < 0.001), and longer prothrombin time (*p* = 0.017) (Table 2).

A multivariable analysis admitted factors that were shown to be significant in the univariate analysis. Hepatic encephalopathy, serum total bilirubin, albumin, and

Table 1. Patient characteristics of the analysed cohort and comparisons between conservative treatment group (Cons T) and transcatheter arterial embolisation (TAE) groups

Variables	Total	Cons T group	TAE group	p value
Patients, n (%)	71	20 (28)	51 (72)	
Age (y)	65.1 (13.3)	68.2 (10.7)	63.8 (14.1)	0.378 NS
Sex, n (%)				0.621 NS
Male	56 (79)	15 (75)	41 (80)	
Female	15 (21)	5 (25)	10 (20)	
Cause of liver damage, n (%)				0.767 NS
Alcohol	7 (10)	1 (5)	6 (12)	
Hepatitis B	28 (39)	7 (35)	21 (41)	
Hepatitis C	18 (25)	4 (20)	14 (27)	
Non-B, non-C	6 (8)	1 (5)	5 (10)	
Child-Pugh classification, n (%)				0.786 NS
A	8 (11)	2 (10)	6 (12)	
B	34 (48)	8 (40)	26 (51)	
C	22 (31)	7 (35)	15 (29)	
Hepatic encephalopathy, n (%)				0.002
Present	5 (7)	4 (20)	1 (2)	
Ascites, n (%)				0.209 NS
Present	59 (83)	15 (75)	44 (86)	
Shock vital, n (%)				0.719 NS
Present	16 (22)	4 (20)	12 (23)	
Tumour size (cm)	7.5 (3.9)	7.2 (0.8)	7.6 (4.1)	0.842 NS
Tumour morphology, n (%)				0.778 NS
Massive	34 (47)	6 (30)	28 (54)	
Diffuse	14 (19)	5 (25)	9 (17)	
Portal vein tumour thrombosis, n (%)				0.326 NS
Present	19 (27)	7 (35)	12 (24)	
History of HCC treatment, n (%)				0.089 NS
Present	42 (59)	15 (75)	27 (53)	
Secondary management, n (%)				0.083 NS
TAE	6 (8)	0 (0)	6 (12)	
Surgery	1 (1)	1 (5)	0 (0)	
None	62 (87)	19 (95)	43 (84)	
Serum albumin (g/l)	2.85 (0.64)	2.81 (0.55)	2.87 (0.68)	0.720 NS
Serum total bilirubin (µmol/l)	3.47 (5.08)	5.89 (8.62)	2.51 (2.39)	0.012
Serum AFP (ng/ml)	47821 (113213)	7721 (14084)	58132 (125013)	0.238 NS
AST (U/l)	197.8 (262.5)	205.0 (218.9)	195.0 (278.9)	0.889 NS
ALT (U/l)	114.7 (240.7)	96.6 (118.5)	121.4 (273.4)	0.705 NS
Haemoglobin (g/dl)	8.99 (2.49)	9.16 (2.53)	8.92 (2.50)	0.726 NS
Prothrombin time (s)	32.8 (24.6)	18.7 (15.1)	37.8 (25.0)	0.003
BUN (mg/dl)	24.2 (15.7)	26.8 (20.4)	23.3 (13.7)	0.411 NS
CRE (mg/dl)	1.43 (1.47)	1.23 (0.79)	1.50 (1.65)	0.524 NS

Cons T – conservative treatment, TAE – transcatheter arterial embolization, NS – not significant, AFP – α -fetoprotein, AST – aspartate aminotransferase, ALT – alanine aminotransferase
Continuous variables are indicated in the mean (SD)

Table 2. Univariate analysis searching for factors influencing overall survival

Variables	Number	Median survival (day)	<i>p</i> value (log-rank)
Age			0.316 NS
≤ 58	24	17	
> 58 and < 73	22	25	
≥ 73	25	20	
Sex			0.006
Male	56	25	
Female	15	10	
Institution			0.855 NS
A	15	20	
B	43	17	
C	13	28	
Primary management			0.213 NS
TAE	51	28	
Cons T	20	16	
Child-Pugh classification			0.012
A	8	30	
B	34	22	
C	22	11	
Hepatic encephalopathy			< 0.001
Absent	64	25	
Present	5	1	
Ascites			0.988 NS
Absent	11	17	
Present	59	22	
Shock vital			0.105 NS
Absent	54	28	
Present	16	10	
Tumour size (cm)			0.832 NS
≤ 4.3	17	29	
> 4.3 and < 7.8	18	25	
≥ 7.8	19	11	
Tumour morphology			0.748 NS
Massive	34	22	
Diffuse	14	16	
Portal vein tumour thrombosis			< 0.001
Absent	52	29	
Present	19	10	
Distant metastasis			0.005
Absent	55	25	
Present	16	14	
History of HCC treatment			0.049
Absent	29	18	
Present	42	28	

Table 2. Cont.

Variables	Number	Median survival (day)	<i>p</i> value (log-rank)
Serum albumin (g/l)			0.018
≤ 2.5	23	11	
> 2.5 and < 3.2	21	38	
≥ 3.2	20	20	
Serum total bilirubin (μmol/l)			< 0.001
≤ 1.2	23	34	
> 1.2 and < 2.5	23	20	
≥ 2.5	24	10	
Serum AFP (ng/ml)			0.173 NS
≤ 420	14	30	
> 420 and < 15 700	15	15	
≥ 15 700	15	18	
AST (U/l)			0.079 NS
≤ 63	23	28	
> 63 and < 144	23	18	
≥ 144	24	13	
ALT (U/l)			0.228 NS
≤ 32	24	30	
> 32 and < 62	24	17	
≥ 62	22	14	
Haemoglobin (g/dl)			0.125 NS
≤ 7.7	23	16	
> 7.7 and < 10.0	22	22	
≥ 10.0	25	30	
Prothrombin time (s)			0.017
≤ 14	23	34	
> 14 and < 40	23	10	
≥ 40	23	22	
BUN (mg/dl)			0.732 NS
≤ 16.1	24	25	
> 16.1 and < 23.3	24	20	
≥ 23.3	22	25	
CRE (mg/dl)			0.974 NS
≤ 0.8	24	25	
> 0.8 and < 1.3	21	17	
≥ 1.3	25	18	

CI – confidence interval, TAE – transcatheter arterial embolization, Cons T – conservative treatment, NS – not significant, HCC – hepatocellular carcinoma, AFP – α -fetoprotein, AST – aspartate aminotransferase, ALT – alanine aminotransferase

prothrombin time were excluded from the analysis because they are included in the Child-Pugh classification. The multivariable analysis identified only the presence of distant metastasis as an independent factor determining lower overall survival ($p = 0.023$) (Table 3, Figure 2).

We performed an additional subanalysis including 55 patients without distant metastasis. A multivariable analysis showed that the presence of portal vein tumour thrombosis was the only significant independent prognostic factor ($p = 0.015$) (Table 4, Figure 3).

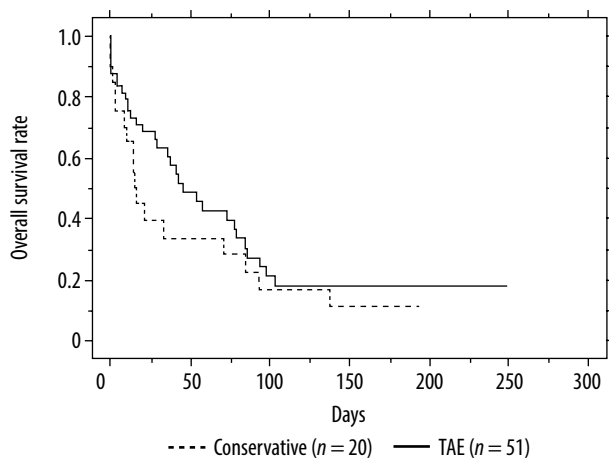


Figure 1. Cumulative survival rates in the conservative treatment (Cons T) group ($n = 20$) and in the transcatheter arterial embolization (TAE) group ($n = 51$). Difference between groups is not significant ($p = 0.213$)

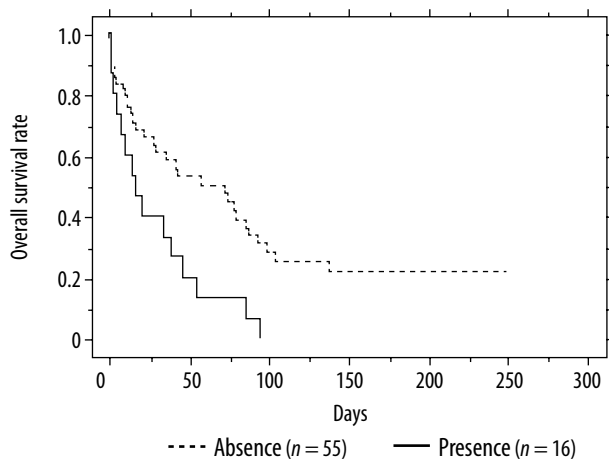


Figure 2. Cumulative survival rates in the absence of distant metastasis group ($n = 55$) and in the presence group ($n = 16$). Overall survival rate is significantly higher in the absence group than in the presence group ($p = 0.005$)

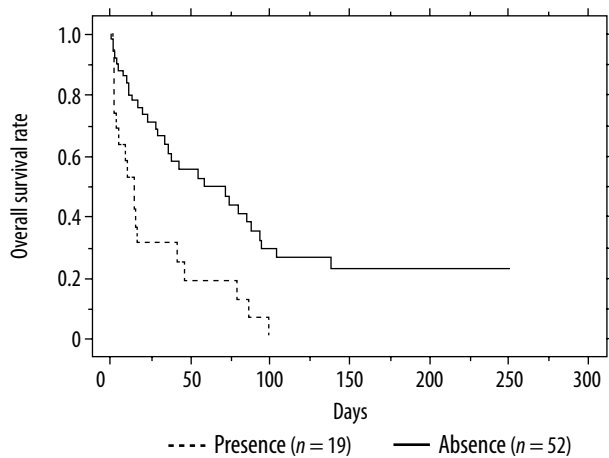


Figure 3. Cumulative survival rates in the absence of portal vein tumor thrombosis group ($n = 42$) and in the presence group ($n = 13$) without distant metastasis. Overall survival rate is significantly higher in the absence group than in the presence group ($p < 0.001$)

Table 3. Multivariable analysis searching for factors influencing overall survival

Variables	Hazard ratio	95% CI	p value
Sex (female)	1.967	0.889-4.355	0.095 NS
Child-Pugh classification			
C	2.208	0.574-8.491	0.249 NS
B	1.282	0.361-4.548	0.700 NS
Portal vein tumor thrombosis (present)	2.080	0.962-4.497	0.063 NS
Distant metastasis (present)	2.313	1.123-4.767	0.023
History of HCC treatment (present)	1.524	0.731-3.174	0.261 NS

CI – confidence interval, NS – not significant, HCC – hepatocellular carcinoma

Table 4. Multivariable analysis including patients without distant metastasis

Variables	Hazard ratio	95% CI	p value
Sex (female)	2.249	0.894-5.657	0.085 NS
Child-Pugh classification			
C	1.849	0.368-9.283	0.455 NS
B	1.379	0.303-6.260	0.678 NS
Portal vein tumour thrombosis (present)	2.896	1.222-6.864	0.015
History of HCC treatment (present)	1.482	0.616-3.564	0.380 NS

CI – confidence interval, NS – not significant, HCC – hepatocellular carcinoma

Discussion

In the past, patients with spontaneously ruptured HCC were treated by various surgical procedures including perihepatic packing, suture plication of bleeding tumour, injection of absolute alcohol, hepatic artery ligation, and liver resection [2-13]. However, because those patients tend to have advanced disease and poor liver function from cirrhosis, invasive surgical interventions may not be tolerated. Thus, less invasive treatments such as TAE or conservative management are chosen in the majority of cases. TAE is considered to be highly effective in controlling haemorrhage due to ruptured HCC, and we expected that it would improve prognosis of the affected patients compared to conservative treatment. In fact, our results showed a better prognosis in the TAE group (MST = 28 days) than in the Cons T group (MST = 16 days), but no significant difference in overall survival was revealed between the two groups ($p = 0.213$). An earlier retrospective study reported by Kirikoshi *et al.* showed a significantly better prognosis in patients treated with TAE (MST = 224.8 days) than in those treated with conservative therapy (MST = 13.1 days)

[11]. The discrepant results can possibly be accounted for by relatively better liver function in their patients than those in our study: percentage of child A patients was 24% and the mean of total bilirubin was 1.8 mmol/l in their study, while percentage of child A patients was 11% and the mean total bilirubin was 3.4 mmol/l in our study.

Despite a multitude of previous studies, no general consensus has been achieved on prognostic factors in patients with spontaneous rupture of HCC. In our multivariable analysis, the presence of distant metastasis was the only significant factor that was associated with lower overall survival (Table 3, Figure 2). Sixteen patients had distant metastasis (lung in 11 cases, lymph node in two cases, peritoneum in one case, adrenal gland in one case, and bone in one case), and their MST was 10 days (22 days in the absence group). Aoki *et al.* [6] analysed patients with spontaneous rupture of HCC and reported that stage IV group was associated with worse prognosis than the stage I-III group. Ueno *et al.* [14] reported that extrahepatic metastasis showed prognostic significance in multivariate analysis of unresectable HCC patients treated with transcatheter arterial chemoembolisation therapy. Distant metastasis of HCC has been regarded as a terminal event, and intrahepatic lesions were not actively treated in such cases [15]. However, some previous reports showed that the metastatic lesion of HCC was a minor cause of death and the main cause of death was advanced intrahepatic lesions. In those reports, it was said that if a patient's liver status is good, treatment for liver and metastatic lesion may improve survival [16-19]. In general, ruptured HCC patient's liver status was mostly not good. In cases where distant metastasis is present, one should be careful about introducing TAE for treatment of ruptured HCC. Conservative treatment may be preferred in such cases.

Our univariate analysis revealed several additional items as possible prognostic factors. The presence of portal vein tumour thrombosis was significantly associated with lower overall survival (Table 2). MST of 19 patients with portal vein tumour thrombosis was 10 days while that of the absence group was 29 days. Okazaki *et al.* performed TAE in 38 patients with ruptured HCC. Although patients without portal vein tumour thrombus showed longer MST (133 days) than those with it (90 days), no significant difference in prognosis was demonstrated [13]. Nevertheless, our subanalysis including patients without distant metastasis ($n = 55$) identified it as an independent prognostic factor ($p = 0.015$) (Table 4, Figure 3). Thus, we consider that portal vein tumour thrombus could be a prognostic factor of ruptured HCC. Portal vein tumour thrombus was found in 12-39% of patients with HCC [1,20-22] and 18-57% of patient with ruptured HCC [6,12,13]. Yamada *et al.* [23] reported that TAE was contraindicated for patients with portal vein tumour thrombus, because TAE might increase the risk of ischaemic liver damage. On the other hand, some groups reported that TAE was a safe treatment method of HCC with peripheral portal vein

tumour thrombus if the patient has good liver function [24-27]. In our study, 19 patients (26%) had portal vein tumour thrombus, and TAE was conducted in 12 cases. There was no significant difference in the survival rate between TAE and conservative treatment ($p = 0.1329$). When central portal vein tumour thrombus is present, patients with ruptured HCC should be treated conservatively.

Tarantino *et al.* [5] reported that Child-Pugh A vs. B/C variables were statistically significant for overall survival of ruptured HCC patients. In agreement with their report, there was a significant difference in overall survival by Child-Pugh classification factor ($C > A$) in our univariate analysis (Table 2), although significant association was not confirmed in the multivariable analysis. This could be partly due to the small number of patients in the Child-Pugh A group ($n = 8$).

The presence of hepatic encephalopathy, which is one of the criteria of Child-Pugh classification, was associated with lower overall survival in our univariate analysis (Table 2). Five patients had hepatic encephalopathy, and their MST was one day, whereas MST of 64 patients without it was 25 days. Kim *et al.* [7] studied 62 patients with ruptured HCC and found that early deaths were independently associated with the presence of hepatic encephalopathy.

Serum levels of albumin and total bilirubin are also included in the criteria of Child-Pugh classification. In the univariate analysis, lower albumin and higher bilirubin levels were found to be significantly associated with worse prognosis in ruptured HCC (Table 2). Okazaki *et al.* [13] reported that MST of the lower serum bilirubin value group (≤ 3.0 mg/dl) was 165 days and that of the higher value group (> 3.0 mg/dl) was 13 days, and that there was significant difference in the survival rate between lower and higher value groups. In our study, MST of the lower serum bilirubin value group (≤ 3.0 μ mol/l) was 25 days and that of the higher serum bilirubin value group (> 3.0 μ mol/l) was 14 days.

There were some limitations in our study. Selection bias may exist due to the retrospective nature of this study. The Cons T group was relatively small.

Conclusions

The presence/absence of distant metastasis appears to be a prognostic factor in spontaneous rupture of HCC. In cases of absent metastasis, portal vein tumour thrombosis could influence the prognosis. Although TAE was associated with longer survival than conservative treatment, our data failed to provide evidence of a significant impact of TAE as the primary management of ruptured HCC. TAE should be conducted with caution, especially in patients with advanced disease.

Conflict of interest

The authors declare that they have no conflict of interest.

References

1. Ikai I, Arii S, Okazaki M, et al. Report of the 17th nationwide follow-up survey of primary liver cancer in Japan. *Hepatol Res* 2007; 37: 676-691.
2. Lai ECS, Choi TK, Wong J. Spontaneous ruptured hepatocellular carcinoma. An appraisal of surgical treatment. *Ann Surg* 1989; 210: 24-28.
3. Liu CL, Fan ST, Lo CM, et al. Management of spontaneous rupture of hepatocellular carcinoma: Single-center experience. *J Clin Oncol* 2001; 19: 3725-3732.
4. Lai ECH, Lau WY. Spontaneous rupture of hepatocellular carcinoma. *Arch Surg* 2006; 141: 191-198.
5. Tarantino L, Sordelli I, Calise F, et al. Prognosis of patients with spontaneous rupture of hepatocellular carcinoma in cirrhosis. *Updates Surg* 2011; 63: 25-30.
6. Aoki T, Kokubo N, Matuyama Y, et al. Prognostic impact of spontaneous tumor rupture in patients with hepatocellular carcinoma. *Ann Surg* 2014; 3: 532-142.
7. Kim YI, Ki HS, Kim MH, et al. Analysis of the clinical characteristics and prognosis factors of ruptured hepatocellular carcinoma. *Korean J Hepatol* 2009; 15: 148-158.
8. Feng Z, Xin SC, Kun H, et al. Treatment outcomes of spontaneous rupture of hepatocellular carcinoma with hemorrhagic shock: a multicenter study. *SpringerPlus* 2016; 5: 1101.
9. Pillai LV, Lim KF, Bujang MA, et al. Diagnosis and Management of ruptured hepatoma: signal center experience over 10 years. *Med J Malaysia* 2013; 68: 405-409.
10. Chearanai O, Plengvanit U, Asavanich C, et al. Spontaneous rupture of primary hepatoma: Report of 63 cases with particular reference to the pathogenesis and rationale treatment by hepatic artery ligation. *Cancer* 1983; 51: 1532-1536.
11. Ong GB, Taw JL. Spontaneous rupture of hepatocellular carcinoma. *BMJ* 1972; 4: 146-149.
12. Kirikoshi H, Saito S, Yoneda M, et al. Outcomes and factors influencing survival in cirrhotic cases with spontaneous rupture of hepatocellular carcinoma: a multicenter study. *BMC Gastroenterol* 2009; 9: 29-38.
13. Okazaki M, Higashihara H, Koganemaru F, et al. Intraoperative hemorrhage from hepatocellular carcinoma: Emergency chemoembolization or embolization. *Radiology* 1991; 180: 647-651.
14. Ueno K, Miyazono N, Inoue H, et al. Transcatheter arterial chemoembolization therapy using iodized oil for patients with unresectable hepatocellular carcinoma. *Cancer* 2000; 88: 1574-1581.
15. Bruix J, Sherman M. Management of hepatocellular carcinoma. *Hepatology* 2005; 42: 1208-1236.
16. Katyal S, Oliver JH, Peterson MS, et al. Extrahepatic metastasis of hepatocellular carcinoma. *Radiology* 2000; 216: 698-703.
17. Natsuizaka M, Omura T, Akaike T, et al. Clinical features of hepatocellular carcinoma with extrahepatic metastases. *J Gastroenterol Hepatol* 2005; 20: 1781-1787.
18. Uka K, Aikata H, Takaki S, et al. Clinical feature and prognosis of patients with extrahepatic metastasis from hepatocellular carcinoma. *World J Gastroenterol* 2007; 13: 414-420.
19. Uchino K, Tateishi R, Shiina S, et al. Hepatocellular carcinoma with extrahepatic metastasis. *Cancer* 2011; 117: 4475-4487.
20. Marrero JA, Fontana RJ, Barrat A, et al. Prognosis of hepatocellular carcinoma: Comparison of 7 staging systems in an American cohort. *Hepatology* 2005; 41: 707-716.
21. Ninagawa M, Makuuchi M. Treatment of hepatocellular carcinoma accompanied by portal vein tumor thrombus. *World J Gastroenterol* 2006; 12: 7561-7567.
22. Jia L, Kiryu S, Watadani T, et al. Prognosis of hepatocellular carcinoma with portal vein tumor thrombus: Assessment based on clinical and computer tomography characteristics. *Acta Med Okayama* 2012; 66: 131-141.
23. Yamada R, Sato M, Kawabata M, et al. Hepatic artery embolization in 120 patients with unresectable hepatoma. *Radiology* 1983; 148: 397-401.
24. Chung JW, Park JH, Han JK, et al. Hepatocellular carcinoma and portal vein invasion: result of treatment with transcatheter oily chemoembolization. *AJR Am J Roentgenol* 1995; 8: 315-321.
25. Yen FS, Wu JC, Kuo BI, et al. Transcatheter arterial embolization for hepatocellular carcinoma with portal vein thrombosis. *J Gastroenterol Hepatol* 1995; 10: 237-240.
26. Furuse J, Iwasaki M, Yoshino M, et al. Hepatocellular carcinoma with portal vein tumor thrombus: embolization of arterioportal shunts. *Radiology* 1997; 204: 787-790.
27. Yang MY, Jeong SW, Kim DK, et al. Treatment of hepatocellular carcinoma with portal vein thrombosis by Sorafenib combined with hepatic arterial infusion chemotherapy. *Gut Liver* 2010; 4: 423-427.