



Title	Comparison of the effects of polyethylene glycol and hyaluronic acid in prevention of epidural fibrosis
Author(s)	Karabulut, Enis; Karaavci, Funda Aksunger; Eroksuz, Hatice
Citation	Japanese Journal of Veterinary Research, 66(3), 133-143
Issue Date	2018-08
DOI	10.14943/jjvr.66.3.133
Doc URL	http://hdl.handle.net/2115/71334
Type	bulletin (article)
File Information	p133-143 Enis_Karabulut.pdf



[Instructions for use](#)

Comparison of the effects of polyethylene glycol and hyaluronic acid in prevention of epidural fibrosis

Enis Karabulut^{1,*}, Funda Aksunger Karaavci² and Hatice Eroksuz³

¹ Firat University, Veterinary Faculty, Department of Surgery, 23119 Elazig/ TURKEY

² Bingol University, Faculty of Veterinary Medicine 12000 Bingol/ TURKEY

³ Firat University, Veterinary Faculty, Department of Pathology, 23119 Elazig/ TURKEY

Received for publication, January 19, 2017; accepted, January 9, 2018

Abstract

The aim of this study was to evaluate of the effect of 5% Polyethylene Glycol 4000 in the prevention of epidural fibrosis and to compare the results with hyaluronic acid. A total of 36 adult New Zealand White Rabbits were used in the study. Three groups were formed with each group including 12 rabbits (Group I: Control, Group II: 5% Polyethylene Glycol 4000, Group III: Hyaluronic acid). Hemilaminectomy was performed at L5 vertebrae on the right side. Three rabbits randomly selected from each group at postoperative 2nd, 4th, 8th and 12th week were euthanized. Macroscopic and histopathological evaluation were performed in terms of the amount of scar tissues. Statistical evaluation was made with Mann-Whitney U Test and Kruskal-Wallis Variance Analysis. $P < 0.05$ was considered statistically significant. In the hemilaminectomy sites of Group I, severe thickness and tenacious epidural scar adhesions were found between the dura mater and surrounding tissues. In the Group II, dura mater was clean without any evidence of adhesion or scar tissue and minimal adhesions were present. In the Group III, moderate adhesion and scar tissue or minimal adhesion and very thin scar tissue were observed. Statistically; Group II was significantly different from Group I ($P < 0.000$) and Group III ($P < 0.002$), and Group III was significantly different from Group I ($P < 0.001$). It was concluded that 5% Polyethylene glycol 4000 can safely be used locally during operation in the area of decompression in order to prevent epidural fibrosis encountered as a postoperative complication after hemilaminectomy.

Key Words: Epidural fibrosis, hemilaminectomy, hyaluronic acid, polyethylene glycol, prevention.

INTRODUCTION

Epidural fibrosis is a serious cause in the natural healing process that occurs after almost every lumbar spinal intervention and constitutes 10% to 24% of cases in failed back surgery syndrome^{15,33,47}. The formation of epidural fibrosis

(extradural fibrous tissue) is a very gradual process. It occurs the result of invasion of postoperative hematoma and dense fibrous tissue that forms at the periosteum fibrous layer and on the deep surface of the paravertebral muscles. This process that referred to as epidural fibrosis can be developed after laminectomy / hemilaminectomy¹⁵.

*Corresponding author: Enis Karabulut, Assoc. Prof. Dr., Firat University Veterinary Faculty, Department of Surgery, 23119, Elazig, TURKEY
Phone: +90 424 2370000/3859. Fax: +90 424 2388173. E-mail: ekarabulut@firat.edu.tr
doi: 10.14943/jjvr.66.3.133

Extreme scar tissue adhering to nerve roots and dura mater is cause continuous pain^{8,11,14,15,29,34,47,57}. Although there is no consensus on the proportion of the problems associated with spinal epidural fibrosis, if there is no bone and disk pathology, many studies have focused on the possibility that recurrent symptoms after lumbar spinal operations may be epidural fibrosis^{48,50}. Many authors have noted that epidural fibrosis is not only encountered a major difficulty when operation is required, but is also responsible for intraoperative complications and bad postoperative results^{3,43}.

It has been aimed to prevent epidural fibrosis by using different biological and non-biological materials⁷. For this purpose; ADCON-L (Anti-adhesion barrier gel)³², omega-3¹⁷, chitin³⁵, fat grafts²², resveratrol⁵⁵, poly (L-glutamic acid)/chitosan³⁷, amniotic membrane¹⁴, omentum greft¹⁰, hyaluronic acid (HA)^{26,42}, gel and sepra film forms of hyaluronic acid^{31,59}, rosuvastatin²³, sodium hyaluronate³², cepea extract-heparin and allantoin mixture⁵⁸, aprotinin³⁶, pimecrolimus⁶, aceclofenac⁵², mitomycin-C⁵⁴, absorbable cement⁶⁶, 4% icodextrin²⁸, and novel biodegradable lamina⁴⁰ has been used. However, an acceptable success has not yet been achieved in the prevention or reduction of epidural fibrosis^{2,34,57}.

Among all methods, autogenous fat grafting studies were found to be more reliable than other approaches^{9,19,22,46}, and it seems to be the most preferred material in spinal surgery until this day. However, autogenous fat grafting still has a number of concerns, such as seroma, infection, necrosis, cystic deposition, and direct caudal pressure²². At the same time, It has been reported that free fat grafts may be resorb^{9,19}.

Polyethylene Glycol (PEG) 4000 (5%) has been reported to be effective in preventing postoperative intraabdominal adhesions and prevention of adhesions that develop after tenoraphy^{12,27}. It has also been reported that combination of Silk-PEG Hydrogels reduced the formation of epidural fibrosis⁶². In another study, combinaton of mitomycin C-PEG film was used

in the prevention of epidural fibrosis in postlaminectomy model with positive results³⁹.

In this experimental study, It was aimed to compare 5% Polyethylene Glycol 4000 and Hyaluronic acid in prevention of epidural fibrosis.

Material and Methods

The experimental study was approved by the Firat University Ethical Committee of Animal Experiments (Verdict number: 2014/01/05). The project was supported by Firat University Scientific Research Projects Unit (VF.14.14).

The study material included 36 adult New Zealand White Rabbits weighing 2,2-3,6 kilograms which were obtained from Firat University Experimental Research Center. Gender discrimination was not observed in the subjects. Three groups were formed with each group including 12 rabbits (**Group I:** 0.9% NaCl, Control, **Group II:** 5% PEG 4000, **Group III:** HA). Each rabbit was numbered from the ears. Rabbits were anesthetized with Ketamine Hydrochloride (35 mg / kg, I.M. Ketalar, Parke-Davis) 5-10 minutes after injection of Xylazine Hydrochloride (5 mg / kg I.M. Rompun, Bayer). It was placed in the prone position on the operating table, after rabbit's back region was shaved from thoracic vertebrae to sacrum. The L5 level was determined by palpation of the iliac wings. Lumbosacral area was cleaned with 10% povidone-iodine solution, then surgical area was covered with a sterile cloths. In the lumbar area, the skin and subcutaneous connective tissue was passed through the middle line with an incision of about 10 cm, the fascia bilaterally was opened and the paravertebral muscles on the right side were subperiostealized in the L4-L6 region. Hemilaminectomy was performed at L5 vertebrae on the right side. Hemilaminectomy defect, 2 mm in wide and 3 mm in long was made with a steel round bur (Figure 1). It was applied 0.9% NaCl 1 ml in Group I, 5% PEG 4000 (Merck, Germany) 1 ml (5% solution of PEG 4000 was prepared by

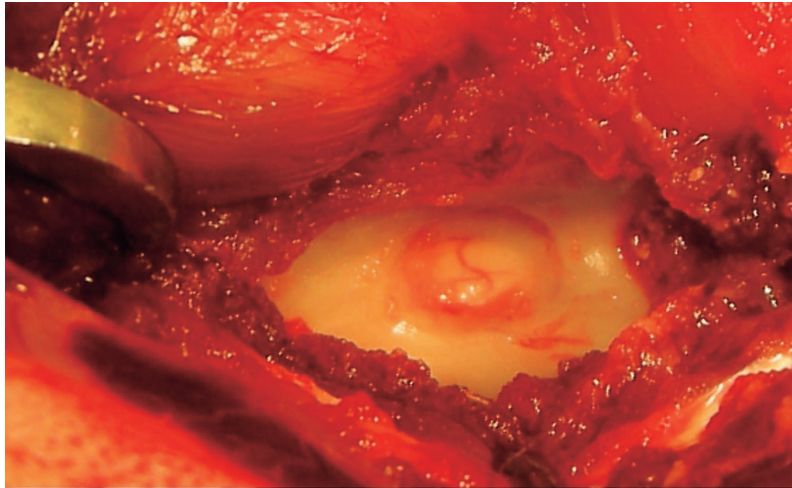


Fig. 1. The appearance of hemilaminectomy in elliptical form with a length of 3 mm on the right side on the L5 vertebra.

boiling 5 g of PEG 4000 in 95 ml of distilled water²⁷⁾ in Group II and HA (Ostenil, Switzerland) 1 ml in Group III to the hemilaminectomy region. Subsequently, paravertebral muscles, fascia and subcutaneous connective tissue were closed with 4-0 vicryl and skin sutured with 3-0 silk. Penicillin (30.000 U / kg, Devapen 400.000 U Deva Ilac) and Flunixin Meglumine (1.1 mg / kg, Fundamin, Bavet) were administered intramuscularly to all rabbits postoperatively for 5 days. Until the day of the euthanasia, the subjects were fed on the normal diet without any restrictions in the Center for Experimental Research at Firat University. Three rabbits randomly selected from each groups at postoperative 2nd, 4th, 8th and 12th weeks were euthanized. The sacrifice process was performed with by carbon dioxide inhalation method. L4-L6 lumbar vertebrae and muscles were removed in blocks and macroscopic evaluations of the hemilaminectomy area at L5 were performed. Macroscopic evaluation was performed using Epidural Fibrosis Gross Score (Grade 0: No scar or adhesion, Grade 1: Minimal adhesion, very thin scar tissue Grade 2: Moderate adhesion and scar tissue, Grade 3: Dense and very tight adhesion and scar tissue)⁴⁸⁾. The L5 vertebrae that underwent hemilaminectomy were fixed in 10% formalin solution and then subjected to 10 days decalcification in 10% formic acid

solution. Paraffin blocks were prepared from the tissue samples that were routinely processed, sections of 5 microns in thickness were prepared with the aid of microtome from the blocks and the obtained preparations were stained with Hematoxyline-Eosin (H.E.) and Masson trichrome method and examined under light microscope (Olympus BX43, DP72) and microscopic pictures were taken. The preparations were graded histopathologically in terms of amount of epidural scar tissue and adhesions (Grade 0: Dura matter is free of scar tissue, Grade I: Presence of only thin fibrous bands between scar tissue and dura matter, Grade II: Continuous adhesions filling less than 2/3 of hemilaminectomy space, Grade III: Adhesions filling more than 2/3 the hemilaminectomy space or/and extend to the nerve roots)²⁴⁾.

Statistical analysis: Statistical evaluation of the results was made using the SPSS 22.0 statistical package. Two groups were compared with Mann-Whitney U Test, three groups were compared by Kruskal-Wallis Variance Analysis. $P < 0.05$ were considered statistically significant¹⁵⁾.

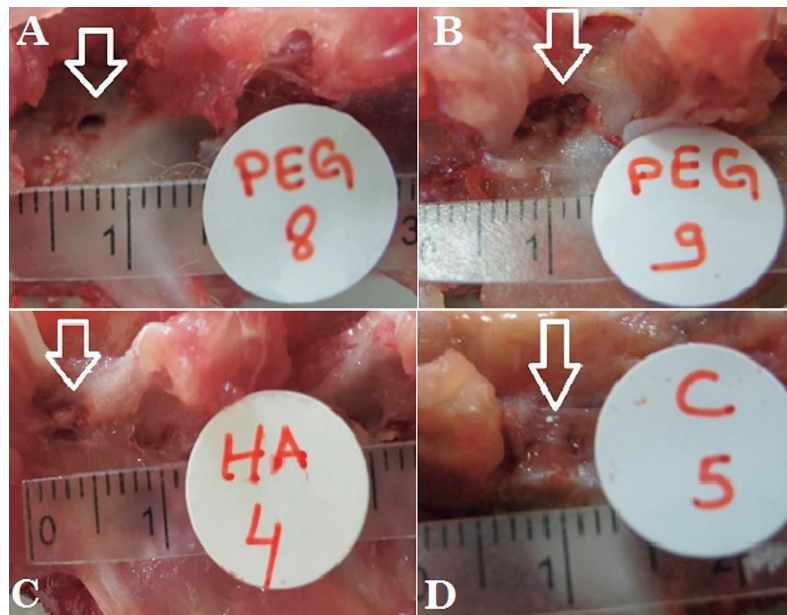


Fig. 2. Appearance of epidural fibrosis levels in the area of hemilaminectomy. A: Anatomical structure intact, no adhesion (Grade 0). **B:** Very thin scar layer and minimal adhesion (Grade 1). **C:** Middle grade scar tissue and adhesion (Grade 2). **D:** Dense and very tight adhesion (Grade 3).

Results

Postoperative complications such as local wound infection and paralysis were not observed in any of the groups (Group I, II, III). No adverse effects of 0.9% NaCl, 5% PEG 4000 and HA used in the experiment were observed.

Macroscopical evaluation

In the hemilaminectomy sites of rabbits treated with 0.9% NaCl (Control group, Group I); severe thickness and tenacious epidural scar adhesions was found between the dura mater and surrounding tissue (in 10 cases Grade 3) (Figure 2D), moderate adhesion and scar tissue (in 1 case Grade 2), and minimal adhesion and very thin scar tissue (in 1 case Grade 1) were observed. In the Group II (5% PEG 4000); dura mater was clean without any evidence of adhesion or scar tissue (in 7 cases Grade 0) (Figure 2A), and minimal adhesions and very thin scar tissue were present (in 5 cases Grade 1) (Figure 2B). In the Group III (HA); moderate adhesion and scar tissue (in 5 cases Grade 2) (Figure 2C), minimal adhesion and very thin scar tissue (in 5 cases

Grade 1), in 1 case Grade 0 and in 1 case Grade 3 were observed. Macroscopic evaluation of groups was presented in Table 1.

It was determined that hemilaminectomy size decreased by approximately 1 mm at 8th and 12th week. In two cases, the area of hemilaminectomy was closed by new bone formation.

According to the epidural fibrosis gross score, Group II (5% PEG 4000) was significantly different from Group I ($P < 0.000$) and Group III ($P < 0.002$). Group III (HA) was significantly different from Group I (Control) ($P < 0.001$). The difference between the groups was significant ($P < 0.000$).

Histopathological evaluation

In the hemilaminectomy sites of rabbits treated with 0.9% NaCl (Control group, Group I); it was observed that filled with severe fibrous tissue of the epidural space and the scar tissue adhered to the dura mater and pulled the dura mater and nerve tissues. (Figure 3A, B). In the Group II (5% PEG 4000); minimal fibrotic changes were observed (Figure 4A, B). In the Group III (HA); fewer fibrotic changes were

Table 1. Macroscopic evaluation of groups according to Epidural Fibrosis Gross Score

GROUPS	WEEKS	GRADE 0	GRADE 1	GRADE 2	GRADE 3	Statistical
Group I (Control, n:12)	2nd	-	1	1	1	a,b,d
	4th	-	-	-	3	
	8th	-	-	-	3	
	12th	-	-	-	3	
Group II (5% PEG 4000, n:12)	2nd	1	2	-	-	a,c,d
	4th	2	1	-	-	
	8th	2	1	-	-	
	12th	2	1	-	-	
Group III (HA, n:12)	2nd	-	2	1	-	b,c,d
	4th	-	1	2	-	
	8th	-	1	1	1	
	12th	1	1	1	-	

PEG: Polyethylene Glycol, HA: Hyaluronic acid. a: Group I was significantly different from Group II ($P < 0.000$) b: Group I was significantly different from Group III ($P < 0.001$). c: Group II was significantly different from Group III ($P < 0.002$). d: The difference between the groups was significant ($P < 0.000$).

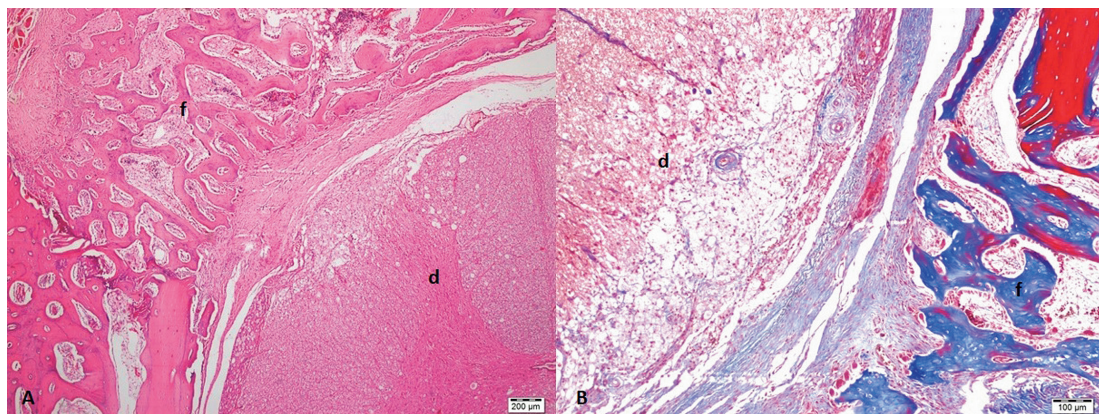


Fig. 3. Photomicrographs of severe fibrosis (epidural adhesion) in the Group I (Control) (in terms of amount of scar tissue: Grade 3). H.E. (A) and Masson trichrome (B). (d: dura mater, f: epidural fibrosis).

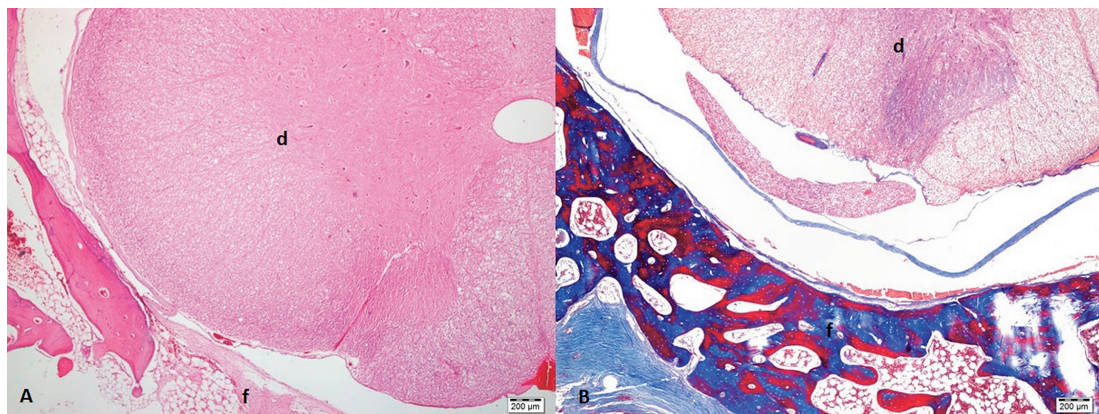


Fig. 4. Photomicrographs of thin fibrosis, no adhesions, duramater free in the Group II (5% PEG 4000) (in terms of amount of scar tissue: Grade 1). H.E. (A) and Masson trichrome (B). (d: dura mater, f: epidural fibrosis).

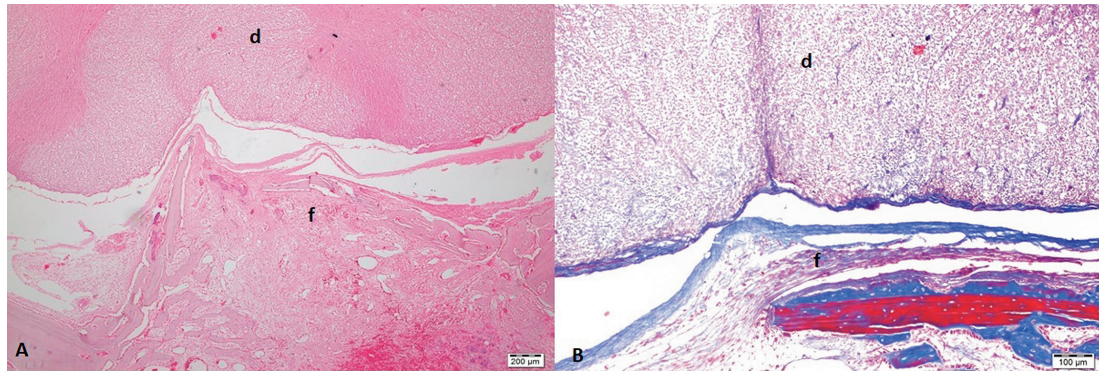


Fig. 5. Photomicrographs of epidural fibrosis in the Group III (HA) (in terms of amount of scar tissue: Grade 2). H.E. (A) and Masson trichrome (B). (d: dura meter, f: epidural fibrosis).

Table 2. Histopathological scoring of epidural scar tissue and adhesions

GROUPS	GRADE 0	GRADE 1	GRADE 2	GRADE 3	Statistical
Group I (Control, n:12)	-	1	2	9	a,b,d
Group II (5% PEG 4000, n:12)	6	4	1	1	a,c,d
Group III (HA, n:12)	1	5	5	1	b,c,d

PEG: Polyethylene Glycol, HA: Hyaluronic acid. a: Group I was significantly different from Group II ($P < 0.000$) b: Group I was significantly different from Group III ($P < 0.001$). c: Group II was significantly different from Group III ($P < 0.034$). d: The difference between the groups was significant ($P < 0.000$).

observed than in the control group (Figure 5A, B). In 5% PEG 4000 group (Group II), the area of hemilaminectomy was closed by new bone formation (two cases).

According to the histopathological scoring of epidural scar tissue and adhesions; in the control group (Group I); presence of only thin fibrous bands between scar tissue and dura matter (in one case Grade 1), continuous adhesions filling less than 2/3 of hemilaminectomy space (in two cases Grade 2) and adhesions filling more than 2/3 the hemilaminectomy space or/and extend to the nerve roots (in 9 cases Grade 3) were detected. In the 5% PEG 4000 group (Group II); dura matter is free of scar tissue (in 7 cases Grade 0), presence of only thin fibrous bands between scar tissue and dura matter (in 4 cases Grade 1) and continuous adhesions filling less than 2/3 of hemilaminectomy space (in one cases Grade 2) were observed. In the HA group (Group

III); dura matter is free of scar tissue (in one case Grade 0), presence of only thin fibrous bands between scar tissue and dura matter (in 5 cases Grade 1), continuous adhesions filling less than 2/3 of hemilaminectomy space (in 5 cases Grade 2) and adhesions filling more than 2/3 the hemilaminectomy space or/and extend to the nerve roots (in one case Grade 3) were detected (Table 2).

According to the histopathological scoring of epidural scar tissue and adhesions, 5% PEG 4000 group (Group II) was significantly different from Group I ($P < 0.000$) and Group III ($P < 0.034$). HA group (Group III) was significantly different from control group (Group I) ($P < 0.001$). The difference between the groups was significant ($P < 0.000$).

Discussion

It has been suggested that laminectomy enhances vascular permeability in the cauda equina, vesicular transport in endothelial cells, the increase in vascular permeability may be due to epidural inflammation, and the increase in permeability may increase epidural adhesions⁴³. What the place of the scar tissue in the etiology of postoperative pain is not fully understood. Epidural fibrosis not only results with pain but also it results with sensory and motor deficiency in related dermatomes¹⁶. However, it has been reported that scar tissue made pressure the peripher anatomical structures and enhances the sensitivity of the nerve root the result of limits the movements of the nerve root, as well as the under of the scar tissue is neuronal atrophy and axonal degeneration^{21,26,63}. Nerve roots can be pulled and compressed by the contraction of surrounding scar adhesions, affecting axoplasmic transport in nerve fibers, arterial blood supply, and venous drainage^{28,64}. In this study, in sections with dense scar tissue, it was observed that the scar tissue adhered to the dura mater and pulled the dura mater and nerve tissues. Similar results have been reported by Bulut *et al*¹⁰.

Osseous regeneration has been determined in the decompression areas (laminectomy and hemilaminectomy) in the majority of experimental studies⁵. Formation of new bone starts from the laminectomy area and osteoblasts are activated²⁴. It has been reported that bone regeneration take place at a rate of 50% in 8th weeks and 75% in 12th weeks¹⁸. In another study has been found a 5-10% reduction in the laminectomy defect at the end of 4th weeks²⁰. In this study, hemilaminectomy size decreased by approximately 1 mm at 8th and 12th weeks. In two cases the area of hemilaminectomy were closed by new bone formation. It has also been reported that postoperative scarring may be limited by making the laminectomy defect as small as possible¹³. In clinical practice, it should be known that the decompression area can be

closed by new bone formation.

It has been reported that gel and seprafilm forms of hyaluronic acid are more effective than use of hyaluronic acid in prevention epidural fibrosis^{26,38,42}. According to the gross score of epidural fibrosis and histopathological scoring of epidural scar tissue, PEG 4000 (5%) was found to be more effective than hyaluronic acid in the prevention of epidural fibrosis.

PEG 4000 is a nontoxic macromolecule²⁷. It provides healing without adhesion via covering defective surfaces or by means of a polymer layer. PEG 4000 is keep denatured proteins in traumatized area and enhances its cosolvent activity^{4,25,41}. PEG 4000 also changes enzyme activity and enzyme structure and forms a hydrophilic layer around the enzyme⁴⁴. PEG 4000, which has the antibacterial property⁴⁵, forms a barrier between the dura mater and the tissues, thereby preventing the formation of epidural fibrosis during the healing process.

Different forms of polyethylene glycol have been used to prevent epidural fibrosis. It has been reported that Silk-Polyethylene Glycol Hydrogels and Mitomycin C-Polyethylene Glycol film combinations reduced the formation of epidural fibrosis^{39,62}. Polyethylene Glycol 4000 (5%) has been used for prevention of adhesions after intraabdominal surgeries and tenoraphy^{12,27}. This study demonstrated that 5% Polyethylene Glycol 4000 can also be used in the prevention of epidural fibrosis. It is an alternative option to the use of hyaluronic acid both economically and in terms of prevention of epidural fibrosis.

Different mechanical barriers, drugs and methods have been used to prevent epidural fibrosis^{1,13,38,49,51,53,56,60,65,67,68}. It was reported that the methodologies used to prevent epidural fibrosis in experimental studies have mostly been unsatisfactory in their clinical applicability, thus, epidural fibrosis continues to be clinically problem²⁶. Satisfactory result has not yet been achieved. Surgical intervention to be applied to remove fibrous tissue is often associated with poor results and newly formed scar tissue. The

goal of treatment is to reduce the incidence of epidural fibrosis⁶¹. Multiple factors (such as postoperative infection, and hematoma, individual variability in the degree of scar formation, amount of bone removed, laminectomy techniques and anatomic location within vertebral column) are involved important roles in the pathogenesis of epidural fibrosis^{30,61}. It is important to know that the individual's wound healing process, the level of traumatization of the tissue, bleeding control, infection and foreign bodies play a role at the scar formation and amount. In this study, severe epidural fibrosis was detected in 9 case in the control group (Group I) despite minimal traumatization of the tissue, bleeding control, and no postoperative infection. In addition to appropriate surgical procedures for the prevention of epidural fibrosis, local or systemic drugs and barriers should be used.

Conclusion

Polyethylene Glycol 4000 (5%) in the prevention of epidural fibrosis encountered as a postoperative complication after hemilaminectomy is an alternative option to the use of hyaluronic acid both economically and in terms of prevention of epidural fibrosis.

Conflict of Interest

Authors have no competing interest.

References

- 1) Akesson WH, Massie JB, Huang B, Giurea A, Sah R, Garfin SR, Kim CW. Topical high-molecular-weight hyaluronan and a roofing barrier sheet equally inhibit postlaminectomy fibrosis. *Spine J* 5, 180-190, 2005
- 2) Alkalay RN, Kim DH, Urry DW, Xu J, Parker TM, Glazer PA. Prevention of postlaminectomy epidural fibrosis using bioelastic materials. *Spine* 28, 1659-1665, 2003
- 3) Annertz M, Jonsson B, Stromqvist B, Holtas S. No relationship between fibrosis and sciatica in the lumbar postdiscectomy syndrome: A study with contrast-enhanced magnetic resonance imaging in symptomatic and asymptomatic patients. *Spine* 20, 449-453, 1995
- 4) Arakawa T, Timasheff SN. Mechanism of poly (ethylene Glycol) Interaction with proteins. *Biochemistry* 24, 6756-6762, 1985
- 5) Aydincak O, Yilmaz MB, Emmez H, Kurt G, Sepici A, Memis L, Baykaner K. The effect of temozolomide on the prevention of epidural fibrosis developing after lumbar laminectomy in rats. *Turk Neurosurg* 22, 706-711, 2012
- 6) Berker C, Tun K, Kaptanoglu E, Kaymaz F, Cevirgen B, Comert A, Tekdemir I. Use of pimecrolimus to prevent epidural fibrosis in a postlaminectomy rat model. *J Neurosurg Spine* 11, 758-763, 2009
- 7) Besaltı O. Kopeklerde laminektomi ve hemilaminektomilerde uygulanan yag dokusu ve spongostan'in etkileri uzerine deneysel calismalar. *Ankara Univ Vet Fak Derg* 43, 457-467, 1996
- 8) Bottegaro NB, Kos J, Pirkic B, Smolec O, Grabarevic Z, Hohsteter M, Selanec J, Vrbanac Z. Reduction of epidural fibrosis after laminectomy in rabbits by omental free graft. *Vet Med* 58, 25-31, 2013
- 9) Bryant MS, Bremer AM, Nyugen TQ. Autogeneic fat transplants in the epidural space in routine lumbar spine: MR imaging assesment. *AJNR* 9, 169-178, 1988
- 10) Bulut G, Dogan S, Doygun M. The effectiveness of omental greft in preventing epidural fibrosis after the spinal surgery: An experimental study. *Uludag Universitesi Tip Fakultesi Dergisi* 33, 115-119, 2007
- 11) Canbulat N. Bel Agrisinda Rehabilitasyon ve Fizyoterapi. In: Omurilik ve Omurga Cerrahisi, 2nd ed. Zileli M, Ozer AF. eds. Meta Basim, Izmir. pp. 1791-1800, 2002.
- 12) Canpolat I, Kilic S, Bulut S, Eroksuz H, Karabulut E. Tenorafi uygulanan at ve merkeplerde adezyonlari onlemek icin silikon tup ve polietilen glikolun (PEG) kullanimi. *Veteriner Cerrahi Dergisi* 3, 37-41, 1997
- 13) Chandler K, Cappello R. Laminectomy membrane formation in dogs: Is the answer still elusive? *Vet J* 172, 1-2, 2006
- 14) Choi HJ, Kim KB, Kwon YM. Effect of amniotic membrane to reduce postlaminectomy epidural adhesion on a rat model. *J Korean*

- Neurosurg Soc 49, 323-328, 2011
- 15) Circi E, Ozalay M, Caylak B, Bacanli D, Derincek A, Tuncay IC. The effect of oophorectomy on epidural fibrosis after laminectomy: An experimental study in rats. *Acta Orthop Traumatol Turc* 47, 193-200, 2013
 - 16) Cokluk C, Aydin K, Tumkaya L. Grading of epidural fibrosis in a new rabbit experimental model for epidural adhesive scar tissue formation. *J Exp Clin Med* 26, 107-111, 2009
 - 17) Cokluk C, Aydin K, Tumkaya L. The effect of Omega-3 solution in the prevention of epidural fibrosis formation in experimental rabbit hemilaminotomy model. *J Exp Clin Med* 27, 16-19, 2010
 - 18) Cook SD, Prewett AB, Dalton JE, Witecloud TS. Reductin in perineural scar formation after laminectomy with polyactive membrane heets. *Spine* 19, 1815-1825, 1994
 - 19) DiFazio FA, Nichols JB, Pope MH, Frymoyer JW. The use of expanded polytetrafluoroethylene as an interpositional membrane after lumbar laminectomy. *Spine* 20, 986-991, 1995
 - 20) Einhaus SL, Robertson JT, Dohan FCJ, Wuek JR, Ahmad S. Reduction of peridural fibrosis after lumbar laminotomy and discectomy in dogs by a resorbable gel Adcon-L. *Spine* 22, 1440-1447, 1997
 - 21) Gerszten PC, Moossy JJ, Flickinger JC, Gerszten K, Kalend A, Martinez AJ. Inhibition of peridural fibrosis after laminectomy using low-dose external beam radiation in a dog model. *Neurosurgery* 46, 1478-1485, 2000
 - 22) Gorgulu A, Simsek O, Cobanoglu S, Imer M, Parsak T. The effect of epidural free fat graft on the outcome of lumbar disc surgery. *Nuerosurg Rev* 27, 181-184, 2004
 - 23) Gurer B, Kahveci R, Gokce EC, Ozveren H, Turkoglu E, Gokce A. Evaluation of topical application and systemic administration of rosuvastatin in preventing epidural fibrosis in rats. *Spine J* 15, 522-529, 2015
 - 24) He Y, Revel M, Loty B. A quantitative model of postlaminectomy scar formation. Effects of a nonsteroidal antiinflammatory drug. *Spine* 20, 557-563, 1995
 - 25) Ingham KC. Precipitation of proteins with polyethylene glycol. *Methods in Enzymology* 182, 301-306, 1990
 - 26) Isik S, Taskapilioglu O, Oz Atalay F, Dogan S. Effects of cross-linked high-molecular-weight hyaluronic acid on epidural fibrosis: Experimental study. *J Neurosurg Spine* 22, 94-100, 2015
 - 27) Karabulut E. Tavsanlarda deneysel olarak olusturulan; intraabdominal adezyonların onlenmesinde polyethylene glycol ve dextran'ın karsilastirmali arastirilmesi. *F U Saglik Bilimleri Dergisi* 9, 272-282, 1995
 - 28) Karanci T, Kelten B, Karaoglan A, Cinar N, Midi A, Antar A, Akdemir H, Yalcinkaya Kara ZM. Effects of 4% Icodextrin on experimental spinal epidural fibrosis. *Turk Neurosurg* 27, 265-271, 2017
 - 29) Karatay M, Erdem Y, Koktekir E, Erkoc YS, Caydere M, Bayar MA. The effect of bevacizumab on spinal epidural fibrosis in a postlaminectomy rat model. *Turk Neurosurg* 22, 753-757, 2012
 - 30) Kasimcan MO, Bakar B, Aktas S, Alhan A, Yilmaz M. Effectiveness of the biophysical barriers on the peridural fibrosis of a postlaminectomy rat model: An experimental research. *Injury* 42, 778-781, 2011
 - 31) Kato T, Haro H, Komori H, Shinomiya K. Evaluation of hyaluronic acid sheet for the prevention of postlaminectomy adhesions. *Spine J* 5, 479-488, 2005
 - 32) Kaya B, Esen HH, Ustun ME. A comparison of the effects of adcon-L, mitomycin C and sodium hyaluronate in experimental epidural fibrosis in rabbits. *J Neurol Sci Turk* 28, 236-242, 2011
 - 33) Kaya M, Yildirim CH, Kosemehmetoglu K, Huseyinoglu U, Erdogan H, Akbasak A, Tasdemiroglu E. Alpha-lipoic acid reduces peridural fibrosis after laminectomy of lumbar vertebrae in rabbits. *Acta Neurochir (Wien)* 154, 1241-1245, 2012
 - 34) Kemaloglu S, Ozkan U, Yilmaz F, Nas K, Gur A, Acemoglu H, Karasu H, Cakmak E. Prevention of spinal epidural fibrosis by recombinant tissue plasminogen activator in rats. *Spinal Cord* 41, 427-431, 2003
 - 35) Keskin F, Esen H. Comparison of the effects of an adhesions barrier and chitin on experimental epidural fibrosis. *Turk Neurosurg* 20, 457-463, 2010
 - 36) Kurt G, Aytar MH, Dogulu F, Cemil B, Erdem O, Baykaner MK, Ceviker N. A comparison of the local effectiveness of mitomycine C, aprotinin, and adcon-L in experimental peridural fibrosis. *Surg Neurol* 70, 608-613, 2008
 - 37) Li C, Wang H, Liu H, Yin J, Cui L, Chen Z. The prevention effect of poly (L-glutamic acid)/chitosan on spinal epidural fibrosis and peridural adhesion in the post-laminectomy rabbit model. *Eur Spine J* 23, 2423-2431,

- 2014
- 38) Liu H, Li HF, Wang JY. Prevention effect of medical self-crosslinking sodium hyaluronate gel on epidural scar adhesion after laminectomy. *Asian Pac J Trop Med* 7, 501-504, 2014
 - 39) Liu J, Ni B, Zhu L, Yang J, Cao X, Zhou W. Mitomycin C-polyethylene glycol controlled-release film inhibits collagen secretion and induces apoptosis of fibroblasts in the early wound of a postlaminectomy rat model. *Spine J* 10, 441-447, 2010
 - 40) Lv C, Zhou Z, Song Y, Liu L, Liu H, Gong Q, Li T, Zeng J, Tu C, Pei F. Novel biodegradable lamina for lamina repair and reconstruction. *Spine J* 13, 1912-1920, 2013
 - 41) Nagelschmidt M, Minor T, Saad S. Polyethylene glycol 4000 attenuates adhesion formation in rats by suppression of peritoneal inflammation and collagen incorporation. *Am J Surg* 176, 76-80, 1998
 - 42) Nahm FS, Lee PB, Choe GY, Lim YJ, Kim YC. Therapeutic effect of epidural hyaluronic acid in a rat model of foraminal stenosis. *J Pain Res* 10, 241-248, 2017
 - 43) North RB, Campbell JN, James CS. Failed Back surgery Syndrome: 5-Year Follow-up in 102 Patients Undergoing Repeated Operation. *Neurosurgery* 28, 685-691, 1991
 - 44) O'Sullivan D, O'Riordain M, O'Connell RP, Dineen M, Brady MP. Peritoneal adhesion formation after lysis: Inhibition by polyethylene glycol. *Brit J Surg* 78, 427-429, 1991
 - 45) Peng L, Chang L, Liu X, Lin J, Liu H, Han B, Wang S. Antibacterial property of a polyethylene glycol-grafted dental material. *ACS Appl Mater Interfaces* 9, 17688-17692, 2017
 - 46) Prusick VR, Lint DS, Bruder J. Cauda Equina Syndrome as a complication of free epidural fat grafting. *J Bone Joint Surg* 70-A(8), 1256-1258, 1988
 - 47) Rabb CH. Failed back syndrome and epidural fibrosis. *Spine J* 10, 454-455, 2010
 - 48) Robertson JT. Role of epidural fibrosis in the failed back: A review. *Eur Spine J* 5 (Suppl 1), 2-6, 1996
 - 49) Rodgers KE, Robertson JT, Espinoza T, Oppelt W, Cortese S, diZerega GS, Berg RA. Reduction of epidural fibrosis in lumbar surgery with oxiplex adhesion barriers of carboxymethylcellulose and polyethylene oxide. *Spine J* 3, 277-284, 2003
 - 50) Ross JS, Robertson JT, Fredericson RCA, Petrie JL. Association between peridural scar and recurrent radicular pain after lumbar discectomy: Magnetic resonance evaluation. *Neurosurgery* 38, 855-861, 1996
 - 51) Sabuncuoglu H, Bavbek M, Sabuncuoglu B, Gadelha E, Kose K, Preul M. Attenuation of postlaminectomy epidural fibrosis with monoclonal antibodies against intercellular adhesion molecule-1 and CD-18. *Spine J* 7, 459-465, 2007
 - 52) Sandoval MA, Hernandez-Vaquero D. Preventing peridural fibrosis with nonsteroidal anti-inflammatory drugs. *Eur Spine J* 17, 451-455, 2008
 - 53) Schimizzi AL, Massie JB, Murphy M, Perry A, Kim CW, Garfin SR, Akeson WH. High-molecular-weight hyaluronan inhibits macrophage proliferation and cytokine release in the early wound of a preclinical postlaminectomy rat model. *Spine J* 6, 550-556, 2006
 - 54) Su C, Yao C, Lu S, Zhang A, Cao X. Study on the optimal concentration of topical mitomycin-C in preventing postlaminectomy epidural adhesion. *Eur J Pharmacol* 640, 63-67, 2010
 - 55) Sun P, Miao B, Xin H, Zhao J, Xia G, Xu P, Hu J, Li Z, Li J. The effect of resveratrol on surgery-induced epidural fibrosis in laminectomy rats. *Evid Based Complement Alternat Med* doi:10.1155/2014/574236, 2014
 - 56) Sun Y, Wang L, Sun S, Liu B, Wu N, Cao X. The effect of 10-hydroxycamptothecine in preventing fibroblast proliferation and epidural scar adhesion after laminectomy in rats. *Eur J Pharmacol* 593, 44-48, 2008
 - 57) Temel SG, Ozturk C, Temiz A, Ersozlu S, Aydinli U. A new material for prevention of epidural fibrosis after laminectomy: Oxidized regenerated cellulose (Interceed), an absorbable barrier. *J Spinal Disord Tech* 19, 270-275, 2006
 - 58) Temiz C, Temiz P, Sayin M, Ucar K. Effect of cepea extract-heparin and allantoin mixture on epidural fibrosis in a rat hemilaminectomy model. *Turk Neurosurg* 19, 387-392, 2009
 - 59) Topsakal C, Akpolat N, Erol FS, Ozveren MF, Akdemir I, Kaplan M, Tiftikci M, Kilic N. Sefrafilm superior to gore-tex in the prevention of peridural fibrosis. *J Neurosurg* 101, 295-302, 2004
 - 60) Turkoglu E, Dinc C, Tuncer C, Oktay M, Serbes G, Sekerci Z. Use of decorin to prevent epidural fibrosis in a post-laminectomy rat model. *Eur J Pharmacol* 724, 86-91, 2014
 - 61) Turkoglu E, Tuncer C, Dinc C, Serbes G, Oktay M, Sekerci Z. The effect of

- etanercept on spinal epidural fibrosis in a postlaminectomy rat model. *Turk Neurosurg* 24, 506–511, 2014
- 62) Wang Y, Liang M, Zheng Z, Shi L, Su B, Liu J, Kaplan DL, Zhang B, Wang X. Adhesion prevention after laminectomy using silk-polyethylene glycol hydrogels. *Adv Healthc Mater* 4, 2120–2127, 2015
- 63) Yamagami T, Matsui H, Tsuji H, Ichimura K, Sano A. Effects of laminectomy and retained extradural foreign body on cauda equina adhesion. *Spine*, 18, 1774–1781, 1993
- 64) Yang J, Ni B, Liu J, Zhu L, Zhou W. Application of liposome-encapsulated hydroxycamptothecin in the prevention of epidural scar formation in New Zealand white rabbits. *Spine J* 11, 218–223, 2011
- 65) Yildiz KH, Gezen F, Is M, Cukur S, Dasoglu M. Mitomycin C, 5-fluorouracil, and cyclosporin A prevent epidural fibrosis in an experimental laminectomy model. *Eur Spine J* 16, 1525–1530, 2007
- 66) Zeinalizadeh M, Miri SM, Ardalan FA, Makeki F, Zakeri M, Aghajanzadeh E, Habibi Z. Reduction of epidural fibrosis and dural adhesions after lamina reconstruction by absorbable cement: An experimental study. *Spine J* 14, 113–118, 2014
- 67) Zhang C, Kong X, Liu C, Liang Z, Zhao H, Tong W, Ning G, Shen W, Yao L, Feng S. ERK2 small interfering RNAs prevent epidural fibrosis via the efficient inhibition of collagen expression and inflammation in laminectomy rats. *Biochem Biophys Res Commun* 444, 395–400, 2014
- 68) Zhang C, Kong X, Ning G, Liang Z, Qu T, Chen F, Cao D, Wang T, Sharma HS, Feng S. All-trans retinoic acid prevents epidural fibrosis through NF-KB signaling pathway in post-laminectomy rats. *Neuropharmacology* 79, 275–281, 2014