

## RVC OPEN ACCESS REPOSITORY – COPYRIGHT NOTICE

This author's accepted manuscript may be used for non-commercial purposes in accordance with [Wiley Terms and Conditions for Self-Archiving](#).

The full details of the published version of the article are as follows:

TITLE: Successful treatment of canine acute respiratory distress syndrome secondary to inhalant toxin exposure

AUTHORS: Greensmith, T D; Cortellini, S

JOURNAL: Journal of Veterinary Emergency and Critical Care

PUBLISHER: Wiley

PUBLICATION DATE: 8 August 2018 (online)

DOI: <https://doi.org/10.1111/vec.12754>

# Successful treatment of canine acute respiratory distress syndrome secondary to inhalant toxin exposure

Thomas D. Greensmith, BVetMed, MVetMed and Stefano Cortellini, DMV, MVetMed, DACVECC, DECVECC

## Abstract

**Objective** – To describe the successful management of a dog with acute respiratory distress syndrome secondary to inhalant toxin exposure. **Case summary** – An 8-year-old male neutered Greyhound was referred with severe respiratory distress 56 hours after exposure to an aerosol toxicant. The patient developed respiratory difficulties requiring veterinary attention within 12 hours of initial exposure. Treatment at the referral hospital included mechanical ventilation and supportive care. The patient was discharged 5 days after admission to the referral hospital. **New or unique information** – This is the first report, to the authors' knowledge, of canine acute respiratory distress syndrome secondary to inhalant toxin exposure not associated with smoke inhalation. The report summarizes the provided care and subsequent successful outcome.

*(J Vet Emerg Crit Care 2018; 00(0): 1–7) doi: 10.1111/vec.12754*

**Keywords:** acute lung injury, ARDS, canine, mechanical ventilation, pulmonary injury

## Abbreviations

ARDS acute respiratory distress syndrome

BAL bronchoalveolar lavage

CT computed tomography

PEEP positive end-expiratory pressure

VetARDS veterinary acute lung injury and acute respiratory distress syndrome

## Introduction

Acute lung injury and acute respiratory distress syndrome (ARDS) share the same inflammatory related pathophysiology and are differentiated by the degree of hypoxemia.<sup>1</sup> Precise definitions of the 2 syndromes exist in people,<sup>2</sup> although acute lung injury is no longer part of the recommended terminology in human medicine.<sup>3</sup> Definitions for veterinary acute lung injury and acute respiratory distress syndrome (VetARDS) were created by the Dorothy Havemeyer working group and are described elsewhere.<sup>4</sup>

Many risk factors have been documented for ARDS in people and these are assumed to be similar in dogs.<sup>4</sup> Veterinary acute lung injury and acute respiratory distress syndrome is a rare clinical entity with only sporadic reports in the veterinary literature

of successful management in dogs<sup>5-7</sup>; however, inhalant toxins (including the compounds outlined in this report) other than smoke have not been documented as a cause for VetARDS.<sup>1</sup> A previously published case series describes 2 dogs that developed chemical pneumonitis secondary to inhalation of a waterproofing spray containing hydrocarbons.<sup>8</sup> Both dogs recovered with supportive care; however, neither dog was definitively diagnosed with VetARDS due to a lack of arterial blood gas sampling.

This report describes a case of canine VetARDS following exposure to an inhalant toxin, a commercial grout protector spray,<sup>a</sup> along with its management and successful outcome. The constituents of the spray are fluorinated carbon polymers, petroleum naphtha, heptane, butane, and propane (2-3%, 10-20%, 30-60%, 10-30%, and 10-30% by weight, respectively).

### **Case Summary**

An 8-year-old, 28.5 kg male neutered Greyhound was referred to the Emergency Service of the Queen Mother Hospital for Animals of the Royal Veterinary College for acute onset of respiratory distress characterized by increased respiratory effort and tachypnea. The patient had been previously healthy other than a history of well controlled hypothyroidism.

On the day of initial presentation to the primary veterinarian (12 hours from exposure), both the owners and the patient were exposed to an aerosolized grout protection product<sup>a</sup> documented by the manufacturers to be an irritant, with strict recommendations to avoid inhalation of any fumes/vapors via adequate ventilation of enclosed spaces or the use of an appropriate breathing apparatus. Both owners developed self-limiting respiratory signs, with one requiring hospitalization within 24 hours of exposure. The dog described in the current report was assessed by his primary care veterinarian for acute onset of tachypnea with the remainder of the clinical examination being unremarkable. Serum biochemistry and survey thoracic radiographs were reported as unremarkable. Hematology revealed increased hematocrit, increased RBC concentration, and increased hemoglobin, all findings consistent with his breed.<sup>9</sup> Oxygenation was assessed once during hospitalization, with an oxygen saturation (SpO<sub>2</sub>) (36 hours post-exposure) reported as >95%. Supportive care was provided including meloxicam, intravenous fluid therapy, cefuroxime, and metoclopramide; no supplemental oxygen was provided. Due to progressive respiratory deterioration, he was referred for further diagnostic evaluation and intensive care.

On admission to the intensive care unit at the Queen Mother Hospital for Animals (56 hours following exposure) the dog had markedly increased respiratory effort and orthopnea, with a respiratory rate of 130/min. Rectal temperature was normal (38.5°C [101.3°F]). No abnormalities were noted with the cardiovascular system. Thoracic

auscultation revealed increased bronchovesicular noises bilaterally, considered to be consistent with the patient's degree of increased respiratory effort. No adventitious respiratory sounds were audible. The remainder of the physical examination was unremarkable.

Bilateral nasal cannulae were placed and oxygen was administered at 50–100 mL/kg/min. While receiving supplemental oxygen, an arterial blood sample<sup>b</sup> was taken yielding severe hypoxemia (Table 1). Biochemistry<sup>c</sup> documented mildly increased creatine kinase (Table 2). Hematology<sup>d</sup> documented mild lymphopenia with increased RBC concentration, hemoglobin, hematocrit, and mean corpuscular hemoglobin (Table 2). An *Angiostrongylus vasorum* ELISA<sup>e</sup> was negative.

Due to the severity of hypoxemia, and subjective concern for respiratory fatigue, the patient was anesthetized 5 hours after presentation using midazolam,<sup>f</sup> fentanyl,<sup>g</sup> and propofol,<sup>h</sup> and a sterile endotracheal tube was placed. Volume-controlled mechanical ventilation<sup>i</sup> with positive end expiratory pressure (PEEP) of 7.8 cm H<sub>2</sub>O, tidal volume of 10.1 mL/kg, and FiO<sub>2</sub> of 0.8 was initiated. General anesthesia was maintained using infusions of midazolam (0.17–0.25 mg/kg/hr), fentanyl (0.05–0.2 µg/kg/min), and propofol (0.08–0.2 mg/kg/min) and the patient was instrumented with arterial, central venous, and urinary indwelling catheters. Patient monitoring consisted of continuous electrocardiography, capnography, pulse oximetry, and direct blood pressure monitoring.

Computed tomography<sup>j</sup> (CT) of the thorax was performed and revealed a marked increase in soft tissue attenuation in all lung lobes, with a peripheral rim of unaffected lung (Figure 1). A blind bronchoalveolar lavage (BAL) was performed and cytology was nondiagnostic due to low cellularity. There was no evidence of intra- or extracellular bacteria, and culture subsequently revealed no growth of microorganisms.

Within 3 hours of starting mechanical ventilation oxygenation markedly improved (Table 1). However, hypercapnia and acidemia developed (Table 1). A point-of-care thoracic ultrasound examination revealed no evidence of pneumothorax or pleural effusion. Despite the degree of lung involvement on CT only minimal B lines (“lung rockets”) were noted<sup>10</sup> and no evidence of left atrial enlargement was identified that would be suggestive of left sided heart failure. An ACTH stimulation test, and a Baermann fecal floatation exam excluded hypoadrenocorticism and *Angiostrongylus vasorum*, respectively.

During the first 23 hours of ventilation, PaCO<sub>2</sub> remained increased reaching a peak of 108.2 mm Hg (Table 1) despite a respiratory rate of 28–37/min, and tidal volume of 7.9–12.4 mL/kg. Over the following 21 hours, tidal volume was increased further (12.6–14.5 mL/kg) and PaCO<sub>2</sub> decreased, remaining below 65 mm Hg, with subsequent improvement in acidemia.

After 40 hours of mechanical ventilation, the patient's respiratory secretions appeared progressively more viscous and purulent. A second blind BAL was performed and in-clinic cytology revealed neutrophilic inflammation with no observed intracellular bacteria. The patient's oxygenation remained acceptable on an  $\text{FiO}_2$  of 0.4 (Table 1), and it was deemed appropriate to attempt weaning the patient from the mechanical ventilation. A dose of hydrocortisone<sup>k</sup> (1 mg/kg IV) was administered prior to weaning to reduce the mild oropharyngeal swelling that had developed during mechanical ventilation. Prior to disconnection from the ventilator, the PEEP was decreased over a 4-hour period. During the same period, the  $\text{FiO}_2$  was titrated down (from 0.4 to 0.3); propofol, midazolam, and fentanyl infusions were tapered and stopped completely upon ventilator disconnection. For the final hour of ventilation, the mode was switched to synchronized intermittent mandatory ventilation with a low level of pressure support (starting at 6 cm  $\text{H}_2\text{O}$  and gradually decreasing to 2 cm  $\text{H}_2\text{O}$  during the hour) to assess if adequate respiratory muscle strength was present. Urine output during the entire period of mechanical ventilation remained low (0.35–1.7 mL/kg/hr), but with normal specific gravity (1.045), and the patient developed progressive mild pitting edema in all four limbs and face. The patient was extubated within 1 hour after disconnection from the ventilator, having spent total of 44 hours on mechanical ventilation and 45 hours intubated. Following extubation, the patient became agitated and was subsequently administered 2 doses of methadone<sup>l</sup> (0.1 mg/kg IV) and one dose of medetomidine<sup>m</sup> (1  $\mu\text{g}/\text{kg}$  IV).

Following weaning, nasal oxygen was administered at 50 mL/kg/min using the previously placed bilateral nasal cannulae. Rectal temperature began to increase (reaching a maximum of 40.0°C [104°F]) within the 4-hour period following disconnection from the ventilator. At the same time as the increased rectal temperature, reference laboratory evaluation of the second blind BAL documented neutrophilic inflammation with rare intracellular cocci and rods. Empiric intravenous amoxicillin clavulanate<sup>n</sup> was initiated (20 mg/kg IV every 8 hours) 6 hours from obtaining the second BAL while awaiting the culture results. Rectal temperature returned to normal (38.9°C [102°F]) within 24 hours following disconnection from the ventilator. The patient remained hypoxemic when breathing room air until 30 hours after disconnection, when normoxemia was documented (Table 1); oxygen supplementation was discontinued at this stage. When the dog began to eat, levothyroxine sodium<sup>o</sup> was restarted. Several decubitus ulcers had developed over bony prominences and 1 site on the distal left radius began discharging purulent material. This material was sampled and submitted for culture, and topical therapy with 0.05% chlorhexidine was initiated. Eleven hours after disconnection from the ventilator, the patient was eating, drinking, and fully ambulatory; 78 hours after disconnection the patient was discharged.

Following discharge, the patient received a 5 day course of oral amoxicillin clavulanate<sup>p</sup> (11.4 mg/kg orally every 12 h) for his suspected bacterial pneumonia, tramadol<sup>q</sup> (1.75

mg/kg orally every 8 h) for mild joint pain following prolonged recumbency and levothyroxine sodium<sup>o</sup> (28.1 µg/kg orally every 12 hr). Following discharge culture results for the discharging decubitus ulcer were reported as *Escherichia coli*, *Pseudomonas aeruginosa*, and *Enterococcus faecium*, all of which were resistant to amoxicillin clavulanate. At the time these results were available the ulcer had fully healed and the patient had finished his initial course of antimicrobial therapy. Culture results for the second BAL were also available and documented no growth of microorganisms. As the dog was reported to be doing well, no additional antimicrobials were prescribed. No repeat thoracic imaging was performed at any stage due to the owners' financial constraints.

On discussion with the owners 8 months after discharge the dog was reported to be clinically normal, with no change to his quality of life or on his level of function. His owners reported full recovery to his predisease state occurred within 2 weeks of discharge from the hospital.

## **Discussion**

This report describes the development of VetARDS following exposure to an inhalant toxicant in the dog. Current guidelines<sup>4</sup> define VetARDS as acute onset (<72 hr) of tachypnea and labored breathing at rest, in the presence of known risk factors, with evidence of inefficient gas exchange. Tachypnea was noted within 12 hours of exposure to the toxic vapor, with a PaO<sub>2</sub>/FiO<sub>2</sub> ratio <200 upon admission to the referral hospital (56 hours from exposure). The guidelines also require evidence of pulmonary capillary leak in the absence of increased pulmonary capillary pressures; although the patient was not assessed by a board-certified cardiologist, there was no prior history of cardiac disease and point-of-care ultrasound examination did not show evidence of left atrial enlargement. Other diseases that may have caused severe respiratory distress, such as preexisting pneumonia and *Angiostrongylus vasorum* infection, were excluded based on initial BAL, ELISA testing, and Baermanns', respectively. Infectious pneumonia as a cause for the patient's VetARDS was deemed highly unlikely on the basis of 2 negative BAL cultures, along with atypical CT findings. Fungal pneumonia was discounted as neither BAL cytology was suggestive of fungal disease, and the patient had never travelled outside the United Kingdom. Neurogenic and negative pressure pulmonary edema were also unlikely due to the lack of predisposing factors, such as seizures or upper airway obstruction, along with the atypical pattern of pulmonary pathology. A nonmandatory criterion for VetARDS is evidence of diffuse alveolar inflammation.<sup>4</sup> The authors are unable to fulfill this criterion as the initial BAL sample was hypocellular and may not have been a representative airway sample; the second BAL sample, while neutrophilic, documented bacteria.

Given that the patient's clinical signs developed shortly after exposure to the toxic vapor and resolved without the use of targeted treatment (ie, initial antibiotics or

furosemide), along with the lack of evidence of other identifiable disease processes to explain the sudden respiratory dysfunction, the authors believe that the toxic exposure resulted in VetARDS in this patient.

The initial hypoxemia noted improved rapidly after instituting mechanical ventilation (Table 1). Based solely on the  $\text{PaO}_2/\text{FiO}_2$  ratio used in the Berlin definitions,<sup>3</sup> our patient would be classified as having 'moderate' ARDS initially, improving to 'mild' ARDS following 3 hours of mechanical ventilation. The Berlin definition requires arterial sampling be performed with a PEEP of 5 cm  $\text{H}_2\text{O}$ ; it is known that changes in both ventilator settings and  $\text{FiO}_2$  affect the  $\text{PaO}_2/\text{FiO}_2$  ratio in people.<sup>11-13</sup> Current VetARDS criteria do not include any requirement for PEEP during arterial sampling.<sup>4</sup>

Even with predefined PEEP levels, standardized ventilator settings have been shown to affect the stratification of ARDS patients in people.<sup>11</sup> Similar to the case presented here, both patients outlined by Kelmer et al also experienced marked improvements in the  $\text{PaO}_2/\text{FiO}_2$  ratio within the first 2 hours of invasive mechanical ventilation.<sup>5</sup> The authors therefore believe that the marked changes in the  $\text{PaO}_2/\text{FiO}_2$  ratio prior to and after instituting mechanical ventilation, are likely due to the application of PEEP and positive pressure ventilation. Acute respiratory distress syndrome in people must develop within 7 days of the injury or insult, but it is not classified based on the duration of ARDS itself.<sup>3</sup> While many cases of ARDS in people have a prolonged time course, depending on etiology, some patients have a short duration of ARDS.<sup>14</sup>

Although the patient presented in this case improved quickly, and required only 44 hours of mechanical ventilation, according to the current veterinary definitions, the patient fulfilled all criteria for VetARDS. Other currently confirmed cases of canine VetARDS have required between 17.5 hours and 13 days of mechanical ventilation.<sup>5,7</sup> In a case series of dogs with respiratory distress, 10 patients underwent mechanical ventilation with a range of 2-92 hours (median 18.5 hr); 5 of these dogs fulfilled the human definition for ARDS as defined at that time.<sup>15</sup> It seems logical to conclude that the underlying etiology and pathophysiology, along with the variable host response to tissue injury, may explain the difference in duration of VetARDS cases reported thus far.

The exact etiology of ARDS development following nonthermal inhalation injury varies depending on the toxin, not all constituents of the product described in this report have been thoroughly investigated as to their mechanism of pulmonary damage. Pulmonary injury following exposure to waterproofing grout sealers has been documented in people.<sup>16</sup> A case report exists of a human developing ARDS after inhalation of vapors from heating fluorinated carbon polymers. The patient exhibited the same relative sparing of peripheral lung parenchyma on CT, required invasive mechanical ventilation and was discharged 8 days after toxic exposure.<sup>14</sup> The product inhaled by our patient contained fluorinated carbon polymers at 2-3% by weight. The mechanism of

pulmonary injury from fluorinated carbon polymers is unknown, but may be due to surfactant disruption and subsequent alveolar collapse or type II pneumocyte injury.<sup>16,17</sup> Another component of the product described is naphtha (petroleum) at 10–20% by weight; naphtha vapor is known to be directly irritant to the respiratory and mucous membrane epithelium<sup>18</sup> and may account for some degree of the oropharyngeal swelling noted prior to extubation. Prolonged orotracheal intubation likely accounts for the majority of the oropharyngeal swelling, given that it was not documented initially but appeared toward the end of mechanical ventilation. Finally, the hydrocarbons contained within the product described in this report (heptane, butane, and propane; 30–60%, 10–30%, and 10–30% by weight, respectively) have been reported to cause ARDS when inhaled in people, due to loss of surfactant and subsequent alveolar collapse.<sup>19</sup> Hydrocarbons, as a group, are known to be directly irritant to the pulmonary tract, reducing surfactant levels, promoting pulmonary inflammation, bronchospasm, pulmonary edema, and necrosis<sup>20,21</sup>; the net effects of these is reduced pulmonary compliance, hypoxemia, and in some cases ARDS.<sup>21</sup> The case presented in this report bears numerous similarities to previously reported chemical pneumonitis in 2 dogs following hydrocarbon inhalation<sup>8</sup> with respect to the temporal relationship of toxic exposure, clinical deterioration over the first 24–72 hours, and subsequent complete recovery. Pneumonitis is likely part of the same spectrum of disease as ARDS<sup>1</sup> and the dogs reported previously by Young et al may have had VetARDS. However, without a more thorough diagnostic workup (including blood gas analysis) the dogs do not meet the current definition.<sup>4</sup> Neither of those dogs required mechanical ventilation and both recovered following supportive treatment with supplemental oxygen, bronchodilators, intravenous fluids, and either steroids or antimicrobials (1 dog each respectively). The dog presented in this report was mechanically ventilated allowing thorough diagnostic evaluation, including bronchoalveolar lavage and arterial sampling, to be performed with reduced risk to the patient.

Although this patient ultimately survived to discharge, several complications were encountered during the treatment period. Marked hypercapnia and acidemia that were responsive only to marked elevations in tidal volume occurred, with administration of tidal volumes higher than desired for a lung protective ventilation strategy. The use of lower tidal volumes in people with ARDS has resulted in improved survival rates;<sup>22</sup> however, in this patient lower tidal volumes resulted in marked hypercapnia, reduced arterial oxygen tension, and severe respiratory acidosis (Table 1) despite increases in ventilator set respiratory rate until tidal volumes of 12.6–14.5 mL/kg were used. The commonly cited normal canine tidal volume is 10–15 mL/kg;<sup>23</sup> human athletes have higher tidal volumes than the normal population<sup>24</sup> and given the highly athletic nature of the Greyhound breed, it is reasonable to assume similar physiologic adaptations may exist. The authors feel that a lung protective ventilation strategy extrapolated from human medicine guidelines, with tidal volumes of 6–8 mL/kg,<sup>22</sup> may not be directly applicable to all veterinary patients (eg, due to differences in chest conformation,



internal thoracic volume, and respiratory system compliance between species and breeds) and further work could focus on the optimum ventilator settings in VetARDS patients. Low volume tidal ventilation (less than 10-15 mL/kg) has been proven to cause incremental decreases in pH, increased PaCO<sub>2</sub>, and decreased lung compliance, but was well tolerated in a population of healthy dogs.<sup>25</sup> The authors stipulated that the effects of low tidal volume ventilation in patients with VetARDS required further investigation. In this specific case, permissive hypercapnia was initially adopted but later abandoned due to persistent acidosis. Permissive hypercapnia is a cornerstone of lung protective ventilator strategies. In tolerating increased PaCO<sub>2</sub> levels, the aim is to avoid damage induced by increased lung stretching.<sup>26</sup> In one prospective study into permissive hypercapnia in people, the mean PaCO<sub>2</sub> documented was 67 mm Hg, with an associated decrease in arterial pH (mean 7.23).<sup>27</sup> It is not currently known if the beneficial effects of permissive hypercapnia are due to the elevated carbon dioxide itself or the acidosis, and buffering of the acidosis is controversial.<sup>2</sup>

### ***Conclusions***

Inhalant toxin exposure, other than smoke, has not previously been reported as a cause of VetARDS. The temporal relationship, lack of any other defined risk factors, and concurrent respiratory issues experienced by the owners in contact with the same substance make it the most likely cause for VetARDS in this dog. Successful recovery was documented in this case following 44 hours of mechanical ventilation despite several complicating factors.

### ***Acknowledgments***

The authors wish to thank Dr. Panagiotis Mantis and Dr. Emma Mapletoft for their help in acquiring, interpreting, and reporting the CT findings in this case.

### ***Tables and Figures***

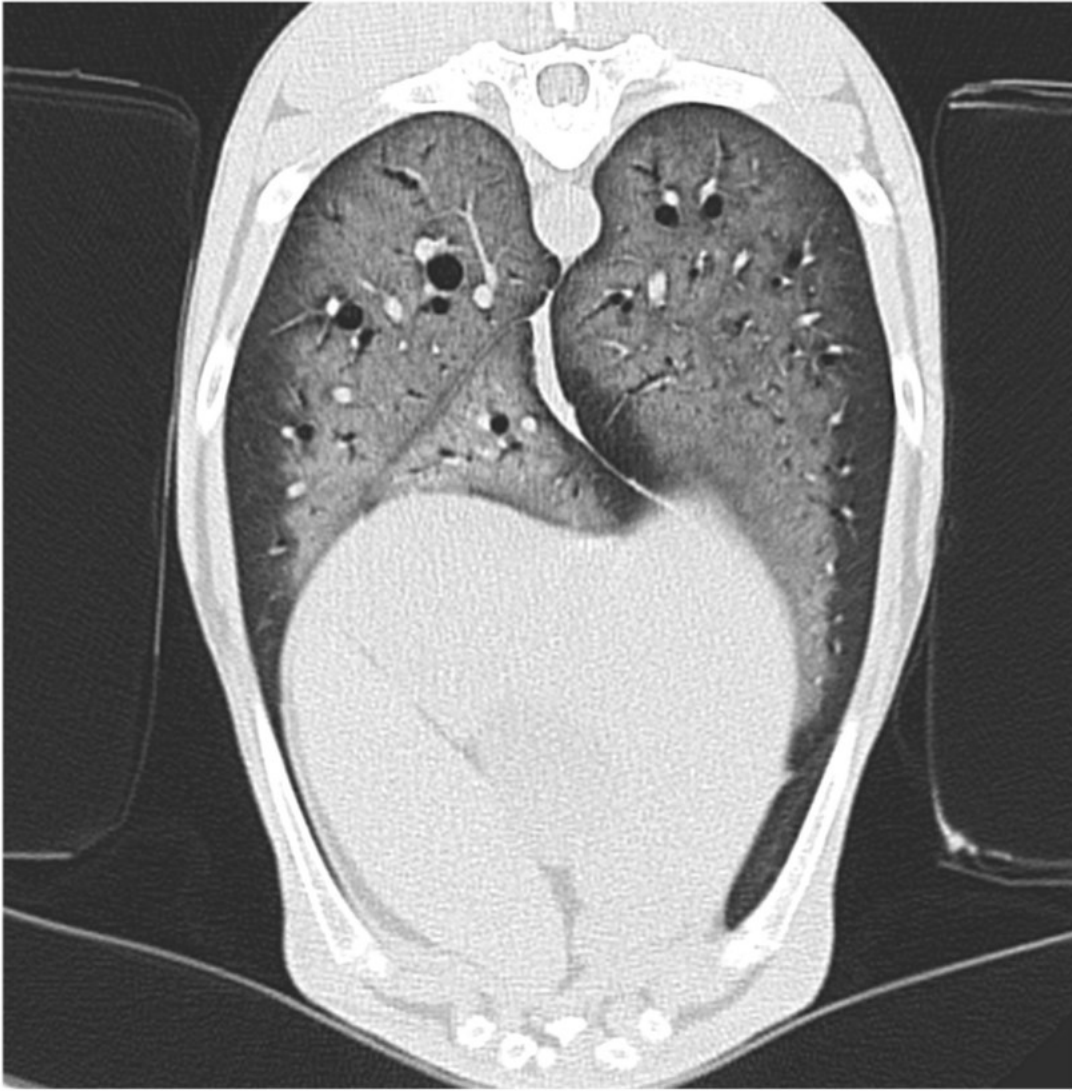
**Table 1:** Selected blood gas, acid-base, and ventilation parameters during hospitalization in dog exposed to inhalant toxicant

Hours	-2 <sup>§</sup>	3 <sup>§</sup>	7 <sup>§</sup>	9 <sup>§</sup>	11 <sup>§</sup>	14 <sup>§</sup>	15.5 <sup>§</sup>	21 <sup>§</sup>	23 <sup>§</sup>	27 <sup>§</sup>	33 <sup>§</sup>	43.5 <sup>§</sup>	0.5 <sup>§</sup>	2 <sup>  </sup>	22 <sup>  </sup>	30 <sup>  </sup>
RR	130	30	30	28	28	28	33	34	37	37	37	37	47	36	40	32
pH	7.40	7.25	7.19	7.22	7.31	7.16	7.07	7.15	7.23	7.31	7.31	7.34	7.40	7.36	7.49	7.44
PaCO <sub>2</sub> (mm Hg)	32.7	65.2	75.5	71.8	55.6	82.5	108.2	89.4	68.1	50.8	46.0	42.0	31.4	38.9	27.6	32.8
ETCO <sub>2</sub> (mm Hg)	NA	42	46	48	35	44	60	48	28	30	26	24	NA	NA	NA	NA
PaO <sub>2</sub> (mm Hg)	45.6	114.9	122.2	149.8	235.0	84.9	87.5	123.2	129.6	123.4	129.2	98.7	57.5	165.0	67.6	85.6
FiO <sub>2</sub>	0.3	0.4	0.5	0.5	0.6	0.5	0.5	0.45	0.45	0.4	0.4	0.3	0.21	0.4	0.21	0.21
PaO <sub>2</sub> /FiO <sub>2</sub>	152	287	244	300	392	170	175	273	288	309	323	329	274	413	322	408
V <sub>T</sub> (mL/kg)	NA	10.2	10.3	11.2	11.9	7.9	8.6	9.8	12.4	12.6	12.6	14.5	NA	NA	NA	NA
PEEP (cm H <sub>2</sub> O)	NA	7.8	8.0	8.3	8.4	8.3	8.3	10.0	9.3	9.2	8.3	5.7	NA	NA	NA	NA
Creatinine (μmol/L) [mg/dL]	NA	111 [1.26]	84 [0.95]	88 [1.00]	80 [0.90]	89 [0.94]	100 [1.13]	143 [1.62]	135 [1.53]	102 [1.15]	NA	43.5 <sup>§</sup>	80 [0.90]	NA	75 [0.85]	NA
Urea (mmol/L) [mg/dL]	4.0 [11.2]	6.9 [19.3]	6.2 [17.4]	6.0 [16.8]	5.2 [14.6]	5.6 [15.7]	6.7 [18.8]	NA	NA	NA	NA	37	3.9 [10.9]	NA	NA	NA

<sup>§</sup>Prior to ventilation; <sup>||</sup>during ventilation; <sup>§</sup>after disconnection from the ventilator; RR, respiratory rate; ETCO<sub>2</sub>, end tidal carbon dioxide; V<sub>T</sub>, tidal volume.

**Table 2:** Abnormal hematology and biochemistry values from a dog exposed to an inhalant toxicant resulting in severe pulmonary injury

	Patient result	Reference interval
<b>Complete blood count</b>		
Hematocrit [L/L] (%)	0.644 [64.4%]	0.37–0.55 [37-55]
RBC concentration (× 10 <sup>12</sup> /L) [10 <sup>6</sup> /μL]	8.65 [8.65]	5.5–8.5 [5.5-8.5]
Hemoglobin (g/L) [g/dL]	213 [21.3]	120–180 [12.0-18.0]
Lymphocytes (× 10 <sup>9</sup> /L) [10 <sup>3</sup> /μL]	0.08 [0.08]	1–4.8 [1-4.8]
MCH (pg)	24.6	19.5–24.5
<b>Biochemistry</b>		
Creatine kinase (U/L)	617	61–394



**Figure 1:** Lung window transverse CT at the level of the 9th rib, displaying generalized increased soft tissue attenuation with a peripheral rim of normal lung parenchyma.

### **Footnotes**

<sup>a</sup> Nicobond grout protector aerosol retail 500 mL (N2540758), N&C Building Products Ltd., Romford, UK.

<sup>b</sup> Stat Profile pHox Ultra, Nova Biomedical Corporation, MA.

<sup>c</sup> ILab600 Chemistry Analyzer, Instrumentation Laboratory, MA.

- <sup>d</sup> Advia 2120i Haematology System, Siemens Healthcare Ltd., Camberley, UK.
- <sup>e</sup> Idexx Angio Detect, Idexx Europe B.V., Hoofddorp, the Netherlands.
- <sup>f</sup> Midazolam hydrochloride, Roche Products Ltd., Welwyn Garden City, UK.
- <sup>g</sup> Fentanyl citrate, Eurovet Animal Health B.V., Bladel, The Netherlands.
- <sup>h</sup> Propofol, Norbrook Laboratories Ltd., Newry, UK.
- <sup>i</sup> Nellcor Puritan Bennett 840 Ventilator System, Puritan-Bennett Corporate, Pleasanton, CA.
- <sup>j</sup> 16-slice MDCT scanner MX 8000 IDT, Philips Medical Systems, Cleveland, OH.
- <sup>k</sup> Hydrocortisone sodium succinate, Pfizer Ltd., Kent, UK.
- <sup>l</sup> Methadone hydrochloride, Le Vet Beheer B.V., Oudewater, The Netherlands.
- <sup>m</sup> Medetomidine hydrochloride, Le Vet Beheer B.V.
- <sup>n</sup> Amoxicillin clavulanate, GlaxoSmithKline, Middlesex, UK.
- <sup>o</sup> Levothyroxine sodium, Eurovet Animal Health B.V.
- <sup>p</sup> Amoxicillin clavulanate, Norbrook Laboratories Ltd.
- <sup>q</sup> Tramadol hydrochloride, Bristol Laboratories, Bristol, UK.

## **References**

1. DeClue AE, Cohn LA. Acute respiratory distress syndrome in dogs and cats: a review of clinical findings and pathophysiology. *J Vet Emerg Crit Care* 2007; 17(4):340-7.
2. Bernard GR, Artigas A, Brigham KL, et al. Consensus Committee: The American-European Consensus Conference on ARDS: definitions, mechanisms, relevant outcomes, and clinical trial coordination. *Am J Respir Crit Care* 1994; 149(3):818-24.
3. ARDS Definition Task Force, Ranieri VM, Rubenfeld GD, et al. Acute respiratory distress syndrome: the Berlin Definition. *JAMA* 2012; 307(23):2526-33.
4. Wilkins PA, Otto CM, Baumgardner JE, et al. Acute lung injury and acute respiratory distress syndromes in veterinary medicine: consensus definitions: the Dorothy Russell Havemeyer Working Group on ALI and ARDS in Veterinary Medicine. *J Vet Emerg Crit Care* 2007; 17(4):333-9.

5. Kelmer E, Love LC, DeClue AE, et al. Successful treatment of acute respiratory distress syndrome in 2 dogs. *Can Vet J* 2012; 53(2):167-73.
6. Guillaumin J, Hopper K. Successful outcome in a dog with neurological and respiratory signs following smoke inhalation. *J Vet Emerg Crit Care* 2013; 23(3):328-34.
7. Sabino CV, Holowaychuk M, Bateman S. Management of acute respiratory distress syndrome in a French Bulldog using airway pressure release ventilation. *J Vet Emerg Crit Care* 2013; 23(4):447-54.
8. Young BC, Strom AM, Prittie JE, et al. Toxic pneumonitis caused by inhalation of hydrocarbon waterproofing spray in two dogs. *J Am Vet Med Assoc* 2007; 231(1):74-8.
9. Campora C, Freeman KP, Lewis FI, et al. Determination of haematological reference intervals in healthy adult greyhounds. *J Small Anim Pract* 2011; 52(6):301-9.
10. Lisciandro GR. Abdominal and thoracic focused assessment with sonography for trauma, triage, and monitoring in small animals. *J Vet Emerg Crit Care* 2011; 21(2):104-22.
11. Villar J, Blanco J, del Campo R, et al. Assessment of PaO<sub>2</sub>/FiO<sub>2</sub> for stratification of patients with moderate and severe acute respiratory distress syndrome. *BMJ Open* 2015; 5(3):e006812.
12. Villar J, Pérez-Méndez L, López J, et al. An early PEEP/FiO<sub>2</sub> trial identifies different degrees of lung injury in patients with acute respiratory distress syndrome. *Am J Respir Crit Care Med* 2007; 176(8):795-804.
13. Karbing DS, Kjaergaard S, Smith BW, et al. Variation in the PaO<sub>2</sub>/FiO<sub>2</sub> ratio with FiO<sub>2</sub>: mathematical and experimental description, and clinical relevance. *Crit Care* 2007; 11(6):R118.
14. Bracco D, Favre JB. Pulmonary injury after ski wax inhalation exposure. *Ann Emerg Med* 1998; 32(5):616-9.
15. Parent C, King LG, Van Winkle TJ, Walker LM. Respiratory function and treatment in dogs with acute respiratory distress syndrome: 19 cases (1985-1993). *J Am Vet Med Assoc* 1996; 208(9):1428-33.
16. Daubert GP, Spiller HA, Crouch BI, et al. Pulmonary toxicity following exposure to waterproofing grout sealer. *J Med Toxicol* 2009; 5(3):125-9.
17. Yamashita M, Tanaka J, Hirai H, et al. Pulmonary collapse and pneumonia due to inhalation of water-proofing aerosols in female CD-1 mice. *J Toxicol Clin Toxicol* 1995; 33(6):631-637.
18. Sullivan JB, Krieger GR, eds. *Hazardous Materials Toxicology: Clinical Principles of Environmental Health*. Baltimore: Williams and Wilkins; 1992, p. 1122.
19. Diaz JH. *Color Atlas of Human Poisoning and Envenoming*, 1st ed. Boca Raton, FL: CRC Press; 2006, pp.

124-125.

20. Tormoehlen LM, Tekulve KJ, Nanagas KA. Hydrocarbon toxicity: a review. *Clin Toxicol* 2014; 52(5):479-89.
21. Makrygianni EA, Palamidou F, Kaditis AG. Respiratory complications following hydrocarbon aspiration in children. *Pediatr Pulmonol* 2016; 51(6):560-9.
22. The Acute Respiratory Distress Syndrome Network. Ventilation with lower tidal volumes as compared with traditional tidal volumes for acute lung injury and the acute respiratory distress syndrome. *N Engl J Med* 2000; 342(18):1301-8.
23. Tranquilli WJ, Thurmon JC, Grimm KA. (eds). *Lumb and Jones' Veterinary Anesthesia*, 4th ed. Oxford, UK: Blackwell; 2007, p. 124.
24. Myriantsefs P, Baltopoulos G. A higher tidal volume may be used for athletes according to measured FVC. *The Scientific World Journal* 2013; 2013:1-6.
25. Oura T, Rozanski EA, Buckley G, Bedenice D. Low tidal volume ventilation in healthy dogs. *J Vet Emerg Crit Care* 2012; 22(3): 368-71.
26. O' Croinin D, Chonghaile MN, Higgins B, Laffey JG. Bench-to-bedside review: permissive hypercapnia. *Crit Care* 2005; 9(1): 51-59.
27. Hickling KG, Walsh J, Henderson S, Jackson R. Low mortality rate in adult respiratory distress syndrome using low-volume, pressure-limited ventilation with permissive hypercapnia: a prospective study. *Crit Care Med* 1994; 22: 1568-1578.