

Spectrum of arthroscopic findings in 84 canine elbow joints diagnosed with medial compartment erosion

Arthroscopische bevindingen bij 84 caniene ellebogen met erosie van het mediale gewrichtscompartiment

E. Coppieeters, E. de Bakker, B. Broeckx, Y. Samoy, G. Verhoeven, E. Van der Vekens, B. Van Ryssen

Department of Veterinary Medical Imaging and Small Animals Orthopedics,
Faculty of Veterinary Medicine, Ghent University, Salisburylaan 133, B-9820 Merelbeke, Belgium

eva.coppieeters@ugent.be

ABSTRACT

Elbow dysplasia is an important cause of forelimb lameness in large breed dogs. The aim of this study was to report on the arthroscopic findings associated with medial compartment erosion (MCE) of the canine elbow joint. Retrospectively, records of 84 elbow joints from 66 dogs diagnosed arthroscopically with MCE were retrieved from a medical records database (2008 - 2012). The radiographic degree of osteoarthritis was determined. Arthroscopic images and videos were evaluated in detail. In nine joints (10.7%), MCE was the only pathological finding (= group 1). Group 2 (n = 50, 59.5%) consisted of elbows with MCE concomitant with medial coronoid process (MCP) pathology. In group 3 (n = 25 joints, 29.8%), MCE was diagnosed during a second-look arthroscopy in dogs presented with lameness after arthroscopic treatment for medial coronoid disease. There was a significant age difference ($p < 0.001$) between the groups, with dogs in group 1 being the oldest. Complete erosion of the medial compartment was most commonly found in group 1, whereas focal cartilage erosion was mostly identified in group 2. Overall, additional cartilage pathology of the lateral part of the humeral condyle and/or the radial head was recognized in 58.3% of the joints (49/84).

SAMENVATTING

Elleboogdysplasie is een veel voorkomende oorzaak van manken op de voorpoot bij grote hondsrassen. Het doel van deze studie was om de arthroscopische bevindingen geassocieerd met erosie van het mediale elleboogcompartiment te beschrijven. Uit een medische database werden de dossiers geselecteerd van honden gediagnosticeerd met erosie van het mediale elleboogcompartiment. In de periode 2008-2012 werden 84 ellebogen (66 honden) gediagnosticeerd met deze aandoening. De radiografische graad van osteoarthritis werd bepaald en de arthroscopische beelden en video's werden in detail geëvalueerd. Bij negen gewrichten (10,7%) was erosie de enige pathologische bevinding (= groep 1). Groep 2 (n = 50, 59,5%) betrof ellebogen met erosie van het mediale compartiment en een letsel van de mediale processus coronoïdeus. In groep 3 (n = 25, 29,8%) werd erosie van het mediale compartiment gediagnosticeerd tijdens een revisie-artroscopie bij honden die reeds eerder behandeld werden voor een letsel van de mediale processus coronoïdeus. Bij het vergelijken van de groepen was er een significant verschil ($p < 0,001$) in leeftijd waarbij de honden in groep 1 het oudste waren. In groep 1 werd voornamelijk complete erosie van het mediale gewrichtscompartiment gezien, terwijl in groep 2 meestal focale erosie werd opgemerkt. Bij 58,3% van de gewrichten (49/84) werd eveneens kraakbeenschade in het laterale gewrichtscompartiment waargenomen.

INTRODUCTION

Elbow dysplasia is an important cause of forelimb lameness in large breed dogs (Fitzpatrick et al., 2009a; Michelsen, 2013; Barthélémy et al., 2014). The elbow

dysplasia complex includes several pathologies, such as osteochondritis dissecans (OCD) of the medial part of the humeral condyle (MHC), an ununited anconeal process, joint incongruence and disease of the medial coronoid process, combined with a varying degree of

cartilage damage (Fitzpatrick et al., 2009; Michelsen, 2013; Barthélémy et al., 2014). Radioulnar incongruity is believed to be an important factor in the development of elbow dysplasia because of chronic supra-physiologic loading of the medial joint compartment (Gemill and Clements, 2007; Werner et al., 2009; Böttcher et al., 2013; Fitzpatrick et al., 2013). A histological study demonstrated fatigue microdamage in the region of the medial coronoid process (MCP) in dogs diagnosed with a fragmented MCP, supporting the hypothesis of chronic overload of the medial compartment in dysplastic elbows (Danielson et al., 2006). In a more advanced stage of medial coronoid disease, full thickness cartilage lesions with exposure of the subchondral bone (modified Outerbridge grade 4-5) (Fitzpatrick et al., 2009c; Vermote et al., 2010; Griffon, 2012; Coppieters et al., 2015) of the medial part of the humeral condyle (MHC) and the corresponding ulnar contact area develop (Fitzpatrick et al., 2009c; Vermote et al., 2010; Coppieters et al., 2015). This advanced cartilage damage can be referred to as medial compartment erosion (MCE) (Coppieters et al., 2015). It seems likely that fragmentation of the MCP and erosions of the medial compartment are attributable to a common pathway (Fitzpatrick et al., 2009a).

Clinical signs of MCE are similar to other lesions in the elbow dysplasia complex (Vermote et al., 2010; Coppieters et al., 2012; Griffon, 2012; Coppieters et al., 2015). However, most dogs with MCE demonstrate marked clinical abnormalities, such as obvious lameness, limited range-of-motion or signs of severe pain on elbow manipulation (Coppieters et al., 2015). Furthermore, little information is available on the type of dogs affected by MCE and the underlying pathology. Therefore, MCE is difficult to diagnose based on the history and clinical examination. Routinely used imaging techniques, such as radiography and computed tomography, cannot visualize articular cartilage (Moore et al., 2008; Coppieters et al., 2015). Arthroscopic inspection of the joint, the gold standard for articular cartilage evaluation (Van Rysen et al., 1993; Meyer-Lindeberg et al., 2003), is the most reliable method to diagnose MCE. The modified Outerbridge classification (Griffon, 2012) is the best-known and most commonly used grading system to evaluate cartilage pathology based on the appearance of the articular surface and the depth of the lesions (Fitzpatrick et al., 2009b; Vermote et al., 2010; Griffon, 2012; Coppieters et al., 2015). Currently, the description of MCE is based on the modified Outerbridge classification grade of the MHC and the corresponding ulnar contact areas. Detailed information on the exact location or the extent of the lesions is lacking.

MCE is reported in three situations: As a single pathology, as a concomitant finding with MCP pathology and/or OCD of the MHC, or as a finding during second-look arthroscopy in dogs with persistent or recurrent lameness after initial arthroscopic treatment of

medial coronoid disease (Vermote et al., 2010; Coppieters et al., 2012; Perry and Li, 2014; Coppieters et al., 2015; Coppieters et al., 2016a). The prevalence of those three groups in joints with MCE has not been reported yet.

MCE can be treated by load-transferring techniques or unicompartamental arthroplasty systems (Fitzpatrick et al., 2009c; Gutbrod and Guerrero, 2012; Smith et al., 2013; Franklin et al., 2014; Wendelburg and Beale, 2014). The extent of the cartilage damage within the medial joint compartment, for example cartilage damage expanding into the ulnar trochlear notch, might influence prognosis after treatment. In addition, these techniques require healthy cartilage of the lateral joint compartment. Although it has been reported that pathology of the lateral compartment is less commonly observed (Fitzpatrick et al., 2009c), the prevalence in joints with MCE has not been established yet. Therefore, it is difficult to determine the number of dogs that would benefit from those treatment options.

The aim of this retrospective study was to report on the arthroscopic lesions in dogs with MCE, determine the associated radiographic degree of osteoarthritis, describe the prevalence of the three groups in joints with MCE, and report on the prevalence of concomitant lesions of the lateral compartment. This knowledge may facilitate the diagnosis and treatment decision-making in the future.

MATERIALS AND METHODS

In this retrospective study, medical records of dogs that underwent elbow arthroscopy at the Department of Medical Imaging of the Faculty of Veterinary Medicine (UGhent), from 2008 to 2012, were reviewed. To be included in this study, the following inclusion criterion had to be met: 1. clear elbow lameness and arthroscopic diagnosis of MCE (modified Outerbridge grade 4-5 of the MCP and MHC) (Table 1); 2. complete information about signalment, history, clinical and orthopedic examination; 3. a complete set of diagnostic high quality radiographs made one day to three weeks prior to the arthroscopic joint inspection; 4. still and video images of the arthroscopic inspection of the joint when diagnosed with MCE; and 5. still and video images of the first arthroscopy in patients diagnosed with MCE during a second-look arthroscopic procedure. Data collected from the medical records included gender, age at diagnosis, breed, duration of lameness, body weight, and in some cases, time between the first and second arthroscopy. In the case of dogs re-presented with lameness after the arthroscopic treatment of medial coronoid disease, the duration of lameness between the first and second arthroscopic treatment was considered. Twenty-two elbows diagnosed with MCE via arthroscopy were excluded because the inclusion criteria were not met. In

Table 1. Modified Outerbridge classification: grading system used to score the depth of the articular cartilage damage (Vermote et al., 2010; Griffon, 2012; Coppieters et al., 2015).

Modified Outerbridge classification	Description of gross cartilage findings
0	Normal cartilage
1	Chondromalacia (cartilage with softening and swelling)
2	Fibrillation Superficial erosions with pitting or a ‘cobblestone’ appearance Lesions that do not reach subchondral bone
3	Deep ulceration that does not reach the subchondral bone
4	Full thickness cartilage loss with exposure of the subchondral bone
5	Eburnated bone

case of diagnosis of bilateral MCE, both elbow joints were included in the study.

Radiographic examination of the elbows included an extended and flexed mediolateral view and a craniocaudal (15°-pronation) view. Radiographs were evaluated to determine the degree of osteoarthritis: 0 = no osteophytes, 1 = osteophytes \leq 2 mm, 2 = osteophytes 2-5 mm and 3 = osteophytes $>$ 5 mm (Hazewinkel, 2008).

Arthroscopy was performed with a 2.4 or 1.9 mm, 25° fore-oblique arthroscope (Richard Wolf, Knittlingen, Germany) using a standard medial approach (Van Ryssen et al., 1993). Digital still and video images were taken of all elbow joints. The arthroscopic

findings were assessed by the first author and an experienced orthopedic surgeon at the same moment, until a consensus was reached. In patients with MCE, the extent of the cartilage lesions of the MHC and the MCP was evaluated and scored as focal, diffuse or complete erosion (Fitzpatrick et al., 2015; Coppieters et al., 2016b) (Figure 1). Radioulnar incongruity of the joint was evaluated, as previously reported by Wagner et al. (2007), at the base, midbody and apex of the MCP. Joints were classified as normal (no step), or mildly (step $<$ 2 mm) or severely (step \geq 2 mm) incongruent. Pathology of the lateral joint compartment, including the radial head and the lateral part of the humeral condyle, was also recorded. Additionally,

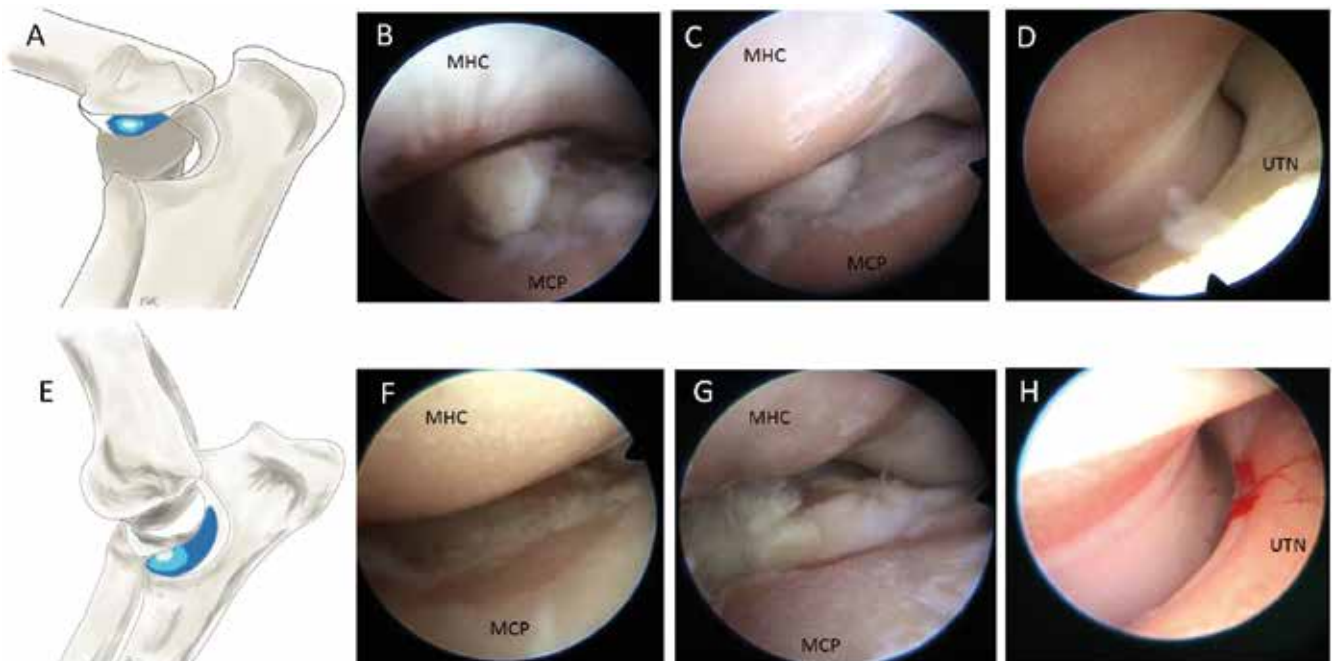


Figure 1. Schematic representation of the extent of the cartilage erosion on the medial part of the humeral condyle (MHC) (A) and the medial coronoid process (MCP) (E), and corresponding arthroscopic images, obtained via a standard medial approach (15), illustrating focal (B and F), diffuse (C and G) and complete (D and H) erosion of the MHC (top row) and the MCP (lower row) in elbow joints with medial compartment erosion. A, E. Focal erosions are very localized full-thickness cartilage erosions (white area). Diffuse erosions affect the majority of the cartilage surface of the MCP or the MHC but the cartilage of the trochlear notch or the corresponding humeral cartilage is still intact (light blue area). Complete erosions affect the entire surface of the MHC or the MCP including the cartilage of the ulnar trochlear notch (UTN) and the corresponding humeral cartilage (dark blue area).

Table 2. Breed distribution of 66 dogs with medial compartment erosion.

Breed	Number of dogs
Labrador retriever	27 (40.9%)
Cross-breed	7 (10.6%)
German shepherd dog	5 (7.6%)
Rottweiler	5 (7.6%)
Bernese mountain dog	5 (7.6%)
American bulldog	2 (3%)
Large Münsterländer	2 (3%)
Single breeds*	13 (19.7%)
Total	66 (100%)

*One of each: Airdale terrier, Belgian Malinois, Border collie, Chow Chow, Dutch partridge dog, French bulldog, Golden retriever, Greater Swiss mountain dog, Scotch collie, Sheltie, Tibetan mastiff, Weimaraner and White Swiss shepherd dog.

the presence of fissuring or fragmentation of the MCP and/or OCD of the MHC was recorded. After the retrospective evaluation of the radiographs and the data obtained by arthroscopy, the elbow joints were divided in three groups: group 1 = MCE as a single pathology, group 2 = MCE concomitant with a fragmented/fissured MCP and/or OCD and group 3 = MCE at second-look arthroscopy in dogs with persistent or recurrent lameness after arthroscopic treatment of medial coronoid disease (Vermote et al., 2010; Coppieters et al., 2013; Perry and Li, 2014; Coppieters et al., 2015, Coppieters et al., 2016a). For joints to be included in group 1, the absence of a concomitant fragment or fissure of the MCP needed to be confirmed by computed tomographic examination performed prior to the arthroscopy. The initial arthroscopic treatment performed in the joints of group 3 consisted of the removal of the fragmented or fissured part of the MCP and debridement of the remaining part of the MCP. All dogs in group 3 were clearly lame according to the owner and the veterinarian at the time of the second-look arthroscopy.

Postoperative care

The dogs were released on the day of the arthroscopic treatment. The dogs received a non-steroidal anti-inflammatory drug for three weeks. For all dogs,

restricted exercise with leash walks was advised for a period of six weeks postoperatively.

Statistical analysis

Age and duration of lameness were compared for the three groups by the non-parametrical Kruskal-Wallis test. Post-hoc comparisons were done using the Wilcoxon rank sum test with the Bonferroni-correction. A Fisher-exact test with Monte Carlo simulation (2000 replicates) was performed to examine the relation between group and degree of osteoarthritis, incongruity, extent of MCP and MHC lesions, presence of linear abrasion tracks, presence of white areas and damage of the lateral compartment. The results are reported as percentages, median and range when appropriate. Statistical analysis was conducted with R (version 3.1.2, "Pumpkin Helmet") (R Core team, 2012). Significance was set at $P < 0.05$.

RESULTS

In the period from 2008 to 2012, a total of 587 elbows were diagnosed with lesion(s) included in the elbow dysplasia complex. The prevalence of MCE, diagnosed via arthroscopy, in this study population was 18.1% ($n = 106$, including cases with incomplete medical records). Of those 106 joints, 84 joints (66 dogs) were diagnosed with MCE and met the inclusion criteria for this study. Twenty breeds were represented, of which the Labrador retriever (27 dogs, 40.9%) was most common (Table 2). Male:female ratio was 1.6:1. Left and right distribution of MCE was almost equal (left: 47.6%, 40 elbows and right: 52.4%, 44 elbows) and 18 dogs had bilateral MCE. The median weight of the dogs was 32.5 kg (range 15 - 60kg). Nine joints (10.7%, 8 dogs) were assigned to group 1, 50 joints (59.5%, 40 dogs) to group 2 and 25 joints (29.8%, 19 dogs) to group 3. One dog was included in both groups 1 and 2 because of a bilateral diagnosis with MCE, which was considered a single pathology in one elbow and concomitant in the other elbow. Overall, a significant age difference ($p < 0.001$) between the groups was observed: dogs in Group 1 were significantly older than dogs in group 2 ($p < 0.001$) and dogs in group 3 ($p = 0.025$). Dogs in

Table 3. Distribution of degree of radioulnar incongruity per group of medial compartment erosion (MCE). Group 1 = MCE as a single pathology, group 2 = MCE concomitant to a coronoid pathology and group 3 = MCE at second-look arthroscopy in dogs with lameness after arthroscopic treatment of medial coronoid disease. Joint incongruity was evaluated during arthroscopic inspection and graded as normal (no radio-ulnar step), or mildly (step < 2 mm) or severely (step ≥ 2 mm) incongruent (Wagner et al., 2007).

	Total amount of joints	Congruent joints	Mildly incongruent joints	Severely incongruent joints
Group 1	9	9 (100%)	0 (0%)	0 (0%)
Group 2	50	13 (26.0%)	24 (48.0%)	13 (26.0%)
Group 3	25	14 (56.0%)	8 (32.0%)	3 (12.0%)

group 2 were significantly younger than dogs in group 3 ($p < 0.001$). The median age at diagnosis in group 1 was 8.5 years (range 6.6 - 11 years), in group 2 1.8 years (range 0.5 - 10.5 years) and in group 3 6.9 years (range 0.9 - 9.9 years). The median duration of lameness at the diagnosis of MCE was five months (range 1 - 78 months). No significant difference ($p = 0.199$) in duration of lameness was found between the three groups.

The radiographic degree of osteoarthritis per group is demonstrated in Figure 2. No significant difference ($p = 0.519$) was found between the three groups. In general, a high degree of osteoarthritis (degree 2 or 3) was present in 82.1% of the joints (69/84), 15.5% of the joints (13/84) only demonstrated small osteophytes (degree 1), and in 2.4% of the joints (2/84) no osteophytes were present (degree 0). In the 2 joints without osteophytes, some sclerosis of the ulnar trochlear notch was noticed.

A significant difference ($p < 0.001$) in degree of incongruity between the three groups was observed (Table 3). The distribution of focal, diffuse and complete pathology of the MHC and the MCP per group is shown in Tables 4 and 5. There was a significant difference in the extent of the cartilage erosion of the MCP ($p < 0.001$) and the MHC ($p < 0.001$) between groups. Focal erosion was more frequently seen in group 2, while complete erosion was predominantly seen in group 1.

All joints in group 1 were considered to be congruent on arthroscopic inspection (Table 3). The radio-

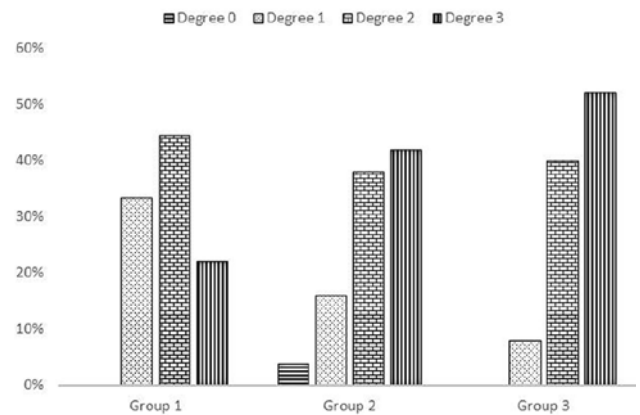


Figure 2. Distribution of the radiographic degree of osteoarthritis per group of medial compartment erosion (MCE). Group 1 = MCE as a single pathology, group 2 = MCE concomitant to a coronoid pathology and group 3 = MCE at second-look arthroscopy in dogs with lameness after arthroscopic treatment of medial coronoid disease. Osteoarthritis was scored as 0 = no osteophytes, 1 = osteophytes ≤ 2 mm, 2 = osteophytes 2-5 mm and 3 = osteophytes > 5 mm (Hazewinkel, 2008).

ular congruity of these joints was confirmed by the CT examination in all but one joint.

In group 2, MCE was diagnosed concomitant to various MCP lesions: a displaced fragment of the MCP in 42 joints (84.0%), a non-displaced fragment in 7 joints (14.0%) and a fissure in 1 joint (2.0%). In addition, a loose cartilage flap (OCD) of the MHC was

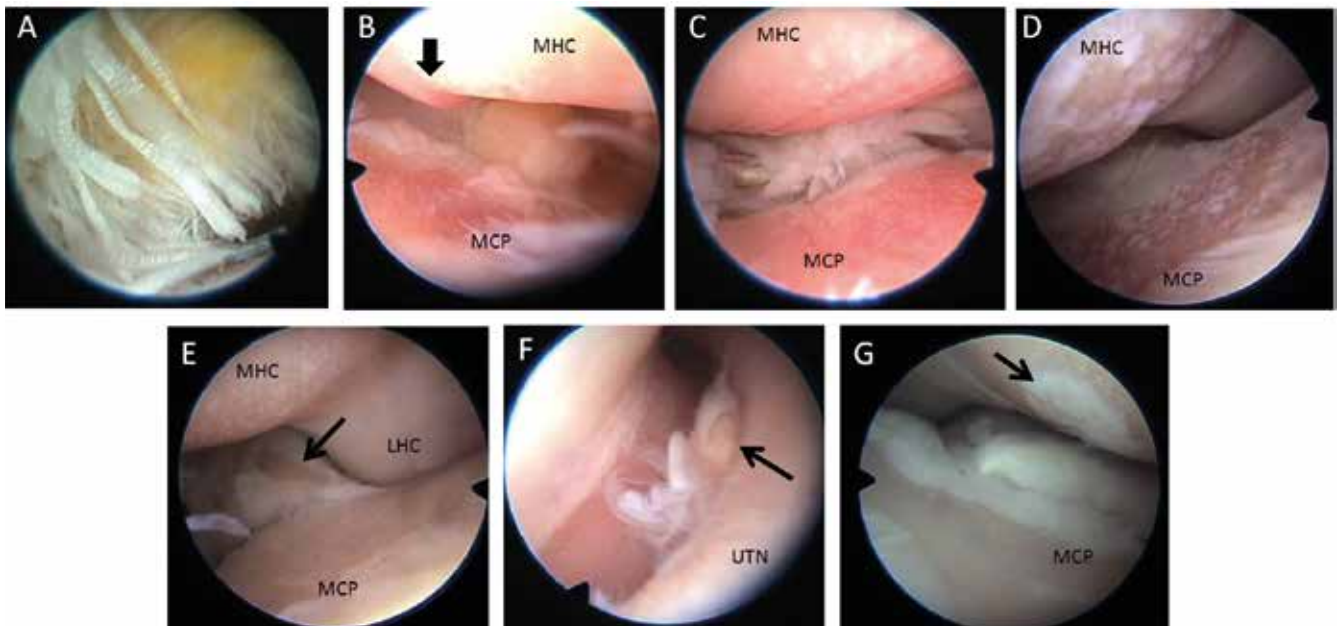


Figure 3. Arthroscopic images, obtained via a medial approach (Van Ryssen et al., 1993) of findings in dogs with erosion of the medial elbow compartment (MCP: medial coronoid process, MHC: medial part of the humeral condyle, UTN: ulnar trochlear notch). A. Fibrillated enthesis and yellow discoloration of the flexor muscles. B. A profound linear abrasion track in the subchondral bone of the MHC (arrow). C. Superficial linear abrasion tracks on the MHC. D. White areas in the eroded medial joint compartment. E. Full-thickness cartilage lesion of the medial part of the radial head (arrow). F. Cartilage damage of the lateral part of the humeral condyle (LHC) concomitant to the presence of an osteochondral fragment of unknown origin (arrow). G. OCD-like lesion (arrow) on the MHC surrounded by an area of full-thickness cartilage loss.

Table 4. Distribution of the extent of the cartilage pathology of the medial coronoid process (MCP) in joints with medial compartment erosion (MCE). Group 1 = MCE as a single pathology, group 2 = MCE concomitant to a coronoid pathology and group 3 = MCE at second-look arthroscopy in dogs with lameness after arthroscopic treatment of medial coronoid disease.

MCP	Focal erosion	Diffuse erosion	Complete erosion
Group 1	0 (0%)	1 (11.1%)	8 (88.9%)
Group 2	30 (60.0%)	13 (26.0%)	7 (14.0%)
Group 3	7 (28.0%)	8 (32.0%)	10 (40.0%)

Table 5. Distribution of the extent of the cartilage pathology of the medial part of the humeral condyle (MHC) in joints with medial compartment erosion (MCE). Group 1 = MCE as a single pathology, group 2 = MCE concomitant to a coronoid pathology and group 3 = MCE at second-look arthroscopy in dogs with lameness after arthroscopic treatment of medial coronoid disease.

MHC	Focal erosion	Diffuse erosion	Complete erosion
Group 1	0 (0%)	0 (0%)	9 (100%)
Group 2	22 (44.0%)	20 (40.0%)	8 (16.0%)
Group 3	1 (4.0%)	8 (32.0%)	16 (64.0%)

observed in 10 joints and an OCD-like lesion, consisting of fibrocartilaginous tissue attached in a rounded defect on the MHC, was noticed in 2 joints (Figure 3). Both OCD and OCD-like lesions were surrounded by an area of full-thickness cartilage loss. In 2 joints, an osteochondral fragment of unknown origin was found additional to an MCP lesion.

Group 3 consisted of 25 joints of dogs presented with lameness after arthroscopic treatment of medial coronoid disease, of which 11 joints (44.0%) demonstrated concomitant loose scar tissue, 5 joints (20.0%) attached scar tissue and 5 joints (20.0%) a calcified body at the level of the MCP. In the remaining 4 joints (16.0%), MCE was the only pathology found in the medial joint compartment. All these joints had been treated for disease of the MCP (chondromalacia (n = 4), fissure (n = 10), non-displaced fragment (n = 6), displaced fragment (n = 5)), of which 4 joints were treated for OCD of the MHC as well. During the first arthroscopy, 14 joints (56.0%) demonstrated normal cartilage, except for the MCP lesion or OCD of the MHC, 8 joints (32.0%) demonstrated mild cartilage damage (modified Outerbridge grade 1-2) and 3 joints (12.0%) already showed moderate cartilage damage (modified Outerbridge 3). The average time between the first and second arthroscopic inspection was 3.3 years (range 0.3 – 6.8 years). The median duration of lameness before the second-look arthroscopy was 5 months (range 2 – 78 months).

The occurrence of superficial and profound linear abrasion tracks in the subchondral bone of the MCP and the MHC is illustrated in Figure 4. In general, linear abrasion tracks in the subchondral bone were observed in joints with diffuse or complete erosions leading to bone-to-bone contact between the MHC and the MCP. No significant difference ($p = 0.073$)

was found between groups in the presence of linear abrasion tracks on the MCP. However, a significant difference was found in the difference of linear abrasion tracks on the MHC ($p = 0.033$). Linear abrasion tracks on the MHC were most commonly found in group 1 (66.7% of the joints), and were least found in group 2 (24.0% of the joints). In 10 joints (11.9%), multiple white areas were noticed in the eroded part of the MCP and/or MHC (Figure 3). No significant difference ($p = 0.071$) was found between the groups in the presence of these areas. Additional cartilage pathology of the lateral joint compartment (radial head and/or lateral part of the humeral condyle) was recognized in 49 joints (58.3%). Both the radial head and the lateral part of the humeral condyle demonstrated cartilage damage in 14 joints (16.7%). The distribution and severity of pathology of the radial head and lateral part of the humeral condyle are illustrated in Figure 5. A significant difference ($p = 0.012$) was found between groups in the presence of damage of the lateral joint compartment. Some damage of the lateral compartment was identified in all joints in group 1, in 48% of the joints of group 2 and in 64% of the joints of group 3. In general, the only visible damage of the radial head was limited to its medial part (Figure 3). All joints with a complete erosion of the MHC still showed a sharp demarcation with the cartilage of the lateral joint compartment, even when some cartilage damage of the lateral part of the humeral condyle was observed.

Abnormalities at the enthesis of the flexor muscles, consisting of a fibrillated enthesis of the flexor muscles to the medial humeral epicondyle, a thickening of the flexor muscles or yellow discoloration of the flexor muscles, were detected in 25 joints (29.8%) (Figure 3).

DISCUSSION

MCE, an advanced stage of medial coronoid disease, has gained more interest and several specific treatment techniques have been developed to address this debilitating disease of the canine elbow joint. Joints with MCE can be divided into three groups: MCE as a single finding (group 1), MCE concomitant with a fragmented/fissured MCP and/or OCD of the MHC (group 2), and MCE as a finding during second-look arthroscopy in dogs with lameness after arthroscopic treatment of medial coronoid disease (Group 3) (Vermote et al., 2010; Coppieters et al., 2012; Perry and Li, 2014, Coppieters et al., 2015, Coppieters et al., 2016a). Limited information is available on the prevalence of the three specific groups of MCE and their characteristics. This study demonstrates significant differences in age, joint incongruity, extent of the cartilage lesions, damage in the lateral joint compartment and presence of linear abrasion tracks on the MHC between the three groups of MCE and illustrates that several additional pathologies may occur in these joints.

The high number of Labrador retrievers in this study is prominent. Other studies reporting on treatment techniques for MCE also mention a high frequency of Labrador retrievers (Fitzpatrick et al., 2009c; Fitzpatrick et al., 2015). Possibly, this breed is more vulnerable to cartilage degeneration. More likely, this high number of Labrador retrievers affected with MCE can be explained by the popularity and the high prevalence of elbow dysplasia in general within this breed (Meyer-Lindeberg et al., 2003; Fitzpatrick et al., 2009a; Coopman et al., 2014).

The dogs in group 1 were significantly older than dogs in the other two groups and had a minimum age of 6.6 years old. This finding is in contrast with other studies that reported MCE as a single finding in younger dogs as well (Olsson, 1987; Vermote et al., 2010). Possibly, subtle concomitant pathology of MCP or MHC may have been overlooked in these younger dogs. Next to the older age of the dogs, complete erosion of the medial compartment was most frequently seen in joints in group 1. This finding is consistent with the conclusion of a study on Labrador retrievers with disease of the MCP reporting a significant relationship between age and the global cartilage pathology (Farrell et al., 2014).

The radiographic degree of osteoarthritis was high in the majority of the joints. This could be expected since it is known that there is a correlation between the radiographic degree of osteoarthritis and articular cartilage damage in the medial elbow compartment (Fitzpatrick et al., 2009a; Vermote et al., 2010; Farrell et al., 2014). However, two joints diagnosed with MCE demonstrated no osteophytes. A similar finding has been reported by Vermote et al. (2010). Therefore, the diagnosis of MCE cannot be excluded based on radiographic examination only.

The etiology of MCE has not been clarified yet. A common pathway between disease of the MCP and MCE has been suggested (Fitzpatrick et al., 2009a). Radioulnar incongruity may generate supraphysiologic overload of the medial joint compartment (Gemill and Clements, 2007; Werner et al., 2009, Böttcher et al., 2013, Fitzpatrick et al., 2013). However, in the present study several joints with MCE were considered congruent based on arthroscopic joint inspection. Possibly, incongruity was only temporary present during skeletal growth (Michelsen, 2013), or joint congruity was misinterpreted during arthroscopy. Although arthroscopy has been described to be an appropriate technique for the diagnosis of radioulnar incongruity (Wagner et al., 2007; Werner et al., 2009), it is known that insertion of the arthroscope and/or the non-weight bearing position of the leg can influence the interpretation of joint incongruity (Skinner et al., 2015). Nevertheless, the remarkable finding of all joints in group 1 being congruent on arthroscopy could be confirmed by CT examination in all but one joint. Therefore, it is possible that other factors may be involved in the development of medial compartment erosion, especially when it is presented as a single finding.

In this study, MCE was most often identified concomitant with a MCP lesion (group 2). A displaced fragment of the MCP was the predominant concomitant finding in this group. Conflict between the intact portion of the MCP and the MHC and/or chronic inflammation created by the presence of a fragment might have caused the development of MCE (Samoy et al., 2012; Michelsen, 2013). Linear abrasion tracks in the subchondral bone were least found in this group. Those linear abrasion tracks, possibly caused by profound humeroulnar conflict, were mostly observed in joints with diffuse or complete erosions leading to bone-to-bone contact between the MHC and the MCP. Since focal erosion was most frequently observed in group 2, this could explain the lower occurrence of linear abrasion tracks in this group.

MCE in dogs with lameness after arthroscopic treatment of disease of the MCP was the second largest group in this study. It has been suggested that fragmentation of the MCP is a first step of medial coronoid disease before erosion of the more resilient part of the MCP occurs (Fitzpatrick et al., 2009a). Indeed, the first arthroscopic treatment of these joints only consisted of fragment removal, making further supraphysiologic loading of the remaining part of the MCP possible. However, more than half of the joints of group 3 were considered congruent joints. Although elbow congruency is challenging to assess, it is likely that other factors or other unknown underlying conditions are involved in the etiopathogenesis of these severe cartilage erosions. For example, it is possible that the initial surgical intervention, interrupting the joint surface, triggered the progression of degenerative cartilage damage (Coppieters et al., 2016a).

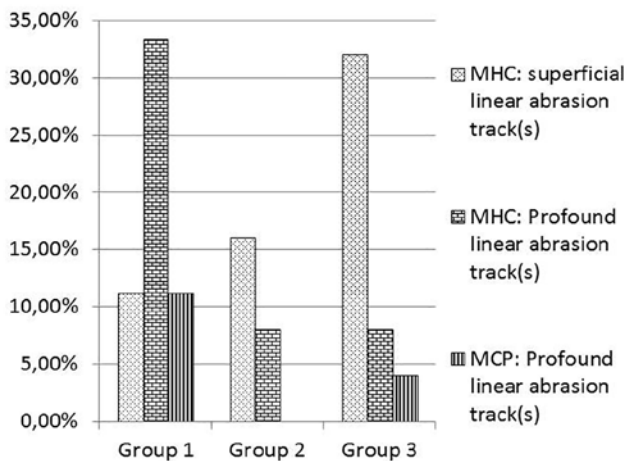


Figure 4. Prevalence of linear abrasion tracks in the subchondral bone of the medial part of the humeral condyle (MHC) and the medial coronoid process (MCP) in joints with medial compartment erosion (MCE). Group 1 = MCE as a single pathology, group 2 = MCE concomitant to a coronoid pathology and group 3 = MCE at second-look arthroscopy in dogs with lameness after arthroscopic treatment of medial coronoid disease.

Information on the prevalence of pathology of the lateral elbow compartment in joints with MCE is scarce in the literature, since MCE only relates to cartilage damage of the MHC and the corresponding ulnar contact area (Fitzpatrick et al., 2009c, Vermote et al., 2010; Coppieters et al., 2015). In general, it is stated that pathology of the lateral compartment is less common (Fitzpatrick et al., 2009a). In this study, cartilage damage of the radial head and/or the lateral part of the humeral condyle has been identified in more than half of the joints with MCE, of which minor damage (modified Outerbridge grade 1-3) of the radial head was the most frequent finding. In vitro studies have demonstrated that the proximal articular surfaces of the radius and the ulna contribute almost equally to load transfer through the elbow joint (Preston et al., 2000; Mason et al., 2005). The radial contact area is located on the caudomedial aspect of the radial articular surface, with its longest dimension oriented mediolaterally (Preston et al., 2000). In the present study, damage of the radial articular surface was only observed in the medial part of this area (Figure 3). Possibly, only the part of the radial head that corresponds with the eroded MHC displays cartilage loss. Therefore, detailed inspection of the radial articular surface is recommended during arthroscopic joint inspection, and additional damage of the radial head should be taken into account before specific treatment methods for MCE, such as a unicompartamental elbow arthroplasty or a sliding humeral osteotomy, are considered (Fitzpatrick et al., 2009c; Franklin et al., 2014).

In ten joints (11.9%), multiple white areas were noticed within the eroded part of the MCP and/or MHC. These might be areas of fibrocartilaginous repair tis-

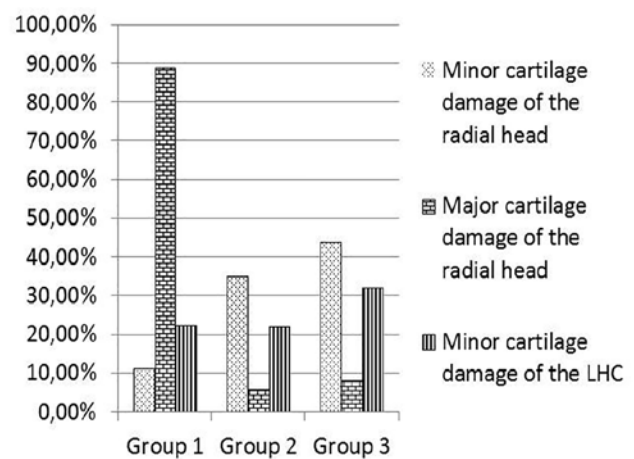


Figure 5. Prevalence of major (modified Outerbridge grade 4-5) and minor (modified Outerbridge grade 1-3) cartilage damage of the radial head and the lateral part of the humeral condyle (LHC) in joints with medial compartment erosion (MCE). Group 1 = MCE as a single pathology, group 2 = MCE concomitant to a coronoid pathology and group 3 = MCE at second-look arthroscopy in dogs with lameness after arthroscopic treatment of medial coronoid disease.

sue. However, due to the retrospective nature of this study, histopathological examination of these lesions was not performed. Thus, it cannot be excluded that these areas are resilient parts of articular cartilage.

Abnormalities at the enthesis of the flexor muscles were detected in almost one third of the joints. It is known that arthroscopy often reveals abnormalities at the enthesis of the flexor muscles in joints with elbow dysplasia lesions (de Bakker et al., 2013). The clinical relevance of these findings is unclear.

In veterinary medicine, the modified Outerbridge classification system is considered the 'gold standard' for arthroscopic evaluation of cartilage lesions (Fitzpatrick et al., 2009a; Farrell et al., 2014). However, this grading system only takes into account the depth of the cartilage lesion, without considering the extent of the lesion. A recent study evaluated the global articular cartilage damage in Labrador retrievers using a composite cartilage score (CCS) which accounted for lesion depth, location and surface area (Farrell et al., 2014). However, this CCS system was not suitable for our study, since nearly all joints with modified Outerbridge grade 4 and 5 (MCE) would have been classified in the highest category being 'severe disease'. Therefore we proposed a new classification scheme, using the terms focal, diffuse and complete, to determine the extent of the cartilage lesions in joints with MCE. A limitation of this classification is that it is rather subjective and not quantitative, since our data were collected retrospectively. The use of the proposed grading scheme allows a classification that may be useful to decide on the type of therapeutic approach as well in the future.

In conclusion, this study provides an overview

of the arthroscopic findings in three types of MCE. Significant differences in age, radioulnar incongruity, extent of the cartilage lesions, damage in the lateral compartment and presence of linear abrasion tracks on the MHC were identified between the three groups. These findings may contribute to the determination of underlying pathophysiological characteristics that lead to MCE. In addition, this study illustrated several additional pathologies that can occur in joints with MCE, including cartilage damage of the lateral joint compartment, flexor enthesopathy and/or a fragment, a calcified body or loose scar tissue at the level of the MCP. These additional pathologies should not be overlooked when MCE is diagnosed and should be taken into account when treatment-decisions are made.

REFERENCES

- Barthélémy N., Griffon D., Ragety G., Carrera I., Schaeffer D. (2014). Short- and long-term outcomes after arthroscopic treatment of young large breed dogs with medial compartment disease of the elbow. *Veterinary Surgery* 43, 935-943.
- Böttcher P., Bräuer S., Werner H. (2013). Estimation of joint incongruence in dysplastic canine elbows before and after dynamic proximal ulnar osteotomy. *Veterinary Surgery* 42, 371-376.
- Coopman F., Broeckx B., Verelst E., Deforce D., Saunders J., Duchateau L., Verhoeven G. (2014). Combined prevalence of inherited skeletal disorders in dog breeds in Belgium. *Veterinary Comparative Orthopaedics and Traumatology* 27, 395-397.
- Coppieters E., Samoy Y., Pey P., Waelbers T., Van Ryssen B. (2012). Medial compartment disease in a young Large Münsterländer. *Vlaams Diergeneeskundig Tijdschrift* 81, 88-92.
- Coppieters E., Gielen I., Verhoeven G., Van Vynckt D., Van Ryssen B. (2015). Erosion of the medial compartment of the canine elbow: occurrence, diagnosis and currently available treatment options. *Veterinary Comparative Orthopaedics and Traumatology* 28, 9-18.
- Coppieters E., Seghers H., Verhoeven G., Gielen I., Samoy Y., de Bakker E., Van Ryssen B. (2016a). Arthroscopic, computed tomographic and radiographic findings in 25 dogs with lameness after arthroscopic treatment of medial coronoid disease. *Veterinary Surgery* 45, 246-253.
- Coppieters E., Van Ryssen B., van Bree H., Verhoeven G., Broeckx B., de Bakker E., Deforce D., Gielen I. (2016b). Computed tomographic findings in canine elbows with erosion of the medial compartment. *Veterinary Radiology and Ultrasound* 57, 572-581.
- Danielson K., Fitzpatrick N., Muir P., Manley P. (2006). Histomorphometry of fragmented medial coronoid process in dogs: A comparison of affected and normal coronoid processes. *Veterinary Surgery* 35, 501-509.
- de Bakker E., Samoy Y., Coppieters E., Mosselmans L., Van Ryssen B. (2013). Arthroscopic features of primary and concomitant flexor enthesopathy in the canine elbow. *Veterinary Comparative Orthopaedics and Traumatology* 26, 340-347.
- Farrell M., Heller J., Solano M., Fitzpatrick N., Sparrow T., Kowaleski M. (2014). Does radiographic arthrosis correlate with cartilage pathology in Labrador Retrievers affected by medial coronoid process disease. *Veterinary Surgery* 43, 155-165.
- Fitzpatrick N., Smith T., Evans R., Yeadon R. (2009a). Radiographic and arthroscopic findings in the elbow joints of 263 dogs with medial coronoid disease. *Veterinary Surgery* 38, 213-223.
- Fitzpatrick N., Yeadon R., Smith T. (2009b). Early clinical experience with osteochondral autograft transfer for treatment of osteochondritis dissecans of the medial humeral condyle in dogs. *Veterinary Surgery* 38, 246-260.
- Fitzpatrick N., Yeadon R., Smith T., Schulz K. (2009c). Techniques of application and initial clinical experience with sliding humeral osteotomy for treatment of medial compartment disease of the canine elbow. *Veterinary Surgery* 38, 261-278.
- Fitzpatrick N., Caron A., Solano M. (2013). Bi-oblique dynamic proximal ulnar osteotomy in dogs: reconstructed computed tomographic assessment of radioulnar congruence over 12 weeks. *Veterinary Surgery* 42, 727-738.
- Fitzpatrick N., Bertran J., Solano M. (2015). Sliding humeral osteotomy: Medium-term objective outcome measures and reduction of complications with a modified technique. *Veterinary Surgery* 44, 137-149.
- Franklin S., Schulz K., Karnes J. (2014). Theory and development of a unicompartamental resurfacing system for treatment of medial compartment disease of the canine elbow. *Veterinary Surgery* 43, 765-773.
- Gemill T., Clements D. (2007). Fragmented coronoid process in the dog: is there a role for incongruency? *Journal of Small Animal Practice* 48, 361-368.
- Griffon D. (2012). Surgical disease of the elbow. In: Tobias K., Johnston S. (editors). *Veterinary Surgery Small Animal*. Elsevier-Saunders, St.Louis, p.732-751.
- Gutbrod A., Guerrero T. (2012). Effect of external rotational humeral osteotomy on the contact mechanics of the canine elbow joint. *Veterinary Surgery* 41, 845-852.
- Hazewinkel H. (2008). Elbow dysplasia: definitions and clinical diagnoses. In: *Proceedings of the 23rd Annual Meeting International Elbow Working Group*. Dublin, Ireland.
- Mason D., Schulz K., Fujita Y., Kass P., Stover S. (2005). *In vitro* force mapping of normal canine humeroradial and humeroulnar joints. *American Journal of Veterinary Research* 66, 132-135.
- Meyer-Lindenberg A., Langhann A., Fehr M., Nolte I. (2003). Arthrotomy versus arthroscopy in the treatment of the fragmented medial coronoid process of the ulna (FCP) in 421 dogs. *Veterinary Comparative Orthopaedics and Traumatology* 16, 204-210.
- Michelsen J. (2013). Canine elbow dysplasia: Aetiopathogenesis and current treatment recommendations. *The Veterinary Journal* 196, 12-19.
- Moore A., Benigni L., Lamb C. (2008). Computed tomography versus arthroscopy for detection of canine elbow dysplasia lesions. *Veterinary Surgery* 37, 390-398.
- Olsson S. (1987). General and etiologic factors in canine osteochondrosis. *Veterinary Quarterly* 9, 268-278.
- Perry K., Li L. (2014). A Retrospective study of the short-term complication rate following 750 elective elbow arthroscopies. *Veterinary Comparative Orthopaedics and Traumatology* 27, 68-73.
- Preston C., Schulz K., Kass P. (2000) *In vitro* determination of contact areas in the normal elbow joint of dogs.

- American Journal of Veterinary Research* 61, 1315-1321.
- R Core team. (2012). R A Language and Environment for Statistical Computing. Vienna, Austria 2012: R Foundation for Statistical Computing. ISBN 3-900051-07-0 (accessed March 15, 2015). Available from: <http://www.R-project.org/>.
- Samoy Y., Van Vynckt D., Gielen I., van Bree H., Duchateau L., Van Ryssen B. (2012). Arthroscopic findings in 32 joints affected by severe elbow incongruity with concomitant fragmented medial coronoid process. *Veterinary Surgery* 41, 355-361.
- Skinner O., Warren-Smith C., Burton N., Parsons K. (2015). Computed tomographic evaluation of elbow congruity during arthroscopy in a canine cadaveric model. *Veterinary Comparative Orthopaedics and Traumatology* 28, 19-24.
- Smith Z., Wendelburg K., Tepic S. (2013). *In vitro* biomechanical comparison of load to failure testing of a canine unconstrained medial compartment elbow arthroplasty system and normal canine thoracic limbs. *Veterinary Comparative Orthopaedics and Traumatology* 26, 356-365.
- Van Ryssen B., van Bree H., Simoens P. (1993). Elbow arthroscopy in clinically normal dogs, *American Journal of Veterinary Research* 54, 191-198.
- Vermote K., Bergenhuyzen A., Gielen I., van Bree H., Duchateau L., Van Ryssen B. (2010). Elbow lameness in dogs of six years and older: arthroscopic and imaging findings of medial coronoid disease in 51 dogs. *Veterinary Comparative Orthopaedics and Traumatology* 23, 43-50.
- Wagner K., Griffon D., Thomas M., Schaeffer D., Schulz K., Samii V., Necas A. (2007). Radiographic, computed tomographic, and arthroscopic evaluation of experimental radio-ulnar incongruence in the dog. *Veterinary Surgery* 36, 691-698.
- Wendelburg K., Beale B. (2014). Medium and long term evaluation of sliding humeral osteotomy in dogs. *Veterinary Surgery* 43, 804-813.
- Werner H., Winkels P., Grevel V., Oechtering G., Böttcher P. (2009). Sensitivity and specificity of arthroscopic estimation of positive and negative radio-ulnar incongruence in dogs. *Veterinary Comparative Orthopaedics and Traumatology* 22, 437-441.

Uit het verleden

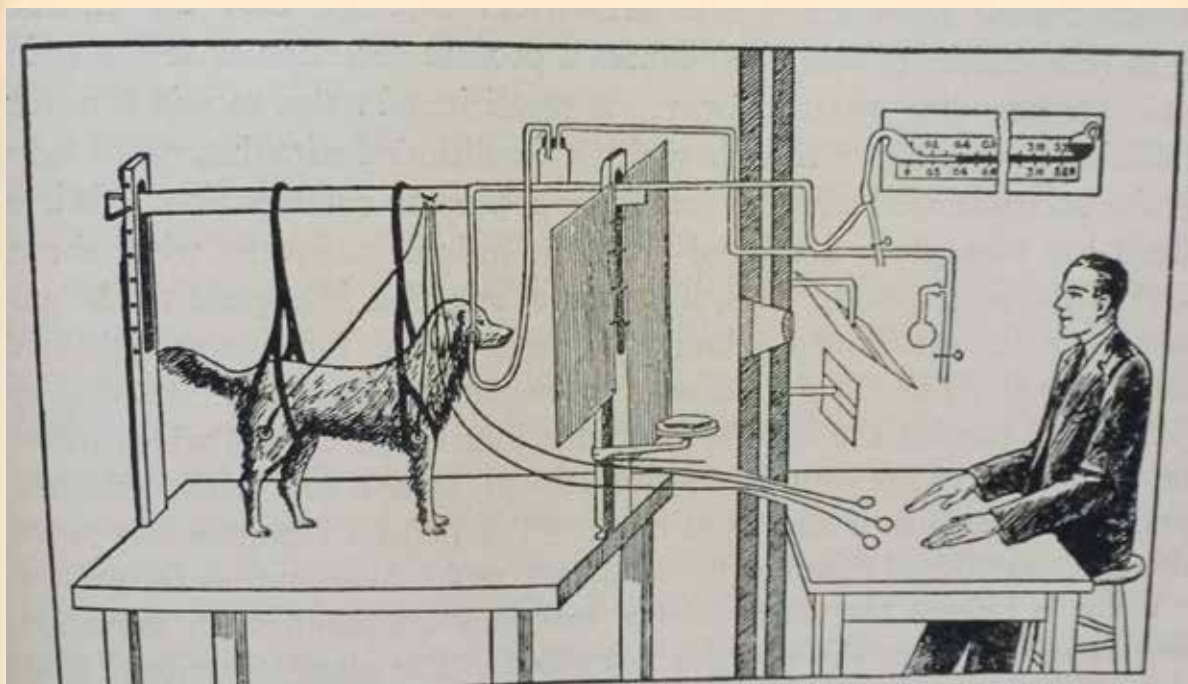


FIG. 388. Illustrating arrangements for experiments upon conditioned reflexes (from Pavlov, *Lectures on Conditioned Reflexes*, International Publishing Company, New York).