

Case 15826

Aggressive Giant Cell tumour of the Metacarpal

Lucas Verniers (1), Adelard De Backer (2), Wim Vanhove (3), Gwen Sys (3), Filip Vanhoenacker (4, 5, 6)

(1) Ghent University, Medical Student, Corneel Heymanslaan 10, 9000 Ghent, Belgium

(2) General Hospital Sint-Lucas, Department of Radiology, Groenebriel 1, 9000 Ghent, Belgium

(3) Ghent university, Department of Orthopaedics, Corneel Heymanslaan 10, 9000 Ghent, Belgium

(4) AZ Sint-Maarten Duffel-Mechelen, Department of Radiology, Leopoldstraat 2, 2800 Mechelen, Belgium

(5) Ghent University Hospital, Department of Radiology, Corneel Heymanslaan 10, 9000 Ghent, Belgium

(6) Antwerp University Hospital, Department of Radiology, Wilrijkstraat 10, 2650 Edegem, Belgium

UZ Ghent; Corneel heymanslaan 10 9000 Ghent, Belgium; Email:lucas.verniers@ugent.be

Section: Musculoskeletal System

Published: 2018, Jul. 4

Patient: 54 year(s), female

Clinical History

A 54-year-old female presented with a 2-month history of insidious onset of swelling and pain at the left thumb. Initial conservative treatment failed. Physical examination confirmed swelling at the 1st carpometacarpal (CMC) joint and a limited abduction. The patient was otherwise well with no history of prior malignancy.

Imaging Findings

Plain radiographs demonstrated an expansile osteolytic lesion in the proximal epiphysis and diaphysis of the left 1st metacarpal bone (MC1). The cortex appeared markedly thinned. There was no surrounding sclerosis nor periosteal reaction (Fig. 1). CT confirmed a large lytic lesion with soft

tissue attenuation, cortical thinning and destruction (Fig. 2). MR imaging showed bone marrow replacement with distal epiphyseal sparing. The lesion was of low signal intensity (SI) on T1-weighted images (WI) and intermediate to high SI on T2-WI. Moderate enhancement and soft-tissue extension was noted on contrast-enhanced images (Fig. 3). Bone scintigraphy demonstrated increased radionuclide uptake but absence of multifocality (Fig. 4). Surgical biopsy and subsequent histopathological examination revealed Giant Cell Tumour (GCT). Preoperative Imaging (Fig. 5-6) 3 months later preceding MC1 resection (Fig. 7) and cement grafting (Fig. 8) showed marked increase of the lesion size. Histopathological findings of the resection specimen confirmed GCT without malignant degeneration.

Discussion

GCT of bone is a benign, but locally aggressive lesion with a tendency for local recurrence after resection. Metastasis is rare. Histologically, it is composed of multinucleated giant cells within a stroma of mononuclear cells. GCT account for approximately 5% of all primary bone tumours [1, 2]. It predominantly occurs between 20 and 50 years of age with a female predominance [1, 3, 4].

GCT of the bone commonly occur in the epi-metaphyseal region of long bones. The distal femur, proximal tibia and distal radius are commonly involved, with the spine and sacrum being less involved [3, 5]. The bones of the hand and foot are rarely involved, with a reported frequency of about 2% of all GCT. Metacarpal involvement is extremely rare [5].

Clinical presentation is usually nonspecific including pain, swelling, limited range of motion and pathological fractures [1, 5].

On conventional radiographs and CT, GCT is typically seen as an eccentric, epi-metaphyseal osteolytic lesion, with well-defined non-sclerotic border and extension underneath the subchondral articular bone [1-3, 5-7]. GCT may also show aggressive features consisting of, poorly demarcated margins, cortical thinning and destruction and soft tissue extension [5]. CT may be useful in evaluating cortical bone integrity, absence of matrix mineralization and demonstration of pathologic fracture [2, 4]. GCT of the hand tends to be less eccentric and more centrally located [7].

MR imaging can help determine the precise intramedullary and soft-tissue extent of the lesion [7]. Generally, GCT has a low-to-intermediate signal on T1-WI and a heterogeneous-high signal on T2-WI [2-4, 7]. However, due to intra-tumoural hemosiderin or fibrosis, the signal may be low on T2-WI [2]. The lesion enhances after intravenous gadolinium contrast administration, reflecting the increased vascular supply [6].

Bone scintigraphy may detect multifocality [4].

Extensive curettage or resection is the treatment of choice of GCT of the hand bones [2, 6, 7]. The combination of intraoperative cryogenic agents or methyl-methacrylate packing and resection has resulted in a recurrence rate of less than 10% [6]. For maintenance of the CMC function, resection is followed by bone reconstruction using an autogenous bone graft or allograft [2].

Although histology is mandatory for a definitive diagnosis, analysis of imaging characteristics of a lesion can be helpful in suggesting the correct diagnosis of a GCT. Epiphyseal extension and the low SI on T2-WI on MRI are useful signs in imaging characterization of aggressive GCT even at

rare localizations such as the metacarpal.

Written informed patient consent for publication has been obtained.

Final Diagnosis

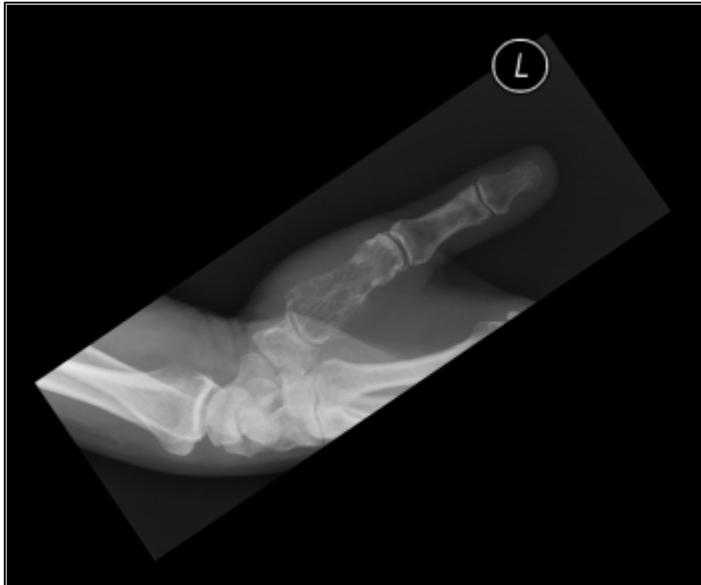Giant cell tumour of the bone.

Differential Diagnosis List

Aneurysmal Bone Cyst, Expansile lytic acrometastases, Osteosarcoma, Chondroblastoma ,
Chondrosarcoma, Brown tumour , Plasmocytoma

Figures

Figure 1 Plain radiograph



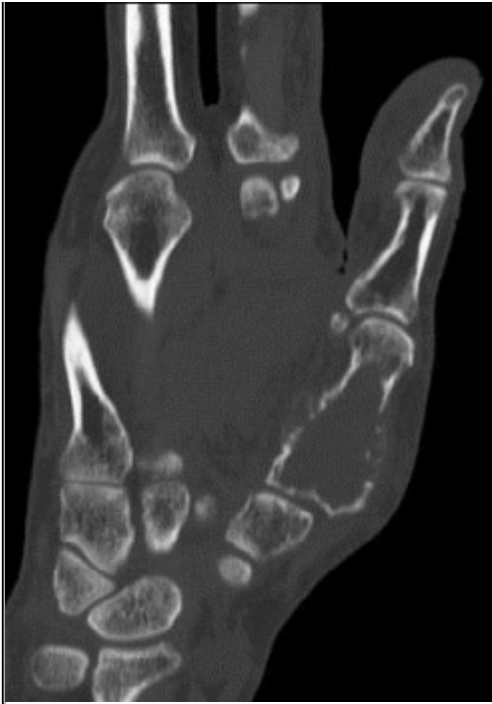
Plain radiograph of the left thumb shows an expansile osteolytic lesion in the proximal epiphysis of the metacarpal bone with diaphyseal extension. The cortex appears markedly thinned and is focally destroyed.

© De Backer A, Department of Radiology, AZ Sint-Lucas, Ghent, Belgium

Area of Interest: Musculoskeletal bone;
Imaging Technique: Plain radiographic studies;
Procedure: Diagnostic procedure;
Special Focus: Neoplasia;

Figure 2 CT findings

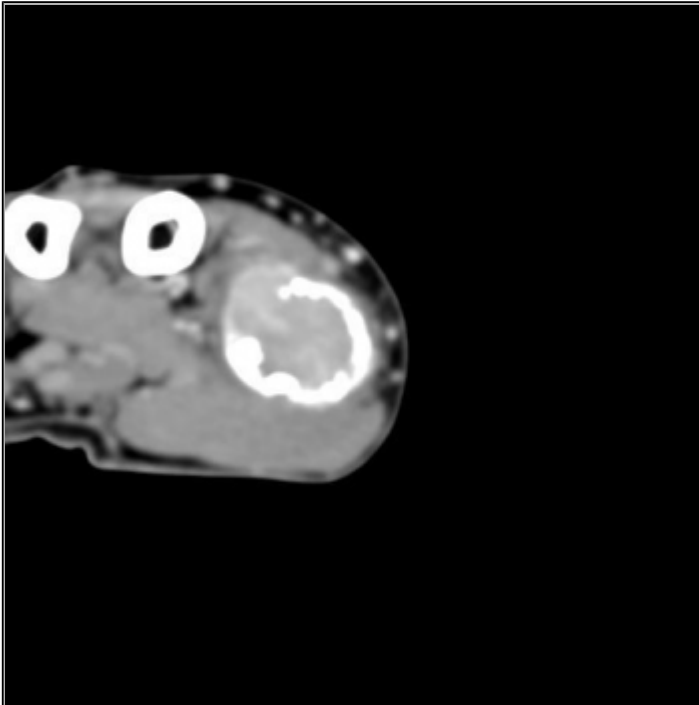




A. Sagittal reformatted image confirmed a large lytic lesion, marked thinning of the cortex and cortical destruction.

© De Backer A, Department of Radiology, AZ Sint-Lucas, Ghent, Belgium

Area of Interest: Musculoskeletal bone;
Imaging Technique: CT;
Procedure: Diagnostic procedure;
Special Focus: Neoplasia;



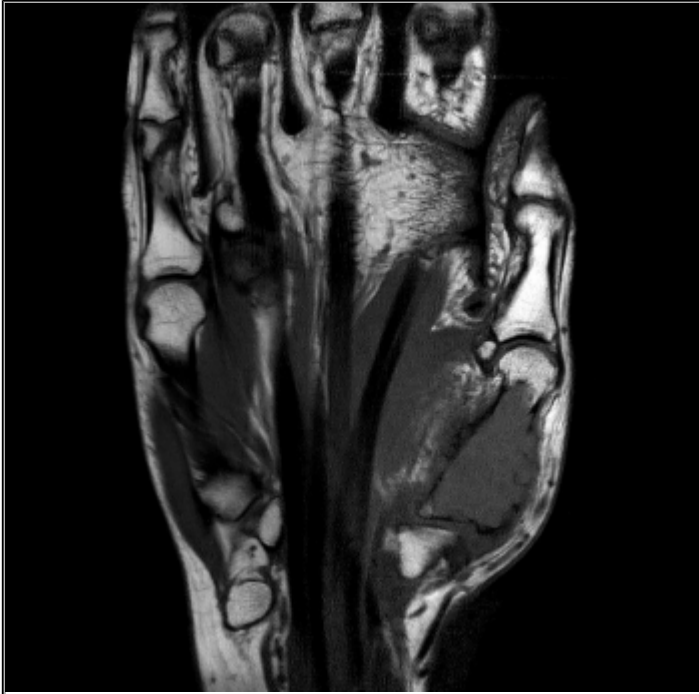
B. Axial contrast-enhanced CT image shows enhancement of the intramedullary soft tissue lesion.

© De Backer A, Department of Radiology, AZ Sint-Lucas, Ghent, Belgium

Area of Interest: Musculoskeletal bone;
Imaging Technique: CT;

Procedure: Diagnostic procedure;
Special Focus: Neoplasia;

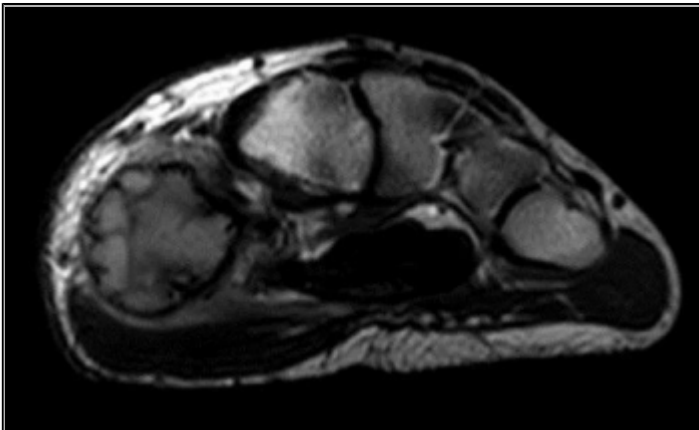
Figure 3 MR imaging findings.



A. Coronal T1-WI shows bone marrow replacement in the diaphysis and proximal epiphysis.

© De Backer A, Department of Radiology, AZ Sint-Lucas, Ghent, Belgium

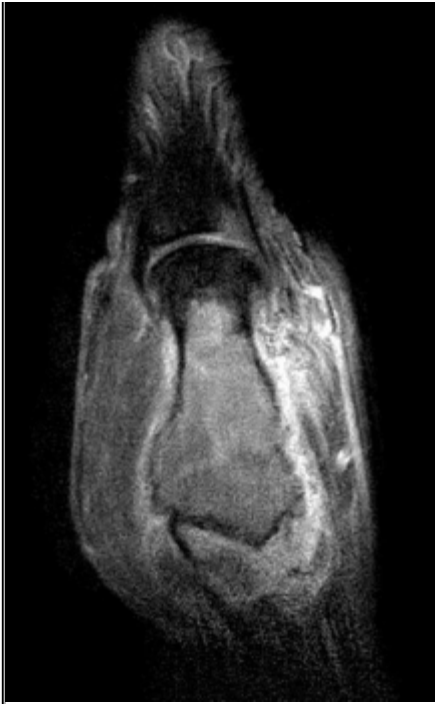Area of Interest: Musculoskeletal bone;
Imaging Technique: MR;
Procedure: Diagnostic procedure;
Special Focus: Neoplasia;



B. Axial T2-WI shows heterogeneous, intermediate to high SI of the lesion with intralesional foci of low signal intensity.

© De Backer A, Department of Radiology, AZ Sint-Lucas, Ghent, Belgium

Area of Interest: Musculoskeletal bone;
Imaging Technique: MR;
Procedure: Diagnostic procedure;
Special Focus: Neoplasia;




C. Coronal contrast-enhanced T1-WI with fat suppression demonstrates moderate lesion enhancement and soft-tissue extension.

© De Backer A, Department of Radiology, AZ Sint-Lucas, Ghent, Belgium

Area of Interest: Musculoskeletal bone;
Imaging Technique: MR-Diffusion/Perfusion;
Procedure: Diagnostic procedure;
Special Focus: Neoplasia;

Figure 4 Bone scintigraphy



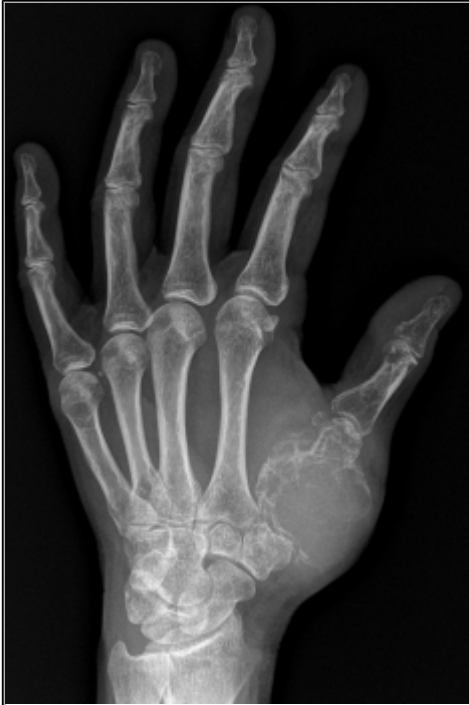Bone scintigraphy demonstrates increased radionuclide uptake and central photopenia. This finding is known as the "doughnut" sign.

© De Backer A, Department of Radiology, AZ Sint-Lucas, Ghent, Belgium

Area of Interest: Musculoskeletal bone;
Imaging Technique: Nuclear medicine conventional;

Procedure: Diagnostic procedure;
Special Focus: Neoplasia;

Figure 5 Plain radiograph (3 months later)

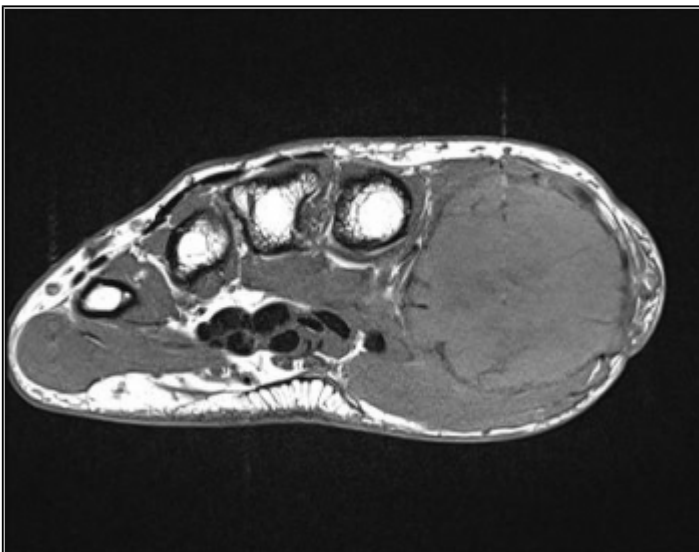


Plain radiograph performed three months later. There is marked increase of the size, expansion and cortical breakthrough of the lesion.

© De Backer A, Department of Radiology, AZ Sint-Lucas, Ghent, Belgium

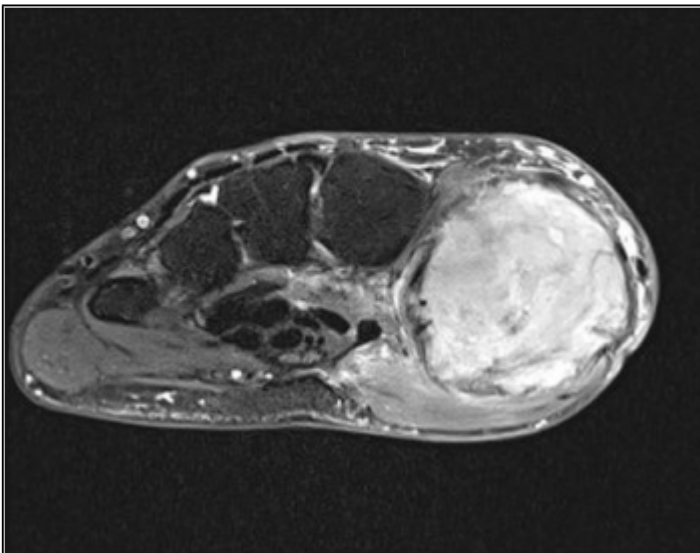
Area of Interest: Musculoskeletal bone;
Imaging Technique: Plain radiographic studies;
Procedure: Diagnostic procedure;
Special Focus: Neoplasia;

Figure 6 MRI findings (3 months later)



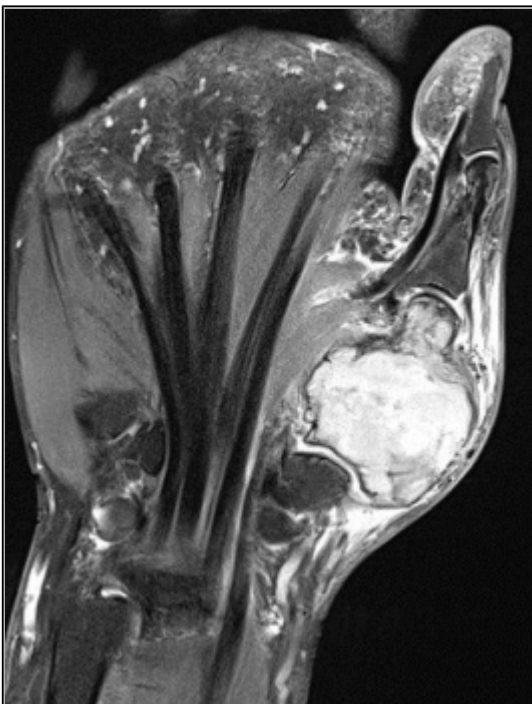
A. MR findings performed three months after initial MR examination. Axial T1-WI shows further tumour growth. Bone marrow replacement is of heterogeneously low signal intensity.

Area of Interest: Musculoskeletal bone;
Imaging Technique: MR;
Procedure: Diagnostic procedure;
Special Focus: Neoplasia;



B and C: On axial and coronal fat suppressed T2-WI an intermediate to high SI is seen with intralesional areas of low signal intensity. There is no extension into the CMC and metacarpophalangeal joint

Area of Interest: Musculoskeletal bone;
Imaging Technique: MR;
Procedure: Diagnostic procedure;
Special Focus: Neoplasia;

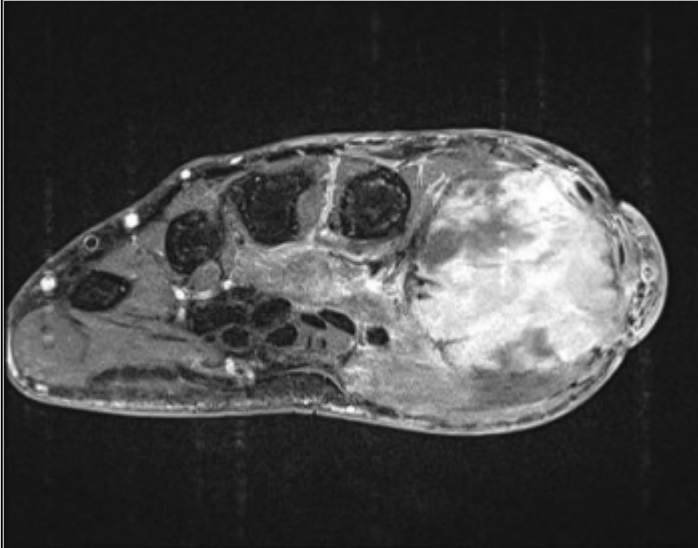


B and C: On axial and coronal fat suppressed T2-WI an intermediate to high SI is seen with

intralesional areas of low signal intensity. There is no extension into the CMC and metacarpophalangeal joint

© De Backer A, Department of Radiology, AZ Sint-Lucas, Ghent, Belgium

Area of Interest: Musculoskeletal bone;
Imaging Technique: MR;
Procedure: Diagnostic procedure;
Special Focus: Neoplasia;

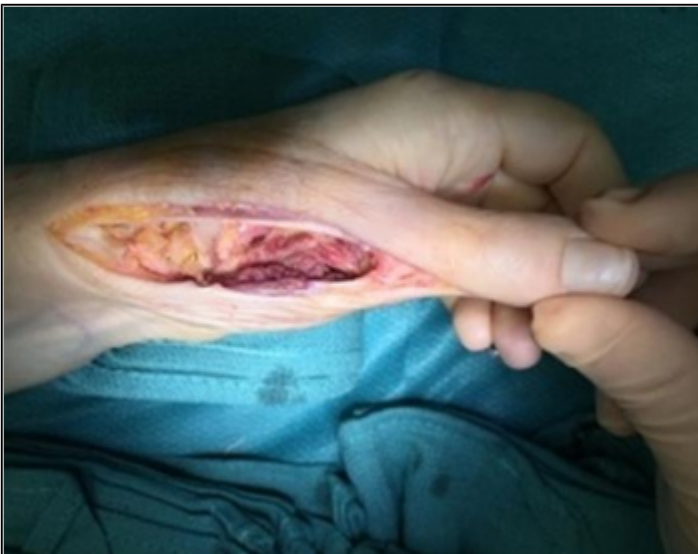

D. On axial contrast-enhanced T1-WI with fat suppression demonstrates heterogeneous enhancement of the lesion and its soft tissue extension.

© De Backer A, Department of Radiology, AZ Sint-Lucas, Ghent, Belgium

Area of Interest: Musculoskeletal bone;
Imaging Technique: MR-Diffusion/Perfusion;
Procedure: Diagnostic procedure;
Special Focus: Neoplasia;

Figure 7 Intra-operative

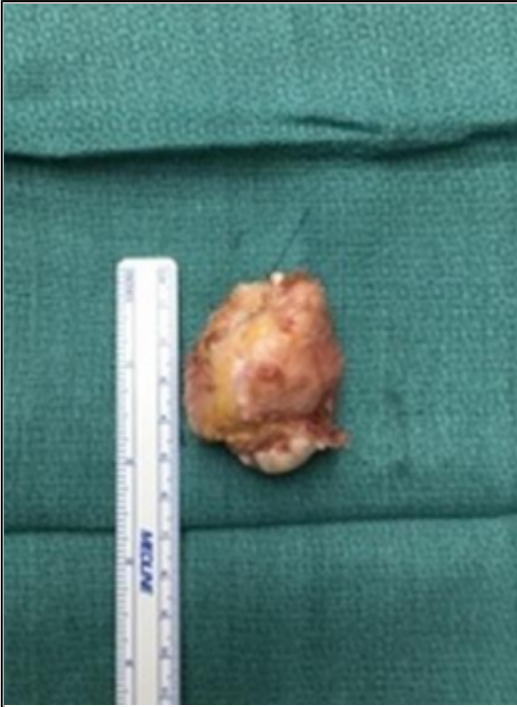

A. Operative view of first metacarpal.

© Planckaert G, UZ Ghent, Ghent, Belgium

Area of Interest: Musculoskeletal soft tissue;

Imaging Technique: Experimental;
Procedure: Intraoperative;
Special Focus: Neoplasia;

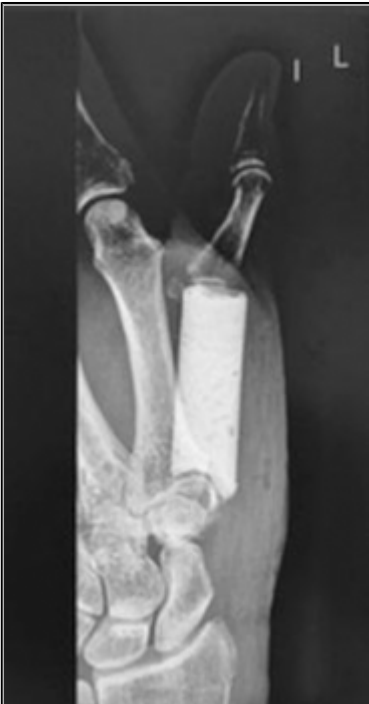

B. Resection specimen measuring 5.4 cm.

© Planckaert G, UZ Ghent, Ghent, Belgium

Area of Interest: Musculoskeletal bone;
Imaging Technique: Experimental;
Procedure: Intraoperative;
Special Focus: Neoplasia;

Figure 8 Post-operative



Post-operative plain radiograph of the left thumb. The resection cavity is filled with methyl acrylate bone cement.

© De Backer A, Department of Radiology, AZ Sint-Lucas, Ghent, Belgium

Area of Interest: Musculoskeletal bone;
Imaging Technique: Plain radiographic studies;
Procedure: Diagnostic procedure;
Special Focus: Neoplasia;

References

- [1] Sobti A, Agrawal P, Agarwala S, Agarwal M (2016) Giant Cell Tumor of Bone - An Overview The Archives of Bone and Joint Surgery 4(1):2-9.
- [2] Matev B, Georgiev H, Georgiev G (2012) Giant cell tumor of the fourth metacarpal: case report and literature review Journal of Radiotherapy and Medical Oncology 18:73-77.
- [3] Jin AK, Park JS, Park SY, et al (2011) Aggressive Behavior of a Giant Cell Tumor Involving the Metacarpal Bone During Pregnancy: Case Report Journal of the Korean Radiological Society 64(5):509-513.
- [4] Pereira HM, Marchiori E, Severo A (2014) Magnetic resonance imaging aspects of giant-cell tumours of bone Journal of Medical Imaging and Radiation Oncology 58(6):674-8.
- [5] Chakarun CJ, Forrester DM, Gottsegen CJ, Patel DB Jr (2013) Giant cell tumor of bone: review, mimics, and new developments in treatment Radiographics 33(1):197-211.
- [6] Roy S, Mukherjee S, Mahata M, Datta J, Das TK (2016) Giant cell tumor in first metacarpal bone: A rare entity International Journal of Medical Science and Public Health 5:1049-1051.
- [7] McEnery KW, Raymond AK (1999) Giant cell tumor of the fourth metacarpal American Journal of Roentgenology 172(4):1092.

Citation

Lucas Verniers (1), Adelard De Backer (2), Wim Vanhove (3), Gwen Sys (3), Filip Vanhoenacker (4, 5, 6)

(1) Ghent University, Medical Student, Corneel Heymanslaan 10, 9000 Ghent, Belgium

(2) General Hospital Sint-Lucas, Department of Radiology, Groenebriel 1, 9000 Ghent, Belgium

(3) Ghent university, Department of Orthopaedics, Corneel Heymanslaan 10, 9000 Ghent, Belgium

(4) AZ Sint-Maarten Duffel-Mechelen, Department of Radiology, Leopoldstraat 2, 2800 Mechelen, Belgium

(5) Ghent University Hospital, Department of Radiology, Corneel Heymanslaan 10, 9000 Ghent, Belgium

(6) Antwerp University Hospital, Department of Radiology, Wilrijkstraat 10, 2650 Edegem, Belgium

UZ Ghent; Corneel heymanslaan 10 9000 Ghent, Belgium; Email:lucas.verniers@ugent.be (2018,

Jul. 4)

Aggressive Giant Cell tumour of the Metacarpal {Online}

URL: <http://www.eurorad.org/case.php?id=15826>