

Pathogenesis, diagnosis and treatment of Rasmussen encephalitis

A European consensus statement

C. G. Bien,¹ T. Granata,² C. Antozzi,² J. H. Cross,³ O. Dulac,⁴ M. Kurthen,¹ H. Lassmann,⁵ R. Mantegazza,² J.-G. Villemure,⁶ R. Spreafico² and C. E. Elger¹

¹University of Bonn, Department of Epileptology, Bonn, Germany, ²Instituto Nazionale Neurologico 'C. Besta', Milan, Italy, ³Institute of Child Health and Great Ormond Street Hospital for Children NHS Trust, London, UK, ⁴Service de Maladies Métaboliques et Neurologie Hôpital Necker Enfants Malades, Paris, France, ⁵Medical University of Vienna, Brain Research Institute, Vienna, Austria, and ⁶Centre Hospitalier Universitaire Vaudois, Lausanne, Switzerland

Correspondence to: Dr Christian G. Bien, University of Bonn, Department of Epileptology, Sigmund-Freud-Str. 25, 53105 Bonn, Germany
E-mail: christian.bien@ukb.uni-bonn.de
C. G. Bien and T. Granata contributed equally to this manuscript.

Summary

Rasmussen encephalitis (RE) is a rare but severe immune-mediated brain disorder leading to unilateral hemispheric atrophy, associated progressive neurological dysfunction and intractable seizures. Recent data on the pathogenesis

of the disease, its clinical and paraclinical presentation, and therapeutic approaches are summarized. Based on these data, we propose formal diagnostic criteria and a therapeutic pathway for the management of RE patients.

Keywords: encephalitis; epilepsy; pathophysiology; diagnostic criteria; therapy

Abbreviations: AED = anti-epilepsy drug; BBB = blood–brain barrier; CTL = cytotoxic T lymphocyte; EPC = epilepsia partialis continua; FDG = fluorodeoxyglucose; GluR3 = glutamate receptor subunit 3; GrB = Granzyme B; HE = hemispherectomy or any of its variants; IVIG = intravenous immunoglobulins; PEX/PAI = plasma exchange/protein A IgG immuno-adsorption; RE = Rasmussen encephalitis; SPECT = single photon emission computed tomography; TCR = T cell receptors

Received September 21, 2004. Revised January 6, 2005. Accepted January 7, 2005. Advance Access publication February 2, 2005

Introduction

In 1958, Theodore Rasmussen and co-workers from the Montreal Neurological Institute reported three patients suffering from 'focal seizures due to chronic localized encephalitis' (Rasmussen *et al.*, 1958). Since the late 1980s, most researchers and clinicians have adopted the term Rasmussen encephalitis (RE) or Rasmussen syndrome for this condition (Piatt *et al.*, 1988; Andermann, 1991). In recent years, important new insights have added to our understanding of the pathophysiology, the diagnosis and the management of the condition. Here, we present a summary of the existing knowledge and experience with an emphasis on the clinical management of RE patients. The consensus proposed here for the diagnosis and therapy of RE results from a symposium entitled 'Current concepts and controversies

in Rasmussen's encephalitis' held at the 6th European Congress on Epileptology in Vienna on 1 June 2004.

Aetiology and pathogenesis of RE

RE is a rare disease that should be envisaged as sporadic, since there is no evidence for a genetic component (Andermann *et al.*, 1991; Grenier *et al.*, 1991). There is, at present, no conclusive evidence why and how RE starts. A viral aetiology was already suggested by Rasmussen based on the constituents of the immune reaction in the brains such as lymphocyte infiltration and microglial nodules (Rasmussen *et al.*, 1958). The similarities of RE and Russian spring summer meningoencephalitis, which is caused by a flavivirus, further supported this hypothesis (Asher and Gajdusek, 1991).

However, so far all attempts to identify a pathogenic viral agent have been contradictory and inconclusive (Friedman *et al.*, 1977; Rasmussen, 1978; Walter and Renella, 1989; Power *et al.*, 1990; Farrell *et al.*, 1991; Gilden and Lipton, 1991; Vinters *et al.*, 1993; McLachlan *et al.*, 1993, 1996; Atkins *et al.*, 1995; Jay *et al.*, 1995). Available data continue to suggest an immune basis to the pathogenesis of RE. Evidence has emerged both of a role for humoral factors, namely autoantibodies, as well as more recently T lymphocytes, namely cytotoxic T cells.

Humoral autoimmunity

In the course of raising antibodies against subunit 3 of the ionotropic glutamate receptor (GluR3) in rabbits, two out of four rabbits immunized with the GluR3 fusion protein developed seizures. Histopathological examination of their brains revealed bihemispheric inflammatory changes which were reported to mimic those of RE. Subsequent studies in patients showed that three out of four RE patients' sera harboured those GluR3 antibodies. One of these patients improved transiently after plasma exchange (Rogers *et al.*, 1994). Other reports of temporary or longer lasting improvement of the symptoms of RE by removal of antibodies from the circulation have subsequently been published (Andrews *et al.*, 1996; Palcoux *et al.*, 1997; Antozzi *et al.*, 1998; Granata *et al.*, 2003a). How autoantibodies might lead to brain tissue destruction and seizure activity has been answered in two different ways: Some authors report evidence that GluR3 antibodies mediate an excessive, cytotoxic activation of the glutamate receptor using *in vitro* (Twyman *et al.*, 1995; Levite *et al.*, 1999) and *in vivo* systems (Levite and Hermelin, 1999). Others have observed signs of a complement activation on neurons and glial cells in animals and affected humans without measurable channel activating properties (He *et al.*, 1998; Whitney *et al.*, 1999; Whitney and McNamara, 2000; Frassoni *et al.*, 2001).

More recently, the specificity of GluR3 autoantibodies for RE has been challenged. Two groups, both using an enzyme-linked immunosorbent assay approach to detect antibodies against different GluR3 peptides, reached congruent results: GluR antibodies (in serum, but similar results in CSF samples) are not present in all RE patients, and they are found in other epilepsy forms in a comparable proportion (Wiendl *et al.*, 2001; Mantegazza *et al.*, 2002). A subsequent report even questioned these partially positive results by use of five different approaches to test for GluR3 antibodies (Watson *et al.*, 2004). However, further arguments for a humoral or complement-dependent pathogenesis (not necessarily mediated by GluR3 antibodies) have been provided: Yang and co-workers described a RE case with antibodies against the cytosolic presynaptic protein munc-8 (Yang *et al.*, 2002). In brain samples of four RE patients, Baranzini and colleagues studied the immunoglobulin heavy chain CDR3 (IgGVH-CDR3) repertoire and analysed it by size spectratyping and sequencing. They found evidence for clonally

expanded B lymphocytes in RE, but the IgGVH-CDR3 sequences were diverse among the four cases. Possible reasons put forward for this included determinant spreading and genetic or antigenic heterogeneity (Baranzini *et al.*, 2002). Xiong and colleagues showed that the sequential application of the complement cascade proteins C5b6, C7, C8 and C9, which are known to lead to the formation of the membrane attack complex (MAC), into the hippocampi of rats lead to epileptic seizures and massive necrotic hippocampal cell death (Xiong *et al.*, 2003).

Taken together, there is highly conflicting evidence regarding the pathogenic effect and even the mere presence of elevated GluR3 autoantibodies in RE. This does not exclude that other humoral mechanisms may contribute to the pathogenesis of RE. Future antibody research in RE will probably concentrate on detecting possibly pathogenic antibodies other than GluR3 antibodies (Lang *et al.*, 2004).

T cell mediated cytotoxicity in RE

In the first extensive histopathological-immunohistochemical study on RE brains, it was found that the majority of the inflammatory round cells were T lymphocytes (Farrell *et al.*, 1995). Consecutively, Li *et al.* (1997) analysed these T cells with regard to their T cell receptors (TCR). This group studied TCR expression in RE brain samples by quantitative assessment of TCR V β gene transcripts. A restricted (oligoclonal) BV family usage was found; however, the TCR V β families that were predominantly expressed displayed a limited size heterogeneity and extensive repetition of in-frame CDR3 nucleotide motifs compared with controls. These findings suggest that the local immune response in RE includes restricted T cell populations that have likely expanded from a few precursor T cells responding to discrete antigenic epitopes (Li *et al.*, 1997). Further immunohistochemical studies on RE brain specimens provided evidence of a Granzyme B (GrB) mediated cytotoxic T lymphocyte (CTL) attack against neurons. All elements of such a reaction could be documented in RE: T cells containing GrB granules, target cells (here neurons) expressing major histocompatibility complex (MHC) class I and dying by apoptosis. This CTL mechanism is suitable to explain the progressive brain tissue loss. However, it cannot directly account for the epileptic activity in RE brains and there is, at present, no evidence against which antigen(s) the CTLs are directed (Bien *et al.*, 2002a).

Gahring and co-workers have provided a potential link between the GluR3-autoantibody-hypothesis and the findings regarding CTLs (Gahring *et al.*, 2001): they found that the immunogenic section of the GluR3 protein could be exposed to the immune system only after cleavage of GluR3 by GrB. A necessary prerequisite for this is that an internal N-linked glycosylation sequence within the GluR3-GrB recognition sequence (ISND*S) is not glycosylated. This observation concords with an earlier study indicating a possible interrelationship of GrB⁺ proteolytic effects and a

humoral autoimmunity in systemic autoimmune diseases (Casciola-Rosen *et al.*, 1999). However, in view of the doubtful relevance of the GluR3 antibodies the study by Gahring and colleagues can, at present, not serve as a valid explanation for RE pathogenesis.

RE as an epileptic encephalopathy

In analogy to other conditions of childhood epilepsies with progressive neurological deterioration, it has been suggested that in RE, too, the epileptic activity itself may contribute to the functional decline (Nabbout and Dulac, 2003). After a few months, partial motor seizures affect, in an apparently independent fashion, various areas of the same side of the body, the affected part of the body increasing over time. EEG recordings show unilateral deterioration of the background activity and repeat focal rhythmic discharges migrating from one area of the cortex to another on the affected side, often without clear correspondence to the clinical events and, as with the clinical events, the discharges persist during sleep. Focal motor deficit usually follows the onset of epilepsy. The strength of the affected part of the body decreases and the patient progressively becomes hemiparetic. However, the downhill course of motor abilities on the affected side is irregular and depends of the intensity of the seizure activity, with periods of improvement when there is transient control of the seizures (Chinchilla *et al.*, 1994). It is thus often difficult to determine whether the motor defect is purely functional because of frequent seizures and therefore reversible, or if it results from loss of cortical cells. Nevertheless, steroids given early in the course of the disease are able to reduce the severity of the deficit, particularly for children with onset after 4 years of age, provided seizure activity is brought under control (Chinchilla *et al.*, 1994).

Whether humoral, cellular or mixed, the immune effector cells or antibodies originate from the blood stream. Since in Rasmussen disease the brain involvement is mainly unilateral, some factor additional to autoimmunity must contribute to the pathogenesis in order to determine unilaterality. Focal epilepsy could be this factor. Indeed, seizure discharges are known to functionally damage the blood–brain barrier (BBB). Humoral compounds could therefore reach the neurons and damage them, increasing the epileptic activity and the functional damage to the BBB, closing thereby a vicious circle (Andrews *et al.*, 1996). This would be of importance for antibodies, as they cannot cross an intact BBB, in contrast to activated T cells. The concept of epileptogenic encephalopathy would, in this disorder, have a larger and specific meaning: seizures would not only generate functional defect, but also contribute to the immunologically generated neuronal loss and brain atrophy.

In conclusion, the precise nature and sequence of the pathogenetically relevant processes have not yet been agreed on. Some authors (Antel and Rasmussen, 1996; Krauss *et al.*, 1996; Baranzini *et al.*, 2002) ask if, in all RE patients and indeed at all stages of their disease, a uniform process takes

place. However, this cannot be clarified at this stage and there are at present no data to distinguish potential pathogenetic subgroups, especially not with regard to specific therapeutic strategies.

Clinical features

Clinical disease course

Reported cohorts of individuals with RE are not large, but conclusions about the natural history of the disease can be drawn (Oguni *et al.*, 1991; Bien *et al.*, 2002*c,d*; Chiapparini *et al.*, 2003; Granata *et al.*, 2003*b*). Although seen in adulthood, the majority present in childhood with an average age at disease manifestation of 6 years of age (Oguni *et al.*, 1991). Three disease stages have recently been proposed. Initially, there may be a rather non-specific ‘prodromal stage’ with a relatively low seizure frequency and rarely mild hemiparesis with a median duration of 7.1 months (range: 0 months to 8.1 years). Following this, all patients enter an ‘acute stage’ of the disease, although for a third of cases, this appears to be the initial clinical disease manifestation. It is characterized by frequent seizures, mostly simple partial motor seizures often in the form of *epilepsia partialis continua* (EPC). The neurological deterioration becomes manifest by progressive hemiparesis, hemianopia, cognitive deterioration and, if the language dominant hemisphere is affected, aphasia (Oguni *et al.*, 1991). The median duration of this stage is 8 months (range 4–8 months). After that, the patients pass into the ‘residual stage’ with permanent and stable neurological deficits and still many seizures, although less frequent than in the acute stage. At this stage, not all the patients are hemiplegic (Bien *et al.*, 2002*d*). The large time ranges for the duration of the disease stages indicate the high variability of speed and severity of the destructive process in different patients. For clinical monitoring of the disease progress, hemiparesis is the most useful marker as this feature is most consistently found, and it allows quantitative evaluation, even in children. Since it can be increased by additional transient postictal paresis in cases with motor seizures, several examinations—especially in periods without high frequency of seizures—may be necessary to obtain a reliable impression of the degree of permanent motor impairment. In addition, periodic assessment of neuropsychological performance is recommended in order to detect cognitive decline, especially in cases without overt hemiparesis, such as those of temporal lobe origin (Hennessy *et al.*, 2001).

Epileptic seizures

Three features of the epilepsy in RE patients have been noted: (i) the polymorphism of seizures in a given patient; (ii) the frequent occurrence of EPC; and (iii) the medical intractability of seizures, particularly of EPC (see the section on Treatment below). The different semiologies of seizures, often noted on longitudinal evaluation of patient records (Granata *et al.*, 2003*b*), is best explained as a ‘march (of

the epileptic focus) across the hemisphere' (Oguni *et al.*, 1991). Congruent observations have been made by serial neuroimaging studies. However, apart from the rare cases of bilateral RE, all seizures originate in one hemisphere. Oguni and co-workers quantified the clinical seizure types during the disease course of their series of 48 patients. Simple partial motor seizures involving one side of the body were the most common (occurring in 77% of cases), followed by secondarily generalized tonic clonic seizures (42%), complex partial seizures (19% with automatisms and 31% with subsequent unilateral motor involvement), postural seizures probably originating in the supplementary motor region (24%) and somatosensory seizures (21%) (Oguni *et al.*, 1991).

EPC has been reported to occur in 56–92% of patients at some time during their disease course (Oguni *et al.*, 1991; Honavar *et al.*, 1992; Bien *et al.*, 2002*d*; Granata *et al.*, 2003*b*). EPC was originally described in Russian adults (Koshewnikow, 1895) suffering from Russian spring-summer encephalitis (Omorokow, 1927) and has subsequently caused extensive discussions regarding its nature and origin. This debate cannot be summarized here. Today, EPC is most commonly viewed as cortical and epileptic with mainly three peculiarities:

- (i) it cannot be influenced by anticonvulsive drugs;
- (ii) unlike other motor seizures, EPC does not have the general tendency to spread (as Jacksonian seizures do—even though Jacksonian seizures may evolve from time to time from EPC);
- (iii) it does not stop after the usual short time of focal motor seizures. (Juil-Jensen and Denny-Brown, 1966; Bancaud *et al.*, 1977; Thomas *et al.*, 1977; Wieser *et al.*, 1978; Cockerell *et al.*, 1996).

Less common manifestations of RE

Adolescent and adult cases

Even though RE has for a long time been considered as a childhood disease, adolescent and adult patients have been described by several groups (Gray *et al.*, 1987; Oguni *et al.*, 1991; McLachlan *et al.*, 1993; Hart *et al.*, 1994*b*, 1997; Larner *et al.*, 1995; Krauss *et al.*, 1996; Bhatjiwale *et al.*, 1998; Leach *et al.*, 1999; Bien *et al.*, 2002*d*) and based on figures from Montreal, can be estimated to account for about 10% of all RE cases (Oguni *et al.*, 1991; Hart *et al.*, 1997). The oldest patient reported so far was 54-years-old (Vadlamudi *et al.*, 2000). The Montreal group described 13 patients, who had in common a localization-related seizure disorder and the pathological features of chronic encephalitis. Even if one excludes two highly atypical cases (numbers 4 and 13, who obviously had another disease, as already considered by the authors), the similarities between the 'true' adolescent/adult and the childhood RE cases were more obvious than the differences (Hart *et al.*, 1997). They appear to have a more protracted and milder clinical

course with less residual functional deficits and lower degrees of hemiatrophy and more frequent occipital lobe seizure onset (Hart *et al.*, 1997; Bien *et al.*, 2002*d*), but identical histopathological as well as clinical, electrophysiological and neuroimaging findings.

Dual pathology

Cases with dual pathology (RE plus low grade tumour, cortical dysplasia, tuberous sclerosis, vascular abnormalities or old ischaemic lesions) have been described (Hart *et al.*, 1998; Firlik *et al.*, 1999; Palmer *et al.*, 1999; Thom *et al.*, 1999; Bien *et al.*, 2002*d*). In the Montreal series, ~10% of cases had dual pathology (Hart *et al.*, 1998). The diagnosis of dual pathology has, in part, been suspected based on MRI findings, but always been confirmed by histopathology (biopsy or resective epilepsy surgery).

Bilateral RE

Several clinical and electrophysiological features have suggested bilateral cerebral affection in otherwise typical unihemispheric cases, e.g. secondary spread of focal seizures to the contralateral side, interictal epileptiform abnormalities on the contralateral side (see below), or mild contralateral atrophy (Hart and Andermann, 2000). A recent volumetric study of serial MRIs of 11 (immunotherapeutically treated) RE patients showed, that not only the 'affected', but also the 'unaffected' hemispheres underwent progressive atrophy—the latter, however, at a significantly lower rate. The authors suggested a Wallerian degeneration of commissural fibres, the effect of the chronic epilepsy or the treatment as possible reasons for this phenomenon, but argued against a similar primary pathogenic process in both hemispheres (Larionov *et al.*, 2005). The term 'bilateral RE' should therefore be reserved for cases with inflammatory lesions in both hemispheres. Among the ~200 RE cases reported in the literature, bihemispheric involvement has been suggested in nine (McLachlan *et al.*, 1993; Chinchilla *et al.*, 1994; DeToledo and Smith, 1994; Tobias *et al.*, 2003). Using the above criteria, four cases (Chinchilla *et al.*, 1994; Tobias *et al.*, 2003) are examples of true bilateral RE. Two other cases were brothers with a presentation and course highly atypical for RE. As concluded by the authors of that report, these patients may have had a variant of RE (Silver *et al.*, 1998). In the remaining three, the diagnosis of 'bilateral RE' is in doubt (McLachlan *et al.*, 1993; DeToledo and Smith, 1994).

We conclude that bilateral RE is very rare. There is no evidence for an inherent tendency of RE to spread to the contralateral side after longstanding disease. Of note, the above named four convincing cases had signs of bilateral involvement earlier than 13 months after disease onset (Chinchilla *et al.*, 1994; Tobias *et al.*, 2003). This seemingly paradoxical finding is most important in view of surgical indications: with over 10 years follow-up: no case of RE initially cured by surgery from the epilepsy point of view exhibited delayed relapse on the contralateral side, even

when the affected hemisphere was not removed but purely disconnected (Delalande and Bulteau, 2002).

RE with delayed seizures onset

An Israeli-German group studied two patients with progressive hemiparesis and biopsy evidence of RE. These patients developed unilaterally generated seizures only after several months (Korn-Lubetzki *et al.*, 2004).

Movement disorders in RE

Frucht (2002) presented a RE case with features of hemidystonia and hemiathetosis in addition to EPC. On MRI, this case had atrophy of the ipsilateral caudate and lentiform nuclei in addition to one-sided cortical affection. In an accompanying editorial, Andermann (2002) argued that movement disorders in RE probably have been underreported so far. An English group reporting on basal ganglia atrophy in RE (most markedly of the caudate nucleus) identified two of six cases initially presenting with hemidystonia (Bhatjiwale *et al.*, 1998).

Histopathology

The histopathological properties of RE have been described in several studies. Using standard histochemical staining techniques, Robitaille (1991) divided the Montreal material of brain specimens into four groups that were found to correspond to disease duration. Group 1 (earliest cases) revealed inflammation with numerous microglial nodules, with or without neuronophagia, perivascular round cells and glial scarring. Group 2 was characterized by several microglial nodules, cuffs of perivascular round cells, and at least one gyral segment of complete necrosis. Group 3 included cases displaying neuronal loss and gliosis with moderately abundant perivascular round cells and few microglial nodules. Finally, group 4 (latest cases) showed no or few microglial nodules, neuronal loss and mild perivascular inflammation, combined with various degrees of gliosis and glial scarring (Robitaille, 1991). The round cell infiltrates in RE brains consist almost exclusively of T lymphocytes (Farrell *et al.*, 1995). A large recent pathological study on the brain specimens obtained at 45 hemidecortications confirmed and refined Robitaille's description of a stagewise course (Pardo *et al.*, 2004). Using a quantitative histopathological-immunohistochemical approach, another group demonstrated densities of T cells, microglial nodules and activated astrocytes to be inversely correlated with disease duration (Bien *et al.*, 2002c). More recently, the same group extended their immunohistochemical observations by characterizing the majority of CD3⁺ cells (T cells) as CD8⁺ and containing GrB⁺ granules. A proportion of 7.0% of the CD8⁺ lymphocytes laid in apposition to neurons. Neurons were positive for MHC class I. A few neurons were found to die by apoptosis. These findings were interpreted as evidence for a cytotoxic T cell reaction against neurons. Another diagnostically

relevant observation was that <5% of the CD68⁺HLA-DR⁺ cells had macrophage morphology (the remainder had microglial morphology). Inclusion bodies suggestive of a viral infection have not been observed in RE. CD20⁺ cells (B cells) and CD138⁺ cells (plasma cells) are extremely rare. Signs of immunoglobulin deposits or activated complement were not found (Bien *et al.*, 2002a).

Paraclinical features of RE

EEG features

As early as 4 months after disease onset in a series of 12 patients, Granata and colleagues found pronounced EEG changes in their patients (Granata *et al.*, 2003b). They described polymorphic delta waves over the affected hemisphere, mainly in a temporal and central location. Nine out of 12 patients in addition had epileptiform abnormalities, which in five cases tended to evolve into (subclinical) ictal EEG patterns. During the disease course, the already initially impoverished background activity showed further flattening with persistence of the above described abnormalities. In the majority of patients, contralateral asynchronous slow waves and epileptiform discharges occurred. However, ictal patterns were never recorded from contralateral electrodes. So and Gloor (1991) found bilaterally independent ictal onsets in three out of 32 patients. Andrews and co-workers described serial EEGs in two patients. In both, they observed contralateral epileptiform discharges which, in the long term, became even more frequent than the ipsilateral ones (Andrews *et al.*, 1997). As in other conditions, EPC in RE is not always accompanied by rhythmic EEG discharges on surface EEG (Bancaud *et al.*, 1970; So and Gloor, 1991).

In summary, there is evidence that the EEG may contribute to the tentative diagnosis of RE already in early disease stages. The following unihemispheric findings strongly suggest RE: impairment of background activity and sleep spindles; focal slow activity; multifocal ictal discharges; and subclinical ictal discharges. In cases with the secure diagnosis of RE, the documentation of an independent contralateral seizure onset may raise the suspicion of bilateral disease (see above).

MRI

Serial MRI findings of several patients have been published during the last years. The Italian group (Chiapparini *et al.*, 2003; Granata *et al.*, 2003b) found that, within the first 4 months after disease onset, the majority of patients exhibit unilateral enlargement of the inner and outer CSF compartments, most accentuated in the insular and periinsular regions, with increased cortical or subcortical (or both) T2 (and FLAIR) signal. In addition, they observed atrophy of the ipsilateral head of the caudate nucleus in the majority of cases. A few patients transiently showed focal cortical swelling on early scans. Subsequently, a spread of signal changes and atrophy within the affected hemispheres was observed.

The German group combined similar observations with quantitative evaluation of cell densities of inflammatory cells and reactive astrocytes in brain specimens obtained from regions with MRI abnormalities. In areas with increased signal, the number of T cells, microglial nodules and GFAP⁺ astrocytes was increased compared with more chronically affected areas with advanced atrophy and no more signal increase (Bien *et al.*, 2002c). Using a quantitative approach (calculation of the 'hemispheric ratio', i.e. the ratio affected/unaffected hemisphere on planimetry of axial and coronal slices including the Sylvian fissure) to assess the temporal evolution of hemiatrophy, the same group found that most of the tissue loss occurs during the first 12 months after onset of the acute disease stage (Bien *et al.*, 2002d). However, it may, in some cases, go on for several years (Bhatjiwale *et al.*, 1998; Chiapparini *et al.*, 2003). In 11 immunotreated RE patients, volumetric assessment of serial MRIs during early disease stages revealed a median tissue loss of 29.9 cm³ per year in the affected and of 6.8 cm³ in the unaffected hemispheres (Larionov *et al.*, 2005). Totally normal findings on very early scans have been reported, but are rare (Geller *et al.*, 1998; Kaiboriboon *et al.*, 2000; Lee *et al.*, 2001). Gadolinium enhancement is very rare in RE (Nakasu *et al.*, 1997; Yacubian *et al.*, 1997; Bien *et al.*, 2002c; Chiapparini *et al.*, 2003).

Laboratory tests

No laboratory test is available to positively support the diagnosis of RE. GluR3 antibodies in serum (and CSF alike) do not discriminate between RE and noninflammatory epilepsy (Wiendl *et al.*, 2001; Mantegazza *et al.*, 2002; Watson *et al.*, 2004). Moreover, the presence or absence of GluR3 antibodies does not allow specific pathogenic clues in a given patient and should not be used to select or exclude a specific treatment.

CSF tests

The largest series of CSF tests has been reported by the Montreal group. In ~50% of the examinations, cell counts and protein levels were in the normal range. In the remainder, elevated cell counts (16–70 cells/ μ l, predominantly lymphocytes), an increased protein content (50–100 mg/dl) or a first or midzone elevation of the colloidal gold curve were observed. In only 15% of the abnormal CSF tests, all three parameters were abnormal (Rasmussen *et al.*, 1978; Rasmussen and Andermann, 1989). Oligoclonal bands were an inconsistent finding ranging from 0 to 67% in three small series (Dulac *et al.*, 1991; Grenier *et al.*, 1991; Granata *et al.*, 2003b). Therefore, CSF standard tests are not suitable to exclude or confirm the diagnosis of RE. Serological CSF tests are usually applied to rule out a CNS infection by known neurotropic agents.

Imaging studies other than morphological MRI

PET studies, almost exclusively performed using the tracer fluorodeoxyglucose (FDG), showed abnormalities confined to

the affected hemisphere. In most cases, large areas of hypometabolism were observed; in the remainder (mostly 'ictal' studies in patients with ongoing EPC), additional areas of focal hypermetabolism were found (Hajek *et al.*, 1991; Hwang *et al.*, 1991; Tampieri *et al.*, 1991; Caplan *et al.*, 1996; Duprez *et al.*, 1997; Banati *et al.*, 1999; Kaiboriboon *et al.*, 2000; Fiorella *et al.*, 2001; Lee *et al.*, 2001; Chiapparini *et al.*, 2003; Maeda *et al.*, 2003; Shah *et al.*, 2003). In the largest available study (15 patients), FDG-PET changes in early stages (disease duration up to 1 year) were confined to frontotemporal areas. In later stages, abnormalities also affected posterior cortical regions (Lee *et al.*, 2001). One case study suggested that FDG-PET-hypermetabolism correlates with ongoing electrical seizure activity whereas methionin-PET-hypermetabolism indicates areas of inflammation, but this needs to be confirmed in larger patients group (Maeda *et al.*, 2003). It has been proposed that PET might guide brain biopsy in cases with inconclusive or normal MRI findings, especially in early stages (Lee *et al.*, 2001).

With interictal and ictal single photon emission computed tomography (SPECT), the same type of results and conclusions have been reached as with PET (English *et al.*, 1989; Hwang *et al.*, 1991; Burke *et al.*, 1992; Buchhalter *et al.*, 1994; Duprez *et al.*, 1997; Geller *et al.*, 1998; Leach *et al.*, 1999; Hartley *et al.*, 2002; Thomas *et al.*, 2003; Chiapparini *et al.*, 2003).

Magnetic resonance spectroscopy (MRS) studies consistently showed decreased N-acetyl-aspartate (NAA) levels and increased (or normal) choline (cho) peaks resulting in a decreased NAA/cho-ratio suggestive of neuronal loss or dysfunction (Matthews *et al.*, 1990; Cendes *et al.*, 1995; Geller *et al.*, 1998; Sener, 2000, 2003; Chiapparini *et al.*, 2003). Partly observed increased lactate peaks seemed to be associated with the presence of EPC (Matthews *et al.*, 1990; Cendes *et al.*, 1995; Sener, 2000; Chiapparini *et al.*, 2003). The present studies do not provide evidence for RE-specific MRS abnormalities.

In conclusion, PET, SPECT and MRS techniques are not suitable for defining the inflammatory nature of the condition. They may, however, help in confirming the unihemispheric nature in suspected early RE findings.

Brain biopsy

Brain biopsy is not required in all RE cases because other criteria can be sufficient to diagnose the condition (see Table 1). In 'burnt out' cases, brain biopsy may give non-specific results and not lead to initiation of immunomodulatory treatment (see below). In cases fulfilling neither the diagnostic criteria listed in Table 1 Part A nor the non-invasive criteria of Table 1 Part B as well as in less common RE forms, brain biopsy can contribute considerably to diagnostic certainty. Regarding brain biopsy, it has to be considered that abnormal and normal tissue elements may be located in very close apposition (Robitaille, 1991; Farrell *et al.*, 1995; Pardo *et al.*, 2004). Therefore, false negative

Table 1 Diagnostic criteria for RE

RE can be diagnosed if either all three criteria of Part A or two out of three criteria of Part B are present. Check first for the features of Part A. Then, if these are not fulfilled, of Part B. In addition: If no biopsy is performed, MRI with administration of gadolinium and cranial CT needs to be performed to document the absence of gadolinium enhancement and calcifications to exclude the differential diagnosis of a unihemispheric vasculitis (Derry *et al.*, 2002).

Part A:

- | | |
|-------------|---|
| 1. Clinical | Focal seizures (with or without Epilepsia partialis continua) and Unilateral cortical deficit(s) |
| 2. EEG | Unihemispheric slowing with or without epileptiform activity and Unilateral seizure onset |
| 3. MRI | Unihemispheric focal cortical atrophy and at least one of the following:
Grey or white matter T2/FLAIR hyperintense signal
Hyperintense signal or atrophy of the ipsilateral caudate head |

Part B:

- | | |
|-------------------|---|
| 1. Clinical | Epilepsia partialis continua or Progressive* unilateral cortical deficit(s) |
| 2. MRI | Progressive* unihemispheric focal cortical atrophy |
| 3. Histopathology | T cell dominated encephalitis with activated microglial cells (typically, but not necessarily forming nodules) and reactive astrogliosis.
Numerous parenchymal macrophages, B cells or plasma cells or viral inclusion bodies exclude the diagnosis of RE. |

*'Progressive' means that at least two sequential clinical examinations or MRI studies are required to meet the respective criteria. To indicate clinical progression, each of these examinations must document a neurological deficit, and this must increase over time. To indicate progressive hemiatrophy, each of these MRIs must show hemiatrophy, and this must increase over time.

results may be obtained in a small stereotactic needle biopsy. If there are no contraindications, an open biopsy comprising meninges, grey and white matter is preferable. If, in suspicious cases, histology does not clearly show lymphocytic inflammation and microglial (nodular) activation, evaluation of serial sections may be necessary. More limited surgical tissue collection, especially stereotactic procedures, increases the risk of falsely negative results in an unacceptable manner. Biopsy should be taken from a non-eloquent area where there is increased T2/FLAIR signal on MRI (Bien *et al.*, 2002c). In cases without clear MRI lesions, PET or SPECT may be helpful to determine the site of biopsy (Lee *et al.*, 2001). A gradient of inflammatory intensity from frontotemporal to occipital areas, especially in early cases, has been observed (Pardo *et al.*, 2004). Therefore, frontal or temporal biopsies are generally preferable (Lee *et al.*, 2001). Cases with predominant parietal or occipital involvement, however, exist (Bien *et al.*, 2002d). True histopathological differential diagnoses to RE are not as numerous as sometimes assumed. Chronic viral encephalitides (Booss and Esiri, 2003), paraneoplastic encephalitis (Graus *et al.*, 1990; Farrell *et al.*, 1995) and nonparaneoplastic limbic encephalitis (Bien *et al.*, 2000) need to be considered. If the results of brain biopsy are inconclusive, further clinical and MRI follow-up studies (e.g. every 6 months) are required to clarify the nature of the disease.

Differential diagnoses

Differential diagnostic considerations usually need to cover: (i) other unilateral neurological syndromes; (ii) other reasons for EPC; or (iii) other inflammatory or infectious diseases possibly mimicking RE. Potential differential diagnoses and diagnostic steps to exclude these are summarized in Table 2.

Diagnosis

The diagnosis of RE rests on clinical, electrophysiological (EEG) and morphological studies (MRI, in some cases histopathology). In most chronic patients (i.e. after a disease duration of >1 year), differential diagnoses are few. The particular challenge, however, is the early recognition of the disease, i.e. before progressive hemiatrophy and progressive loss of neurological functions is evident. Early diagnosis is desirable (Bien *et al.*, 2002c,d; Granata *et al.*, 2003b) as immunosuppressive therapy may be most effective at this time. Therefore, any formal diagnostic criteria should be able to identify early as well as chronic cases. Age at onset has not been included among the diagnostic criteria, although it must be stressed that mostly RE starts in childhood.

Ten years ago, formal diagnostic criteria for RE were proposed (Hart *et al.*, 1994b). These criteria are still adequate in cases with EPC (so-called group A). However, the non-EPC group (group B) characterized by the authors only by the combination of 'focal epilepsy and biopsy evidence of [not further specified] chronic encephalitis' appears no longer sufficiently sensitive or specific. We therefore propose the diagnostic criteria given in Table 1. These criteria have the following aims: (i) to allow the diagnosis at all stages; (ii) to enable early diagnosis and thereby early decision about specific treatment (epilepsy surgery or immunotherapy); and (iii) to limit the use of brain biopsy to cases in which the diagnosis cannot be clarified by other means. To achieve these aims, the two-step approach outlined in the Table 1 has been designed. Any patient suspected to have RE should be checked for the highly characteristic clinical, EEG and MRI features listed in Part A. This is based on the results of a recent Italian study (Granata *et al.*, 2003b). If this combination is present, RE can be diagnosed without further follow-up studies (to document the progressive course of the

Table 2 Differential diagnoses to Rasmussen encephalitis

	Clinical and laboratory criteria
1. <i>Unihemispheric epileptic syndromes</i>	
Cortical dysplasia (Desbiens <i>et al.</i> , 1993)	EPC usually starts in infancy or early childhood
Hemimegalencephaly (Fusco and Vigeveno, 1991; Ishii <i>et al.</i> , 1995; Ohtsuka <i>et al.</i> , 1999)	
Tuberous sclerosis (Curatolo <i>et al.</i> , 2002; Karenfort <i>et al.</i> , 2002; McClintock, 2002)	MRI with gadolinium
Sturge-Weber-syndrome (Arzimanoglou and Aicardi, 1992; Kramer <i>et al.</i> , 2000)	No progression on MRI
Stroke (Thomas <i>et al.</i> , 1977; Nelson and Lynch, 2004)	Usually occurring in infancy
Hemiconvulsion-hemiplegia-epilepsy-syndrome (Kataoka <i>et al.</i> , 1988; Salih <i>et al.</i> , 1997; Freeman <i>et al.</i> , 2002)	Initial (tonic-)clonic unilateral seizure, presenting as status epilepticus
	Early MRI: affection of whole hemisphere indicative of diffuse cytotoxic edema
	Thereafter persistent fixed or slightly improving hemiparesis; hemispheric atrophy on MRI, and focal epilepsy MRI
Tumour (Botez and Brossard, 1974)	
2. <i>Epilepsia partialis continua (EPC) due to metabolic disorders</i>	
Diabetes mellitus:	History
Ketotic/non-ketotic hyperglykemia (Singh <i>et al.</i> , 1973; Singh and Strobos, 1980; Sabharwal <i>et al.</i> , 1989)	Blood tests
Type I diabetes and anti-GAD-65-antibodies (Barnett <i>et al.</i> , 2001)	Anti-GAD-65-antibodies
Renal or hepatic encephalopathy (Morres and Dire, 1989)	History
	Blood tests
3. <i>Metabolic or degenerative progressive neurological diseases</i>	
MELAS and other mitochondriopathies (Andermann <i>et al.</i> , 1986; Antozzi <i>et al.</i> , 1995; Schuelke <i>et al.</i> , 1998; Kunz, 2002)	Blood-lactate (low sensitivity)
	Mitochondrial DNA genetic testing for mutations
	Muscle biopsy
	Biochemical assessment of activity of mitochondrial enzymes
Alpers syndrome (Wilson <i>et al.</i> , 1993; Worle <i>et al.</i> , 1998; Rasmussen <i>et al.</i> , 2000)	History, progressive illness
	EEG
	MRI
	Evoked potentials
	Liver function tests
	Biochemical assessment of activity of mitochondrial enzymes
	EEG
	MRI
	Evoked potentials
	Skin biopsy
4. <i>Inflammatory/infectious diseases</i>	
Cerebral vasculitis in systemic connective tissue disease (e.g. lupus erythematosus) (Yoshida <i>et al.</i> , 1995)	History
	Other clinical features
	Autoantibodies (ANA, ANCA)
	CCT: calcifications
	MRI: gadolinium enhancement
	Brain biopsy
'Unihemispheric cerebral vasculitis mimicking Rasmussen's encephalitis' (Derry <i>et al.</i> , 2002)	History (vaccination status, early measles)
	EEG: periodic discharges
	Measles-antibodies in CSF
Subacute sclerosing panencephalitis (Lyon <i>et al.</i> , 1977) and other delayed subacute measles encephalitis with or without immunodeficiency	Tumour search
Paraneoplastic syndrome (Shavit <i>et al.</i> , 1999)	Onconeural antibodies (anti-Hu)
	Occurs only in Siberia
Russian spring summer meningoencephalitis (RSSE) (Omorokow, 1927)	History of tick-bites
	Antibody reaction against the specific virus of RSSE
	Brain biopsy: inclusion bodies
	History of previous episode(s)
	Additional deficits
	MRI
	Oligoclonal bands
	Evoked potentials
	14-3-3 protein in CSF (cave: no absolute specificity; 14-3-3 status of RE patients unknown)
	EEG
	MRI
Creutzfeldt-Jakob-disease (Fried <i>et al.</i> , 1995; Barnett <i>et al.</i> , 2001)	

Table 2 *Continued*

HIV (Ferrari <i>et al.</i> , 1998; Bartolomei <i>et al.</i> , 1999)	Blood antibody tests
Cat scratch disease (Nowakowski and Katz, 2002; Puligheddu <i>et al.</i> , 2004)	History Cutaneous papules, lymphadenopathy Serology (<i>Bartonella henselae</i>)
5. <i>Other</i>	
Proconvulsive drugs:	
Metrizimide (Shiozawa <i>et al.</i> , 1981)	History
Penicillin, Azlocillin-Cefotaxim (Wroe <i>et al.</i> , 1987)	
Bone marrow transplant (Antunes <i>et al.</i> , 2000)	History
Gliomatosis cerebri (Shahar <i>et al.</i> , 2002)	MRI

disease) and without brain biopsy. The Part A criteria of Table 1 are highly characteristic of early cases. To cover also the RE cases with a different presentation, we added Part B. If a patient fails to fulfil the criteria of Part A, he or she should be checked for the criteria of Part B. The criteria make use of the progressive nature of clinical and MRI deficits or of brain biopsy. Criteria listed in Part B in addition to Part A are highly likely to cover early cases, residual 'burnt out' cases and less common forms of RE. Only the (extraordinarily rare) cases of bilateral RE cannot be subsumed to these criteria. On the other hand, fulfilment of these criteria excludes other diseases. To our knowledge, only a histopathologically demonstrated vasculitis of the type described by Derry and colleagues in one single case could be mistaken for RE on the basis of these criteria without brain biopsy (Derry *et al.*, 2002). The only non-invasively assessed differences to RE in this case were gadolinium enhancement on MRI and calcifications on cranial CT. It is therefore required to rule out these features if RE is to be diagnosed without histopathological examination.

Treatment

Treatment of RE pursues two goals: alleviation of the seizure disorder and cessation of the progressive neurological deficit (and associated loss of brain tissue). The concept of this two-fold aim appears adequate in view of the timely dissociation of epilepsy manifestation from the development of cerebral hemiatrophy and functional deterioration which occur in parallel (Oguni *et al.*, 1991; Bien *et al.*, 2002*d*). Epileptic seizures can precede the other clinical features or RE; in the 'prodromal stage' (Bien *et al.*, 2002*d*), they may in rare cases start several months after the other signs and symptoms (Korn-Lubetzki *et al.*, 2004), and they may persist when the destructive encephalitic process obviously has itself 'burnt out' (Oguni *et al.*, 1991). Thus, while both epilepsy and neurological decline are most likely caused by the immunological process, the specific mechanisms involved may not be totally the same and may be differentially accessible for therapy.

Anti-epilepsy drug (AED) therapy

AEDs have consistently been found to be ineffective against EPC, but to have some effect against the other seizure types

(Piatt *et al.*, 1988; Dubeau and Sherwin, 1991; Topcu *et al.*, 1999). No anticonvulsive mono- or combination-therapy has been described to be superior to other regimens (Dubeau and Sherwin, 1991).

Epilepsy surgery

Epilepsy surgery has played a major role in seizure treatment of RE since the 1950s. It remains the only 'cure' of the disease progression, but not without neurological deficit. Examination of histopathological specimens from surgery permits the identification of the encephalitic nature of the disease (Rasmussen *et al.*, 1958). The earlier RE series almost exclusively consisted of surgically treated cases, e.g. 47 out of 48 patients in the Montreal series (Oguni *et al.*, 1991). This may have led to a somewhat biased view on the natural history of RE with an over-representation of more severely affected cases who may have been transferred to tertiary epilepsy centres for presurgical (pre-hemispherectomy) assessment more readily than cases with a milder disease course. The results of focal resections in RE patients have been disappointing (Olivier, 1991; Honavar *et al.*, 1992). Hemispherectomy and its modern variants (HE) (Villemure *et al.*, 1991; Delalande *et al.*, 1992; Honavar *et al.*, 1992; Schramm *et al.*, 1995, 2001; Villemure and Mascott, 1995; Carson *et al.*, 1996; Shimizu and Maehara, 2000), however, have been found to be the so far only—and highly effective—therapy to achieve seizure freedom. In RE patients, seizure freedom rates between 62.5% and 85% (Honavar *et al.*, Vining *et al.*, 1997; Delalande and Bulteau 2002; Villemure, 2002; Granata *et al.*, 2003*b*; Kossoff *et al.*, 2003; Jonas *et al.*, 2004; Pulsifer *et al.*, 2004) have been reported. In recent HE series, mostly disconnective techniques have been applied (see below). The mortality in HEs done on RE patients in such series has been reported as 0% (Devlin *et al.*, 2003; Kossoff *et al.*, 2003; Jonas *et al.*, 2004) to 4% (Villemure, 2002), and the complication rate (excluding hydrocephalus requiring shunt placement) as 0% with partly resective and partly disconnective techniques (Villemure 2002; Jonas *et al.*, 2004) to 22% with resective techniques only (Vining *et al.*, 1997).

Such a wide range in seizure control and complications is striking. One important variable that accounts for this is the surgical methodology utilized, whether based on resection or disconnection. As far as complications are concerned, there

is accumulating evidence that disconnective techniques (functional hemispherectomy and hemispherotomy) are associated with a lower incidence of complications compared with anatomical hemispherectomies (Villemure, 1997a,b). A possible disadvantage of those techniques compared with anatomical hemispherectomy is that incomplete disconnections may give rise to residual seizures. In experienced centres, the technique should not influence seizure outcome, but only the rate of complications.

Timing of surgery

There is a controversy as to whether HE should be proposed early in the disease course (Vining *et al.*, 1997) or only when the neurological deficits, which inevitably induced by the operation (loss of fine finger movements, hemianopia and, if the dominant hemisphere is affected, aphasia), have been brought about by the natural course of the disease (Villemure *et al.*, 1991; Honavar *et al.*, 1992; Rasmussen, 1993). The latter standpoint is supported by the observation that not all patients proceed to maximal deficits, especially—but not exclusively—in the late-onset form (Oguni *et al.*, 1991; Bien *et al.*, 2002d). The advocates of early surgery have argued that the advantages of seizure freedom and a post-HE overall functional improvement justify the ‘anticipation’ of ‘inevitable’ consequences of the disease (Vining *et al.*, 1993, 1997).

The decision will be influenced by the dominance of the hemisphere and be made only after extensive review and discussion with the child and family. It requires information about the deficits and advantages caused by the surgical procedure in relation to the disease course without surgical intervention. The consequences of a HE in RE can be summarized as follows.

Motor outcome after HE

After HE, patients will have a spastic hemiplegia of the contralateral side with loss of the (functionally highly relevant) fine motor hand movements (van Empelen *et al.*, 2004). However, only a minority of patients are unable to walk without the use of assistive devices. As reported in a large recent HE series (consisting not only of RE cases), patients not achieving ambulation post-operatively were either immobile pre-operatively due to the underlying disease process, or had major post-operative complications, or suffered from persistent disabling seizures (Kossoff *et al.*, 2003).

Hemianopia

Another inevitable consequence of HE is a homonymous hemianopia to the contralateral side. Because of insufficient cooperation of many patients, it is often difficult to clarify if a hemianopia is already present due to the disease process itself when HE is considered. However, most clinicians treating RE patients feel that the risk of inducing hemianopia which is not present pre-operatively is tolerable because it does not interfere with the patient’s overall functioning (Villemure *et al.*, 1991).

Language

More difficult is the situation in patients with involvement of the hemisphere dominant for language functions. The most reliable test for language dominance is the Wada test. Language functional MRI (fMRI) testing may become an additional, non-invasive tool for assessment of language function lateralization. However, its applicability may be impaired by the reduced ability of patients to follow the instructions and the limited comparability of the two hemispheres due to the unilateral atrophy (Hertz-Pannier *et al.*, 2002). Further clues towards language lateralization may be derived from interictal and ictal language dysfunction. A group of RE patients with left-sided hemidecortication (without information on preoperative language dominance by Wada testing) showed impairment of expressive and receptive language functions compared with RE patients after right-sided HE. There were no significant differences in general intelligence, receptive language, visual motor-skills, behaviour or adaptive/developmental functioning between the two groups (cross-sectional data). Compared with their presurgical performance, the patients having undergone left-sided surgery deteriorated only in expressive language performance in a significant manner but not in general intelligence, receptive language, visual motor-skills, behaviour or adaptive/developmental functioning (longitudinal data) (Pulsifer *et al.*, 2004). The risk of post-operative language deficits, however, is not uniform for all patients. Particular concern regarding post-operative language deficits arises in cases with disease onset after the age of 4–6 years. One out of eight left-sided affected RE patients with a disease onset before the age of 6 years showed left-sided language dominance on Wada testing, whereas in eight patients starting above the age of 6 years, this ratio was exactly vice-versa (Taylor, 1991). Based on this and other observations (e.g. Branch *et al.*, 1964; Ogden, 1988; Boatman *et al.*, 1999), it is commonly assumed that the ability to establish (almost) complete language representation in the hemisphere not originally determined for this ends during the age period between 4 and 6 years. Six patients (with assumed left-sided dominance) underwent left-sided hemidecortication after an RE onset between 5.3 and 10.4 years. At 9–13 months of follow up, patients re-achieved their pre-operative scores on some tests of receptive language subfunction. However, they largely produced only telegraphic speech output (Boatman *et al.*, 1999). In a bilingual girl with RE onset at age 5 years, severe deficits in both languages, especially in expressive functions, were observed after a left-sided HE at the age of 10 years (Trudeau *et al.*, 2003). In contrast to these cases, two RE cases with late language transfer have also been reported. In one, manifestation of left-hemispheric RE was at 8 years of age. Compared with his pre-operative performance, the patient showed improved language performance after left-sided HE at the age of 15 years. In this patient, left-sided language dominance had been assessed by Wada testing at the age of 9 years and right sided dominance

immediately pre-operatively (Loddenkemper *et al.*, 2003). The second with disease onset at the age of 11 years became profoundly aphasic and underwent HE at the age of sixteen. Post-operatively, language dramatically improved (Telfeian *et al.*, 2002). A functional correlate for transfer of language functions in RE was suggested by Hertz-Pannier and colleagues in their report of a patient with onset of left sided RE at age 5.5 years. This boy underwent left sided HE at the age of 9 years. The post-operative course was like that of Boatman's patients (see above). Interestingly, the post-operative improvement mainly of receptive language functions was reflected in a right-hemisphere inferior frontal, temporal and parietal activation on fMRI in areas not activated during a fMRI obtained early in the disease course (Hertz-Pannier *et al.*, 2002).

Studies on the HE outcome in children with an onset of left-sided RE prior to the age of 4 years are rare. There are some reports on children with left-sided RE or other left-hemispheric diseases acquired very early in life undergoing hemispherectomy later on. Their language outcome following HE was better than in patients with disease onset after the age of 6 years; however, it was still below the normal age range (Ogden, 1988; Stark *et al.*, 1995; Stark and McGregor, 1997). It cannot be deduced from the existing literature if the age at surgery is a relevant prognostic factor for language outcome in this patient group (Vargha-Khadem *et al.*, 1991; Stark and McGregor, 1997).

The question of when and if HE on the dominant side is appropriate causes difficulties and often controversies. In the mid- to long-term course of RE, deficits may fluctuate over time and, in some conservatively treated patients, at least temporary improvement of previously impaired functions have been reported (Andrews *et al.*, 1996; Hart *et al.*, 1994b; Bien *et al.*, 2004). We suggest that in cases of dominant hemisphere involvement, HE is indicated in cases of very severe intractable epilepsy (i.e. manifest or impending complications due to the seizure activity) or with severe aphasia, which has been stable for at least some months (to exclude only temporarily aphasic patients). In children with a disease onset prior to the age of ~4 years, i.e. without fixed hemispheric lateralization, the decision in favour of or against HE should primarily be based on seizure severity and motor assessment rather than language considerations. Any decision made must be made on a multidisciplinary basis, individualised to the patient in question and only after full discussion with the family.

Immunotherapy

Immunosuppressive, immunomodulatory and antiviral treatment approaches have been applied, and several case reports and a few case series have been reported with variable and sometimes conflicting results (for a review, see Bien *et al.*, 2002b). Here, treatments with <6 reported patients in the literature will not be discussed further. This leaves the following regimens as the basis for our

recommendations: (i) corticosteroids (Chinchilla *et al.*, 1994; Hart *et al.*, 1994b; Granata *et al.*, 2003a); (ii) intravenous immunoglobulins (IVIG) (Walsh, 1991; Hart *et al.*, 1994b; Wise *et al.*, 1996; Leach *et al.*, 1999; Villani *et al.*, 2001; Granata *et al.*, 2003a); (iii) corticosteroids plus IVIG (Hart *et al.*, 1994b; Krauss *et al.*, 1996; Vinjamuri *et al.*, 2000); (iv) plasmapheresis (PEX) or protein A IgG immunoadsorption (PAI) (Andrews *et al.*, 1996; Palcoux *et al.*, 1997; Antozzi *et al.*, 1998; Granata *et al.*, 2003a); and (v) tacrolimus (Bien *et al.*, 2004).

Corticosteroids

Prednisolone/prednisone started at high doses and slowly tapered down have been reported to have beneficial effects on seizures and neurological functions in several series, particularly when started early in the course (Chinchilla *et al.*, 1994; Hart *et al.*, 1994b; Granata *et al.*, 2003a). Not unexpectedly, serious side effects partly necessitating steroid withdrawal have been noticed; fluid retention/Cushing's syndrome in all patients and, in single cases, psychosis, behavioural abnormalities, septicaemia, osteoporosis, hypertension and candidiasis (Chinchilla *et al.*, 1994; Hart *et al.*, 1994b; Granata *et al.*, 2003a). For long-term steroid therapy, it has been recommended to start with boluses of intravenous (i.v.) methylprednisolone [e.g. 400 mg/m²/day (Hart *et al.*, 1994b) or, in children, 20 mg/kg/day (Granata *et al.*, 2003a)] and then to introduce 1–2 mg/kg/day oral prednisolone or prednisone (Hart *et al.*, 1994a; Granata *et al.*, 2003a). This dose should be slowly reduced, ideally to a dose below the threshold of Cushing's syndrome. Short-term steroid bolus administration (dosing as above) has been found to be effective in blocking status epilepticus (Hart *et al.*, 1994b; Granata *et al.*, 2003a).

IVIG

Good effects of IVIG on seizures and neurological functions were reported in some case studies and in Hart's large series where IVIG is recommended as the first-line immunotherapy (Hart *et al.*, 1994b). In recent years, favourable responses of adult cases (Leach *et al.*, 1999; Villani *et al.*, 2001) have led to the proposal IVIG as first-line treatment especially in late-onset cases (Granata *et al.*, 2003a). Single responding cases with a follow-up of >12 months have been reported (Leach *et al.*, 1999; Granata *et al.*, 2003a). The recommended dosing scheme is to start with three to five consecutive infusions of 0.4 g/kg/day and to proceed with a monthly dose of 0.4–2.0 g/kg distributed over 1–5 consecutive days. Side effects of IVIG treatment are rare.

IVIG plus steroid

In case of insufficient effect of IVIG, Hart *et al.* (1994b) recommended a combination of 0.4 g/kg/month IVIG plus corticosteroids (dosing as above).

PEX/PAI

PEX cycles have been performed at a frequency of three to six single volume exchanges on consecutive or alternate days, repeated every 2 to 8 weeks (Andrews *et al.*, 1996; Granata *et al.*, 2003a). Selective periodic immuno-adsorption with protein A has been used as a long-term management with positive results in adolescent-adult onset patients (Antozzi *et al.*, 1998; Antozzi, 2004). PEX/PAI improved neurological function and seizure frequency in some patients during the weeks following the intervention that could be reinstated by repeat treatment. There is very limited experience with long term PEX/PAI treatment in RE (Granata *et al.*, 2003a).

Tacrolimus

Based on the observation of T lymphocyte mediated cell damage in RE brains, (Bien *et al.*, 2002a) performed long-term treatment with the T cell inhibiting immunosuppressant tacrolimus (oral application) in seven patients (median follow-up 25.4 months, range 12.4–32.0 months). In this trial, for the first time a surrogate marker of the RE disease process (the calculation of the hemispheric ratio from serial MRIs) was used as an additional outcome parameter. Also, for the first time, a control group consisting of 12 historical untreated patients was compared with the treatment group. The tacrolimus patients had a superior outcome regarding neurological function and progression rate of cerebral hemiatrophy on MRI, but no better seizure outcome. Their cognitive outcome was surprisingly good (only one patient deteriorated). None of the tacrolimus patients, but seven out of 12 control patients proceeded to hemispherectomy. Relevant tacrolimus side effects were not observed (Bien *et al.*, 2004).

Conclusions and recommendations for treatment of RE

Based on the reported experience with RE treatments, we recommend the following therapeutic pathway of the figure for patients fulfilling the diagnostic criteria for RE (Fig. 1).

Once a patient is diagnosed as having RE (field 1 in Fig. 1), it should be assessed if HE would lead to a relevant impairment of his/her motor or language functions according to the above summarized existing experience on the consequences of HE (field 2 in Fig. 1). If no relevant deterioration is to be expected (because the disease itself has already caused profound impairment) and the patient is suffering from intractable seizures (field 3 in Fig. 1), HE should be proposed (field 4 in Fig. 1). If there are no (more) intractable seizures (e.g. in ‘burnt out’ cases), no specific therapy is suggested (field 5 in Fig. 1). If in those patients intractable seizures recur (field 6 in Fig. 1), HE should be proposed (field 4 in Fig. 1).

In RE patients at risk of relevant functional deterioration by HE, i.e. with retained motor or language skills relevant for every-day function, it should be assessed if they are still in the course of ongoing deterioration (field 7 in Fig. 1). Indicators for ongoing progression are an increase of functional impairment (especially: EPC or high seizure frequency; increase of hemiparesis, cognitive or language deficits) or of cerebral hemiatrophy during the last 6–12 months. If the patient has been in a stable condition during this period, no specific treatment is recommended because it can be assumed that he or she has reached the residual stage of the disease (field 8 in Fig. 1). If there are, however, signs of continuous deterioration, the patient should be started on immunotherapy (field 9 in Fig. 1). Patients on immunotherapy (field 9 in Fig. 1) as

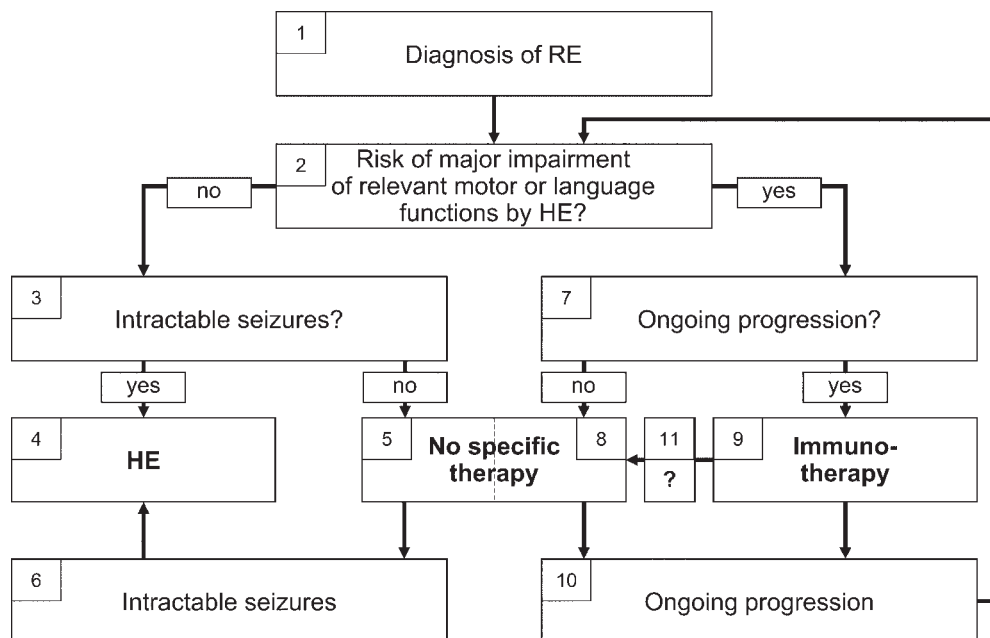


Fig. 1 Therapeutic approach to the RE patient.

well as those without specific treatment because of apparent inactivity of the destructive disease process (field 8 in Fig. 1) should be monitored for further progression. We suggest examining those patients every 6–12 months clinically and by brain MRI. If significant deterioration becomes evident, the patient should again be evaluated for eligibility for HE as described above (field 2 in Fig. 1). If there is still a risk of impairment by HE, the patient should proceed to immunotherapy (field 9 in Fig. 1) [because the criteria of ongoing progression (field 7 in Fig. 1) is fulfilled in these cases as evident from their passing through field 10 in Fig. 1], i.e. immunotherapy should either be initiated (if patients have been on no specific treatment before i.e. field 8 in Fig. 1) or changed (if patients have received immunotherapy before, field 9 in Fig. 1). Regular follow-up studies to detect a relevant disease progression (field 10 in Fig. 1) should be performed. It is not clear to date after what period of stabilization on immunotherapy this kind of treatment should be discontinued (field 11 in Fig. 1). It may be guessed that 2–3 years in a stable condition are the minimal time period before trying to taper any immunotreatment. If long-term steroid administration is performed, the lowest possible dose to maintain therapeutic benefit should be commenced. Again, we recommend regular follow-up examinations.

In general, patients having seizures should be treated with AEDs at any stage of the disease to reduce the frequency of non-EPC seizures. We recommend steroid boluses or PEX/PAI for periods of status epilepticus. There is, at present, insufficient evidence to give specific guidelines regarding the choice of the initial kind of immunotreatment. In the light of the present experience, steroids, IVIG, PEX/PAI or tacrolimus appear to be most suitable. At present, there is no evidence in favour of one specific treatment over the others; moreover, none of them has been proven to be an alternative to surgery in halting the disease process.

Our recommendation to reserve HE for patients with profound neurological deficits in order to avoid iatrogenic harm to them needs to be considered in relative terms in any patient who is severely disabled by seizures or side effects of the AEDs. In those patients, the consequences of HE should be weighted against the possibly deleterious consequences of frequent or even continuous intractable seizures.

Prospects of therapeutic research in RE

Previous experience

Up to now, case reports or uncontrolled patient series have provided the available evidence on surgical and immunological treatments of RE. This limitation is due to the small number of RE patients. Insofar, RE shares the typical problems of other orphan diseases. From the existing reports, it is obvious that HE offers a good prospect of achieving seizure freedom, albeit at the price of induction of severe deficits. On the other hand, it is unclear if immunotherapies are able to modify the long-term outcome of RE patients. An

immunotherapy may prolong the period of high seizure frequency and deterioration without finally preventing the loss of function. Thus, the patient will at last be offered radical surgery, that is, the very treatment that had been withheld at the earlier stage in view of the preserved language and motor functions. However if this is found for one immunotherapeutic regimen, another one may still be beneficial. At present, it is far from clear how to rank the immunotherapies described above in RE.

Recommended future therapeutic research

From these and other considerations, the following general principles of future therapeutic research are outlined:

- (i) Any kind of valid therapeutic report should inform about the long-term outcome of the patients treated, i.e. to cover a follow-up of at least 1 or 2 years. (A rapid beneficial effect, even if short-lived, of a treatment with a known mode of action may provide hints toward the pathogenesis of the disease studied. A report on such a short term-observation does, however, not provide meaningful therapeutic information in a chronically progressive disorder.)
- (ii) Given the variability of the RE course, only studies on patient cohorts (not on single cases) will provide relevant new information.
- (iii) For any such study of a treated patient cohort, a control group will be necessary. As a minimum requirement, an adequate historical control group should be retrospectively analyzed. (Comparisons with historical non-operated and non-immunotreated controls might turn out to be particularly meaningful since placebo-controlled studies are no longer conceivable in RE. Also, there are unlikely to be long-term courses of untreated patients in the future—whereas this was not so rare in the past when the disease and its treatment options were less well known than today.) The ideal type of study would be a controlled clinical trial in a prospective, randomized, multi-centre manner. Even though such a trial is conceivable, it will be logistically difficult to perform.
- (iv) Which patients should be included? Because of the non-uniform activity of the pathological process during the disease course and in different age groups, only patients at similar disease stages and of similar ages should be compared.
- (v) What kind of interventions should be compared in such a trial? A design with a placebo control group in this progressive condition will be unacceptable for ethical committees and potential study candidates in the light of existing reports on therapies that may prevent disability. Therefore, comparative trials will be the only realistic option. As to the type of the interventions to be compared, a prospective randomised comparison of surgical and immunotherapeutical treatments is

unacceptable in the light of the considerations above. According to the therapeutic pathway presented here (Fig. 1), there will be only very rarely, if ever, a situation in which HE and long-term immunotreatment will appear to be equally beneficial for the patient. This leaves the prospective, randomized long-term comparison of currently accepted treatments to each other or of a 'new' therapy to one of the accepted regimens as the most desired future type of therapeutic trial in RE. It should include patients during early rather than late periods of RE. More than 1 year or so after the onset of the acute stage, many patients will have entered the residual stage and will therefore either be eligible for HE or will no longer benefit from immunotherapy or both. A double-blind design may not be feasible in such a long-term study, especially if a drug like IVIG is tested.

- (vi) What are appropriate efficacy parameters? The most relevant and best assessable clinical measures are regularly assessed degree of hemiparesis and seizure frequency. Periodic testing of neuropsychological functions or health-related quality of life may be further options. A study with regular follow-up visits and pre-defined exit criteria (e.g. a certain increase in the degree of hemiparesis) may be most adequate. This would permit a timely consideration of HE or change of immunotherapy according to the therapeutic pathway given above if a trial drug fails to stop the chronic progression.
- (vii) An additional MRI surrogate measure of the destructive disease process assessing the degree of hemiatrophy over time during the study course might further enhance the validity of such a study.

References

- Andermann F, editor. Chronic encephalitis and epilepsy. Rasmussen's syndrome. Boston: Butterworth-Heinemann; 1991.
- Andermann F. Rasmussen syndrome and movement disorder. *Mov Disord* 2002; 17: 437–8.
- Andermann F, Lugaresi E, Dvorkin GS, Montagna P. Malignant migraine: the syndrome of prolonged classical migraine, epilepsy partialis continua, and repeated strokes: a clinically characteristic disorder probably due to mitochondrial encephalopathy. *Funct Neurol* 1986; 1: 481–6.
- Andermann E, Oguni H, Guttmann RD, Osterland CK, Antel JP, Eeg-Olofsson O, et al. Genetic aspects of chronic encephalitis. In: Andermann F, editor. Chronic encephalitis and epilepsy. Boston: Butterworth-Heinemann; 1991. p. 167–75.
- Andrews PI, Dichter MA, Berkovic SF, Newton MR, McNamara JO. Plasmapheresis in Rasmussen's encephalitis. *Neurology* 1996; 46: 242–6.
- Andrews PI, McNamara JO, Lewis DV. Clinical and electroencephalographic correlates in Rasmussen's encephalitis. *Epilepsia* 1997; 38: 189–94.
- Antel JP, Rasmussen T. Rasmussen's encephalitis and the new hat. *Neurology* 1996; 46: 9–11.
- Antozzi C. Immunotherapy [abstract]. *Epilepsia* 2004; 45 Suppl 3: 20.
- Antozzi C, Franceschetti S, Filippini G, Barbiroli B, Savoirdo M, Fiacchino F, et al. Epilepsia partialis continua associated with NADH-coenzyme Q reductase deficiency. *J Neurol Sci* 1995; 129: 152–61.
- Antozzi C, Granata T, Aurisano N, Zardini G, Confalonieri P, Airaghi G, et al. Long-term selective IgG immuno-adsorption improves Rasmussen's encephalitis. *Neurology* 1998; 51: 302–5.
- Antunes NL, Boulad F, Prasad V, Rosenblum M, Lis E, Souweidane M. Rolandic encephalopathy and epilepsy partialis continua following bone marrow transplant. *Bone Marrow Transplant* 2000; 26: 917–9.
- Arzimanoglou A, Aicardi J. The epilepsy of Sturge-Weber syndrome: clinical features and treatment in 23 patients. *Acta Neurol Scand Suppl* 1992; 140: 18–22.
- Asher DM, Gajdusek DC. Virologic studies in chronic encephalitis. In: Andermann F, editor. Chronic encephalitis and epilepsy. Rasmussen's syndrome. Boston: Butterworth-Heinemann; 1991. p. 147–58.
- Atkins MR, Terrell W, Hulette CM. Rasmussen's syndrome: a study of potential viral etiology. *Clin Neuropathol* 1995; 14: 7–12.
- Banati RB, Goerres GW, Myers R, Gunn RN, Turkheimer FE, Kreutzberg GW, et al. [¹¹C](R)-PK11195 positron emission tomography imaging of activated microglia *in vivo* in Rasmussen's encephalitis. *Neurology* 1999; 53: 2199–203.
- Bancaud J, Bonis A, Talairach J, Bordas-Ferrer M, Buser P. Syndrome de Kojewnikow et acces somato-moteurs (etude clinique, E.E.G. E.M.G. et S.E.E.G.). *Encephale* 1970; 59: 391–438.
- Bancaud J, Bonis A, Trottier S, Talairach J, Dulac O. L'epilepsie partielle continue: syndrome et maladie. *Rev Neurol Paris* 1982; 138: 803–14.
- Baranzini SE, Laxer K, Saketkhoo R, Elkins MK, Parent JM, Mantegazza R, et al. Analysis of antibody gene rearrangement, usage, and specificity in chronic focal encephalitis. *Neurology* 2002; 58: 709–16.
- Barnett M, Prosser J, Sutton I, Halmagyi GM, Davies L, Harper C, et al. Paraneoplastic brain stem encephalitis in a woman with anti-Ma2 antibody. *J Neurol Neurosurg Psychiatry* 2001; 70: 222–5.
- Bartolomei F, Gavaret M, Dhiver C, Gastaut JA, Gambarelli D, Figarella-Branger D, et al. Isolated, chronic, epilepsy partialis continua in an HIV-infected patient. *Arch Neurol* 1999; 56: 111–4.
- Bhatjiwale MG, Polkey C, Cox TC, Dean A, Deasy N. Rasmussen's encephalitis: neuroimaging findings in 21 patients with a closer look at the basal ganglia. *Pediatr Neurosurg* 1998; 29: 142–8.
- Bien CG, Schulze-Bonhage A, Deckert M, Urbach H, Helmstaedter C, Grunwald T, et al. Limbic encephalitis not associated with neoplasm as a cause of temporal lobe epilepsy. *Neurology* 2000; 55: 1823–8.
- Bien CG, Bauer J, Deckwerth TL, Wiendl H, Deckert M, Wiestler OD, et al. Destruction of neurons by cytotoxic T cells: a new pathogenic mechanism in Rasmussen's encephalitis. *Ann Neurol* 2002a; 51: 311–8.
- Bien CG, Elger CE, Wiendl H. Advances in pathogenic concepts and therapeutic agents in Rasmussen's encephalitis. *Expert Opin Investig Drugs* 2002b; 11: 981–9.
- Bien CG, Urbach H, Deckert M, Schramm J, Wiestler OD, Lassmann H, et al. Diagnosis and staging of Rasmussen's encephalitis by serial MRI and histopathology. *Neurology* 2002c; 58: 250–7.
- Bien CG, Widman G, Urbach H, Sassen R, Kuczaty S, Wiestler OD, et al. The natural history of Rasmussen's encephalitis. *Brain* 2002d; 125: 1751–9.
- Bien CG, Gleissner U, Sassen R, Widman G, Urbach H, Elger CE. An open study of tacrolimus therapy in Rasmussen's encephalitis. *Neurology* 2004; 62: 2106–9.
- Boatman D, Freeman J, Vining E, Pulsifer M, Miglioretti D, Minahan R, et al. Language recovery after left hemispherectomy in children with late-onset seizures. *Ann Neurol* 1999; 46: 579–86.
- Booss J, Esiri MM. Viral encephalitis in humans. Washington DC: ASM Press; 2003.
- Botez MI, Brossard L. Epilepsia partialis continua with well-delimited subcortical frontal tumor. *Epilepsia* 1974; 15: 39–43.
- Branch C, Milner B, Rasmussen T. Intracarotid sodium amyltal for the lateralization of cerebral speech dominance. Observations in 123 patients. *J Neurosurg* 1964; 21: 399–405.
- Buchhalter, J., Burchiel, K., Bettis, D., D'Agostino, A. Ictal SPECT as a guide to early surgery for Rasmussen's encephalopathy [abstract]. *Epilepsia* 1994; 35 Suppl 8: 50.
- Burke GJ, Fifer SA, Yoder J. Early detection of Rasmussen's syndrome by brain SPECT imaging. *Clin Nucl Med* 1992; 17: 730–1.
- Caplan R, Curtiss S, Chugani HT, Vinters HV. Pediatric Rasmussen encephalitis: social communication, language, PET and pathology before and after hemispherectomy. *Brain Cogn* 1996; 32: 45–66.

- Carson BS, Javedan SP, Freeman JM, Vining EP, Zuckerberg AL, Lauer JA, et al. Hemispherectomy: a hemidecortication approach and review of 52 cases. *J Neurosurg* 1996; 84: 903–11.
- Casciola-Rosen L, Andrade F, Ulanet D, Wong WB, Rosen A. Cleavage by Granzyme B is strongly predictive of autoantigen status: implications for initiation of autoimmunity. *J Exp Med* 1999; 190: 815–26.
- Cendes F, Andermann F, Silver K, Arnold DL. Imaging of axonal damage *in vivo* in Rasmussen's syndrome. *Brain* 1995; 118: 753–8.
- Chiapparini L, Granata T, Farina L, Ciceri E, Erbetta A, Ragona F, et al. Diagnostic imaging in 13 cases of Rasmussen's encephalitis: can early MRI suggest the diagnosis? *Neuroradiology* 2003; 45: 171–83.
- Chinchilla D, Dulac O, Robain O, Plouin P, Ponsot G, Pinel JF, et al. Reappraisal of Rasmussen's syndrome with special emphasis on treatment with high doses of steroids. *J Neurol Neurosurg Psychiatry* 1994; 57: 1325–33.
- Cockerell OC, Rothwell J, Thompson PD, Marsden CD, Shorvon SD. Clinical and physiological features of epilepsy partialis continua. Cases ascertained in the UK. *Brain* 1996; 119: 393–407.
- Curatolo P, Verdecchia M, Bombardieri R. Tuberos sclerosis complex: a review of neurological aspects. *Eur J Paediatr Neurol* 2002; 6: 15–23.
- Delalande O, Bulteau C. Hemispherotomy for Rasmussen's encephalitis: technique and long-term results. Oral presentation at the 2nd International Symposium on Rasmussen's encephalitis, Montreal, December 2002.
- Delalande O, Pinard JM, Basevat C, Gauthe M, Plouin P, Dulac O. Hemispherotomy: A new procedure for central disconnection [abstract]. *Epilepsia* 1992; 33: 99–100.
- Derry C, Dale RC, Thom M, Miller DH, Giovannoni G. Unihemispheric cerebral vasculitis mimicking Rasmussen's encephalitis. *Neurology* 2002; 58: 327–8.
- Desbiens R, Berkovic SF, Dubeau F, Andermann F, Laxer KD, Harvey S, et al. Life-threatening focal status epilepticus due to occult cortical dysplasia. *Arch Neurol* 1993; 50: 695–700.
- DeToledo JC, Smith DB. Partially successful treatment of Rasmussen's encephalitis with zidovudine: symptomatic improvement followed by involvement of the contralateral hemisphere. *Epilepsia* 1994; 35: 352–5.
- Devlin AM, Cross JH, Harkness W, Chong WK, Harding B, Vargha-Khadem F, et al. Clinical outcomes of hemispherectomy for epilepsy in childhood and adolescence. *Brain* 2003; 126: 556–66.
- Dubeau F, Sherwin AL. Pharmacologic principles in the management of chronic focal encephalitis. In: Andermann F, editor. *Chronic encephalitis and epilepsy: Rasmussen's syndrome*. Boston: Butterworth-Heinemann; 1991. p. 179–92.
- Dulac O, Robain O, Chiron C, Plouin P, Pinel JF, Vigeveno F, et al. High-dose steroid treatment of epilepsy partialis continua due to chronic focal encephalitis. In: Andermann F, editor. *Chronic encephalitis and epilepsy. Rasmussen's syndrome*. Boston: Butterworth-Heinemann; 1991. p. 193–9.
- Duprez TP, Grandin C, Gadisieux JF, De Volder A, Thauvoy C, Keyeux A, et al. MR-monitored remitting-relapsing pattern of cortical involvement in Rasmussen syndrome: comparative evaluation of serial MR and PET/SPECT features. *J Comput Assist Tomogr* 1997; 21: 900–4.
- English R, Soper N, Shepstone BJ, Hockaday JM, Stores G. Five patients with Rasmussen's syndrome investigated by single-photon-emission computed tomography. *Nucl Med Commun* 1989; 10: 5–14.
- Farrell MA, Cheng L, Cornford ME, Grody WW, Vinters HV. Cytomegalovirus and Rasmussen's encephalitis [letter; comment]. *Lancet* 1991; 337: 1551–2.
- Farrell MA, Droogan O, Secor DL, Poukens V, Quinn B, Vinters HV. Chronic encephalitis associated with epilepsy: immunohistochemical and ultrastructural studies. *Acta Neuropathol Berl* 1995; 89: 313–21.
- Ferrari S, Monaco S, Morbin M, Zanusso G, Bertolasi L, Cerini R, et al. HIV-associated PML presenting as epilepsy partialis continua. *J Neurol Sci* 1998; 161: 180–4.
- Fiorella DJ, Provenzale JM, Edward CR, Crain BJ, Al Sugair A. 18F-fluorodeoxyglucose positron emission tomography and MR imaging findings in Rasmussen encephalitis. *Am J Neuroradiol* 2001; 22: 1291–9.
- Firlik KS, Adelson PD, Hamilton RL. Coexistence of a ganglioglioma and Rasmussen's encephalitis. *Pediatr Neurosurg* 1999; 30: 278–82.
- Frasconi C, Spreafico R, Franceschetti S, Aurisano N, Bernasconi P, Garbelli R, et al. Labeling of rat neurons by anti-GluR3 IgG from patients with Rasmussen encephalitis. *Neurology* 2001; 57: 324–7.
- Freeman JL, Coleman LT, Smith LJ, Shield LK. Hemiconvulsion-hemiplegia-epilepsy syndrome: characteristic early magnetic resonance imaging findings. *J Child Neurol* 2002; 17: 10–6.
- Fried I, Spencer DD, Spencer SS. The anatomy of epileptic auras: focal pathology and surgical outcome. *J Neurosurg* 1995; 83: 60–6.
- Friedman H, Ch'ien L, Parham D. Virus in brain of child with hemiplegia, hemiconvulsions, and epilepsy. *Lancet* 1977; 2: 666.
- Frucht S. Dystonia, athetosis, and epilepsy partialis continua in a patient with late-onset Rasmussen's encephalitis. *Mov Disord* 2002; 17: 609–12.
- Fusco L, Vigeveno F. Reversible operculum syndrome caused by progressive epilepsy partialis continua in a child with left hemimegalencephaly. *J Neurol Neurosurg Psychiatry* 1991; 54: 556–8.
- Gahring LC, Carlson NG, Meyer EL, Rogers SW. Cutting edge: Granzyme B proteolysis of a neuronal glutamate receptor generates an autoantigen and is modulated by glycosylation. *J Immunol* 2001; 166: 1433–8.
- Gambardella A, Pasquinelli G, Cittadella R, Bono F, Oliveri RL, Valentino P, et al. Kufs' disease presenting as late-onset epilepsy partialis continua. *Neurology* 1998; 51: 1180–2.
- Geller E, Faerber EN, Legido A, Melvin JJ, Hunter JV, Wang Z, et al. Rasmussen encephalitis: complementary role of multitechnique neuroimaging. *Am J Neuroradiol* 1998; 19: 445–9.
- Gilden DH, Lipton H. Cytomegalovirus and Rasmussen's encephalitis [letter; comment]. *Lancet* 1991; 337: 239.
- Granata T, Fusco L, Gobbi G, Freri E, Ragona F, Broggi G, et al. Experience with immunomodulatory treatments in Rasmussen's encephalitis. *Neurology* 2003a; 61: 1807–10.
- Granata T, Gobbi G, Spreafico R, Vigeveno F, Capovilla G, Ragona F, et al. Rasmussen's encephalitis: early characteristics allow diagnosis. *Neurology* 2003b; 60: 422–5.
- Graus F, Ribalta T, Campo E, Monforte R, Urbano A, Rozman C. Immunohistochemical analysis of the immune reaction in the nervous system in paraneoplastic encephalomyelitis. *Neurology* 1990; 40: 219–22.
- Gray F, Serdaru M, Baron H, Daumas Duport C, Laron P, Sauron B, et al. Chronic localised encephalitis (Rasmussen's) in an adult with epilepsy partialis continua. *J Neurol Neurosurg Psychiatry* 1987; 50: 747–51.
- Grenier Y, Antel JP, Osterland CK. Immunologic studies in chronic encephalitis of Rasmussen. In: Andermann F, editor. *Chronic encephalitis and epilepsy. Rasmussen's syndrome*. Boston: Butterworth-Heinemann; 1991. p. 125–34.
- Hajak M, Antonini A, Leenders KL, Wieser HG. Epilepsia partialis continua studied by PET. *Epilepsy Res* 1991; 9: 44–8.
- Hart Y, Andermann F. Rasmussen syndrome. In: Oxbury JM, Polkey CE, Duchowny M, editors. *Intractable focal epilepsy*. London: WB Saunders; 2000. p. 233–48.
- Hart Y, Andermann F, Fish D, Cortez M, Hwang P, Silver K, et al. The medical treatment of chronic encephalitis and epilepsy. In: Wolf P, editor. *Epileptic seizures and syndromes*. London: John Libbey, 1994a. p. 399–404.
- Hart YM, Cortez M, Andermann F, Hwang P, Fish DR, Dulac O, et al. Medical treatment of Rasmussen's syndrome (chronic encephalitis and epilepsy): effect of high-dose steroids or immunoglobulins in 19 patients. *Neurology* 1994b; 44: 1030–6.
- Hart YM, Andermann F, Fish DR, Dubeau F, Robitaille Y, Rasmussen T, et al. Chronic encephalitis and epilepsy in adults and adolescents: a variant of Rasmussen's syndrome? *Neurology* 1997; 48: 418–24.
- Hart YM, Andermann F, Robitaille Y, Laxer KD, Rasmussen T, Davis R. Double pathology in Rasmussen's syndrome: a window on the etiology? *Neurology* 1998; 50: 731–5.
- Hartley LM, Gordon I, Harkness W, Harding B, Neville BG, Cross JH. Correlation of SPECT with pathology and seizure outcome in children undergoing epilepsy surgery. *Dev Med Child Neurol* 2002; 44: 676–80.

- He XP, Patel M, Whitney KD, Janumpalli S, Tenner A, McNamara JO. Glutamate receptor GluR3 antibodies and death of cortical cells. *Neuron* 1998; 20: 153–63.
- Hennessy MJ, Koutroumanidis M, Dean AF, Jarosz J, Elwes RD, Binnie CD, et al. Chronic encephalitis and temporal lobe epilepsy: A variant of Rasmussen's syndrome? *Neurology* 2001; 56: 678–81.
- Hertz-Pannier L, Chiron C, Jambaque I, Renaux-Kieffer V, Van de Moortele PF, Delalande O, et al. Late plasticity for language in a child's non-dominant hemisphere: a pre- and post-surgery fMRI study. *Brain* 2002; 125: 361–72.
- Hess DC, Sethi KD. Epilepsia partialis continua in multiple sclerosis. *Int J Neurosci* 1990; 50: 109–11.
- Honavar M, Janota I, Polkey CE. Rasmussen's encephalitis in surgery for epilepsy. *Dev Med Child Neurol* 1992; 34: 3–14.
- Hwang PA, Gilday DL, Spire J-P, Hosny H, Chugani HT, Garnett ES, et al. Chronic focal encephalitis of Rasmussen: Functional neuroimaging studies with positron emission tomography and single-photon emission tomography scanning. In: Andermann F, editor. *Chronic encephalitis and epilepsy. Rasmussen's syndrome*. Boston: Butterworth-Heinemann; 1991. p. 61–72.
- Ishii M, Sugita K, Niimi H. A case of epilepsia partialis continua associated with hemimegalencephaly. *Psychiatry Clin Neurosci* 1995; 49: S302–3.
- Jay V, Becker LE, Otsubo H, Cortez M, Hwang P, Hoffman HJ, et al. Chronic encephalitis and epilepsy (Rasmussen's encephalitis): detection of cytomegalovirus and herpes simplex virus 1 by the polymerase chain reaction and *in situ* hybridization. *Neurology* 1995; 45: 108–17.
- Jonas R, Nguyen S, Hu B, Asarnow RF, LoPresti C, Curtiss S, et al. Cerebral hemispherectomy: Hospital course, seizure, developmental, language, and motor outcomes. *Neurology* 2004; 62: 1712–21.
- Juul-Jensen P, Denny-Brown D. Epilepsia partialis continua. *Arch Neurol* 1966; 15: 563–78.
- Kaiboriboon K, Cortese C, Hogan RE. Magnetic resonance and positron emission tomography changes during the clinical progression of Rasmussen encephalitis. *J Neuroimaging* 2000; 10: 122–5.
- Karenfort M, Kruse B, Freitag H, Pannek H, Tuxhorn I. Epilepsy surgery outcome in children with focal epilepsy due to tuberous sclerosis complex. *Neuropediatrics* 2002; 33: 255–61.
- Kataoka K, Okuno T, Mikawa H, Hojo H. Cranial computed tomographic and electroencephalographic abnormalities in children with post-hemicontensive hemiplegia. *Eur Neurol* 1988; 28: 279–84.
- Korn-Lubetzki I, Bien CG, Bauer J, Gomori M, Wiendl H, Trajo L, et al. Rasmussen encephalitis with active inflammation and delayed seizures onset. *Neurology* 2004; 62: 984–6.
- Koshewnikow AJ. Eine besondere Form von corticaler Epilepsie. *Neurol Centralbl* 1895; 14: 47–8.
- Kossoff EH, Vining EP, Pillas DJ, Pyzik PL, Avellino AM, Carson BS, et al. Hemispherectomy for intractable unilateral hemispheric epilepsy etiology vs outcome. *Neurology* 2003; 61: 887–90.
- Kramer U, Kahana E, Shorer Z, Ben Zeev B. Outcome of infants with unilateral Sturge-Weber syndrome and early onset seizures. *Dev Med Child Neurol* 2000; 42: 756–9.
- Krauss GL, Campbell ML, Roche KW, Haganir RL, Niedermeyer E. Chronic steroid-responsive encephalitis without autoantibodies to glutamate receptor GluR3. *Neurology* 1996; 46: 247–9.
- Kunz WS. The role of mitochondria in epileptogenesis. *Curr Opin Neurol* 2002; 15: 179–84.
- Lang B, Watson R, Bermudez I, Sattelle D, Jepson J, Vincent A. Antibodies to neuronal alpha7 acetylcholine receptor in patients with Rasmussen's encephalitis [abstract]. *J Neuroimmunol* 2004; 154: 192.
- Larionov S, König R, Urbach H, Sassen R, Elger CE, Bien CG. MRI brain volumetry in Rasmussen encephalitis: The fate of affected and 'unaffected' hemispheres. *Neurology*. In press 2005.
- Larner AJ, Smith SJ, Duncan JS, Howard RS. Late-onset Rasmussen's syndrome with first seizure during pregnancy [letter]. *Eur Neurol* 1995; 35: 172.
- Leach JP, Chadwick DW, Miles JB, Hart IK. Improvement in adult-onset Rasmussen's encephalitis with long-term immunomodulatory therapy. *Neurology* 1999; 52: 738–42.
- Lee JS, Juhasz C, Kaddurah AK, Chugani HT. Patterns of cerebral glucose metabolism in early and late stages of Rasmussen's syndrome. *J Child Neurol* 2001; 16: 798–805.
- Levite M, Hermelin A. Autoimmunity to the glutamate receptor in mice—a model for Rasmussen's encephalitis? *J Autoimmun* 1999; 13: 73–82.
- Levite M, Fleidervish IA, Schwarz A, Pelled D, Futerman AH. Autoantibodies to the Glutamate Receptor Kill Neurons via Activation of the Receptor Ion Channel. *J Autoimmun* 1999; 13: 61–72.
- Li Y, Uccelli A, Laxer KD, Jeong MC, Vinters HV, Tourtellotte WW, et al. Local-clonal expansion of infiltrating T lymphocytes in chronic encephalitis of Rasmussen. *J Immunol* 1997; 158: 1428–37.
- Loddenkemper T, Wyllie E, Lardizabal D, Stanford LD, Bingaman W. Late language transfer in patients with Rasmussen encephalitis. *Epilepsia* 2003; 44: 870–1.
- Lyon G, Ponsot G, Lebon P. Acute measles encephalitis of the delayed type. *Ann Neurol* 1977; 2: 322–7.
- Maeda Y, Oguni H, Saitou Y, Mutoh A, Imai K, Osawa M, et al. Rasmussen syndrome: multifocal spread of inflammation suggested from MRI and PET findings. *Epilepsia* 2003; 44: 1118–21.
- Mantegazza R, Bernasconi P, Baggi F, Spreafico R, Ragona F, Antozzi C, et al. Antibodies against GluR3 peptides are not specific for Rasmussen's encephalitis but are also present in epilepsy patients with severe, early onset disease and intractable seizures. *J Neuroimmunol* 2002; 131: 179–85.
- Matthews PM, Andermann F, Arnold DL. A proton magnetic resonance spectroscopy study of focal epilepsy in humans. *Neurology* 1990; 40: 985–9.
- McClintock WM. Neurologic manifestations of tuberous sclerosis complex. *Curr Neurol Neurosci Rep* 2002; 2: 158–63.
- McLachlan RS, Girvin JP, Blume WT, Reichman H. Rasmussen's chronic encephalitis in adults. *Arch Neurol* 1993; 50: 269–74.
- McLachlan RS, Levin S, Blume WT. Treatment of Rasmussen's syndrome with ganciclovir. *Neurology* 1996; 47: 925–8.
- Morris CA, Dire DJ. Movement disorders as a manifestation of nonketotic hyperglycemia. *J Emerg Med* 1989; 7: 359–64.
- Nabbout R, Dulac O. Epileptic encephalopathies: a brief overview. *J Clin Neurophysiol* 2003; 20: 393–7.
- Nakasu S, Isozumi T, Yamamoto A, Okada K, Takano T, Nakasu Y. Serial magnetic resonance imaging findings of Rasmussen's encephalitis—case report. *Neurol Med Chir Tokyo* 1997; 37: 924–8.
- Nelson KB, Lynch JK. Stroke in newborn infants. *Lancet Neurol* 2004; 3: 150–8.
- Nowakowski GS, Katz A. Epilepsia partialis continua as an atypical presentation of cat scratch disease in a young adult. *Neurology* 2002; 59: 1815–6.
- Ogden JA. Language and memory functions after long recovery periods in left-hemispherectomized subjects. *Neuropsychologia* 1988; 26: 645–59.
- Oguni H, Andermann F, Rasmussen TB. The natural history of the syndrome of chronic encephalitis and epilepsy: a study of the MNI series of forty-eight cases. In: Andermann F, editor. *Chronic encephalitis and epilepsy. Rasmussen's syndrome*. Boston: Butterworth-Heinemann; 1991. p. 7–35.
- Ohtsuka Y, Ohno S, Oka E. Electroclinical characteristics of hemimegalencephaly. *Pediatr Neurol* 1999; 20: 390–3.
- Olivier A. Cortical resection for diagnosis and treatment of seizures due to chronic encephalitis. In: Andermann F, editor. *Chronic encephalitis and epilepsy: Rasmussen's syndrome*. Boston: Butterworth-Heinemann; 1991. p. 205–11.
- Omorokov L. Die Kojewnikoffsche Epilepsie in Sibirien. *Zschr Ges Neurol Psychiat* 1927; 107: 487–96.
- Palcoux JB, Carla H, Tardieu M, Carpentier C, Sebire G, Garcier JM, et al. Plasma exchange in Rasmussen's encephalitis. *Ther Apher* 1997; 1: 79–82.
- Palmer CA, Geyer JD, Keating JM, Gilliam F, Kuzniecky RI, Morawetz RB, et al. Rasmussen's encephalitis with concomitant cortical dysplasia: the role of GluR3. *Epilepsia* 1999; 40: 242–7.

- Pardo CA, Vining EP, Guo L, Skolasky RL, Carson BS, Freeman JM. The pathology of Rasmussen syndrome: stages of cortical involvement and neuropathological studies in 45 hemispherectomies. *Epilepsia* 2004; 45: 516–26.
- Piatt JH Jr, Hwang PA, Armstrong DC, Becker LE, Hoffman HJ. Chronic focal encephalitis (Rasmussen syndrome): six cases. *Epilepsia* 1988; 29: 268–79.
- Power C, Poland SD, Blume WT, Girvin JP, Rice GP. Cytomegalovirus and Rasmussen's encephalitis. *Lancet* 1990; 336: 1282–4.
- Puligheddu M, Giagheddu A, Genugu F, Giagheddu M, Marrosu F. *Epilepsia partialis continua* in cat scratch disease. *Seizure* 2004; 13: 191–5.
- Pulsifer MB, Brandt J, Salorio CF, Vining EP, Carson BS, Freeman JM. The cognitive outcome of hemispherectomy in 71 children. *Epilepsia* 2004; 45: 243–54.
- Rasmussen T. Further observations on the syndrome of chronic encephalitis and epilepsy. *Appl Neurophysiol* 1978; 41: 1–12.
- Rasmussen T. Hemispherectomy for seizures revisited. *Can J Neurol Sci* 1993; 10: 71–8.
- Rasmussen T, Olszewski J, Lloyd-Smith D. Focal seizures due to chronic localized encephalitis. *Neurology* 1958; 8: 435–45.
- Rasmussen T, Andermann F. Update on the syndrome of 'chronic encephalitis' and epilepsy. *Cleveland Clin J Med* 1989; 56 Suppl 2: S181–4.
- Rasmussen M, Sanengen T, Skullerud K, Kvittingen EA, Skjeldal OH. Evidence that Alpers-Huttenlocher syndrome could be a mitochondrial disease. *J Child Neurol* 2000; 15: 473–7.
- Robitaille Y. Neuropathologic aspects of chronic encephalitis. In: Andermann F, editor. *Chronic encephalitis and epilepsy. Rasmussen's syndrome*. Boston: Butterworth-Heinemann; 1991. p. 79–110.
- Rogers SW, Andrews PI, Gahring LC, Whisenand T, Cauley K, Crain B, et al. Autoantibodies to glutamate receptor GluR3 in Rasmussen's encephalitis. *Science* 1994; 265: 648–51.
- Sabharwal RK, Gupta M, Sharma D, Puri V. Juvenile diabetes manifesting as *epilepsia partialis continua*. *J Assoc Physicians India* 1989; 37: 603–4.
- Salih MA, Kabiraj M, Al Jarallah AS, El Desouki M, Othman S, Palkar VA. Hemiconvulsion-hemiplegia-epilepsy syndrome. A clinical, electroencephalographic and neuroradiological study. *Childs Nerv Syst* 1997; 13: 257–63.
- Schramm J, Behrens E, Entzian W. Hemispherical deafferentation: an alternative to functional hemispherectomy. *Neurosurgery* 1995; 36: 509–15.
- Schramm J, Kral T, Clusmann H. Transsylvian keyhole functional hemispherectomy. *Neurosurgery* 2001; 49: 891–900.
- Schuelke M, Bakker M, Stoltenburg G, Sperner J, von Moers A. *Epilepsia partialis continua* associated with a homoplasmic mitochondrial tRNA(Ser(UCN)) mutation. *Ann Neurol* 1998; 44: 700–4.
- Sener RN. Rasmussen's encephalitis: proton MR spectroscopy and diffusion MR findings. *J Neuroradiol* 2000; 27: 179–84.
- Sener RN. Diffusion MRI and spectroscopy in Rasmussen's encephalitis. *Eur Radiol* 2003; 13: 2186–91.
- Shah JR, Juhasz C, Kupsky WJ, Asano E, Sood S, Fain D, et al. Rasmussen encephalitis associated with Parry-Romberg syndrome. *Neurology* 2003; 61: 395–7.
- Shahar E, Kramer U, Nass D, Savitzki D. *Epilepsia partialis continua* associated with widespread gliomatosis cerebri. *Pediatr Neurol* 2002; 27: 392–6.
- Shavit YB, Graus F, Probst A, Rene R, Steck AJ. *Epilepsia partialis continua*: a new manifestation of anti-Hu-associated paraneoplastic encephalomyelitis. *Ann Neurol* 1999; 45: 255–8.
- Shimizu H, Maehara T. Modification of peri-insular hemispherotomy and surgical results. *Neurosurgery* 2000; 47: 367–72.
- Shiozawa Z, Sasaki H, Ozaki Y, Nakanishi T, Huang YP. *Epilepsia partialis continua* following metrizamide cisternography. *Ann Neurol* 1981; 10: 400–1.
- Silver K, Andermann F, Meagher Villemure K. Familial alternating *epilepsia partialis continua* with chronic encephalitis: another variant of Rasmussen syndrome? *Arch Neurol* 1998; 55: 733–6.
- Singh BM, Gupta DR, Stobos RJ. Nonketotic hyperglycemia and *epilepsia partialis continua*. *Arch Neurol* 1973; 29: 187–90.
- Singh BM, Stobos RJ. *Epilepsia partialis continua* associated with nonketotic hyperglycemia: clinical and biochemical profile of 21 patients. *Ann Neurol* 1980; 8: 155–60.
- So N, Gloor P. Electroencephalographic and electrocorticographic findings in chronic encephalitis of the Rasmussen type. In: Andermann F, editor. *Chronic encephalitis and epilepsy. Rasmussen's syndrome*. Boston: Butterworth-Heinemann; 1991. p. 37–45.
- Stark RE, McGregor KK. Follow-up study of a right- and a left-hemispherectomized child: implications for localization and impairment of language in children. *Brain Lang* 1997; 60: 222–42.
- Stark RE, Bleile K, Brandt J, Freeman J, Vining EP. Speech-language outcomes of hemispherectomy in children and young adults. *Brain Lang* 1995; 51: 406–21.
- Tampieri D, Melanson D, Ethier R. Imaging of chronic encephalitis. In: Andermann F, editor. *Chronic encephalitis and epilepsy. Rasmussen's syndrome*. Boston: Butterworth-Heinemann; 1991. p. 47–60.
- Taylor LB. Neuropsychologic assessment of patients with chronic encephalitis. In: Andermann F, editor. *Chronic encephalitis and epilepsy: Rasmussen's syndrome*. Boston: Butterworth-Heinemann; 1991. p. 111–21.
- Telfeian AE, Berqvist C, Danielak C, Simon SL, Duhaime AC. Recovery of language after left hemispherectomy in a sixteen-year-old girl with late-onset seizures. *Pediatr Neurosurg* 2002; 37: 19–21.
- Thom M, Moran NF, Plant GT, Stevens JM, Scaravilli F. Cortical dysplasia with angiodysgenesis and chronic inflammation in multifocal partial epilepsy. *Neurology* 1999; 52: 654–7.
- Thomas JE, Reagan TJ, Klass DW. *Epilepsia partialis continua*. A review of 32 cases. *Arch Neurol* 1977; 34: 266–75.
- Thomas P, Zifkin B, Ghetau G, Delalande O. Persistence of ictal activity after functional hemispherectomy in Rasmussen syndrome. *Neurology* 2003; 60: 140–2.
- Tobias SM, Robitaille Y, Hickey WF, Rhodes CH, Nordgren R, Andermann F. Bilateral Rasmussen encephalitis: post-mortem documentation in a five-year-old. *Epilepsia* 2003; 44: 127–30.
- Topcu M, Turanlı G, Aynaci FM, Yalnizoglu D, Saatci I, Yigit A, et al. Rasmussen encephalitis in childhood. *Childs Nerv Syst* 1999; 15: 395–402.
- Trudeau N, Colozzo P, Sylvestre V, Ska B. Language following functional left hemispherectomy in a bilingual teenager. *Brain Cogn* 2003; 53: 384–8.
- Twyman RE, Gahring LC, Spiess J, Rogers SW. Glutamate receptor antibodies activate a subset of receptors and reveal an agonist binding site. *Neuron* 1995; 14: 755–62.
- Vadlamudi L, Galton CJ, Jeavons SJ, Tannenberg AE, Boyle RS. Rasmussen's syndrome in a 54 year old female: more support for an adult variant. *J Clin Neurosci* 2000; 7: 154–6.
- van Empelen R, Jennekens-Schinkel A, Buskens E, Helders PJ, Van Nieuwenhuizen O. Functional consequences of hemispherectomy. *Brain* 2004; 127: 2071–9.
- Vargha-Khadem F, Isaacs EB, Papaleloudi H, Polkey CE, Wilson J. Development of language in six hemispherectomized patients. *Brain* 1991; 114: 473–95.
- Villani F, Spreafico R, Farina L, Giovagnoli AR, Bernasconi P, Granata T, et al. Positive response to immunomodulatory therapy in an adult patient with Rasmussen's encephalitis. *Neurology* 2001; 56: 248–50.
- Villemure J-G. Hemispherectomy techniques: a critical review. In: Tuxhorn I, Holthausen H, Boenigk H, editors. *Paediatric epilepsy syndromes and their surgical treatment*. London: John Libbey; 1997a. p. 729–38.
- Villemure J-G. Hemispherectomy: Techniques and Complications. In: Wyllie E, editor. *The treatment of epilepsy and practices*. Philadelphia: Lea and Febiger; 1997b. p. 1081–6.
- Villemure J-G. Functional hemispherectomy and peri-insular hemispherotomy in Rasmussen's encephalitis. Oral presentation at the 2nd International Symposium on Rasmussen's encephalitis in Montreal, December 2002.
- Villemure J-G, Mascott CR. Peri-insular hemispherotomy: surgical principles and anatomy. *Neurosurgery* 1995; 37: 975–81.
- Villemure J-G, Andermann F, Rasmussen TB. Hemispherectomy for the treatment of epilepsy due to chronic encephalitis. In: Andermann F, editor.

- Chronic encephalitis and epilepsy: Rasmussen's syndrome. Boston: Butterworth-Heinemann; 1991. p. 235–41.
- Vining EP, Freeman JM, Brandt J, Carson BS, Uematsu S. Progressive unilateral encephalopathy of childhood (Rasmussen's syndrome): a reappraisal. *Epilepsia* 1993; 34: 639–50.
- Vining EP, Freeman JM, Pillas DJ, Uematsu S, Carson BS, Brandt J, et al. Why would you remove half a brain? The outcome of 58 children after hemispherectomy—the Johns Hopkins experience: 1968 to 1996. *Pediatrics* 1997; 100: 163–71.
- Vinjamuri S, Leach JP, Hart IK. Serial perfusion brain tomographic scans detect reversible focal ischaemia in Rasmussen's encephalitis. *Postgrad Med J* 2000; 76: 33–5.
- Vinters HV, Wang R, Wiley CA. Herpesviruses in chronic encephalitis associated with intractable childhood epilepsy. *Hum Pathol* 1993; 24: 871–9.
- Walsh PJ. Treatment of Rasmussen's syndrome with intravenous gammaglobulin. In: Andermann F, editor. *Chronic encephalitis and epilepsy. Rasmussen's syndrome*. Boston: Butterworth-Heinemann; 1991. p. 201–4.
- Walter GF, Renella RR. Epstein-Barr virus in brain and Rasmussen's encephalitis [letter]. *Lancet* 1989; 1: 279–80.
- Watson R, Jiang Y, Bermudez I, Houlihan L, Clover L, McKnight K, et al. Absence of antibodies to glutamate receptor type 3 (GluR3) in Rasmussen encephalitis. *Neurology* 2004; 63: 43–50.
- Whitney KD, McNamara JO. GluR3 autoantibodies destroy neural cells in a complement-dependent manner modulated by complement regulatory proteins. *J Neurosci* 2000; 20: 7307–16.
- Whitney KD, Andrews JM, McNamara JO. Immunoglobulin G and complement immunoreactivity in the cerebral cortex of patients with Rasmussen's encephalitis. *Neurology* 1999; 53: 699–708.
- Wiendl H, Bien CG, Bernasconi P, Fleckenstein B, Elger CE, Dichgans J, et al. GluR3 antibodies: Prevalence in focal epilepsy but no specificity for Rasmussen's encephalitis. *Neurology* 2001; 57: 1511–4.
- Wieser HG, Graf HP, Bernoulli C, Siegfried J. Quantitative analysis of intracerebral recordings in epilepsy partialis continua. *Electroencephalogr Clin Neurophysiol* 1978; 44: 14–22.
- Wilson DC, McGibben D, Hicks EM, Allen IV. Progressive neuronal degeneration of childhood (Alpers syndrome) with hepatic cirrhosis. *Eur J Pediatr* 1993; 152: 260–2.
- Wise MS, Rutledge SL, Kuzniecky RI. Rasmussen syndrome and long-term response to gamma globulin. *Pediatr Neurol* 1996; 14: 149–52.
- Worle H, Kohler B, Schlote W, Winkler P, Bastanier CK. Progressive cerebral degeneration of childhood with liver disease (Alpers Huttenlocher disease) with cytochrome oxidase deficiency presenting with epilepsy partialis continua as the first clinical manifestation. *Clin Neuropathol* 1998; 17: 63–8.
- Wroe SJ, Ellershaw JE, Whittaker JA, Richens A. Focal motor status epilepticus following treatment with azlocillin and cefotaxime. *Med Toxicol* 1987; 2: 233–4.
- Xiong ZQ, Qian W, Suzuki K, McNamara JO. Formation of complement membrane attack complex in mammalian cerebral cortex evokes seizures and neurodegeneration. *J Neurosci* 2003; 23: 955–60.
- Yacubian EM, Marie SK, Valerio RM, Jorge CL, Yamaga L, Buchpiguel CA. Neuroimaging findings in Rasmussen's syndrome. *J Neuroimaging* 1997; 7: 16–22.
- Yang R, Puranam RS, Butler LS, Qian WH, He XP, Moyer M, et al. Autoimmunity to munc-18 in Rasmussen's encephalitis. *Neuron* 2002; 28: 375–83.
- Yoshida T, Tanaka M, Masuda T, Okamoto K, Hirai S. Epilepsia partialis continua with an epileptic focus demonstrated by PET and unique MRI findings: report of a case. *Rinsho Shinkeigaku* 1995; 35: 1021–4.