



Published in final edited form as:

J Nephrol. 2013 ; 26(1): 25–31. doi:10.5301/jn.5000208.

Retention and growth of urinary stones—Insights from imaging

James C. Williams Jr. and James A. McAteer

Indiana University School of Medicine Indianapolis, IN, USA

Abstract

Recent work in nephrolithiasis has benefited from two special kinds of imaging: Endoscopic study of patient kidneys with high quality instruments, and examination of stones with microscopic computed tomography (micro CT). The combination of these has provided new evidence that there is more than one mechanism by which stones are retained in the kidney until they achieve sizes to be clinically relevant. This review describes what is known about the formation of stones on Randall's plaque, the formation of stones on ductal plugs, and ways in which stones may grow in free solution within the calyceal or pelvic spaces. Studies of urolithiasis need to recognize that any group of 'stone formers' likely contains patients who differ fundamentally in which mechanism of stone formation is the primary route for their stones. Separation of patients on the basis of which mechanism (or combination of mechanisms) underlies their disease will be important for advancing research in the area of urolithiasis.

Keywords

urolithiasis; nephrolithiasis

History

Urinary stones have a high prevalence in all countries, and their existence has been known for millennia, but the mechanisms by which these mineral growths come into being are still not well understood. In this review we describe briefly the history of ideas relating to the retention and formation of urinary stones, with emphasis on recent findings and the relevance of newer imaging technologies in helping elucidate the pathologies underlying stones, especially those forming in the kidney.

The formation of urinary stones always requires supersaturation of urine with respect to the mineral being deposited in the stones.[1] However, non-stone formers can produce urine that is supersaturated so that they produce urinary crystals, but these crystals pass harmlessly and do not grow into stones.[2] Because of this, many researchers have reasoned that those who form stones must have a pathology that includes not only supersaturation of the urine but

Correspondence to: James C. Williams, Jr., Ph.D., Department of Anatomy and Cell Biology, Indiana University School of Medicine, 635 Barnhill Drive MS 5055Y, Indianapolis, IN 46202-5120, phone: 317-274-3423, fax: 317-278-2040, jwillia3@anatomy.iupui.edu.

Conflict of interest: none

Human subjects: none

also the retention of small particles within the urinary system so that they can grow into clinically relevant stones.

This was precisely the reasoning that Randall followed when he examined the kidneys of 429 cadavers.[3] He was looking for some mechanism that held the stones in the kidney, so that they could grow to a size that would be manifested clinically. The interstitial plaque that Randall described in this first paper is still called by his name, and we will review evidence that it is indeed an important mechanism by which a nascent stone is retained within the kidney—in some stone patients.

This last point is quite critical: Randall's plaque is a mechanism by which stones are retained in some, but not all, stone formers. One conclusion underlying the present paper is that the search for a *single, universal cause* of urinary stones has been a primary obstacle to progress in this field. That is, in the past many investigators have assumed that all stones must form by a common mechanism. This assumption has constrained thinking, has clouded interpretation of findings, and has hobbled the field.

Randall's 1937 paper shows precisely this mindset, that there is only one, primary cause of urinary stones. The first paragraph of Randall's paper relates the archeological finding of a bladder stone in a 7000-year-old skeleton.[3] The stone was composed of uric acid and struvite/apatite. Such a stone was likely caused by urinary stasis in the bladder and infection, but Randall used this example to lead off his paper, which he concludes with the statement that '*the answer to the secret which has shrouded in mystery the true etiology of primary renal calculus is to be sought in an increasing knowledge of the physiology and pathology of the renal papilla.*' Randall was so focused on finding *one, single cause* for stones that he introduced his paper with a manifestation of stone disease that almost certainly had nothing whatsoever to do with the papillary lesions that he documented so carefully.

If the manifestation of urinary stones is due to multiple different underlying pathologies, then studying patients grouped together simply under the category of 'stone former' will certainly result in confusion. Even specifying patients under the term of 'calcium stone former' can lump together pathologies that appear to be completely separated in primary cause of the disease, as we will review below.

Increased understanding of the diversity of underlying pathologies in stone formers is linked in part to the development of endoscopes that allow visualization of the interior of the kidney in stone formers during surgical procedures.[4, 5] Newer technology for the study of stones removed using these endoscopes has added to the ability to infer the origin of these calculi.[6, 7] Thus it is that we title this paper 'Insights from imaging.'

Stones retained in the kidney on Randall's plaque

As mentioned above, Randall identified a calcification (or plaque) within the renal papillary interstitium that could act as a site for growth of a stone.[3, 8–10] Moreover, the papillary calcification would—at least initially—remain a part of the papillary tissue, so that the growing stone would be retained within the kidney, even when it was very small (Figures 1 and 2). Randall observed stones attached to renal papillae in this manner, and even was able

to obtain some sections of affected papillae to show the calcifications and the way that the papillary epithelium was disrupted over the plaques. Randall reasoned that a urinary stone could not form on the plaque if the papillary epithelium was intact, and thus hypothesized that some event must occur to disrupt the epithelium so that urine could come into contact with the interstitial plaque (Figure 2B).[3]

Recent work has examined in detail the renal papillae of patients who form calcium oxalate stones without any systemic disease, and the basic findings of Randall have been confirmed for these idiopathic stone formers.[4] The plaques that Randall described in his first paper are indeed interstitial, without any mineral being detected within the lumens of tubules.[4, 11] The mildest manifestation of this interstitial calcification appears around the thin limbs of Henle's loop.[11, 12] In this kind of patient, all stones were observed to be adherent to papillae via Randall's plaque,[13] or the stones showed structural evidence via micro-computed tomography (micro CT) of having originally come into being on Randall's plaque, even if they were not observed to be adherent at the time of removal.[14]

Biopsies of adherent stones from such patients have additionally shown that the papillary epithelium is disrupted as Randall described.[15] Moreover, these investigators were able to spectroscopically map the mineral transition from interstitial plaque to stone, showing a fascinating change from tissue apatite to urinary apatite to calcium oxalate. The data suggest an important role of urinary proteins in these transitions,[15] though the precise roles of such proteins are yet to be defined.

Several questions remain to be answered concerning the growth of kidney stones on Randall's plaques. For example, how does the interstitial plaque form? The area density of Randall's plaques on papillae correlates with urine calcium, and inversely with urine volume,[16] suggesting that calcium transport and medullary concentration are involved, but further work remains to be done in this area. One existing hypothesis suggests that the calcium delivered to and absorbed from the medullary thick ascending limb plays an important role in raising the calcium concentration within the thin limbs of the inner medulla,[17] but confirmatory evidence of this mechanism in patients has not yet been reported.

Concerning the loss of overlying epithelium to uncover the plaque for exposure to calyceal urine, no evidence exists on how the event might occur. Randall thought that the ground substance of the connective tissue beneath the papillary epithelium in cadaveric material appeared itself to be damaged in some specimens,[3] but such an observation has not been described in studies of biopsied tissues.[4] Another hypothesis for plaque formation involves pathology of the papillary vasculature,[18] and such pathology could also account for loss of overlying epithelium, but no evidence for such vascular damage has been shown.

It is also not known why sometimes a stone that has grown on Randall's plaque becomes free of its connection to the papilla (Figure 2C).[14] This is certainly true, as studies of passed stones report many with structural evidence of them having formed on Randall's plaque.[19, 20] If a stone that was spontaneously passed shows the morphology of having formed on Randall's plaque,[21] presumably the stone had to have broken free of its

connection to the papilla. Perhaps there is a natural, cellular mechanism by which segments of interstitial plaque can be expelled from the papilla, but at the present time this is completely unknown.

Finally, the actual proportion of stone formers whose stones form solely on Randall's plaque is not known. Such patients have been classed as idiopathic calcium oxalate stone formers—specifically, as those patients forming calcium oxalate stones who show no systemic disease, and who also do not have obvious evidence of genetic hypercalciuria[4, 17]—but no epidemiological data exist to estimate how many calcium stone formers fall into this category. In Randall's work, in which he examined all the autopsied cadavers coming through his institution, 20% of the individuals showed plaques on papillae, and 5.6% showed stones growing on the plaques. This suggests that Randall's plaques may play a role in stone formation in a great many patients, but endoscopic study of patient papillae is likely required to ascertain the true proportion of this type of stone former in the modern population.

Stones retained in the kidney on ductal plugs

In Randall's 1939 paper,[8] he detailed a second kind of papillary lesion—different from interstitial plaques—that could also act as a site for growing a stone that was attached to the renal papilla. This 'papillary lesion type II' was an intratubular calcification that sometimes showed mineral growing onto its distal part that extended out into the calyceal urine. Randall described all of these ductal plugs as being composed of calcium phosphate, and he saw some ductal plugs that did not extend into the urine, but that formed an 'intrarenal calculus,' being entirely contained within the papillary tissue.

This kind of ductal plug has now been described using endoscopic observation and biopsied tissue as occurring in a number of specific kinds of pathologies that all result in renal stones. [17] Randall had hypothesized that ductal plugging requires the person to be in a 'hyperexcretory' state,[9] and the pathologies described so far fit this adjective. For example, persons with cystinuria excrete large quantities of cystine, and these patients form intratubular plugs of cystine and apatite.[22] Hyperparathyroidism and distal renal tubular acidosis both result in urine conditions that favor precipitation of calcium phosphate, and both of these kinds of patients can have massive amounts of plugging of papillary collecting ducts with apatite.[23, 24] Patients with primary hyperoxaluria show tubules plugged with calcium oxalate,[17] and patients with bowel disease or bowel surgery show similar trends, though some of these have tubule plugs of apatite.[4, 25, 26] Brushite stone disease, though its fundamental 'hyperexcretory' etiology is poorly understood, also results in ductal plugging.[27]

In at least some of these patients with mineral deposition in tubule lumens, evidence has been found for the growth of calyceal stones on mineral at the ends of ductal plugs (Figure 3). Thus, this is at least a potential mechanism for the retention of small stones in the kidney while they grow into sizes large enough to be clinically relevant.

Importantly, these examples show more than just another mechanism of stone retention; these examples also show that calcium stones can occur with a papillary pathology that differs dramatically from what is seen with the Randall's plaque-bearing, idiopathic calcium oxalate stone formers. Patients with ductal plugging have obstruction in the collecting ducts, something which is *not* seen in the those patients who have only interstitial plaque.[4] This obstruction is likely part of the cause of cortical pathology that has been seen in at least some forms of stone diseases with ductal plugging.[24, 27] The lack of such tubular obstruction could explain why idiopathic stone formers with only interstitial Randall's plaque showed no renal pathology outside of the presence of plaque.[4]

These differences in underlying pathologies of calcium stone formers mean that if a group of patients is defined only by the term 'calcium stone former,' the ways that stones form among such patients could differ considerably. Patients with only Randall's plaque are likely to be affected by potential treatments for stones in ways that are different from patients with disorders that result in ductal plugging. That is, study of calcium stone formers without separating them by underlying pathology could easily result in a confounding of results because of the differences present within such a classification. However, since endoscopic visualization of renal papillae is a normal part of the assessment and treatment of many stone formers, it is possible to identify calcium stone formers by their papillary pathology so that studies could be done with stone formers classified by papillary appearance, which may be a better system than classification by stone composition alone.

Although this section of the paper has emphasized ductal plugs as a means for retaining stones within the kidney, it must also be said that these hyperexcretory conditions tend to also produce large quantities of stone material that show no evidence of ever having been attached to tissue.[28] Thus, while these kinds of stone diseases do form ductal plugs, and at least some calyceal stones have been verified to be growing on ductal plugs (such as shown in Figure 3) it does not appear that all kidney stones need to form attached to papillary tissue. Possible explanations of how this can happen are explored next.

Stones retained in the kidney by other mechanisms—hypotheses

In the first part of this paper, the rationale was presented that stones normally do not form in the kidney because crystals and crystal aggregates are passed more quickly than they can grow to a size large enough to be lodged within the kidney. This section will address the ways that this balance might be disrupted, so that stones could grow to significant size even without any fastening mechanism to hold them inside the kidney. This mechanism has been referred to as 'free solution crystallization'[28] (Figure 4).

One condition for rapid growth of a stone in free solution would be a hyperexcretory state, so that a large amount of mineral is delivered into the urine so as to produce a supersaturated state that favors rapid crystallization.[29] Additionally, the growth of mineral bodies is accelerated if crystals also aggregate with one another, as has been described in stone formers,[30] so conditions that favor aggregation would be important. Finally, growth of stones in the renal calyx or pelvis would be aided by a low rate of fluid flow in these spaces.

It is the last of these conditions that we know the least about. Flow in the human calyceal-pelvic system is little studied. Schulz et al. summarized all of the work done in this field, and the published reports existing by 1987 were remarkably diverse in their descriptions of 'normal' peristaltic action in the renal calyces and pelvis.[31] The authors also reported their own results of x-ray videography of a series of subjects that included stone formers. They describe a variety of normal and apparently pathologic patterns of contraction and flow in the renal system, and they propose that abnormality in fluid flow in the renal calyceal-pelvic system may contribute to some stone diseases.[31, 32] As far as we can tell, no more work has been done in this area since 1987. It may be that stone formers tend to have abnormal flow in the urinary spaces of the kidney, but confirmation of the work of Schulz et al. has not appeared.

However, urine flow in the rodent kidney is under active study. The nature of normal flow has been described, pacemaker cells for peristalsis have been identified, and knock-out models have revealed important genes for normal urinary flow.[33, 34] The rodent kidney is much simpler than the multi-papillary human kidney, but perhaps the studies with rodents can help focus direction of human studies. Human studies would undoubtedly benefit from technology that would allow the visualization of urinary dynamics *in vivo* in a manner that does not involve ionizing radiation, as traditional x-ray fluoroscopic studies on peristalsis involves substantial exposure of patients to radiation.[35]

So, it is possible that abnormal flow of urine in the kidney could promote the formation of stone by a 'free solution' mechanism, but further study of normal and abnormal urine flow remains to be done. Additionally, this subject is not totally unrelated to the formation of stones that are in some way attached to renal tissue. If a stone forms attached to the renal papilla—either by growth on Randall's plaque or by growth on a ductal plug—the presence of that stone is likely to, itself, *alter urine flow within the calyx*. Moreover, if such a stone gets free of its papillary attachment after it has grown too large to leave the kidney, it can lodge in the pelvis, and disrupt normal urine flow there. In this way, it is possible that the formation of one stone by an attachment mechanism (Randall's plaque or ductal plug) could reduce or restrict urine flow so as to favor the formation of other stones in free solution—but this, too, has been little studied.

Conclusions

Recent study of stone formers using endoscopy and biopsy, combined with study of removed stones with micro CT, has shown that there is more than one mechanism by which stones are retained in the kidney so that they can grow to clinically relevant size. Some kinds of stone formers make stones that grow on Randall's plaques, an interstitial form of papillary calcification that does not involve the deposition of mineral in tubule lumens. Other kinds of stone formers produce mineral that lodges in the papillary collecting ducts, and these ductal plugs can also support the growth of stones that are attached to the papilla. These two mechanisms of stone retention are not mutually exclusive, as some patients who form stones on ductal plugs could also form stones on Randall's plaques, but there are certainly stone formers who have only one of these mechanisms and not the other. Finally, it is certainly true that some stones in some kinds of stone patients must form in a manner that does not

involve attachment to the renal tissue; it seems likely that additional imaging studies in patients to determine how stones can be retained without attachment to renal tissue need to be done.

Acknowledgments

This work was funded by NIH R01 DK59933 and P01 DK56788. We are privileged to work with many investigators who have provided the intellectual impetus for this paper, and we would like to especially thank Drs. Andrew Evan, James Lingeman, Fredric Coe, Allen Rodgers, Saeed Khan, and Dik Kok for helpful discussion as we worked on these ideas.

References

1. Robertson WG, Peacock M, Nordin BE. Activity products in stone-forming and non-stone-forming urine. *Clinical Science*. 1968; 34(3):579–594. [PubMed: 5666884]
2. Daudon M, Hennequin C, Boujelben G, Lacour B, Jungers P. Serial crystalluria determination and the risk of recurrence in calcium stone formers. *Kidney Int*. 2005; 67:1934–1943. [PubMed: 15840041]
3. Randall A. The origin and growth of renal calculi. *Annals of Surgery*. 1937; 105(6):1009–1027. [PubMed: 17856988]
4. Evan AP, Lingeman JE, Coe FL, Parks JH, Bledsoe SB, Shao Y, Sommer AJ, Paterson RF, Kuo RL, Grynepas M. Randall's plaque of patients with nephrolithiasis begins in basement membranes of thin loops of Henle. *J Clin Invest*. 2003; 111(5):607–616. [PubMed: 12618515]
5. Humphreys MR, Miller NL, Williams JC Jr, Evan AP, Munch LC, Lingeman JE. A New World Revealed: Early Experience With Digital Ureterscopy. *J Urol*. 2008; 179(3):970–975. [PubMed: 18207196]
6. Williams JC Jr, Matlaga BR, Kim SC, Jackson ME, Sommer AJ, McAteer JA, Lingeman JE, Evan AP. Calcium oxalate calculi found attached to the renal papilla: Preliminary evidence for early mechanisms in stone formation. *J Endourol*. 2006; 20(11):885–890. [PubMed: 17144856]
7. Williams JC Jr, McAteer JA, Evan AP, Lingeman JE. Micro-computed tomography for analysis of urinary calculi. *Urol Res*. 2010; 38:477–484. [PubMed: 20967434]
8. Randall A. The etiology of primary renal calculus. VII Congress of the International Society of Urology. 1939; 1939:186–261.
9. Randall A. The etiology of primary renal calculus. *International Abstract of Surgery*. 1940; 71(3): 209–240.
10. Randall A. Papillary pathology as a precursor of primary renal calculus. *J Urol*. 1940; 44:580–589.
11. Evan AP, Coe FL, Rittling SR, Bledsoe SB, Shao Y, Lingeman JE, Worcester EM. Apatite plaque particles in inner medulla of kidneys of calcium oxalate stone formers: Osteopontin localization. *Kidney Int*. 2005; 68:145–154. [PubMed: 15954903]
12. Evan AP, Lingeman J, Coe FL, Worcester E. Randall's plaque: Pathogenesis and role in calcium oxalate nephrolithiasis. *Kidney Int*. 2006; 69:1313–1318. [PubMed: 16614720]
13. Miller NL, Gillen DL, Williams JC Jr, Evan AP, Bledsoe SB, Coe FL, Worcester EM, Matlaga BR, Munch LC, Lingeman JE. A formal test of the hypothesis that idiopathic calcium oxalate stones grow on Randall's plaque. *BJU International*. 2009; 103:966–971. [PubMed: 19021625]
14. Miller NL, Williams JC, Evan AP, Bledsoe SB, Coe FL, Worcester EM, Munch LC, Handa SE, Lingeman JE. In idiopathic calcium oxalate stone-formers, unattached stones show evidence of having originated as attached stones on Randall's plaque. *BJU International*. 2010; 105(2):242–245. [PubMed: 19549258]
15. Evan AP, Coe FL, Lingeman JE, Shao Y, Sommer AJ, Bledsoe SB, Anderson JC, Worcester EM. Mechanism of formation of human calcium oxalate renal stones on Randall's plaque. *Anat Rec*. 2007; 290(10):1315–1323.
16. Kuo RL, Lingeman JE, Evan AP, Paterson RF, Parks JH, Bledsoe SB, Munch LC, Coe FL. Urine calcium and volume predict coverage of renal papilla by Randall's plaque. *Kidney Int*. 2003; 64(6):2150–2154. [PubMed: 14633137]

17. Coe FL, Evan AP, Lingeman JE, Worcester EM. Plaque and deposits in nine human stone diseases. *Urol Res.* 2010; 38(4):239–247. [PubMed: 20625890]
18. Stoller ML, Meng MV, Abrahams HM, Kane JP. The primary stone event: A new hypothesis involving a vascular etiology. *J Urol.* 2004; 171(5):1920–1924. [PubMed: 15076312]
19. Cifuentes Delatte L, Miñón-Cifuentes JL, Medina JA. Papillary stones: calcified renal tubules in Randall's plaques. *J Urol.* 1985; 133(3):490–494. [PubMed: 3974005]
20. Cifuentes Delatte L, Miñón Cifuentes J, Medina JA. New studies on papillary calculi. *J Urol.* 1987; 137(5):1024–1029. [PubMed: 3573168]
21. Daudon, M., Traxer, O., Jungers, P., Bazin, D. Stone morphology suggestive of Randall's plaque. In: Evan, AP, Lingeman, JE., Williams, JC., Jr, editors. *Renal Stone Disease*. Vol. 900. Melville, NY: American Institute of Physics; 2007. p. 26–34.
22. Evan AP, Coe FL, Lingeman JE, Shao Y, Matlaga BR, Kim SC, Bledsoe SB, Sommer AJ, Grynepas M, Phillips CL, et al. Renal crystal deposits and histopathology in patients with cystine stones. *Kidney Int.* 2006; 69(12):2227–2235. [PubMed: 16710357]
23. Evan AP, Lingeman JE, Coe FL, Miller NL, Bledsoe SB, Sommer AJ, Williams JC Jr, Shao Y, Worcester EM. Histopathology and surgical anatomy of patients with primary hyperparathyroidism and calcium phosphate stones. *Kidney Int.* 2008; 74:223–229. [PubMed: 18449170]
24. Evan AP, Lingeman J, Coe F, Shao Y, Miller N, Matlaga B, Phillips C, Sommer A, Worcester E. Renal histopathology of stone-forming patients with distal renal tubular acidosis. *Kidney Int.* 2007; 71(8):795–801. [PubMed: 17264873]
25. Evan AP, Lingeman JE, Coe FL, Bledsoe SB, Sommer AJ, Williams JC Jr, Krambeck AE, Worcester EM. Intra-tubular deposits, urine and stone composition are divergent in patients with ileostomy. *Kidney Int.* 2009; 76:1081–1088. [PubMed: 19710630]
26. Evan AP, Lingeman JE, Worcester EM, Bledsoe SB, Sommer AJ, Williams JC Jr, Krambeck AE, Phillips CL, Coe FL. Renal histopathology and crystal deposits in patients with small bowel resection and calcium oxalate stone disease. *Kidney Int.* 2010; 78(3):310–317. [PubMed: 20428098]
27. Evan AP, Lingeman JE, Coe FL, Shao Y, Parks JH, Bledsoe SB, Phillips CL, Bonsib S, Worcester EM, Sommer AJ, et al. Crystal-associated nephropathy in patients with brushite nephrolithiasis. *Kidney Int.* 2005; 67:576–591. [PubMed: 15673305]
28. Coe FL, Evan AP, Worcester EM, Lingeman JE. Three pathways for human kidney stone formation. *Urol Res.* 2010; 38(3):147–160. [PubMed: 20411383]
29. Robertson WG. Kidney models of calcium oxalate stone formation. *Nephron Physiol.* 2004; 98(2):p21–30. [PubMed: 15499211]
30. Robertson WG, Peacock M, Nordin BE. Calcium crystalluria in recurrent renal-stone formers. *Lancet.* 1969; 294(7610):21–24.
31. Schulz E, Hengst E, Brundig P, Haerting R, Pirlich W, Gunther H. Disturbed urinary transport in the pelvi-calyceal system in calcium-oxalate stone patients. *Urol Res.* 1987; 15:109–113. [PubMed: 3590428]
32. Schulz E. Studies on the Influence of the Flow Field in the Pelvi-Calyceal System (Pcs) on the Formation of Urinary Calculi. *Urol Res.* 1987; 15(5):281–286. [PubMed: 3686757]
33. Lang RJ. Role of hyperpolarization-activated cation channels in pyeloureteric peristalsis. *Kidney Int.* 2010; 77(6):483–485. [PubMed: 20186160]
34. Lang RJ, Tonta MA, Zoltkowski BZ, Meeker WF, Wendt I, Parkington HC. Pyeloureteric peristalsis: role of atypical smooth muscle cells and interstitial cells of Cajal-like cells as pacemakers. *The Journal of Physiology.* 2006; 576(3):695–705. [PubMed: 16945969]
35. Hernanz-Schulman M, Goske MJ, Bercha IH, Strauss KJ. Pause and Pulse: Ten Steps That Help Manage Radiation Dose During Pediatric Fluoroscopy. *American Journal of Roentgenology.* 2011; 197(2):475–481. [PubMed: 21785097]

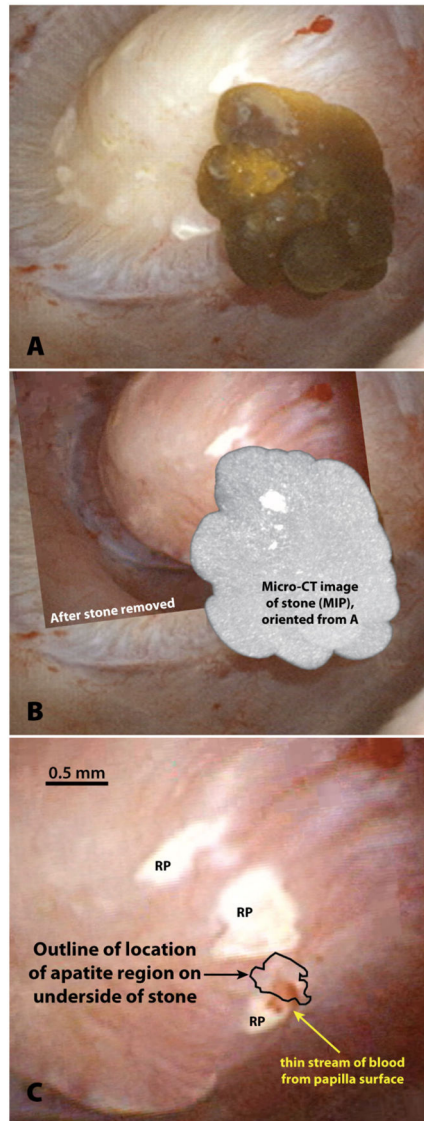


Figure 1. Example of stone growing on Randall's plaque. **A.** Endoscopic view of attached stone on papilla. Papilla is normal in appearance with the exception of the presence of Randall's plaque (RP in panel C). **B.** Combination of endoscopic images before and after stone removal with micro CT image of the removed stone, showing by maximum-intensity projection (MIP) the presence of Randall's plaque that was on the underside of the stone. **C.** Location of plaque that came away with the stone (with resultant bleeding) relative to the plaque remaining on the papilla after stone was removed. [Figure from reference 7, used by permission.]

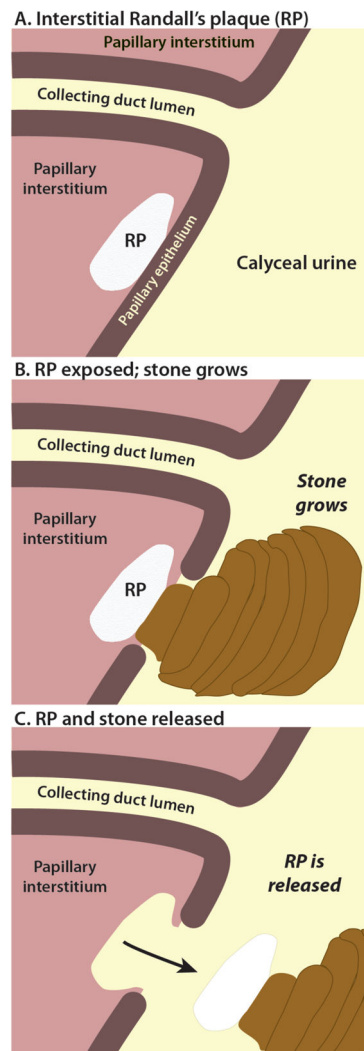


Figure 2. Concept of stone growing on Randall's plaque (RP). **A.** The plaque appears in the interstitial tissue within the renal papilla, with no crystals present in any tubular lumens.^[12] The plaque is composed of calcium phosphate in the mineral form of apatite. **B.** Papillary epithelium is lost, and the plaque is uncovered so that its surface is bathed with urine in the renal calyx. The resulting calcium oxalate stone may grow only very slowly, and can remain small for an extended period of time, as the plaque keeps the stone from flowing out with the urine, and the insolubility of the calcium oxalate makes the stone quite stable with time. The layers in the schematic represent hypothetical growth periods for the stone, periods which could be separated by weeks or even months. **C.** Some stones that are formed on Randall's plaques are released from the papilla in which they formed, by a process that is not known (see text).

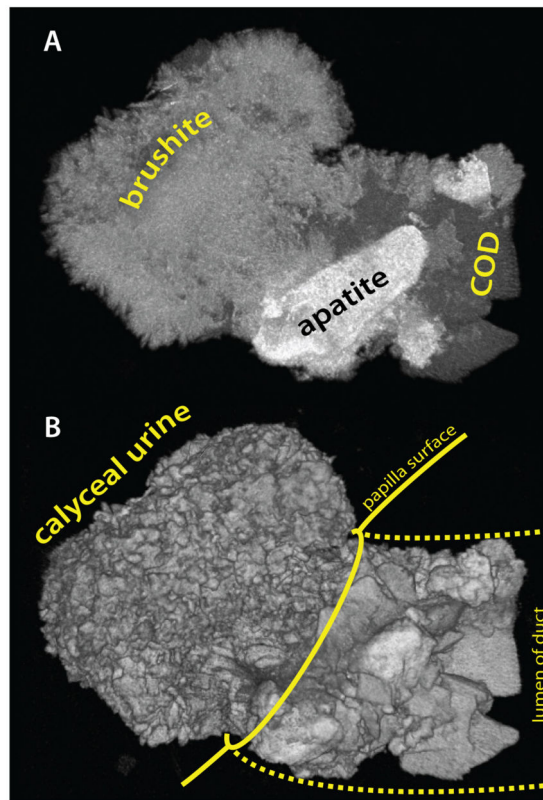


Figure 3. Small stone (about 1.5 mm long) which formed from a ductal plug. **A.** Maximum intensity projection of micro-CT image of stone reveals three different minerals. Calcium phosphate in the form of apatite was present in the ductal lumen (as has been described for brushite stone formers[27]) as was calcium oxalate dihydrate (COD). Brushite—identified by its intermediate x-ray attenuation and radial crystal morphology—formed the bulk of the stone portion that was exposed to the calyceal urine. **B.** Surface rendering showing location of the stone at the mouth of a duct of Bellini. [Figure from reference 7, used by permission.]

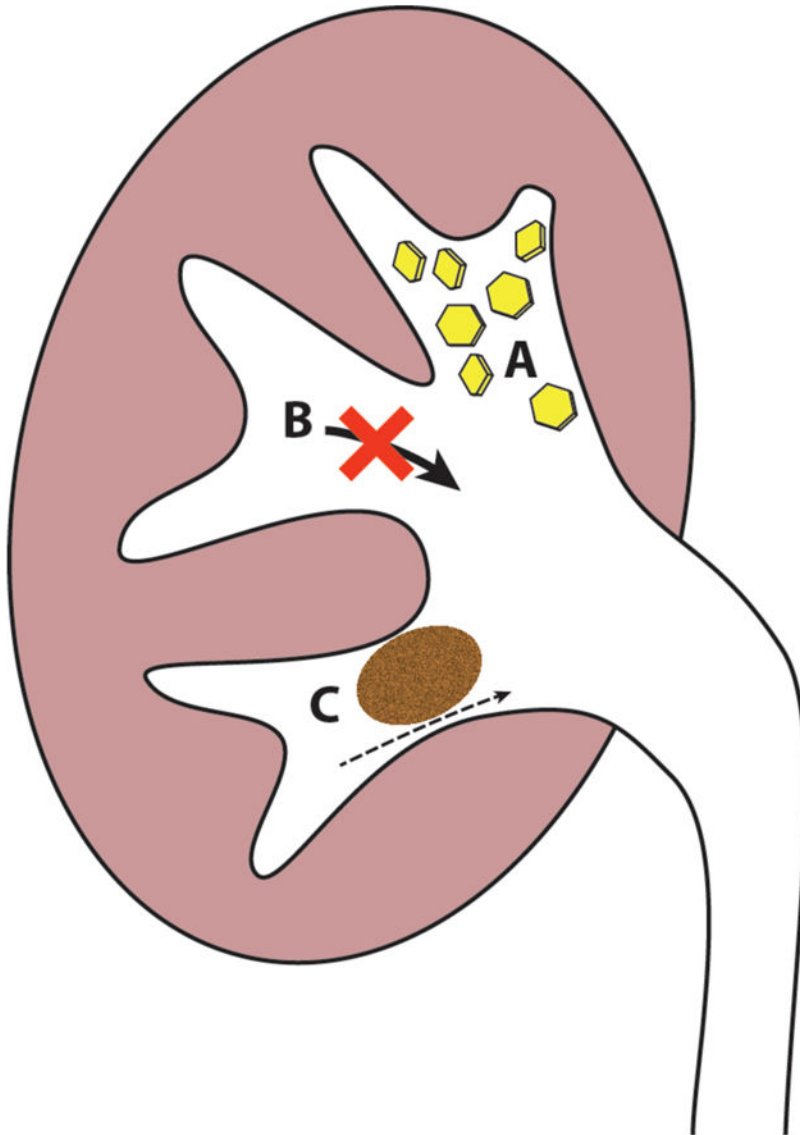


Figure 4.

Hypotheses of how stones might form in free solution within the renal calyx or pelvis, without any attachment to renal tissue. **A.** Rapid formation and aggregation of crystals in the urine would favor the rapid formation of a stone that was too large to leave the renal pelvis. **B.** Dysfunction of calyceal (or pelvic) peristalsis could result in functional stasis of the urine[32], leaving time for formation of a stone in free solution. **C.** The presence of a stone—perhaps one that was initially retained in the kidney by Randall’s plaque or ductal plugging—could disrupt urine flow, resulting in urinary stasis in that region of the kidney, and thus allow for growth of other stones in free solution.