



Debilitating disease in a polyparasitised woylie (*Bettongia penicillata*): A diagnostic investigation

Amy S. Northover^{a,*}, Aileen D. Elliot^a, Sarah Keatley^a, Ziyuan Lim^a, Adriana Botero^a, Amanda Ash^a, Alan J. Lymbery^a, Adrian F. Wayne^b, Stephanie S. Godfrey^c, R.C. Andrew Thompson^a

^a School of Veterinary and Life Sciences, Murdoch University, 90 South Street, Murdoch, Western Australia, 6150, Australia

^b Biodiversity and Conservation Science, Department of Biodiversity, Conservation and Attractions, Brain Street, Manjimup, Western Australia, 6258, Australia

^c Department of Zoology, University of Otago, 362 Leith Street, Dunedin, 9016, New Zealand

ARTICLE INFO

Keywords:

Bettongia penicillata
Fauna translocation
Parastrongylus sp.
Polyparasitism
Sarcocystis sp.
Trypanosoma copemani

ABSTRACT

During monitoring of critically endangered woylie (*Bettongia penicillata*) populations within the south-west of Western Australia, an adult female woylie was euthanased after being found in extremely poor body condition with diffuse alopecia, debilitating skin lesions and severe ectoparasite infestation. *Trypanosoma copemani* G2 and *Sarcocystis* sp. were detected molecularly within tissue samples collected post-mortem. *Potorostrongylus woyliei* and *Parastrongylus* sp. nematodes were present within the stomach and small intestine, respectively. Blood collected ante-mortem revealed the presence of moderate hypomagnesaemia, mild hypokalaemia, mild hyperglobulinaemia and mild hypoalbuminaemia. Diffuse megakaryocytic hypoplasia was evident within the bone marrow. We propose various hypotheses that may explain the presence of severe ectoparasite infection, skin disease and poor body condition in this woylie. Given the potential deleterious effects of parasite infection, the importance of monitoring parasites cannot be over-emphasised.

1. Introduction

Critically endangered woylie (brush-tailed bettong, *Bettongia penicillata*) populations have declined by more than 90% since 1999, and are now restricted to three indigenous wild populations within the south-west of Western Australia (Wayne et al., 2015). In June 2014, as part of the ongoing conservation management of this species, 182 woylies were translocated from Perup Sanctuary, a 423-ha predator-proof enclosure located 50km east of Manjimup (34.2506°S, 116.1425°E), to supplement two natural populations. During monitoring within one of these populations (Walcott, situated 20km north-west of Perup Sanctuary; 34.0592°S, 116.3859°E; Fig. 1) six months after translocation, an adult female resident (i.e. non-translocated) woylie was found in extremely poor body condition with diffuse alopecia and skin lesions predominantly affecting the head, hindlimbs, tail base and tail. Severe ectoparasite infestation was also apparent. Veterinary assessment deemed this animal unsuitable for release and the woylie was euthanased in the field via barbiturate injection while under inhalant anaesthesia. A post-mortem examination was carried out within seven hours of death.

For threatened species such as the woylie, in which only small fragmented wild populations remain, parasites may have a significant impact on population dynamics and host health (Thompson et al., 2010). With regard to woylie population declines, a clear spatio-temporal pattern of decline in population size between 1999 and 2006 was identified, which suggests the potential role of an infectious disease agent (Wayne et al., 2015). Field monitoring carried out immediately prior to, and during this period, found a high prevalence of woylies with moderate to severe alopecia, skin thickening, skin excoriations and scale with a predilection for the head (periocular region and ears) and dorsal tail base/rump region (Wayne et al., 2013). Clinical signs were strikingly similar to those described here. Despite investigation into this ‘skin condition’, a causative disease agent could not be identified. Since then, the focus of investigation has shifted toward the potential role of other disease agents. Trypanosomes have been of particular interest, given the demonstrated pathogenicity of *Trypanosoma copemani* genotype 2 (G2) and the association between *T. copemani* and declining woylie populations (Smith et al., 2008; Botero et al., 2013; Thompson et al., 2014; Godfrey et al., 2018). While previous investigation into the decline has focused on the effects of individual parasite species, the

* Corresponding author. 90 South Street, Murdoch, Western Australia, 6150, Australia.

E-mail address: A.Northover@murdoch.edu.au (A.S. Northover).

<https://doi.org/10.1016/j.ijppaw.2018.07.004>

Received 14 March 2018; Received in revised form 1 June 2018; Accepted 12 July 2018

2213-2244/ © 2018 The Authors. Published by Elsevier Ltd on behalf of Australian Society for Parasitology. This is an open access article under the CC BY-NC-ND license (<http://creativecommons.org/licenses/by-nc-nd/4.0/>).

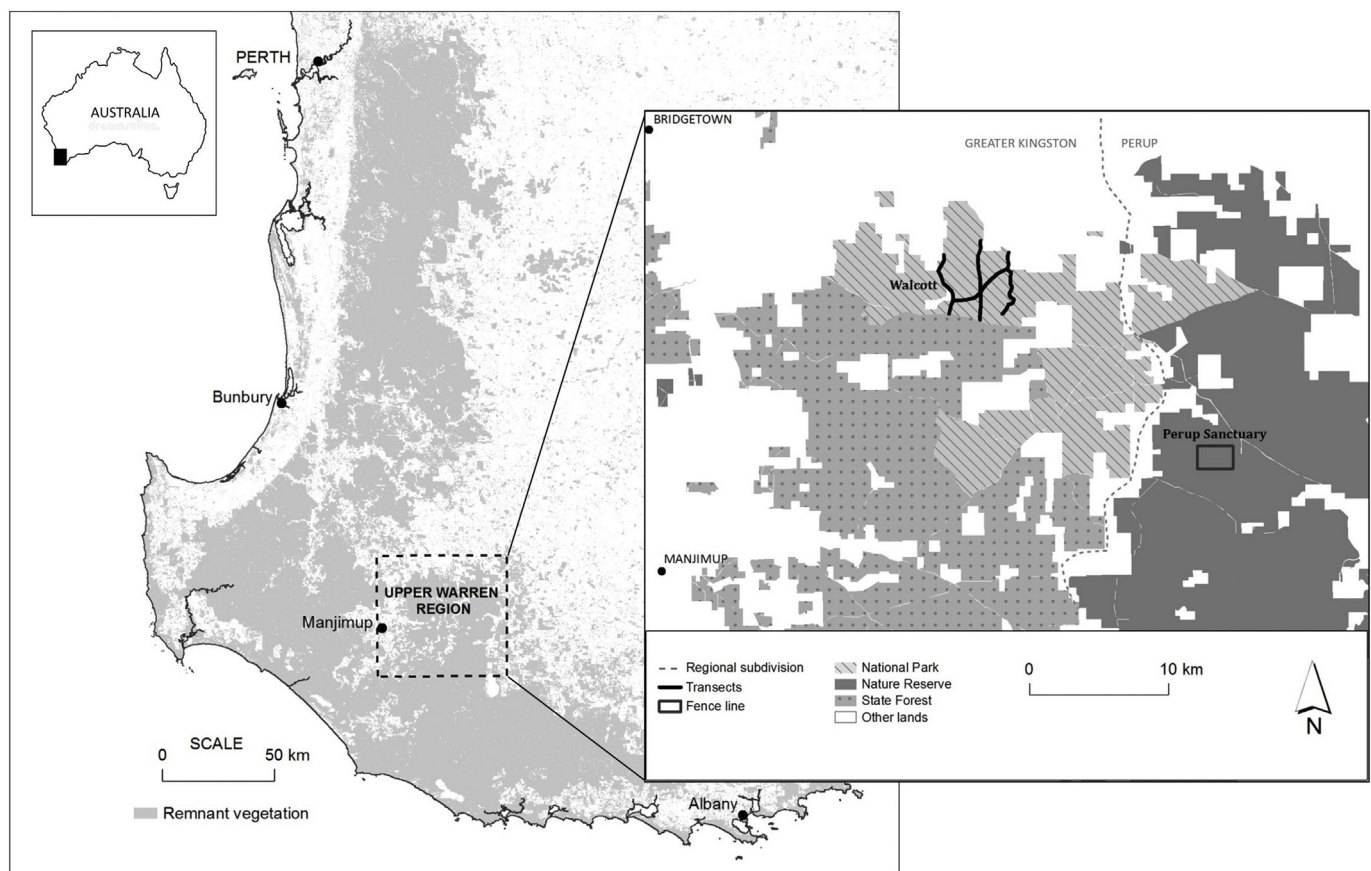


Fig. 1. Map depicting our study sites within the Upper Warren Region. As shown on the right, Walcott is located approximately 20km north-west of Perup Sanctuary.

effect of coinfection has not been evaluated. Here we explore various hypotheses that may explain the presence of severe ectoparasite burdens, debilitating skin disease and poor body condition in this woylie.

2. Materials and methods

2.1. Trapping regime

Trapping was conducted in December 2014. Woylies were captured using Sheffield cage traps (Sheffield Wire Products, Welshpool, WA), which were set along multiple transects (60 traps/night, 200m spacing) at dusk and baited with universal bait (rolled oats, peanut butter and sardines). Newspaper was placed beneath each trap to collect faeces, which were stored chilled prior to examination. Traps were cleared within 3 hours of sunrise.

2.2. Parasitological analysis

2.2.1. Gastrointestinal parasites

Fresh faeces (2.6g) were examined for eggs/oocysts using simple faecal flotation with sodium nitrate (NaNO₃) as described by Northover et al. (2015). The entire gastrointestinal tract was also examined for the presence of endoparasites, and specimens were morphologically identified using keys developed by Mawson (1973), Beveridge and Durette-Desset (2009), and Smales (1997, 2005).

2.2.2. Haemoparasites

Blood was collected ante-mortem (under anaesthesia) from the lateral caudal (tail) vein into EDTA MiniCollect tubes (Greiner Bio-One, Germany) for molecular analyses and stored at -20°C prior to processing. DNA was extracted from 200 μl aliquots of blood using the

QIAamp 96 DNA blood kit (Qiagen, Hilden, Germany), according to the manufacturer's instructions. A nested polymerase chain reaction (PCR) targeting the 18S rDNA gene region was carried out using generic trypanosome primers, as described by Maslov et al. (1996) and McInnes et al. (2009). Positive samples were subsequently screened for the presence of different *Trypanosoma* spp. using clade-specific primers designed by Botero et al. (2013) and McInnes et al. (2011). PCR reactions were performed as outlined in Cooper et al. (2018) with the exception that 2 μl of DNA was added to a 24 μl master mix.

2.2.3. Tissue parasites

Eleven tissue samples (spleen, liver, lung, heart, kidney, brain, oesophagus, tongue, skeletal muscle, anal glands, and bone marrow) were collected post-mortem, extensively washed with phosphate buffered saline, and stored in 100% ethanol for DNA isolation, and fixed in 10% formalin for histopathological analysis. Genomic DNA was obtained using the QIAamp tissue DNA MiniKit (Qiagen, Hilden, Germany) according to the manufacturer's instructions. DNA samples were screened by PCR for the presence of trypanosomes and coccidian parasites. Trypanosome PCR was performed as described above. For the detection of coccidian parasites a fragment of about 800bp from the 18SrDNA gene was amplified using the coccidia generic primers 1L and 3H as described previously (Yang et al., 2001). Sequencing was carried out to confirm parasite genotype/species using the generic coccidian primers in both directions, and using an ABI Prism TM Terminator Cycle Sequencing Kit on an Applied Bio-systems 3730 DNA Analyser (Applied Biosystems, California, USA). Sequences were aligned against reference libraries generated from GenBank®.

2.2.4. Ectoparasites

Prior to euthanasia, the woylie was examined in a systematic

manner (under anaesthesia) and graded subjectively for ectoparasite burden (i.e. 0 = none, 1 = light, 2 = moderate, 3 = heavy) based on the number of ectoparasites visible within both ears, and the number of ectoparasites observed during standardised coat combing. A representative number of ectoparasites were collected and stored in 70% ethanol prior to identification. Ectoparasites collected during ante-mortem and post-mortem examination were identified using keys developed by Roberts (1970), von Kéler (1971), Dunnet and Mardon (1974), and Domrow (1987).

2.3. Histological analysis

Representative pieces of formalin-fixed tissue were cut and embedded in paraffin from which 3 micrometer-thick sections were cut and stained with hematoxylin and eosin (H&E) and examined microscopically, paying particular attention for the presence of parasites, or lesions that may be associated with parasitic infection. Additional periodic acid-Schiff (PAS) histochemistry (reaction from Layton and Bancroft, 2013) and CD3, CD79 and CD20 immunohistochemistry was done on lip mucosa and head skin sections. Immunohistochemistry was undertaken using a polyclonal rabbit anti-human CD3 antibody (A0452 - Agilent Dako), a mouse monoclonal IgG1 CD79a antibody (CM067 - Biocare Medical), and a mouse monoclonal IgG2a CD20 antibody (Clone L26 - Thermo Scientific), using a horse radish peroxidase labelled polymer conjugated with secondary antibodies (Envision Dual Link System - Agilent Dako) according to the manufacturer's instructions.

2.4. Microbiological analysis

Skin from the head and lip, and intestinal tissue was submitted to Vetpath Laboratory Services for fungal culture and aerobic and anaerobic bacterial culture and sensitivity. No viral testing was performed.

2.5. Haematology/biochemistry

Blood was collected (as above) into EDTA and serum MiniCollect tubes (Greiner Bio-One, Germany) and sent to Vetpath Laboratory Services for haematological and biochemical analysis. Three thin peripheral blood smears were also submitted for microscopic examination. Physiological reference intervals for woylies obtained from Species 360 (2014) and Pacioni et al. (2013) were used to interpret the blood results. Reference intervals for magnesium were unavailable from Species 360, thus magnesium results were interpreted using a mean value from the International Species Information System (Teare, 2002).

3. Results

3.1. Gross examination

Veterinary examination in the field determined that this woylie was in extremely poor body condition (subjective body condition score 1.5/5 based on palpation of muscle mass/fat over the hindquarters), although body weight was within the normal adult range (1270 grams). Severe generalised musculoadipose atrophy was confirmed on internal gross examination. There was severe, diffuse alopecia and inflammation affecting the skin of the head and chin, with patchy haemorrhage (top of head, ears and mouth) and crusting (Figs. 2 and 3). The lip margins were severely thickened and inflamed (Figs. 3 and 4). Severe hair loss also affected the hindlimbs (medial thighs, tibia), tail base and tail (Fig. 5) and mild skin thickening/flaking was evident over the flanks and rump. The woylie was subjectively graded with a heavy burden of lice/lice eggs and a moderate burden of fleas, ticks and mites.

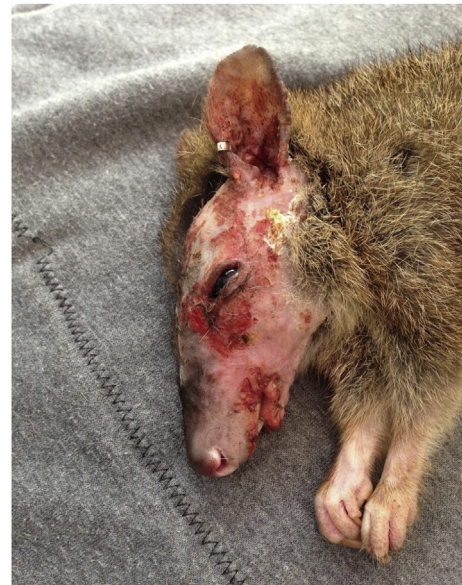

Fig. 2. Lateral view of the head of the woylie, showing severe hair loss and inflammation, patchy haemorrhage (top of head, ears and mouth), and crusting.

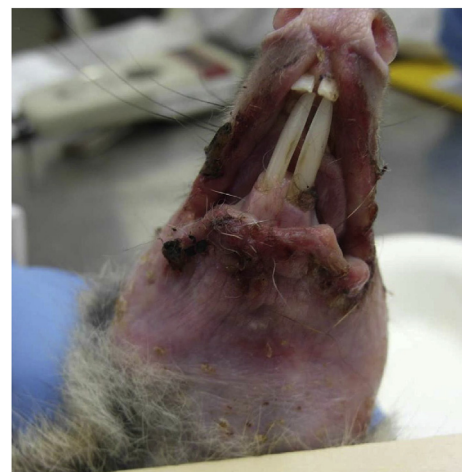

Fig. 3. Ventral view of the head of the woylie, showing severe, diffuse hair loss and inflammation affecting the chin. Excoriated, thickened lip margins are also visible.

3.2. Parasitology

3.2.1. Gastrointestinal parasites

Simple faecal flotation revealed multiple nematode larvae, 31 strongyle eggs ($85 \times 47.5 \mu\text{m}$) and two *Strongyloides*-like eggs ($47.5 \times 32.5 \mu\text{m}$). Within the pyloric region of the stomach, which was grossly unremarkable, 109 *Potorostrongylus woyliei* nematodes were identified. Within the duodenum, 49 *Paraurostrongylus* sp. nematodes were present. The duodenal serosal surface had an abnormal cobblestone appearance and was oedematous. Intestinal contents were mucoid.

3.2.2. Haemoparasites

General PCR screening (performed twice) of blood, and peripheral blood smears were negative for trypanosomes.

3.2.3. Tissue parasites

PCR screening of tissue samples confirmed the presence of trypanosomes within the bone marrow, skeletal muscle, tongue, brain and

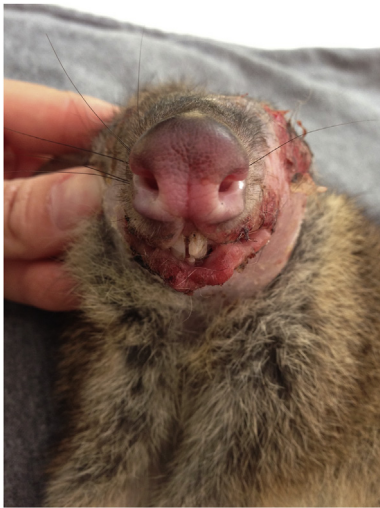

Fig. 4. Frontal view of the head of the woylie, showing thickened and inflamed lip margins.

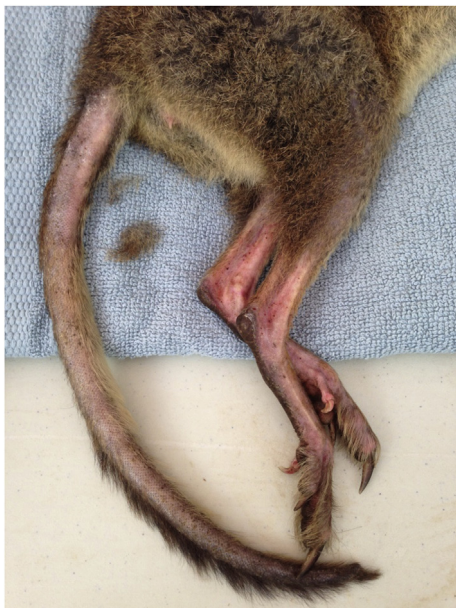

Fig. 5. Lateral view of the woylie, depicting hair loss over the hindlimbs (medial thighs, tibia), tail base and tail (proximal 2 inches of tail have been clipped for blood collection) with scabbing/skin flakes evident over the flanks and rump.

liver. *Trypanosoma copemani* G2 was identified using subsequent DNA sequencing in all of these samples. PCR and DNA sequencing also revealed *Sarcocystis* sp. within the bone marrow, skeletal muscle, tongue, heart, oesophagus and spleen. *Toxoplasma gondii* was not detected.

3.2.4. Ectoparasites

Seven species of ectoparasite were identified; the louse *Paraheterodoxus calcaratus*, ticks (*Ixodes australiensis*, *Ixodes woyliei*, *Amblyomma* sp.), fleas (*Pygiopsylla tunneyi*, *Stephanocircus dasyuri*); and the mite *Haemolaelaps hattanae*.

3.3. Histopathological findings

Histological changes observed within skin and lip lesions were consistent with exudative neutrophilic and eosinophilic dermatitis and cheilitis. No fungi were detected on PAS histochemistry of skin or lip

lesions. Moderate numbers of intraepithelial lymphocytes were found within the lip mucosa and head skin samples and intense cytoplasmic staining was evident on CD3 immunohistochemistry. Mild eosinophilic inflammation within the soft tissues around various organs (oesophagus, skeletal muscle and eye) and within the larynx, liver, bladder and ureter was also present. Diffuse, megakaryocytic hypoplasia was detected in the bone marrow. The duodenal tissue was moderately autolysed, with sloughing of the superficial to mid mucosa. An unidentified larval nematode was detected within the sloughed mucosa. The stomach was histologically normal.

3.4. Microbiological findings

Bacterial culture of head and lip samples resulted in light-moderate pure growth of aerobic coagulase negative *Staphylococcus* sp. No bacterial anaerobes or fungal elements were seen. Small intestinal microbiology resulted in light growth of normal regional flora. *Salmonella* spp. were not detected, nor were bacterial anaerobes or fungal elements.

3.5. Haematological/biochemical findings

Significant biochemical changes included moderate hypomagnesaemia, mild hypokalaemia, mild hyperglobulinaemia and mild hypoalbuminaemia. The sodium/potassium (Na/K) ratio was increased and the albumin/globulin (A/G) ratio was decreased. Glutamate dehydrogenase (GLDH) and beta-hydroxybutyrate (BOHB) could not be interpreted as there are no reference values available for woylies. Using reference intervals from Pacioni et al. (2013), both haematocrit (HCT) and red blood cell (RBC) count were decreased (mild), however as both HCT and RBC count were within normal limits using Species 360 (2014) reference intervals, and haemoglobin levels were normal, these changes were deemed to be clinically insignificant. All other haematological and biochemical results were within normal limits.

4. Discussion

This woylie was infected with multiple parasites and had a particularly high ectoparasite burden compared with other animals encountered during this monitoring program. Due to the complicated interplay of processes by which parasites influence each other, and their host, it is difficult to determine specific parasitic influences on host health and the timeline of events that culminated in disease. Although many of the pathological changes identified in this case (poor body condition, debilitating skin disease, biochemical derangements) may be attributed to parasite infection (see below), this does not definitively establish causation.

Nematodes are usually well-tolerated by macropods, however chronic *Strongyloides* spp. infection may cause progressive anorexia, diarrhoea and weight loss (Winter 1958; Speare et al., 1982); and mortality has been reported in captivity (Vogelnest and Portas, 2008). In this case the stomach was grossly and histopathologically unremarkable, suggesting that *Strongyloides* spp. and *Potrostrongylus woyliei* were non-pathogenic in this woylie.

In contrast, *Paraurostrongylus* sp. nematodes were found within the small intestine and the duodenal surface had an abnormal cobblestone appearance and was oedematous. Trichostrongylid nematodes are reported to have varying degrees of pathogenicity in macropods (Vogelnest and Portas, 2008). Though little is known of the pathogenicity of *Paraurostrongylus* sp. nematodes in woylies, closely related *Aurostrongylus* spp. are not known to be pathogenic in macropods (Spratt et al., 2008). In this case, the gross changes identified within the duodenum, and the relatively high number of *Paraurostrongylus* sp. nematodes (extrapolating from closely related *Aurostrongylus* spp. infecting other macropods; Aussavay et al., 2011; Vendl and Beveridge, 2014), may indicate some degree of pathogenicity associated with

Parastrongylus sp. infection in this woylie; though we lack histopathological evidence to support this (duodenal tissue was autolysed).

The severe, chronic head and lip lesions associated with bacterial and parasitic infection of the skin would undoubtedly have caused discomfort while foraging and eating. Hypomagnesaemia, hypokalaemia, hypoalbuminaemia and severe generalised musculoadipose atrophy may occur with anorexia and subsequent malnutrition (Hand and Novotny, 2002; Mouw et al., 2005). Low protein has been associated with muscle wasting, impaired immunity and poor wound healing (Hand and Novotny, 2002). Gastrointestinal parasites may also promote anorexia (Symons, 1985) or induce other pathophysiological changes (e.g. malabsorption; Koski and Scott, 2001), which may promote malnutrition. As malnutrition may impair immunity and enhance susceptibility to parasite infection, a vicious cycle may ensue (Koski and Scott, 2001; Hand and Novotny, 2002).

The presence of eosinophilic inflammation is suggestive of a systemic allergic reaction, which may be secondary to endoparasite infection, but the mildness of the inflammatory infiltrate suggests that eosinophilia is unlikely to be of clinical significance. Intraepithelial lymphocytes and intense cytoplasmic staining on CD3 immunohistochemistry raise suspicion of epitheliotropic lymphoma (Sheridan and Lefrancois, 2010; Oudejans and van der Valk, 2002). Unfortunately this could not be confirmed, as CD79 and CD20 immunohistochemistry did not work on the woylie positive control tissue (lymph node). Given the compromised state of the mucosal/skin barrier, the presence of intraepithelial lymphocytes may constitute an appropriate immune response to pathogenic microorganisms, rather than malignancy (Sheridan and Lefrancois, 2010).

While *Sarcocystis* spp. have been detected in many native mammalian intermediate hosts, including *S. bettongiae* in the closely related burrowing bettong (*Bettongia lesueur*) (O'Donoghue and Adlard, 2000), infection is thought to be generally non-pathogenic (Ladds, 2009). In other intermediate hosts *Sarcocystis* spp. may cause debilitating disease characterised by anorexia, weight loss, anaemia, weakness, alopecia, abortion and even death (Dubey et al., 2015). In this case, we detected the molecular presence of *Sarcocystis* in various tissues, but did not identify cysts grossly or histologically; thus the pathogenicity of *Sarcocystis* in woylies remains unclear.

Likewise, the significance of the diffuse, megakaryocytic hypoplasia within the bone marrow is uncertain, particularly in the presence of a normal platelet count, and when the sample of bone marrow examined histologically was small and may not have been representative; though we cannot definitively rule out megakaryocyte destruction secondary to immune mediated or infectious disease (Feldman et al., 1988; Lachowicz et al., 2004). A decreased A/G ratio with hyperglobulinaemia is supportive of immune-mediated disease, though a decreased A/G ratio may also be associated with chronic inflammatory disease, infectious disease or neoplasia (Eckersall, 2008).

The skin lesions observed in this woylie may be attributed to ectoparasite infection. Pruritis and self-induced trauma have been documented in other macropods with ectoparasite infestations (Turni and Smales, 2001; Vogelnest and Portas, 2008). The presence of a particularly high number of normally innocuous ectoparasites in this host however, suggests the presence of immunosuppression and/or an underlying disease process. In other species, it has been proposed that trypanosomes may play an immunosuppressive role, enhancing the adverse effects of coinfecting parasites or increasing susceptibility to infection (Griffin et al., 1981; Kaufmann et al., 1992; Sillegem et al., 1994; Goossens et al., 1998; McInnes et al., 2011), although we have no evidence for this in woylies.

Immune function may also be influenced by other disease processes (e.g. neoplasia) or infectious disease agents (e.g. viral infection) that were not investigated here. Likewise, immunosuppression and enhanced vulnerability to parasite infection may occur secondary to stress (Dickens et al., 2009), which may be attributed to factors independent of (e.g. recent translocation, presence of introduced predators, season,

resource availability), or associated with (e.g. malnutrition, coinfection) parasite infection; both of which may promote disease progression within a host and occur concurrently. In a parallel study (Hing et al., 2017), which examined the influence of translocation on stress physiology [measured using faecal cortisol metabolites (FCM)], FCM levels were highest in woylies from Walcott in December 2014, and there was a significant negative relationship between higher FCM levels and lower body condition. Age-related degeneration may also compromise immune function or in the case of advanced tooth wear, may contribute to malnutrition. Tooth wear was not assessed in this case.

5. Conclusion

This case study highlights the complexity of parasite infection and the difficulty of elucidating mechanisms by which parasites influence host health, particularly when the chronology or the nature of host-parasite-immunological associations is unknown. Our results suggest that this woylie was unable to control normally non-pathogenic ectoparasites, which we hypothesise may be associated with immunosuppression and/or an underlying disease process. Importantly, other factors independent of disease (e.g. stress) may have induced immunosuppression and parasite-induced pathology or susceptibility to infection in this host. Given that heavy ectoparasite burdens, poor body condition and skin disease were detected during woylie population declines (Wayne et al., 2013), and an apparent association between *T. copemani* and declining woylie populations also exists, further studies are vital to explore mechanisms by which *T. copemani* G2 may influence coinfecting parasites, immune function and host health.

Declarations of interest

None.

Acknowledgements

This project was primarily funded by the Australian Research Council (LP130101073) and was undertaken in collaboration with the Department of Biodiversity, Conservation and Attractions (DBCA) under DBCA Scientific License's (Regulation 4: written notice of lawful authority; and 17: licence to take fauna for scientific purposes) and in accordance with Murdoch University Animal Ethics Approval (RW2659/14). We have also been supported by grants from the Holsworth Wildlife Research Endowment and the Ecological Society of Australia (HOLSW2015-1-F149), The Royal Zoological Society of New South Wales (Paddy Pallin Grant) and the Australian Wildlife Society. We would like to thank Marika Maxwell, Colin Ward, Chris Vellios, Jamie Flett and Graeme Liddelow from DBCA for their assistance in the field, and our volunteers James Barr, Siobhon Egan, Jade Kelly, Stephanie Hing, Krista Jones, Karen Cavanaugh, Karen Oakley, Bianca Theyer, Mike Bryant and Helen Bryant for their help with sample collection and processing.

References

- Aussavy, M., Bernardin, E., Corrigan, A., Hufschmid, J., Beveridge, I., 2011. Helminth parasite communities in four species of sympatric macropodids in western Victoria. *Aust. Mammal.* 33, 13–20. <https://doi.org/10.1071/AM10020>.
- Beveridge, I., Durette-Desset, M.C., 2009. A new species of the nematode genus *Copemania* (Nematoda: Trichostrongylida), parasitic in the western quoll, *Dasyurus geoffroyi* and the short nosed bandicoot, *Isodon obesulus* from south-western Western Australia. *Record West Aust. Mus.* 25, 345–349.
- Botero, A., Thompson, C.K., Peacock, C., Clode, P.L., Nicholls, P.K., Wayne, A.F., Lymbery, A.J., Thompson, R.C.A., 2013. Trypanosomes genetic diversity, poly-parasitism and the population decline of the critically endangered Australian marsupial, the brush-tailed bettong or woylie (*Bettongia penicillata*). *Int. J. Parasitol.* *Parasites Wildlife* 2, 77–89. <https://doi.org/10.1016/j.ijppaw.2013.03.001>.
- Cooper, C., Keatley, S., Northover, A., Gofton, A.W., Brigg, F., Lymbery, A.J., Pallant, L., Clode, P.L., Thompson, R.C.A., 2018. Next generation sequencing reveals widespread trypanosome diversity and polyparasitism in marsupials from Western Australia. *Int.*

