

UC Davis

Dermatology Online Journal

Title

Infantile bullous pemphigoid with “string of pearls sign”

Permalink

<https://escholarship.org/uc/item/3fw4d2t2>

Journal

Dermatology Online Journal, 23(7)

ISSN

1087-2108

Authors

Raposo, Inês
Machado, Susana
Sampaio, Rita
[et al.](#)

Publication Date

2017-01-01

License

[CC BY-NC-ND 4.0](#)

Peer reviewed

Infantile bullous pemphigoid with “string of pearls sign”

Inês Raposo¹, Susana Machado^{1,2,3}, Rita Sampaio⁴, Manuela Selores^{1,2,3}

Affiliations: ¹Department of Dermatology, Centro Hospitalar do Porto, Portugal ²Instituto de Ciências Biomédicas Abel Salazar, University of Porto, Portugal ³Dermatology Research Unit, Centro Hospitalar do Porto, Portugal ⁴Department of Pathology, Centro Hospitalar do Porto, Portugal

Corresponding Author: Inês Raposo, Serviço de Dermatologia, Centro Hospitalar do Porto, Edifício das Consultas Externas, Ex-CICAP, Rua D. Manuel II, s/n, 4100 Porto, Portugal, E-mail: inesraposovs@gmail.com

Abstract

Bullous pemphigoid (BP) is an immune mediated bullous disease that is manifested by urticarial plaques with superimposed subepidermal blisters and significant pruritus. It is generally found in the elderly, but is rare in the pediatric population. A 5-month-old girl previously diagnosed with hand-foot-mouth disease was examined in our dermatology department owing to vesicles and bullae, initially located to the hands and feet, which progressed with new lesions. Tense vesicles and bullae distributed in an annular string of pearls pattern on the abdomen and facial and cervical regions were noted. Histologic and immunologic findings were consistent with the diagnosis of infantile BP. Disease control was obtained with oral prednisolone and dapsone; the patient was still in clinical remission 6 months after treatment cessation. The differential diagnosis of the clinical presentation of the lesions in our patient is of note, given that this blistering pattern is frequently reported in association with linear IgA bullous dermatosis.

Keywords: bullous pemphigoid; infantile bullous pemphigoid; linear IgA bullous dermatosis; string of pearls sign

Introduction

The differential diagnosis of bullous diseases in the pediatric years is broad, ranging from infectious to genetically determined blistering disorders [1]. Regarding acquired immunobullous diseases, they are extremely rare in newborns, and when present, are usually caused by the transplacental passage of

autoantibodies (pemphigoid gestationis), [1, 2].

BP represents an immune mediated bullous disease that is manifested by urticarial plaques with superimposed subepidermal blisters with significant pruritus. It is generally found in the elderly and is rare in the pediatric population [1]. Among pediatric cases of infantile BP, three variants have been described: infantile (infants, usually lesions with acral location), childhood (children, usually more generalized disease), and localized vulvar disease [1].

Case Synopsis

A 5-month-old girl was observed by her pediatrician because of vesicles and blisters located on the hands, feet, and mouth. She was diagnosed as having hand-foot-mouth disease. Owing to the appearance of new lesions during the following 2 weeks, she was presented to our dermatology department with

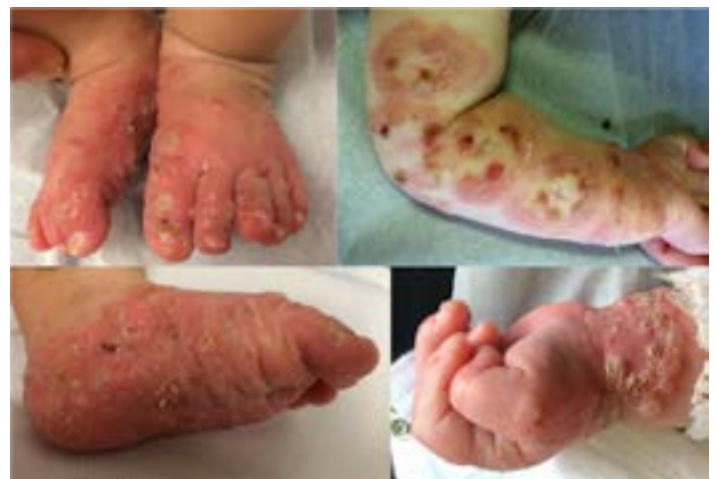

Figure 1. Clinical aspect of the lesions.

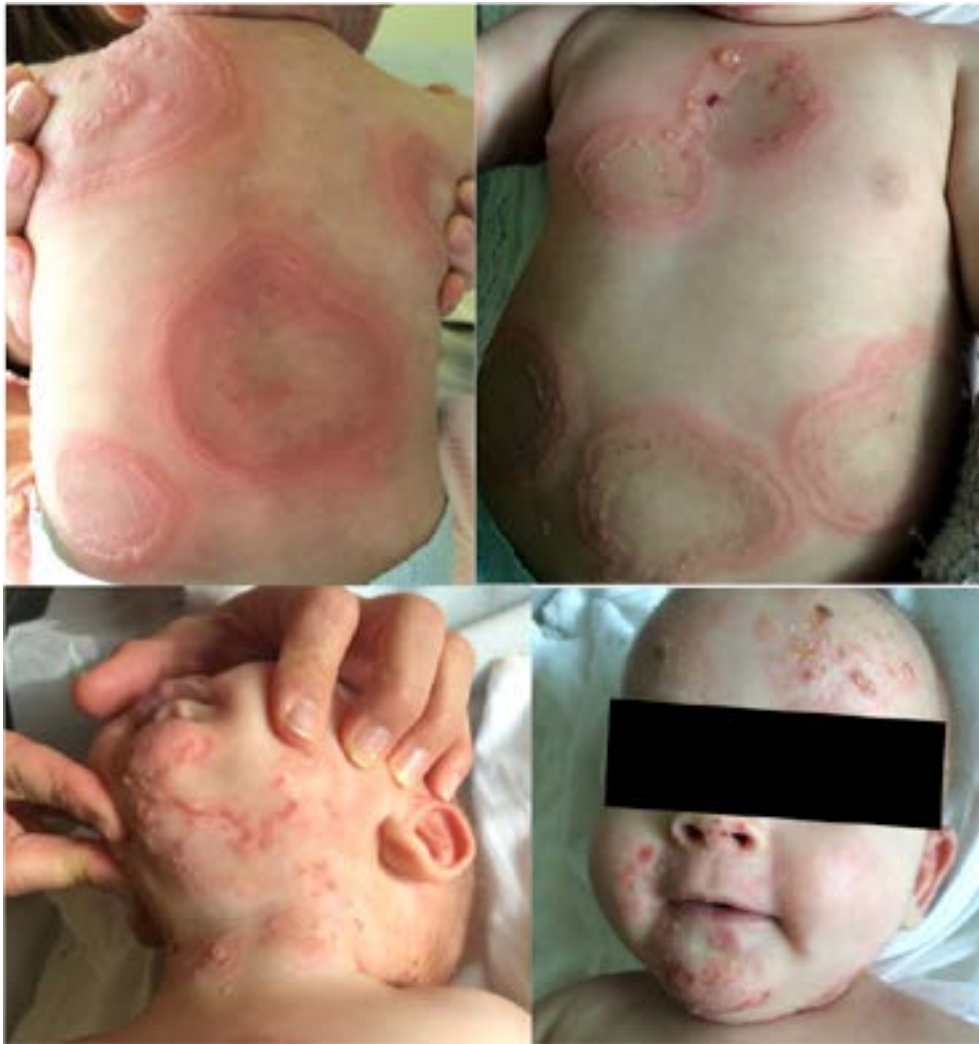

Figure 2. Clinical aspect of the lesions.

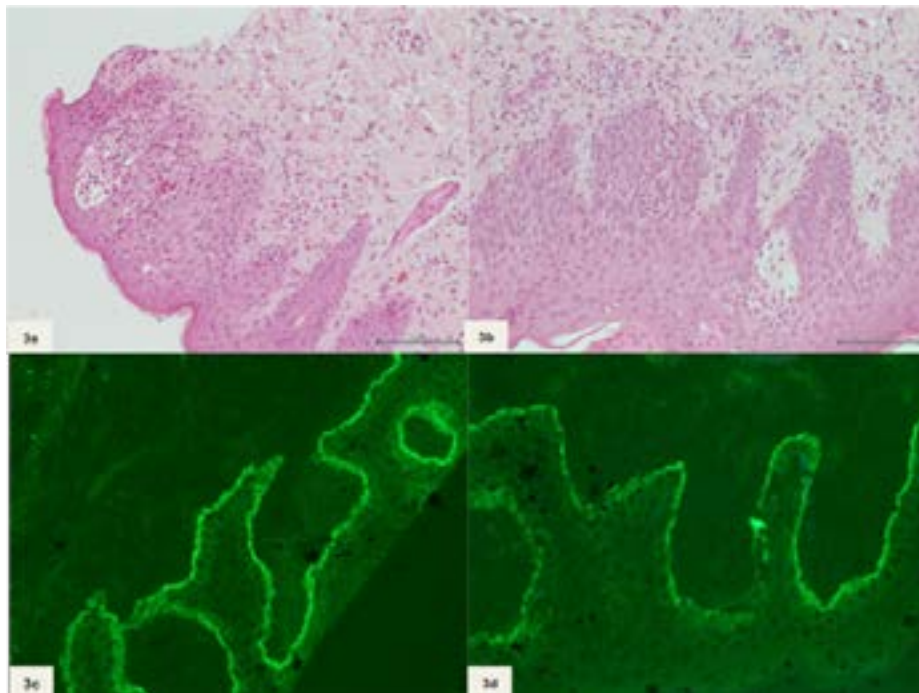


Figure 3. A, B) Hematoxylin-eosin, and C) and D) direct immunofluorescence IgG and C3, respectively. . Magnifications, A) 100x, B) 200x, C) 200x, D) 200x.

several tense vesicles and bullae distributed in an annular string of pearls pattern on the extensor surface of the hands and forearms, feet, abdomen, and facial and cervical regions (Figures 1, 2). Nikolsky sign was negative and no mucosal lesions were present. The patient was irritable, with pruritus and decreased appetite. The patient was the third daughter of a healthy non-consanguineous couple. Delivery was without complications at 39 weeks and the mother did not suffer any dermatologic disease during pregnancy or the post-partum period during this or two previous pregnancies.

Histologic examination showed multiple eosinophils in the superficial dermis and subepidermal clefts (**Figure 3A, B**). Direct immunofluorescence revealed linear staining of IgG (**Figure 3C**) and C3 (**Figure 3D**) along the basement membrane; there was absence of IgA deposits. Anti-BP 180 antibodies were positive in the circulation (124 U/mL). These findings were consistent with the diagnosis of infantile BP.

Treatment was performed initially with topical corticosteroids without improvement. One week later, oral prednisolone (1.5mg/kg/day) was initiated. Dapsone (1mg/kg) was added 10 days after, owing to the persistent activity of the disease. Sustained clinical improvement occurred during the following 4 weeks, after which slow reduction and interruption of therapy was performed during the following month. The patient was still in clinical remission 6 months after treatment cessation.

Case Discussion

The importance of the correct diagnosis of bullous diseases in the pediatric years is a major issue in order to determine prognosis and treatment response. In our case, although the clinical presentation suggested an IgA linear bullous dermatosis (LAD), the absence of IgA deposits on direct immunofluorescence and the finding of IgG linear deposits and BP-180 circulating antibodies led to the diagnosis of BP. LAD or chronic bullous disease of childhood is the most frequent auto-immune bullous disease in the pediatric age group and presents a more prolonged, and sometimes refractory disease, with usual clinical remission before puberty [3]. BP on the other hand, is a rare immune bullous disease in children with a good prognosis and excellent therapeutic response.

Previous clinical reports have been published in which collision of both diseases is observed [4, 5], an association that might be explained by the epitope spreading phenomenon [3]. Regarding the latter phenomenon, an initial inciting inflammatory mechanism exposes cutaneous “immunologic sanctuaries” (namely constituents of the basement membrane) that act additionally as targets to secondary immunologic responses [3].

In fact, two of the major antigens seen in LAD: LAD-1 and LAD-97 represent, respectively, 120-kDa and 97-kDa fragments of one of the major BP antigens: BP-180 [6]. This close immunologic relationship may explain why a primary disease like BP may resemble in some clinical settings LAD. Also the inflammatory infiltrate of BP may expose and modify BP-180 protein and create new immunogenic particles that will be targeted by the adaptive immune system (with the production of specific immunoglobulins, namely IgA) and will be ultimately responsible for the development of LAD. The latter explanation would be an example of the epitope spreading phenomenon between BP and LAD.

In pediatric bullous pemphigoid, acral involvement (hands, feet, head) is reported as the clinical hallmark of the infantile form, whereas the childhood variant usually presents with a more diffuse involvement [1, 7]. No established triggers were found to date for pediatric BP development, namely malignancies or drugs. The reported relation to previous vaccination or infection may simply represent a temporal coincidence given the high number of vaccines received in the first years of life [7]. Hand-foot-mouth disease has been described as a potential trigger of BP exacerbation in adults and may represent a potential activating mechanism of unregulated immunity [8]. Nonetheless, the fact that infantile BP presents in an acral distribution makes it possible for the initial presentation to simply mimic and lead to an incorrect diagnosis of hand-foot-mouth disease [9].

Treatment modalities for bullous pemphigoid consist of topical corticosteroids, systemic corticosteroids, dapsone, sulfapyridine, micofenolate mofetil, and rituximab. Relapse is not common and in general the prognosis is excellent [7]. Although dapsone

is classically viewed as an excellent treatment option in IgA-mediated disease, good therapeutic efficacy has been documented in infantile and adult bullous pemphigoid, especially as an adjuvant treatment modality [7, 10]. This fact, together with the ambiguous clinical presentation of our case, led to the choice of this double-barrelled therapeutic choice.

Conclusion

Delaying appropriate treatment can cause significant morbidity owing to weight loss, dehydration, and failure to thrive. Thus, early diagnosis must be achieved to avoid morbidity [11]. Also, associated symptomatic measures to reduce pruritus and treat co-infection are of the utmost importance [12].

The differential diagnosis of the clinical presentation of the lesions in our patient is of note, given that this blistering pattern is frequently reported in association with LAD [13]. We hereby describe a case of BP with an initial innocent and localized presentation, that generalized and required work up and a more aggressive therapeutic approach.

References

1. Marathe K, Lu J, Morel KD. Bullous diseases: Kids are not just little people. *Clin Dermatol*. 2015;33(6):644-56. Epub 2015/12/22. [PMID: 26686016].
2. Kalkoff E, Fahrig A, Marsch W, Kreft B. Bullous eruption on the back of both hands in a newborn. *Journal der Deutschen Dermatologischen Gesellschaft = J German Soc Dermatol: JDDG*. 2014;12(7):629-31. Epub 2014/05/24. [PMID: 24854504].
3. Fortuna G, Marinkovich MP. Linear immunoglobulin A bullous dermatosis. *Clin Dermatol*. 2012;30(1):38-50. Epub 2011/12/06. [PMID: 22137225].
4. Darling TN, Cardenas AA, Beard JS, et al. A child with antibodies targeting both linear IgA bullous dermatosis and bullous pemphigoid antigens. *Arch Dermatol*. 1995;131(12):1438-42. Epub 1995/12/01. [PMID: 7492135].
5. Akin MA, Gunes T, Akyn L, Ohyama B, Kontas O, Hashimoto T. A newborn with bullous pemphigoid associated with linear IgA bullous dermatosis. *Acta Dermatovenerologica Alpina, Pannonica, et Adriatica*. 2009;18(2):66-70. Epub 2009/07/10. [PMID: 19588060].
6. Olivry T, Dunston SM, Fahey M, Nguyen N, Marinkovich MP. Autoantibodies against the processed ectodomain of collagen XVII (BPAG2, BP180) define a canine homologue of linear IgA disease of humans. *Vet Pathol*. 2000;37(4):302-9. Epub 2000/07/15. [PMID: 10896391].
7. Schwieger-Briel A, Moellmann C, Mattulat B, et al. Bullous pemphigoid in infants: characteristics, diagnosis and treatment. *Orphanet journal of rare diseases*. 2014;9:185. Epub 2014/12/11. [PMID: 25491396].
8. Batts AF, Jalalat SZ, Hunter-Ellul L, Wilkerson MG. Exacerbation of bullous pemphigoid after hand, foot, and mouth disease treated with rituximab. *JAAD case reports*. 2016;2(1):7-9. Epub 2016/04/07.

- [PMID: 27051813].
9. Weinstein M, Fernandez A. Bullous pemphigoid in a 3-month-old mimicking hand-foot-mouth disease. *J Amer Acad Dermatol*. 2014;70(5), Supplement 1, Page AB143.
 10. Gurcan HM, Ahmed AR. Efficacy of dapsone in the treatment of pemphigus and pemphigoid: analysis of current data. *Amer J Clin Dermatol*. 2009;10(6):383-96. Epub 2009/10/15. [PMID: 19824739].
 11. Kuenzli S, Grimaitre M, Krischer J, Saurat JH, Calza AM, Borradori L. Childhood bullous pemphigoid: report of a case with life-threatening course during homeopathy treatment. *Pediatr Dermatol*. 2004;21(2):160-3. Epub 2004/04/14. [PMID: 15078359].
 12. Sousa B, Mota A, Morgado H, Lopes JM, Dias JA. [Bullous pemphigoid in an infant] *Acta Med Port*. 2005;18(2):159-62. Epub 2005/10/07. [PMID: 16206462].
 13. Chanal J, Ingen-Housz-Oro S, Ortonne N, et al. Linear IgA bullous dermatosis: comparison between the drug-induced and spontaneous forms. *Br J Dermatol*. 2013;169(5):1041-8. Epub 2013/07/03. [PMID: 23815152].