

Cardiac Catheterization

The ACRA Anatomy Study (Assessment of Disability After Coronary Procedures Using Radial Access) A Comprehensive Anatomic and Functional Assessment of the Vasculature of the Hand and Relation to Outcome After Transradial Catheterization

Maarten A.H. van Leeuwen, MD; Maurits R. Hollander, MD; Dirk J. van der Heijden, MD; Peter M. van de Ven, PhD; Kim H.M. Opmeer, MD; Yannick J.H.J. Taverne, MD, PhD; Marco J.P.F. Ritt, MD, PhD; Ferdinand Kiemeneij, MD, PhD; Nicolas M. van Mieghem, MD, PhD; Niels van Royen, MD, PhD

Background—The palmar arches serve as the most important conduits for digital blood supply, and incompleteness may lead to digital ischemia when the radial artery becomes obstructed after cardiac catheterization. The rate of palmar arch incompleteness and the clinical consequences after transradial access are currently unknown.

Methods and Results—The vascular anatomy of the hand was documented by angiography in 234 patients undergoing transradial cardiac catheterization. In all patients, a preprocedural modified Allen test and Barbeau test were performed. Upper-extremity function was assessed at baseline and 2-year follow-up by the QuickDASH. Incompleteness of the superficial palmar arch (SPA) was present in 46%, the deep palmar arch was complete in all patients. Modified Allen test and Barbeau test results were associated with incompleteness of the SPA ($P=0.001$ and $P=0.001$). The modified Allen test had a 33% sensitivity and 86% specificity for SPA incompleteness with a cutoff value of >10 seconds and a 59% sensitivity and 60% specificity with a cutoff value of >5 seconds. The Barbeau test had a 7% sensitivity and 98% specificity for type D and a 21% sensitivity and 93% specificity for types C and D combined. Upper-extremity dysfunction was not associated with SPA incompleteness ($P=0.77$).

Conclusions—Although incompleteness of the SPA is common, digital blood supply is always preserved by a complete deep palmar arch. Preprocedural patency tests have thus no added benefit to prevent ischemic complications of the hand. Finally, incompleteness of the SPA is not associated with a loss of upper-extremity function after transradial catheterization. (*Circ Cardiovasc Interv.* 2017;10:e005753. DOI: 10.1161/CIRCINTERVENTIONS.117.005753.)

Key Words: follow-up studies ■ hand ■ humans ■ radial artery ■ upper extremity

The radial artery (RA) is the preferred access site for coronary catheterization and intervention, mainly driven by the low number of access site–related complications.¹ RA occlusion is the most frequent complication after radial access and might lead to disabling symptoms² and in rare cases to acute ischemic events.³ Besides a network of collaterals, digital blood supply is mainly supported by the palmar arches. Incompleteness of the superficial (SPA) and deep palmar arch (DPA) puts patients at an increased risk for digital ischemia when the RA becomes occluded or damaged after cardiac catheterization.

Noninvasive methods have been recommended to assess the patency of a double palmar arch circulation to prevent

ischemic complications of the hand.⁴ The most applied is the modified Allen test (MAT),⁵ although it is more subjective than the Barbeau test.⁶ Although both tests are designed to verify dual palmar arch completeness, anatomic studies in living patients comparing these tests to actual anatomic variations are lacking. Most anatomic knowledge comes from post-mortem studies,⁷ describing variable rates of SPA and DPA completeness. To understand the clinical relevance of palmar arch incompleteness and its relation to commonly used patency tests, we performed a comprehensive angiographic study on the anatomy of the palmar vasculature in patients referred for transradial cardiac catheterization. Anatomy was

Received July 13, 2017; accepted September 22, 2017.

From the Department of Cardiology (M.A.H.v.L., M.R.H., D.J.v.d.H., K.H.M.O., F.K., N.v.R.) and Department of Plastic Surgery (M.J.P.F.R.), VU University Medical Center, Amsterdam, the Netherlands; Department of Epidemiology and Biostatistics, VU University, Amsterdam, the Netherlands (P.M.v.d.V.); Department of Cardiology (N.M.v.M.) and Department of Cardiothoracic Surgery (Y.J.H.J.T.), Erasmus MC, Rotterdam, the Netherlands; Department of Cardiology, Radboud University Medical Center, Nijmegen, the Netherlands (N.v.R.); and Department of Cardiology, Isala Heart Centre, Zwolle, the Netherlands (M.A.H.v.L.).

The Data Supplement is available at <http://circinterventions.ahajournals.org/lookup/suppl/doi:10.1161/CIRCINTERVENTIONS.117.005753/-DC1>.

Correspondence to Niels van Royen, MD, PhD, Department of Cardiology, Radboud University Medical Center, Geert Grooteplein Zuid 10, 6525 GA Nijmegen, the Netherlands. E-mail niels.vanroyen@radboudumc.nl

© 2017 American Heart Association, Inc.

Circ Cardiovasc Interv is available at <http://circinterventions.ahajournals.org>

DOI: 10.1161/CIRCINTERVENTIONS.117.005753

WHAT IS KNOWN

- The application of noninvasive tests to assess the patency of the palmar arches has been advocated before transradial catheterization to prevent ischemic complications of radial artery occlusion.
- Some centers do not apply these tests as a standard preprocedural evaluation given the inability to predict ischemia of the hand.

WHAT THE STUDY ADDS

- This study provides a comparison of angiographic vascular anatomy of the hand during transradial access and functional testing.
- The study informs about the inability of noninvasive patency tests to predict acute ischemic complications.
- Upper-extremity dysfunction after transradial catheterization is not related to palmar arch incompleteness.

related to outcome of the MAT and Barbeau tests, as well as to clinical outcome regarding upper-extremity function at long-term follow-up.

Methods

Study Design and Patient Population

Between May 2014 and September 2015, 1195 patients were admitted at the day care unit for elective coronary angiography or percutaneous coronary intervention at the VU University Medical Center, as represented in the enrollment flowchart (Figure 1). Patients were eligible for study participation when the following exclusion criteria were absent: (1) inability or not willing to give informed consent, (2) ST-segment–elevation myocardial infarction or hemodynamic instability, (3) severe kidney failure with an estimated glomerular filtration rate of <30 mL/min per 1.73 m², and (4) expected femoral access (ie, percutaneous coronary intervention for chronic total occlusion). Informed consent was obtained before the coronary procedure. Study-related measurements (including MAT and Barbeau) were unknown to the treating physician. The study protocol was approved by the local ethics committee.

Aims

The primary objective was to determine the rate of palmar arch incompleteness in patients undergoing transradial angiography and to compare this with the test results of the MAT and Barbeau. The effect of palmar arch incompleteness on digital vascular supply and upper-extremity function at long clinical follow-up were considered as secondary objective.

Noninvasive Patency Tests

Modified Allen Test

The MAT was performed at the day care unit, before radial access. First, simultaneous manual compression of both the radial and ulnar artery (UA) was performed followed by clenching of the hand. Then the patient was asked to open the hand, without hyperextending of the wrist and fingers. The time to reach maximal palmar blush was recorded after pressure release of the UA, while maintaining compression on the RA. Patients were categorized according to the MAT result: normal (0–5 seconds), intermediate (6–10 seconds), or abnormal (>10 seconds).⁸

Barbeau Test

The Barbeau test was performed with plethymography. A pulse oximetry sensor was clamped to the thumb, and tracings were monitored in rest and during compression of the RA (Barbeau test)⁶ or compression of the UA (reverse Barbeau test).⁹ Based on these tracings, patients were categorized into 4 groups (A–D). In summary, type A, no damping of pulse tracing immediately after compression; type B, damping of pulse tracing; type C, loss of pulse tracing followed by recovery of pulse tracing within 2 minutes; and type D, loss of pulse tracing without recovery within 2 minutes. The Barbeau test was performed before radial access and the reverse Barbeau before discharge to determine the occurrence of RA occlusion.

Radial Access and Angiography of the Hand Vasculature

Radial access was standardly performed with a double wall puncture technique and placement of a 6F 10-cm-long sheath (Terumo). The site of radial access was left to the discretion of the operator. A cocktail of 0.2-mg nitroglycerine and 5-mg verapamil was given intra-arterially followed by 5000 IU bolus of unfractionated heparin. The amount of unfractionated heparin was adapted to the patient's body weight when percutaneous coronary intervention was performed. The introducer sheath was removed at the end of the coronary procedure, and a transradial band (Terumo) was applied per manufacturer's instructions.

Angiography of the forearm and hand vasculature was performed by manual contrast injection via the radial introducer sheath according to a standardized protocol. Image acquisition was acquired with a Philips Allura Xper FD10 X-ray system and was set at 30 frames per second with a ×25 magnification. The detector was first positioned to visualize the introducer sheath and the lower arm vasculature. The RA was visualized by retrograde contrast injection (Figure 2A). Then, the contrast antegradely filled the UA and the palmar arch circulation, which was also visualized (Figure 2B and 2C). Image acquisition was stopped until the contrast reached the artery of the thumb (Figure 2D; Movie I in the [Data Supplement](#)).

Angiographic Analyses

The angiograms were reviewed according to a standardized protocol by 2 researchers who were blinded to the clinical data. Angiograms were checked on the presence of palmar arch completeness and anastomotic connections that contributed to digital perfusion of the hand (ie, median artery and arterial collaterals). With a frame counter, flow velocity was obtained by calculating the number of frames the contrast needed to reach certain predefined anatomic landmarks (Figure 2A through 2D): (1) RA (at the level of the radial sheath insertion), (2) UA (at the virtual orthogonal axis of the radial sheath insertion), and (3) artery of the thumb. Vascular dimensions of the palmar arches and main supplying vessels (trajectory of the RA and UA proximal to the predefined anatomic landmark) were obtained with quantitative coronary angiography, using the edge detection method of Philips Xcelera 3.2 (Philips Medical Systems, Eindhoven, the Netherlands). Angiographic and clinical data were prospectively collected and stored in a dedicated electronic database.

Definition of Palmar Arch Completeness

Completeness of the palmar arches was based on a previous anatomic publication that determined the safety of RA harvest.¹⁰ The SPA was defined as complete when it directly supplied all digits, including the ulnar side of the thumb. The DPA was defined as complete when the distal part of the deep palmar branch of the RA was connected with the deep palmar branch of the UA¹⁰. Figure 3 schematically displays how we categorized the potential variants of the palmar arches with respect to completeness.

Upper-Extremity Function and Cold Intolerance

The QuickDASH questionnaire was used to assess upper-extremity function at baseline and follow-up.¹¹ A higher score indicates more upper-extremity dysfunction. A minimal clinically

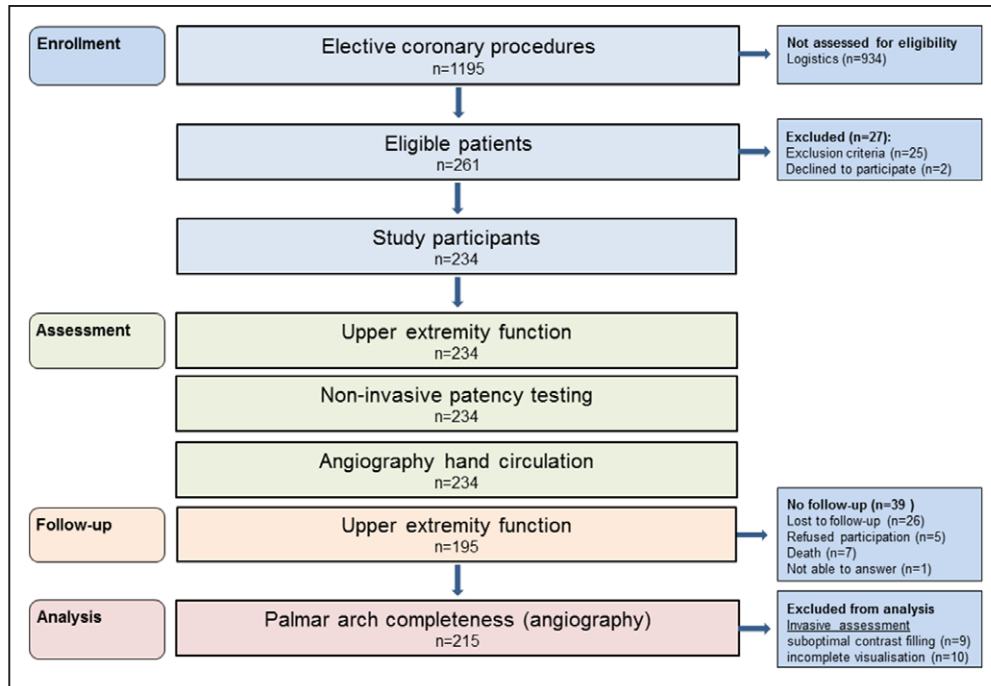


Figure 1. Enrollment flowchart.

important difference of 14 was used to determine the change in clinical status of upper-extremity functioning.¹² The validated Cold Intolerance Symptom Severity (CISS) questionnaire was applied at baseline and follow-up to detect cold intolerance.¹³ Cold intolerance is defined as abnormal pain of the hand and fingers after exposure to cold that leads to significant functional impairment,¹⁴ which commonly occurs after a variety of upper-extremity injuries.¹⁵ Pathological cold intolerance is defined as CISS ≥ 30 .¹⁶ An example of the QuickDASH and CISS questionnaire has been published previously.¹⁷

Statistical Analysis

Continuous variables are presented as mean \pm SD in case of a normal distribution and median plus interquartile range otherwise. Categorical variables are expressed as percentages. Categorical variables were compared between groups using the χ^2 test. The Fisher exact test was used for categorical variables when the total number of observed counts was <10 . Means of continuous variables were compared between groups using independent sample *t* test when data were normally distributed and Mann–Whitney *U* test when this was not the case. Odds ratios (ORs) were calculated from a logistic model. Sensitivity of the MAT and Barbeau tests for incompleteness of the SPA was calculated with angiographic assessment of palmar arch

completeness as the gold standard. Sensitivity and specificity of both tests was represented graphically for different cutoffs in a receiver operating characteristic curve, and the areas under the curve were reported as a measure of discriminative ability. All statistical tests were 2 tailed, and a *P* value of <0.05 was considered statistically significant. All statistical analyses were performed with SPSS for Windows, version 22.0 (SPSS, Inc, Chicago, IL).

Results

Study Population

Between May 2014 and October 2015, 261 patients were screened for study participation, and 934 patients were not assessed for eligibility because of logistics (Figure 1). Patients were mainly excluded from study participation because of anticipated femoral access ($n=18$). Two patients declined to participate. The study population consisted of 234 patients with a mean age of 63 years. Clinical and procedural characteristics are presented in Table 1. Radial access was achieved in all patients. The MAT and Barbeau tests were performed in all study participants and the test results are specified in Table 2.

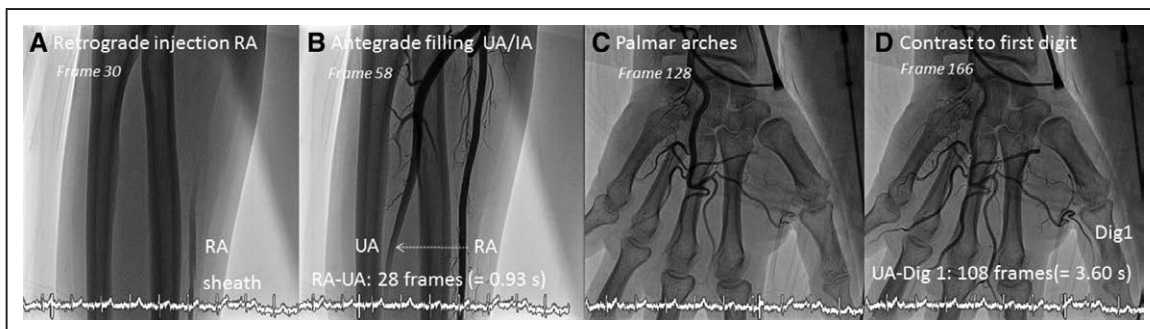


Figure 2. Angiography of the vascular hand supply with estimation of collateral flow. Angiography of the forearm and hand vasculature. After retrograde injection into the radial artery (RA; **A**), contrast reached the ulnar artery (UA) at the virtual orthogonal axis after 0.93 s (**B**). Contrast reached both palmar arches (**C**) and supplied all digits, including the thumb (**D**). The time for contrast to travel between the UA and artery of the thumb was 3.60 s. Dig indicates digit; and IA, interosseous artery.

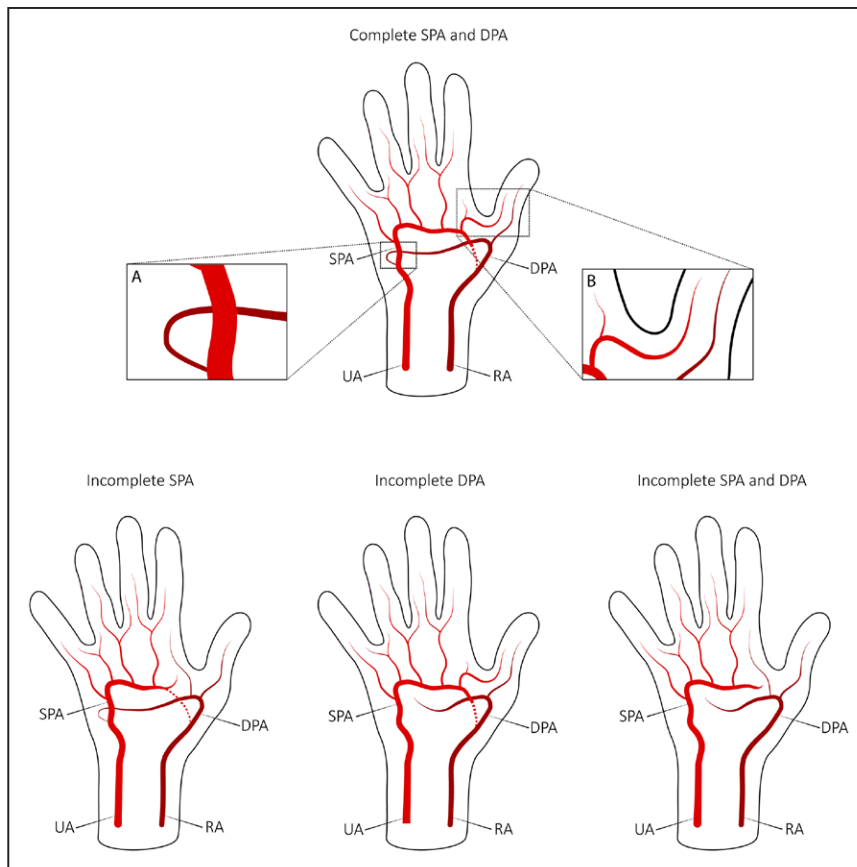


Figure 3. Schematic categorization of palmar arch completeness. The deep palmar arch (DPA) was defined as complete when the distal part of the deep palmar branch of the radial artery (RA) was connected with the deep palmar branch of the ulnar artery (UA; **A**). The superficial palmar arch (SPA) was defined as complete when it directly supplied all fingers, including the ulnar side of the thumb (**B**). The dotted line represents the superficial palmar branch of the RA.

Angiography of the Vascular Hand Supply

Angiography of the vascular hand supply was performed in all study participants without complications and analyzable in 215 patients (92%). Exclusion from analysis was caused by suboptimal contrast filling ($n=9$) or incomplete angiographic visualization of the SPA ($n=10$). Exclusion from analysis was similar in each MAT group (abnormal, 9%; intermediate, 8%; abnormal, 6%; $P=0.78$).

The angiographic characteristics of the vascular hand supply are presented in Table 3. Incompleteness of the SPA was present in 46%, and incompleteness of the DPA was not observed in our population. Angiographic examples of a complete and incomplete SPA are exhibited in Figures I and II in the [Data Supplement](#). Next to the palmar arches, vascular supply of the hand was supported by alternative arterial connections. Interosseous collateral arteries connecting distal to the occluded RA were observed in 54% and a persistent median artery in 6% of patients. Anastomoses between the SPA and DPA were visualized in 49%, and the SPA connected to the RA in 36% of patients via the superficial palmar branch of the RA. A patient example with recruitment of interosseous collateral arteries is exhibited in Figure III in the [Data Supplement](#).

The mean diameters of the palmar arches and main supplying vessels were SPA, 1.78 (± 0.4); DPA, 1.29 (± 0.3); UA, 2.35 (± 0.5), and RA, 2.57 mm (± 0.4). The UA was larger than the RA in 30% of patients. In Table 4, the vascular dimensions were stratified for palmar arch completeness and showed a larger UA and SPA in patients with completeness of the SPA ($P=0.002$ and $P<0.001$, respectively). In contrast, the RA

was larger in case of incompleteness of the SPA ($P=0.017$) with more recruitment of interosseous collaterals (65% versus 44%; $P=0.002$). The mean DPA diameter was also larger in patients with SPA incompleteness, albeit nonsignificant ($P=0.17$). However, the minimum DPA diameter was significantly larger in patients with incompleteness of the SPA (0.26 versus 0.23 mm; $P=0.022$).

In the overall patient population, blood supply to all digits was maintained during occlusive radial access. Patients with incompleteness of the SPA showed a trend for delayed perfusion of the thumb along the collateral pathway (UA-digit 1; $P=0.08$). The time for contrast to travel between the RA and UA was similar in patients with and without completeness of both palmar arches ($P=0.22$), as represented in Table 4.

Correlation Between Angiographic and Noninvasive Assessment of the Palmar Arches

The distribution of SPA incompleteness within the MAT and Barbeau tests is represented in Figure 4A. The proportion of SPA incompleteness was highest in patients with an abnormal preprocedural MAT and was subsequently smaller in patients with an intermediate and normal MAT (P trend=0.001). Patients with an abnormal MAT result have a 3× higher probability for SPA incompleteness (OR, 3.1; 95% confidence interval, 1.6–6.0; $P=0.001$), and patients with a normal MAT have a 2× higher probability for SPA completeness (OR, 2.2; 95% confidence interval, 1.3–3.7; $P=0.006$). Similarly, the highest proportion of SPA incompleteness was observed in patients with a type D Barbeau and subsequently smaller in patients with a type C, B, and A test result (P trend=0.001). Patients

Table 1. Patient and Procedural Characteristics

Demographic characteristics	
Age, y	63±11
Men	164 (76%)
Height, cm	175±8
Weight, kg	85±17
Cardiovascular history	
Previous MI	46 (21%)
Previous PCI	62 (29%)
Previous CABG	2 (1%)
Peripheral artery disease	10 (5%)
Previous radial access	84 (39%)
Previous femoral access	51 (24%)
Cardiovascular risk factors	
Current smoking	38 (18%)
Hypertension	112 (52%)
Hypercholesterolemia	87 (41%)
DM	45 (21%)
BMI, kg/m ²	27 (24–30)
Family history of CVD	75 (36%)
Procedure	
PCI	101 (47%)
Procedural time, min	34 (20–50)
Procedural success	210 (98%)
Radial artery spasm	32 (15%)
Pain score (VAS)	0 (0–3)

BMI indicates body mass index; CABG, coronary artery bypass grafting; CVD, cardiovascular disease; DM, diabetes mellitus; MI, myocardial infarction; PCI, percutaneous coronary intervention; and VAS, visual analogue scale.

with an abnormal Barbeau test (type C+D) have an almost 4× higher odds of SPA incompleteness (OR, 3.7; 95% confidence interval, 1.6–8.8; $P=0.003$), and patients with a type A Barbeau have a 2× higher odds of SPA completeness (OR, 2.0; 95% confidence interval, 1.1–3.6; $P=0.02$).

Table 2. Noninvasive Characteristics of the Vascular Hand Supply

MAT (n=234)	%
Normal (0–5 s)	52
Intermediate (6–10 s)	26
Abnormal (>10 s)	22
Barbeau (n=234)	%
Type A	36
Type B	51
Type C	9
Type D	4

MAT indicates modified Allen test.

Table 3. Invasive Characteristics of the Vascular Hand Supply

Palmar arch incompleteness (n=215)	%
SPA	46
DPA	0
SPA and DPA	0
Additional arterial connections	%
Interosseus collateral arteries	54
Persistent median artery	6
SPA-DPA anastomoses	49
SPA-RA connection	36

DPA indicates deep palmar arch; RA, radial artery; and SPA, superficial palmar arch.

The receiver operating characteristic curves of the MAT and Barbeau tests with the areas under the curve are represented in Figure 4B. When considering maximal palmar blushing after >10 seconds as a positive test for palmar arch incompleteness, 66 patients had a false-negative MAT result and 16 patients, a false-positive MAT result, resulting in a sensitivity of 33%, specificity of 86%, and diagnostic accuracy of 62%. If we applied >5 seconds as cutoff value, the MAT had a sensitivity of 59%, specificity of 60%, and diagnostic accuracy of 60%. For the Barbeau test, the sensitivity was 7%, specificity was 98%, and diagnostic accuracy was 57% if we considered a type D as a positive test result for palmar arch incompleteness. If we regarded a type C+D Barbeau as a positive test result, this would give a sensitivity of 21%, specificity of 93%, and diagnostic accuracy of 60%.

Table 4. Vascular and Flow Characteristics of the Hand Supply Stratified for Palmar Arch Completeness

	Palmar Arch Completeness		P Value
	Yes n=117	No n=98	
Vascular dimensions, mm			
RA	2.51 (±0.4)	2.64 (±0.4)	0.017
UA	2.45 (±0.5)	2.23 (±0.4)	0.002
SPA	1.87 (±0.4)	1.66 (±0.4)	<0.001
DPA	1.27 (±0.3)	1.32 (±0.3)	0.17
Vascular characteristics			
SPA-DPA connection	53%	47%	0.38
SPA-RA connection	59%	8%	<0.001
Distal interosseus collaterals	44%	65%	0.002
Persistent median artery	3%	9%	0.08
Collateral flow, s			
UA-digit 1	3.8 (3.0–5.2)	4.6 (3.4–5.9)	0.08
RA-UA	1.1 (0.8–1.6)	1.3 (0.9–1.8)	0.22

Palmar arch completeness=completeness of SPA and DPA. DPA indicates deep palmar arch; RA, radial artery; SPA, superficial palmar arch; and UA, ulnar artery.

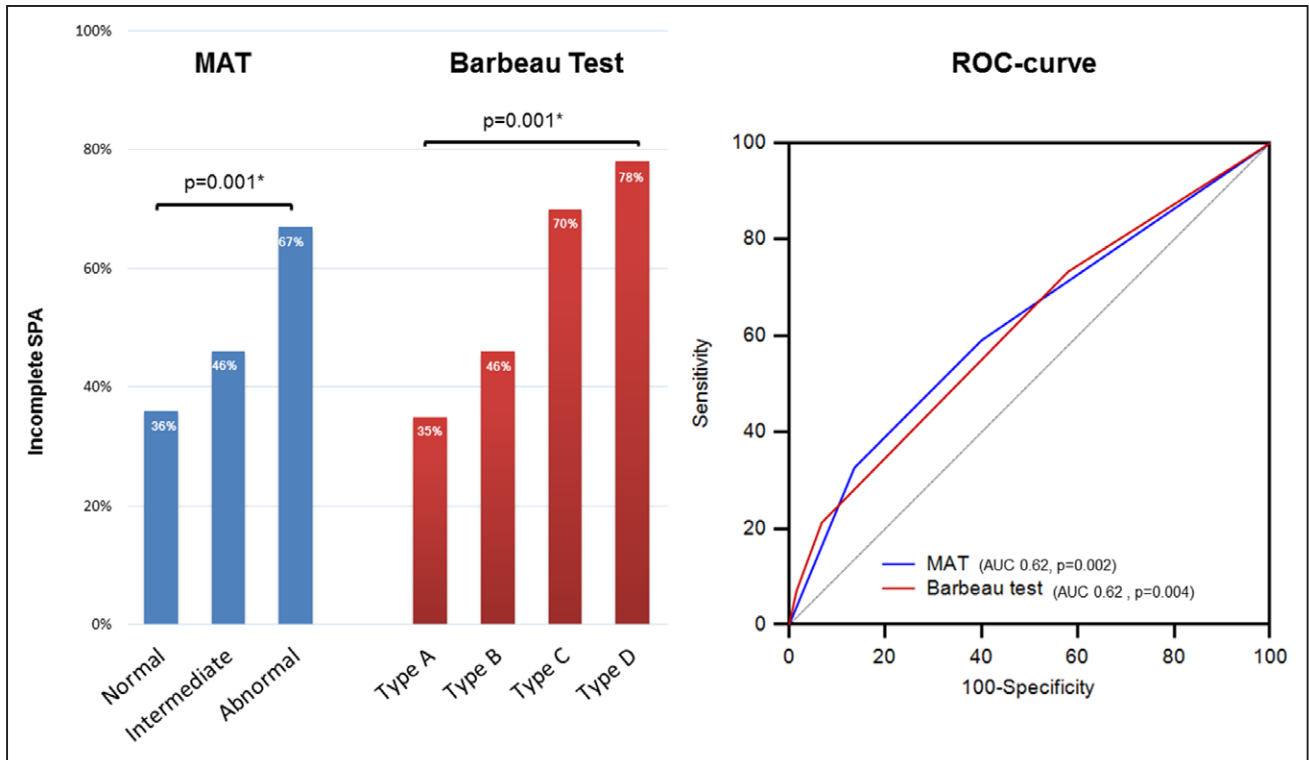


Figure 4. Association between superficial palmar arch (SPA) incompleteness and noninvasive patency tests. AUC indicates area under the curve; MAT, modified Allen test; and ROC, receiver operating characteristic. **P* value was calculated with a test for trend.

Functional Consequences of Palmar Arch Incompleteness

The QuickDASH and CISS questionnaires were obtained in all patients at baseline and in 83% of patients at long-term follow-up (median, 24 months; interquartile range, 20–29). The reasons for absent follow-up were (1) loss to follow-up, n=26; (2) death, n=7; (3) refused further participation, n=5; and (4) cognitive dysfunction, n=1.

At long-term follow-up, QuickDASH scores >0 were equally present in patients with and without SPA incompleteness (31% and 25%; *P*=0.35). The proportion of patients in which QuickDASH increased between baseline and follow-up did not differ between patients with a complete and incomplete SPA (15% versus 14%, respectively; *P*=0.81). When we applied a minimal clinically important difference of 14 for the QuickDASH score, no association was found with SPA incompleteness (Figure 5). The CISS score increased in 14% of patients with complete palmar arches as compared with 16% of patients with SPA incompleteness (*P*=0.69). The number of patients who developed pathological cold intolerance at long-term follow-up was also not statistically different between both groups (Figure 5). A reverse Barbeau type D was present in 4.9% of patients at discharge (representing RA occlusion). In this subset of patients, incompleteness of the SPA was present in 75% and digital supply was supported by interosseous collateral arteries in 63%, inter palmar arch connections in 63% and SPA-RA connection in 13%. Clinical relevant loss of upper-extremity function and the occurrence of pathological cold intolerance were not reported in this subgroup of patients at long-term follow-up.

Discussion

This is the first study evaluating the anatomy of the palmar arch circulation with angiography in patients undergoing transradial cardiac catheterization and its relation with commonly used noninvasive patency tests. The most important findings of our study are (1) digital vascular supply is always preserved during occlusive radial access, irrespective of the anatomic variations and results of noninvasive patency tests;

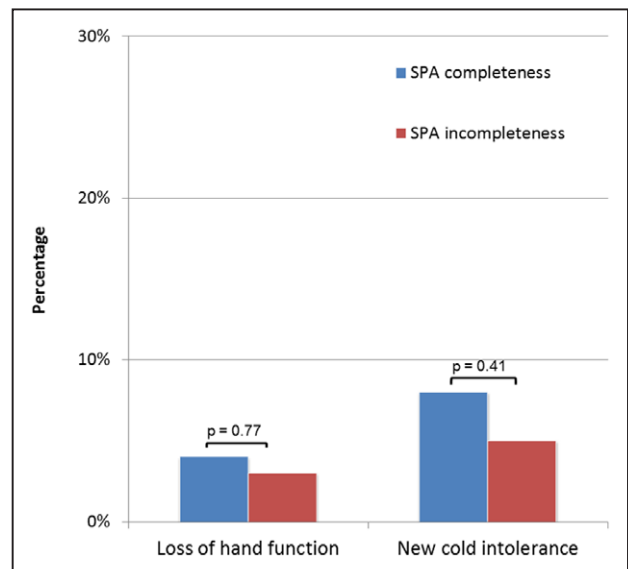


Figure 5. Loss of upper-extremity function and development of pathological cold intolerance, specified for palmar arch completeness. Palmar arch completeness= completeness of the superficial palmar arch (SPA) and deep palmar arch.

(2) the MAT and Barbeau tests have a low diagnostic accuracy for palmar arch incompleteness, mainly because of the poor sensitivity; and (3) long-term functional outcome of the upper extremity after transradial access is not related to the palmar vascular anatomy.

Most knowledge about the vascular anatomy of the hand comes from postmortem studies.⁷ Blood is supplied to the hand by a dense anastomotic network of arches with highly variable patterns, developed during the embryological phase. The most important connections are the SPA and DPA because of their major role with respect to digital blood supply. The DPA is formed by the terminal part of the RA, and the SPA is a continuum of the UA. With different visualization techniques (ie, gross dissection¹⁸ and latex injection¹⁹) and anatomic classifications, highly variable completeness rates were reported for both palmar arches.⁷ DPA completeness was present in our complete cohort, and completeness of the SPA was present in 54%, which falls into the range of previously reported anatomic data (DPA, 67%–100% and SPA, 43%–97%).⁷ Palmar arch completeness was classified according to a previously described method that determined the safety of radial harvest.¹⁰ We applied this particular classification method because it was designed to identify those patients at risk for digital ischemia when the RA becomes compromised, such as the presence of an incomplete SPA and DPA in the same hand. Combined incompleteness of the palmar arches has never been reported in the literature to our knowledge,¹⁰ which is in accordance with our study results. This is of major clinical importance because patients with this anatomic variant are potentially at the largest risk of developing ischemic complications in case of RA occlusion. And even though the SPA did not facilitate the arterial supply of the thumb in approximately half of our patients, perfusion of the thumb was still covered by the DPA during radial access. In contrast to our study, few cases with DPA incompleteness have been reported in postmortem studies.⁷ However, in this subset of patients, we do not expect an increased risk for digital ischemia or long-term complications because digital blood supply is maintained by a dominant SPA, as represented in Figure 3. In a large number of patients, digital blood supply was further supported by anastomotic connections between the palmar arches, a superficial palmar branch of the RA, and a persistent median artery. Normally the median artery ceases to exist during the embryological phase in $\approx 90\%$ of patients. Although when the median artery persists, it connects with the SPA circulation in $\approx 5\%$ of patients, which is in accordance with our study results.²⁰ In contrast to postmortem studies, we were able to visualize collaterals with angiography that were probably recruited at the time of functional occlusion of the RA. Recruitment of collateral arteries to augment digital blood supply was more frequently observed in patients with SPA incompleteness as a natural compensatory mechanism.

In clinical practice, the presence of palmar arch incompleteness is considered a major contraindication for radial harvest.²¹ Noninvasive tests to assess palmar arch completeness have, therefore, been strongly recommended to prevent ischemic complications of the hand. The implementation of these tests has also been advocated before transradial procedures⁴ because RA occlusion is the most frequently reported

complication ($\leq 30\%$)² and might lead to ischemic events.³ The MAT is the most applied test, although prone to subjectivity and without a clear consensus on the optimum cutoff point.²² Plethysmography with the application of the Barbeau test has been considered as a more sensitive tool with the ability to evaluate collateral recruitment.⁶ However, the application of both tests has not resulted in preventing acute ischemia of the hand,²³ as it has been reported in patients with and without abnormal preprocedural patency test results. Also when patients were subjected to transradial cardiac catheterization, capillary thumb lactate levels did not differ across the whole spectrum of MAT results.⁸ We here show that the MAT did not perform satisfactory to detect palmar arch incompleteness. Although the sensitivity increased from 33% to 59% when we applied a cutoff value of >5 seconds (instead of >10 seconds), the specificity dropped from 86% to 60%, resulting in a similar poor diagnostic accuracy. The Barbeau test also performed poorly to assess palmar arch incompleteness. Probably, preprocedural testing with the MAT and Barbeau should be abandoned to prevent acute ischemic events of the hand. Both tests will only lead to false exclusion from transradial procedures and subsequently to more access-related bleeding complications when femoral access is used as an alternative. In this respect, it should be mentioned that acute ischemia of the hand is an extremely rare complication.³ Arterial wall trauma with thromboembolic phenomena to the digital arteries or palmar arch circulation is probably the main underlying mechanism of acute hand ischemia after transradial access.^{3,24,25} Therefore, optimal anticoagulant therapy and meticulous access techniques remain paramount to prevent ischemic complications.

Nonetheless, upper-extremity complaints have been reported in $\leq 50\%$ of patients after RA occlusion,² and ischemia has been described after radial harvest when subjected to manual stress.²⁶ It is reasonable to think that patients with palmar arch incompleteness and a poor compensatory collateral network may develop symptoms and dysfunction of the hand. In patients with SPA incompleteness, we observed delayed perfusion of the thumb, albeit nonsignificant. The thumb is considered as the most important digit with respect to hand function, and inadequate perfusion may be more pronounced during exercise, which might lead to disabling ischemic symptoms. It was previously shown that hand function was deprived 1 month after radial access when patients had a lower Nexfin-derived collateral flow index of the thumb.²⁷ However, we observed that pathological cold intolerance and a clinical relevant reduction of upper-extremity function were similarly reported in patients with and without palmar arch incompleteness at long-term follow-up. In addition, in patients with radial artery occlusion at discharge, palmar arch incompleteness was also not related with a loss of upper-extremity function at long-term follow-up. This suggests that anatomic and physiological changes after radial access might lead to a transient upper-extremity dysfunction in patients with a less-developed collateral system. Our findings are similar with those after RA harvest, reporting no clinical relevant reduction of blood flow and function of the forearm 3 months post-surgery.²⁸ Furthermore, tissue oxygen saturation and tissue capillary blood flow remained unchanged 2 days after RA harvest, whereas both parameters were deprived during RA compression before surgery.²⁹ This

suggests that compensatory mechanisms of the collateral vascular network act rather quickly to maintain digital perfusion when the RA becomes compromised. However, future studies are needed to assess the functional consequences of radial artery occlusion when patients are subjected to manual stress.

In conclusion, the palmar arches preserve digital blood supply in all patients during radial access. Although incompleteness of the SPA is common, incompleteness of the DPA was nonexistent in our patient cohort. The presence of SPA incompleteness is not related with upper-extremity dysfunction after transradial access at long-term follow-up. The MAT and Barbeau tests have a poor ability to detect SPA incompleteness.

Limitations

We were not able to include all consecutive patients because of competing studies and logistics. However, patient characteristics¹¹ and noninvasive test results³⁰ of our study population suggest adequate external validity, which is supported by similar characteristics in the complete consecutive patient cohort (Table I in the [Data Supplement](#)). Although we were not able to visualize the palmar vasculature in all patients, we think that this did not influence our study results because of the similar distribution within each MAT group. Because this is a single center study from Europe with a finite number of patients, our anatomic and functional data should be confirmed by other study groups, including larger number of patients and patients from different ethnic backgrounds. Next to well-validated, self-reported outcome measures that evaluate the global functional capacity of the hand and the impact on daily life (ie, QuickDASH), the addition of more objective measures that address specific components of hand function (ie, hand grip test for strength) is encouraged to confirm our data. The application of manual contrast injection might have affected our study results regarding the flow characteristics. However, flow along the collateral trajectory is mainly driven by systemic blood pressure and microcirculatory resistance. Based on this report, you might also question the diagnostic accuracy of the reverse Barbeau test for the detection of RA occlusion (without ultrasound confirmation). A type D reverse Barbeau might also be present in patients with a small nonoccluded RA and dominant UA-SPA system, supplying the first digit. In addition, assessment of RA occlusion only at discharge is a limitation to our study with regard to upper-extremity dysfunction at long-term follow-up. Spontaneous recanalization occurs in 50% to 60% of patients within 1 to 6 months, and sometimes, RA occlusion may occur after discharge.³¹

Disclosures

None.

References

1. Steg PG, James SK, Gersh BJ. 2012 ESC STEMI guidelines and reperfusion therapy: Evidence-based recommendations, ensuring optimal patient management. *Heart*. 2013;99:1156–1157. doi: 10.1136/heartjnl-2013-304498.
2. Uhlemann M, Möbius-Winkler S, Mende M, Eitel I, Fuernau G, Sandri M, Adams V, Thiele H, Linke A, Schuler G, Gielen S. The Leipzig prospective vascular ultrasound registry in radial artery catheterization:

impact of sheath size on vascular complications. *JACC Cardiovasc Interv*. 2012;5:36–43. doi: 10.1016/j.jcin.2011.08.011.

3. Rademakers LM, Laarman GJ. Critical hand ischaemia after transradial cardiac catheterisation: an uncommon complication of a common procedure. *Neth Heart J*. 2012;20:372–375. doi: 10.1007/s12471-012-0276-8.
4. Hamon M, Pristipino C, Di Mario C, Nolan J, Ludwig J, Tubaro M, Sabate M, Mauri-Ferré J, Huber K, Niemelä K, Haude M, Wijns W, Dudek D, Fajadet J, Kiemeneij F; European Association of Percutaneous Cardiovascular Interventions; Working Group on Acute Cardiac Care of the European Society of Cardiology; Working Group on Thrombosis on the European Society of Cardiology. Consensus document on the radial approach in percutaneous cardiovascular interventions: position paper by the European Association of Percutaneous Cardiovascular Interventions and Working Groups on Acute Cardiac Care** and Thrombosis of the European Society of Cardiology. *EuroIntervention*. 2013;8:1242–1251. doi: 10.4244/EIJV8I11A192.
5. Bertrand OF, Rao SV, Pancholy S, Jolly SS, Rodés-Cabau J, Larose E, Costerousse O, Hamon M, Mann T. Transradial approach for coronary angiography and interventions: results of the first international transradial practice survey. *JACC Cardiovasc Interv*. 2010;3:1022–1031. doi: 10.1016/j.jcin.2010.07.013.
6. Barbeau GR, Arsenault F, Dugas L, Simard S, Larivière MM. Evaluation of the ulnopalmar arterial arches with pulse oximetry and plethysmography: comparison with the Allen's test in 1010 patients. *Am Heart J*. 2004;147:489–493. doi: 10.1016/j.ahj.2003.10.038.
7. Brzezinski M, Luisetti T, London MJ. Radial artery cannulation: a comprehensive review of recent anatomic and physiologic investigations. *Anesth Analg*. 2009;109:1763–1781. doi: 10.1213/ANE.0b013e3181bbd416.
8. Valgimigli M, Campo G, Penzo C, Tebaldi M, Biscaglia S, Ferrari R; RADAR Investigators. Transradial coronary catheterization and intervention across the whole spectrum of Allen test results. *J Am Coll Cardiol*. 2014;63:1833–1841. doi: 10.1016/j.jacc.2013.12.043.
9. Kotowycz MA, Dzavík V. Radial artery patency after transradial catheterization. *Circ Cardiovasc Interv*. 2012;5:127–133. doi: 10.1161/CIRCINTERVENTIONS.111.965871.
10. Ruengsakulrach P, Eizenberg N, Fahrer C, Fahrer M, Buxton BF. Surgical implications of variations in hand collateral circulation: anatomy revisited. *J Thorac Cardiovasc Surg*. 2001;122:682–686. doi: 10.1067/mtc.2001.116951.
11. van Leeuwen MA, van Mieghem NM, Lenzen MJ, Selles RW, Hoefkens MF, Zijlstra F, van Royen N. The effect of transradial coronary catheterization on upper limb function. *JACC Cardiovasc Interv*. 2015;8:515–523. doi: 10.1016/j.jcin.2014.10.025.
12. Sorensen AA, Howard D, Tan WH, Ketchersid J, Calfee RP. Minimal clinically important differences of 3 patient-rated outcomes instruments. *J Hand Surg Am*. 2013;38:641–649. doi: 10.1016/j.jhsa.2012.12.032.
13. Irwin MS, Gilbert SE, Terenghi G, Smith RW, Green CJ. Cold intolerance following peripheral nerve injury. Natural history and factors predicting severity of symptoms. *J Hand Surg Br*. 1997;22:308–316.
14. Koman LA, Slone SA, Smith BP, Ruch DS, Poehling GG. Significance of cold intolerance in upper extremity disorders. *J South Orthop Assoc*. 1998;7:192–197.
15. Klocker J, Peter T, Pellegrini L, Mattesich M, Loescher W, Sieb M, Klein-Weigel P, Fraedrich G. Incidence and predisposing factors of cold intolerance after arterial repair in upper extremity injuries. *J Vasc Surg*. 2012;56:410–414. doi: 10.1016/j.jvs.2012.01.060.
16. Ruijs AC, Jaquet JB, Daanen HA, Hovius SE. Cold intolerance of the hand measured by the CISS questionnaire in a normative study population. *J Hand Surg Br*. 2006;31:533–536. doi: 10.1016/j.jhsb.2006.04.013.
17. van Leeuwen MA, van der Heijden DJ, Hermie J, Lenzen MJ, Selles RW, Ritt MJ, Kiemeneij F, Zijlstra F, Van Mieghem NM, van Royen N. The long-term effect of transradial coronary catheterisation on upper limb function. *EuroIntervention*. 2017;12:1766–1772. doi: 10.4244/EIJ-D-15-00395.
18. Coleman SS, Anson BJ. Arterial patterns in the hand based upon a study of 650 specimens. *Surg Gynecol Obstet*. 1961;113:409–424.
19. Gellman H, Botte MJ, Shankwiler J, Gelberman RH. Arterial patterns of the deep and superficial palmar arches. *Clin Orthop Relat Res*. 2001:41–46.
20. Loukas M, Holdman D, Holdman S. Anatomical variations of the superficial and deep palmar arches. *Folia Morphol (Warsz)*. 2005;64:78–83.
21. Habib J, Baetz L, Satiani B. Assessment of collateral circulation to the hand prior to radial artery harvest. *Vasc Med*. 2012;17:352–361. doi: 10.1177/1358863X12451514.

22. Jarvis MA, Jarvis CL, Jones PR, Spyt TJ. Reliability of Allen's test in selection of patients for radial artery harvest. *Ann Thorac Surg.* 2000;70:1362–1365.
23. Kanei Y, Kwan T, Nakra NC, Liou M, Huang Y, Vales LL, Fox JT, Chen JP, Saito S. Transradial cardiac catheterization: a review of access site complications. *Catheter Cardiovasc Interv.* 2011;78:840–846. doi: 10.1002/ccd.22978.
24. Valentine RJ, Modrall JG, Clagett GP. Hand ischemia after radial artery cannulation. *J Am Coll Surg.* 2005;201:18–22. doi: 10.1016/j.jamcollsurg.2005.01.011.
25. Costa F, van Leeuwen MA, Daemen J, Diletti R, Kauer F, van Geuns RJ, Ligthart J, Witberg K, Zijlstra F, Valgimigli M, Van Mieghem NM. The Rotterdam radial access research: ultrasound-based radial artery evaluation for diagnostic and therapeutic coronary procedures. *Circ Cardiovasc Interv.* 2016;9:e003129. doi: 10.1161/CIRCINTERVENTIONS.115.003129.
26. Manabe S, Tabuchi N, Toyama M, Yoshizaki T, Kato M, Wu H, Kotani M, Sunamori M. Oxygen pressure measurement during grip exercise reveals exercise intolerance after radial harvest. *Ann Thorac Surg.* 2004;77:2066–2070. doi: 10.1016/j.athoracsur.2003.10.052.
27. Hollander MR, van Leeuwen MA, van der Heijden D, Keizer VM, van de Ven PM, SJ IJ, Van Mieghem NM, Amoroso G, Ritt MJ, Knaapen P, van Royen N. Noninvasive assessment of the collateral circulation in the hand, validation of the Nexfin system and relation to clinical outcome after transradial catheterization. *EuroIntervention.* 2017; 12: 1773–1781.
28. Chong WC, Ong PJ, Hayward CS, Collins P, Moat NE. Effects of radial artery harvesting on forearm function and blood flow. *Ann Thorac Surg.* 2003;75:1171–1174.
29. Knobloch K, Lichtenberg A, Pichlmaier M, Tomaszek S, Krug A, Haverich A. Palmar microcirculation after harvesting of the radial artery in coronary revascularization. *Ann Thorac Surg.* 2005;79:1026–1030; discussion 1030. doi: 10.1016/j.athoracsur.2004.03.026.
30. BenitE, VranckxP, JaspersL, JackmaertR, PoelmansC, ConinxR. Frequency of a positive modified Allen's test in 1,000 consecutive patients undergoing cardiac catheterization. *Cathet Cardiovasc Diagn.* 1996;38:352–354. doi: 10.1002/(SICI)1097-0304(199608)38:4<352::AID-CCD5>3.0.CO;2-6.
31. Nagai S, Abe S, Sato T, Hozawa K, Yuki K, Hanashima K, Tomoike H. Ultrasonic assessment of vascular complications in coronary angiography and angioplasty after transradial approach. *Am J Cardiol.* 1999;83:180–186.