

5-2018

Cancer Cachexia: Metabolic Changes that occur in Oxidative Capacity and Carbohydrate and Lipid Metabolism of the Liver

Sarah Ramey

Follow this and additional works at: <https://scholarworks.uark.edu/hhpruht>

Part of the [Exercise Physiology Commons](#), [Exercise Science Commons](#), and the [Systems and Integrative Physiology Commons](#)

Recommended Citation

Ramey, Sarah, "Cancer Cachexia: Metabolic Changes that occur in Oxidative Capacity and Carbohydrate and Lipid Metabolism of the Liver" (2018). *Health, Human Performance and Recreation Undergraduate Honors Theses*. 59.
<https://scholarworks.uark.edu/hhpruht/59>

This Thesis is brought to you for free and open access by the Health, Human Performance and Recreation at ScholarWorks@UARK. It has been accepted for inclusion in Health, Human Performance and Recreation Undergraduate Honors Theses by an authorized administrator of ScholarWorks@UARK. For more information, please contact cmiddle@uark.edu.

Cancer Cachexia: Metabolic Changes that occur in Oxidative Capacity and Carbohydrate and Lipid Metabolism in the Liver

Sarah Ramey

University of Arkansas

Primary Investigator: Nicholas P. Greene, Ph.D.

Committee Members: Nicholas P. Greene, Tyrone A. Washington, and Erin K. Howie

Project assisted by Megan Rosa-Caldwell

A thesis submitted to the Honors College at the University of Arkansas in partial fulfillment of the requirements for the degree Bachelor of Science in Kinesiology with Honors

May 1, 2017

INTRODUCTION AND LITERATURE REVIEW

Cancer is a disease encountered universally. In 2016 it was ranked as the second leading cause of death in the United States (19). One negative side effect of cancer that dramatically affects cancer prognosis and progression is the development of cancer cachexia. Cancer cachexia is defined as cancer associated loss of body weight, predominantly muscle loss (9). It is estimated that cancer cachexia is responsible for the death of 20-40% of all cancer patients depending on the type of cancer (9,10). Current treatments for cancer cachexia thus far have proven ineffective and there is increasing evidence that cancer cachexia, once developed, is largely irreversible (9,10). Therefore, efforts to understand the causes of cancer cachexia progression are critical.

A primary factor in the development of cachexia is increased resting energy expenditure and decreased energy intake (17). During cancer progression, tumors rely primarily on glycolytic metabolism, known as the Warburg effect (11). The resulting tumor growth is explained by a process called the Cori cycle, in which glucose production is increased due to glucose recycling, predominantly occurring in the liver. The liver is necessary in energy regulation and utilization due to the process of gluconeogenesis, possibly another reason for cachexia to advance further (3, 17). This highly inefficient system is at least partially responsible for increased energy demands of the tumor-bearing state, thus tissues responsible for energy utilization may hold key information in the initial stages of cachexia development. The liver is known to be a predominant regulator of whole body metabolism, mediating the storage and breakdown of glycogen and fatty acids for energy requirements (4).

Carbohydrate Metabolism and the Liver

Currently, little is known about liver metabolism in the development of cancer cachexia. Though there is not a lot of research in functions of the liver as it relates to cancer cachexia, Narsale et. al. (14) found that cancer cachexia resulted in hepatic hypertrophy, decreased liver glycogen content and inflammation (14). This revealed that cancer has a significant impact on the liver, specifically liver metabolism, and may in turn play an important role in the development of the cachectic phenotype (14). However, this study only examined liver metabolism after the development of cachexia. Although there is some research revealing alterations in glycogen content of the liver as a result of cancer cachexia, it is still not completely known how cancer also affects lipid and oxidative metabolism during early, pre-cachectic phases and throughout cancer progression.

Lipid Metabolism and the Liver

Though there is still more research needed to fully understand the role of lipids and the liver during progression of cancer cachexia, Petruzzelli & Wagner (17) did find that lipid and oxidative metabolism were severely affected, with specifically an observed increase in lipid breakdown. Fatty acids in the liver are important in storing and circulating forms of energy via lipolysis (15). Das et. al (7) found that lipolysis was increased in cancer patients as assessed by increased adipose triglyceride lipase activity, but however the relationship between cachexia development and lipid synthesis, storage, and utilization are still largely uninvestigated.

Oxidative Metabolism and the Liver

The main organelles of oxidative metabolism are the mitochondria. Previous research has found damage to liver mitochondria to precede impaired whole body metabolism (18). One study found that the liver of cachectic rats revealed a decrease in mitochondrial enzyme activities and ATP concentration (8). Therefore, mitochondrial dysfunction during the advancement of cancer could dramatically affect energy homeostasis for the entire body (8). Some research has shown that hepatic oxidative phosphorylation is decreased in a cancerous rat model and is associated with increased energy demand (17). Therefore, disrupted oxidative capacity and metabolism in the liver could possibly contribute to development of cancer cachexia.

Purpose/Hypothesis

While previous research on cancer cachexia has mainly focused on muscle physiology, more research in other metabolic tissues is necessary to understand the whole body pathology of cancer. Due to the fact that 30-80% of cancer patients experience severe weight loss, there remains a need for research on cancer cachexia because of its impact on survival and quality of life in cancer patients (21). However, the effect of cancer on liver metabolism and subsequent muscle wasting during cachexia remains elusive. Therefore, the purpose of this study was to identify alterations in liver metabolism of tumor-bearing mice by analyzing stained liver sections throughout the progression of Lewis Lung Carcinoma (LLC) induced cancer cachexia. We examined glycogen and lipid content, as well as markers of oxidative quality by performing histological staining techniques in the livers of mice during the progression of cancer cachexia.

We hypothesized that markers of mitochondrial oxidation, glycogen content and lipid metabolism would decline in the liver as cancer cachexia progresses.

Proposed Methods

Animals and Interventions

All animal experiments were performed at the University of Arkansas and were approved by the Institutional Animal Care and Use Committees of the University of Arkansas, Fayetteville.

LLC Tumor Implantation and Tissue Collection

C57BL/6J mice, which are a commonly used mouse for this type of research, were used in this experiment and purchased from Jackson Laboratories (13). The mice were kept on a 12 hours light, 12 hours dark cycle with full access to food and water throughout the course of the study. At 8 weeks of age the mice were sedated with isoflurane and were injected with 1×10^6 Lewis Lung Carcinoma Cells in the left posterior leg, which is a commonly accepted method for inducing cancer cachexia in mice (6). For the control group, the mice were injected with 100 μ L sterile phosphate buffered saline (PBS) which is a frequently used and accepted type of injection for control groups. Cancer was allowed to progress for 1, 2, 3 or 4 weeks. The experimental groups included the PBS, 1wk, 2wk, 3wk, and 4wk of cancer progression, with 12-16 mice in each group. The PBS control group was matched by age to the most cachectic group, in which it was 4 weeks post-implantation, but the animals were 12 weeks of age at the time of tissue collection. The tissues were collected directly after the animals were sedated with isoflurane before euthanasia. Sections of liver were then be cut at 10-12 μ m using a Leica CM1950 clinical cryostat.

Histological Staining

A subset of ~8 mice/group were used for staining. After mice were euthanized under anesthesia and the liver sample is cut, the tissue was frozen in a position that the tissue fibers were perpendicular to the bottom of the mold in an OCT (optimal cutting temperature) media-freezing compound chilled previously in liquid nitrogen. We then wrapped the tissue block in aluminum foil and stored in -80°C. Next, we cut the liver tissue cross-sections (10-12 µm) using a Leica CM1859 clinical cryostat and mounted the sections on a positive charged glass slide. These were stored at -80°C until the stain was performed.

SDH Stain and Analysis

The protocol for the SDH stain we used is based on our laboratory protocol for staining liver tissue to determine if there is a change in mitochondrial SDH activity as an indicator of oxidative capacity. When we were ready to perform the SDH stain, we placed the slide with the liver section in a chamber and incubated it in a prewarmed Incubation Solution (50 mM Sodium succinate, 50 mM Phosphate buffer, 0.12M KH₂PO₄ & 0.88M Na₂HPO₄, 0.5 mg/ml Nitroblue tetrazoliumand) for 40 min in a 37°C water bath. We washed the samples in distilled water for 3 minutes, and let water dry from slide glass. We used Glycerol-based mounting medium (0.12 M KH₂PO₄ and 0.88 M Na₂HPO₄) to mount the slide, and then finally sealed the slide with clear nail polish.

Oil Red O Stain and Analysis

When we are ready to stain, we let slides dry at room temperature for 10-15 minutes. We fixed slides in 3.7% formaldehyde for 10 minutes and then quickly rinse in distilled water. We then placed the slides in 60% isopropyl alcohol (60 ml isopropyl alcohol, volume up to 100 ml with distilled water) in distilled water on a gentle shaker, and after, placed the slides in Oil Red O working solution (4:6 ratio of distilled water to stock Oil Red O) for 30 minutes also on a gentle

shaker. Next, rinsed the slides for 3 minutes in tap water and then placed slides in hematoxylin (heat and filtered before use) for 1 minute. We rinsed the slides in tap water for 3 minutes and then rinsed for 3 more minutes in distilled water. Finally, dried the slides, mounted with a small drop of glycerol and sealed with clear nail polish. In order to remove stain from slides, cleaned with 100% xylenes.

Periodic acid–Schiff (PAS) Stain

The PAS protocol is used to stain for glycogen in the tissue (20). First, we placed the coverslips with the sections of liver tissue in a columbia staining dish (Thomas Scientific #8542-E40). We then added Carnoy's fixative (prepared in fume hood with 60 ml 100% alcohol, 30 ml Chloroform, 10 ml Glacial acetic acid) to the dish and let sit for 10 minutes. Next, rinsed the slides carefully with deionized water before adding the Periodic acid solution (prepared fresh for each stain, Periodic acid 50 mg dissolved in 10 ml deionized water) to the staining dish for 10 minutes. Once again, we rinsed the slides carefully with deionized water. We then added the Schiff Reagent (Harleco 6073/71) and let sit for 5 minutes before washing with tap water. Then, we dehydrated in ascending alcohol solutions (50%, 70%, 80%, 95% x 2, 100% x 2) in the columbia staining dish (Thomas scientific #8542-E30). We then cleared the slides with xylene (3-4x) also in the columbia staining dish. Lastly, we mounted the coverslips onto a labeled glass slide with glycerol mounting medium and secured with clear nail polish.

Image Analysis

We accumulated images with the Nikon Sight DS-Vi1 camera mounted on an Olympus CKX41 inverted microscope. Once the images were collected, we analyzed the images with Nikon Basic Research Imaging Software. For each of the stains, image analysis was performed by taking images of the slides using 20X on the Olympus microscope, with exposure time being the same

for all images (1-2ms). In order to highlight the darker portions of the image (SDH, lipids and glycogen), we went to “Binary” in the top tool bar of the software and define the threshold, which allowed us to analyze the area and intensity of stain of the images.

Statistical Analysis

The time groups (PBS v. 1wk v. 2wk v. 3wk v. 4wk) were the independent variables. With alpha (α) set at 0.05, the results were analyzed by one-way analysis of variance (ANOVA). When the F test was significant we used a Tukey post-hoc to determine differences between means.

Results

Hepatic hypertrophy in the development of cancer-cachexia

When compared to PBS control, 4 wk animals had 30% larger livers in 4 wk animals compared to all other groups (~1000mg compared to ~1300 mg) at the end of cancer progression ($p < 0.0001$). Development of cachexia was evident as there were differences in muscle mass between 1 and 4 wk animals, as shown by Brown et al (5).

Hepatic oxidative phenotype in progression of cancer-cachexia

Using the SDH stain, we found there no statistical differences in the percent area stained, $p = 0.1884$) or sum intensity of stain ($p = 0.1387$) over time of cancer progression (Fig. B and C).

Hepatic lipid content

Using the Oil Red O stain, there were also no statistical differences found in percent area stained ($p = 0.476$, ~4% across groups) throughout progression of cancer.

Hepatic glycogen content

The effect size revealed that there were some differences between 3 wk animals and 1 and 2 wk animals for percent area stained ($p= 0.0094$), but no differences detected between 4 wk animals. There were no statistical differences found in mean intensity ($p= 0.4632$) or sum intensity of stain ($p= 0.1758$).

Figure A

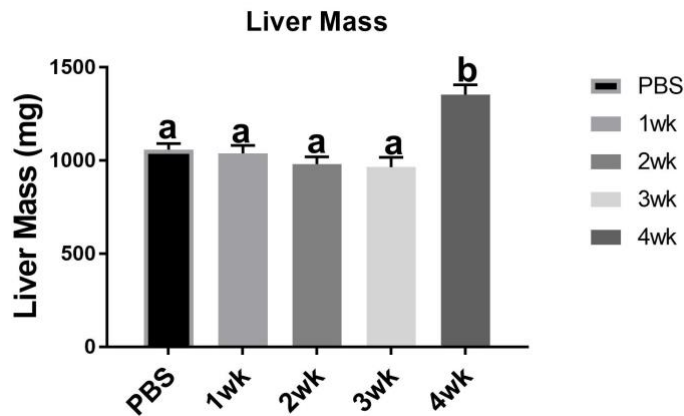


Figure B

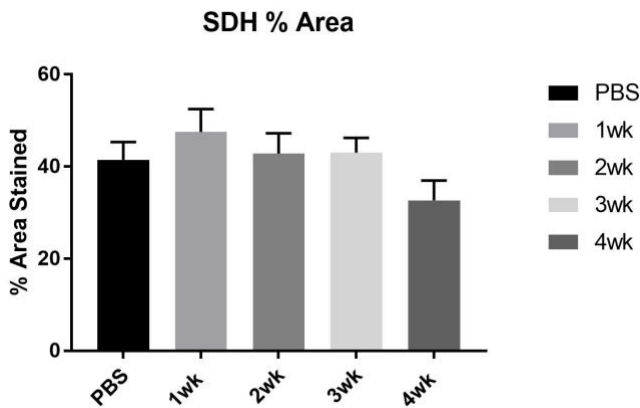


Figure C

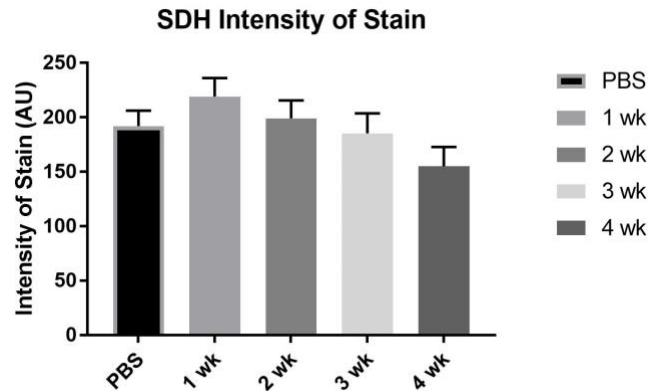


Figure D

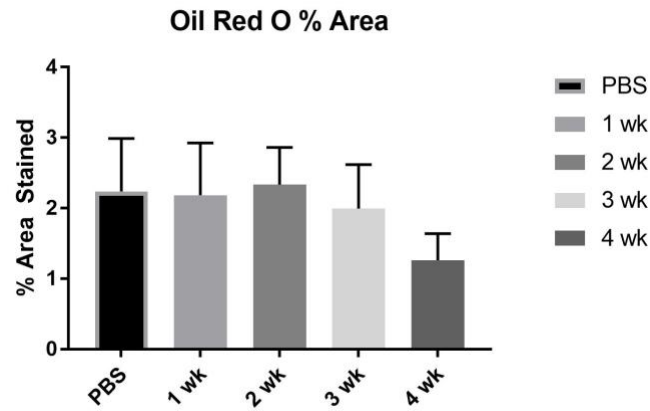


Figure E

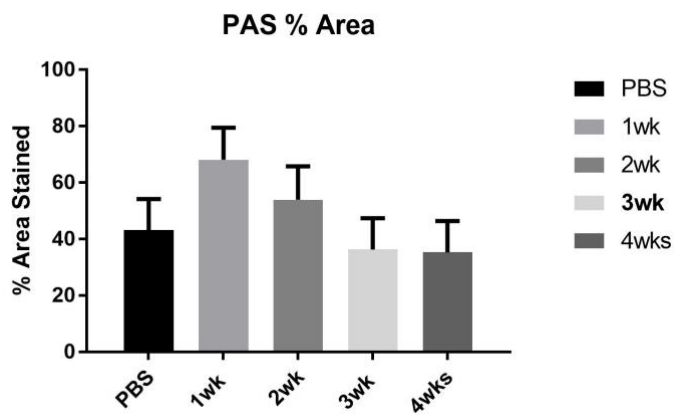


Figure F

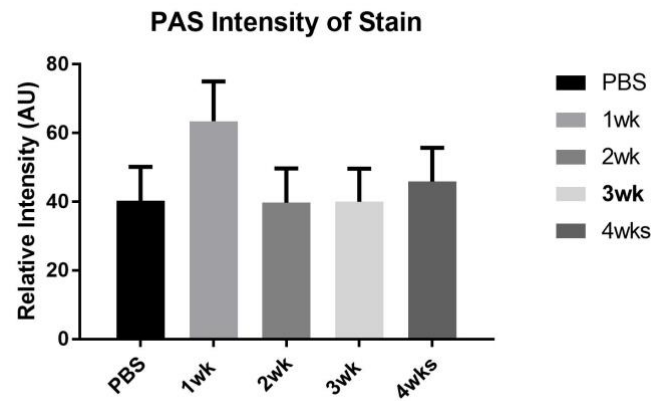


Figure A: Liver Mass from current study. Figure B: SDH % Area. Figure C: SDH Intensity of Stain. Figure D: Oil Red O % Area. Figure E: PAS % Area. Figure F: PAS Intensity of Stain.

Discussion

In summary, our results suggest that liver hypertrophy occurs over progression of cancer. Overall, our results did not reveal differences in cancer cachexia progression with regards to hepatic oxidative phenotype or lipid content, but did show slight differences in glycogen content. Though our results did not reveal what was originally hypothesized, it is important to continue researching the mechanisms behind cancer cachexia. The more we know about the contributing metabolic processes, the more we can do to manage cachexia, and as a result try to prevent the physical effects and diminished quality of life resulting from cachexia.

Our data suggest that there were no differences in each of the variables we investigated. When trying to understand liver phenotype and cancer cachexia, our results suggest that these variables may not be attributable to progression of cancer cachexia. Though there were some differences found between 3 wk and 1 and 2 wk animals in percent area stained for glycogen, it is difficult to say there is a relationship without more data for support. In order to understand liver phenotype, it may be beneficial to look further into glycogen content and into other processes in the liver that may contribute to liver hypertrophy and cancer cachexia.

Though our results do not suggest a relationship between progression of cancer cachexia and hepatic oxidative phenotype, lipid and glycogen content, there were some limitations that may have affected our results. The sample size was based off of a previous study done by Brown et al, but it is feasible that our study was underpowered, therefore affecting our anticipated outcome. Additionally, our analyses focused purely on histochemical analyses of lipid and glycogen contents and did not measure specific concentrations nor turnover of these metabolites, therefore it is possible that we were unable to measure such alterations using these techniques.

In summary, differences in liver sizes do not appear to be attributable to alterations in glycogen storage, oxidative phenotype or lipid content. Though there were no differences found, the increase in liver size suggests disruption of other processes in the liver. To our knowledge, this is the first investigation to attempt to demonstrate correlation between liver metabolic processes and cancer cachexia. Therefore, our study adds to current knowledge about and to underlying mechanisms related to cancer cachexia. For future projects, we will further investigate mechanisms of hepatic hypertrophy in order to determine the relationship between the liver and cancer cachexia progression.

References

1. Annibaldi A, Widmann C. Glucose Metabolism in cancer cells. *Current Opinion in Clinical Nutrition and Metabolic Care*. 2010; 13(4), 466-470.
2. Argilés JM, Busquets S, Stemmler B, López-Soriano FJ. Cancer cachexia: understanding the molecular basis. *Nature reviews. Cancer*. 2014; 14(11), 754-762.
3. Argilés JM, Busquets SI, López-Soriano FJ. Metabolic interrelationships between liver and skeletal muscle in pathological states. *Life Sciences*. 2001; 69(12), 1345-1361.
4. Argilés JM, Stemmler B, López-Soriano FJ, Busquets S. Nonmuscle Tissues Contribution to Cancer Cachexia. *Mediators of Inflammation Journal Article 182872*. 2015.
5. Brown JL, Rosa-Caldwell ME, Lee DE, Blackwell TA, Brown LA, Perry RA, & Washington TA. (2017). Mitochondrial degeneration precedes the development of muscle atrophy in progression of cancer cachexia in tumour-bearing mice. *Journal of cachexia, sarcopenia and muscle*, 8(6), 926-938.
6. Choi E, Carruthers K, Zhang L, Thomas N, Battaglino RA, Morse LR, Widrick JJ. Concurrent muscle and bone deterioration in a murine model of cancer cachexia. *Physiological Reports*. 2013;1(6), e00144.
7. Das SK, Eder S, Schauer S, Diwoy C, Temmel H, Guertl B, Hoefler G. Adipose triglyceride lipase contributes to cancer-associated cachexia. *Science*. 2011; 333(6039), 233-238.
8. Dumas JF, Goupille C, Julienne CM, Pinault M, Chevalier S, Bougnoux P, Servais S, Couet C. Efficiency of oxidative phosphorylation in liver mitochondria is decreased in a rat model of peritoneal carcinosis. *Journal of hepatology*. 2011; 54(2):320-7.
9. Fearon K, Glass CH, David J, Guttridge DC. Cancer Cachexia: Mediators, Signaling, and Metabolic Pathways. *Cell metabolism*. 2012;16, 153-166
10. Fearon K, Strasser F, Anker SD et al. Definition and classification of cancer cachexia: an international consensus. *The Lancet. Oncology*. 2012;12, 489-495
11. Ferreira, LMR. Cancer metabolism: The Warburg effect today. *Experimental and Molecular Pathology*. 2010;89(3), 372-380.
12. Iwata Y, Suzuki N, Ohtake H, Kamauchi S, Hashimoto N, Kiyono T, Wakabayashi S. Cancer cachexia causes skeletal muscle damage via transient receptor potential vanilloid 2-independent mechanisms, unlike muscular dystrophy. *Journal of cachexia, sarcopenia and muscle*. 2015.
13. Lee DE, Brown JL, Rosa-Caldwell, ME, Blackwell TA, Perry RA, Brown LA, Wiggs MP. Cancer Cachexia-Induced Muscle Atrophy: Evidence for Alterations in microRNAs important for Muscle Size. *Physiological Genomics*, physiolgenomics-00006. 2017.
14. Narsale AA, Enos RT, Puppa MJ, et al. Liver Inflammation and Metabolic Signaling in ApcMin/+ Mice: The Role of Cachexia Progression: e0119888. *Journal Article*. 2015; 10(3).
15. Nguyen P, Leray V, Diez M, Serisier S, Le Bloc'h J, Siliart B, Dumon H. Liver lipid metabolism. *Journal Of Animal Physiology and Animal Nutrition*, 2008;92(3), 272-283.
16. Nutrition in Cancer Care. (n.d.). Retrieved March 28, 2017, from <https://www.cancer.gov/about-cancer/treatment/side-effects/appetite-loss/nutrition-hp-pdq#section/all>

17. Petruzzelli M, Wagner EF. Mechanisms of metabolic dysfunction in cancer-associated cachexia. *Genes & development*. 2016;30(5), 489.
18. Rector RS, Thyfault JP, Uptergrove GM, Morris EM, Naples SP, Borengasser SJ, Ibdah JA. Mitochondrial dysfunction precedes insulin resistance and hepatic steatosis and contributes to the natural history of non-alcoholic fatty liver disease in an obese rodent model. *Journal of hepatology*. 2010;52(5), 727-736.
19. Siegel RL, Miller KD, Jemal A. Cancer statistics, 2016. *CA: A Cancer Journal for Clinicians*. 2016; 66(1), 7-30.
20. Thompson SW, Hunt RD. Selected histochemical and histopathological methods.
21. Tisdale, M. J. (2009). Mechanisms of Cancer Cachexia. *Physiological Reviews*. 1966;89(2), 381-410.
22. Tsoli M, Swarbrick MM, Robertson GR. Lipolytic and thermogenic depletion of adipose tissue in cancer cachexia. In *Seminars in cell & developmental biology*. 2016;(Vol. 54, pp. 68-81). Academic Press.
23. Wang H, Lai YJ, Chan YL, Li TL, Wu CJ. Epigallocatechin-3-gallate effectively attenuates skeletal muscle atrophy caused by cancer cachexia. *Cancer letters*. 2011; 305(1), 40-49.