

Clinical, Functional and Structural Studies of Humans and Merino Sheep Corneas from Two Different Regions of Argentina

María Fernanda Suárez¹, Nicolás Crim², Rodolfo Monti², Evangelina Espósito², Julio Alberto Urrets-Zavalía^{2§}, Horacio Marcelo Serra^{1§,*}

¹Department of Clinical Biochemistry, CIBICI, Faculty of Chemical Science, National University of Córdoba, Argentina

²Department of Ophthalmology, University Clinic Reina Fabiola, Catholic University of Córdoba, Argentina

§These authors equally contributed to this work

*Corresponding author: Horacio Marcelo Serra, Department of Clinical Biochemistry, CIBICI, Faculty of Chemical Science, National University of Córdoba, Haya de la Torre esquina Medina Allende; 5000, Córdoba, Argentina, Tel +54 351 4344973; E-mail: hserra@fcq.unc.edu.ar

Received date: Sep 26, 2015; Accepted date: Nov 28, 2015; Published date: Dec 01, 2015

Copyright: © 2015 Serra HM, et al. This is an open-access article distributed under the terms of the Creative Commons Attribution License, which permits unrestricted use, distribution, and reproduction in any medium, provided the original author and source are credited.

Abstract

Objective: The purpose of our work was to study and compare the cornea and tear film of people and sheep inhabiting in a region of Argentinean Patagonia (PATG), and in a geographically and climatically different region in the Argentinean Pampa (CAPT).

Methods: Using cross sectional study, corneal examinations were performed in people and Merino sheep inhabiting PATG and CAPT regions, respectively. All people completed a questionnaire related to work activity, diet, and the use of hats or sunglasses during their life. Eyes from all participants were examined with a portable hand-held slitlamp biomicroscope (BM) to evaluate corneal appearance, epithelium integrity, and transparency. Later on, in a subgroup of participants we studied eyeblinking frequency (EBF), ocular surface staining (FS), breakup time (BUT), Schirmer Tear Test (STT), corneal structure using confocal laser scanning microscopy (CLSM) and light microscopy (LM), and concentrations of serum ascorbate (sAA).

Results: BM studies revealed numerous cases of Climatic Droplets Keratopathy (CDK) only in people inhabiting the PATG region. CLSM studies confirmed typical punctiform deposits at the Bowman's layer in CDK patients living in that region. CLSM images from sheep did not show any abnormalities at the Bowman's layer but exhibited small hyper reflective dots at the epithelium only in animals pasturing in the PATG region. FS and EBF mean values were significant higher in sheep grazing in the PATG region ($p < 0.05$). No differences were found in surface eye tests when people from both regions were analyzed. Low sAA levels were found only in CDK people living in PATG region.

Conclusions: CDK is a multi-factorial disease not only associated to harsh climate. We provide data that low sAA levels can play a role in its genesis in Patagonia patients'... Sheep pasturing in this region with a high prevalence of CDK have high concentration of sAA and did not present any sub epithelial corneal abnormalities.

Keywords: Climatic Droplet Keratopathy; Corneal degeneration; Argentinian Patagonia; Argentinian Pampa; Human; Sheep; Ocular surface

Introduction

CDK is a degenerative and potentially handicapping human corneal disease suffered by people living in particular places around the world. This disease is characterized by slow progression of corneal opacity. The first description of a corneal disease that may have been CDK was made in 1898 by Baquis [1] and three decades later by Lugli [2]. Since then, different descriptions of this disease have been made in different parts of the world characterized by constant winds, low humidity, and chronic exposure to ultraviolet radiation (UVR). Although we have made some significant advances towards the understanding of CDK pathogenesis over the past few years, we still lack detail of molecular events taking place during CDK onset and progression [3]. The decrease of corneal antioxidant protective mechanisms results in oxidative injury of the cornea and causes damage by UVB rays and by reactive oxygen species generated by them. Ascorbic acid (AA) is one

of the molecules which have an important role in the control of oxidative stress and therefore prevent molecular abnormalities that can be produced in the cornea [4].

We have found CDK and performed some ophthalmological studies on individuals who work out in the open as sheep herders during much of the day and throughout the year in a region of the Argentinean Patagonia (El Cuy Department, Province of Río Negro) [5,6]. The Patagonia region is recognized as one out of three geographically and climatically distinct sheep-breeding regions in Argentina, being the Pampa and Puna the other two areas.

The objectives of this work were: a) to study the prevalence of CDK in an area of El Cuy department, Province of Río Negro, in the Argentinean Patagonia, and in a climatically different region of the Argentinean Pampa (area of the Capital department in the Province of Córdoba); b) To investigate if adult sheep grazing in these Argentinean regions have any subepithelial degenerative cornea disorder similar to CDK; c) to determine serum AA (sAA) concentrations in humans and sheep from both areas and d) to perform different ocular surface tests as well as structural studies of the epithelium and sub epithelial

portions of the corneas in both groups of people and animals in order to assess differences between them, if any.

The sheep cornea and tear film data reported in this study will probably benefit vets by enhancing the diagnostic accuracy of ophthalmic corneal diseases in these animals since there is not too much information about ovine anterior eye structures [711].

Materials and Methods

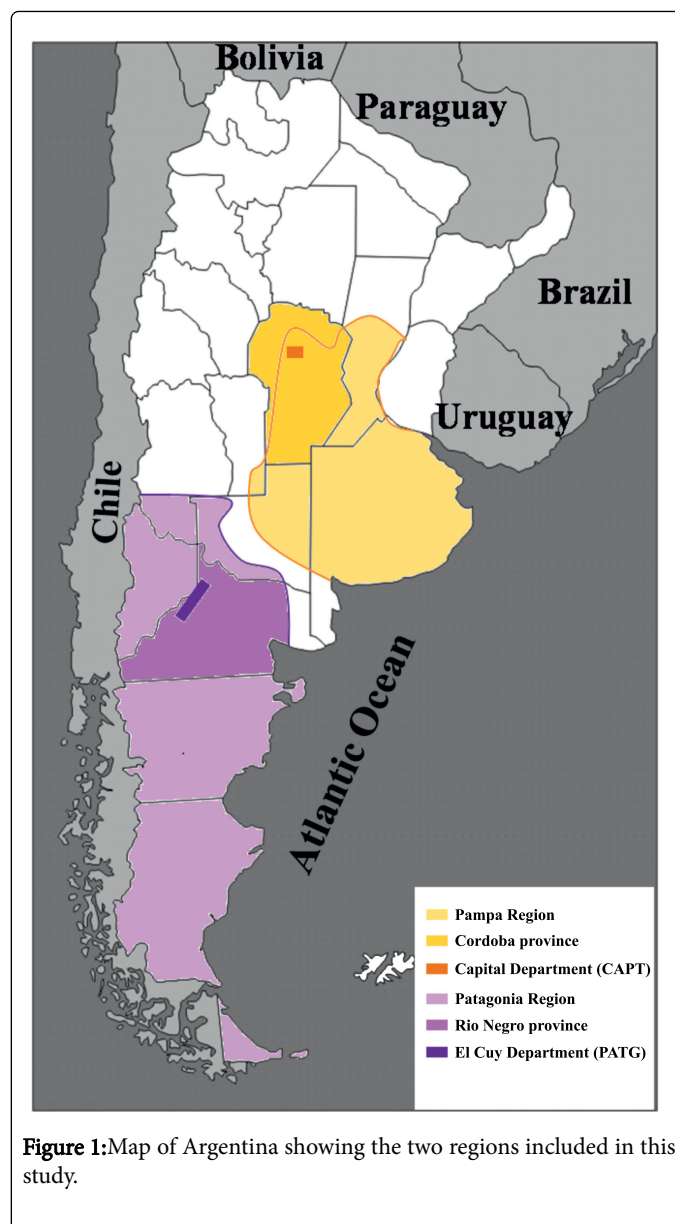
Study design and participants

A cross-sectional study was carried out in individuals older than thirty years who live during their entire life in El Cuy department, Province of Río Negro, of Patagonia region (PATG), n=110; or in the Capital department, Province of Córdoba, of the Pampa region (CAPT), n=102. This investigation was approved by the Institutional Review Board of the Catholic University of Córdoba, and the Institutional Research Ethics Committee of Health, Ministry of Health of the Province of Córdoba, Argentina (recorded in the RePIS), and carried out in accordance with the principles of the Statement of Helsinki. Non probabilistic consecutive patients read a summary of the research project, agreed to take part in the study, signed a written consent, were examined by specialists in ophthalmology and a blood sample were collected.

On the other hand healthy female Argentinean Merino sheep aged 5 to 7 years old from the two regions were also included in this study. Ninety animals grazed in the PATG region and 80 animals in the CAPT area. In each region we studied sheep from two farms. All procedures were in accordance with the Association for Research in Vision and Ophthalmology (ARVO) Statement for the Use of Animals in Ophthalmic and Vision Research.

Regions

The geographic localization of the PATG and CAPT regions is shown in figure 1. The PATG region is located in the central area of the Province of Río Negro, northern Patagonia, Argentina, at 750 meters above sea level, 67° 54'69" 04' west longitudes and 38° 56'40" 25' south latitude. It is situated at 280 kilometers to the west border and 300 kilometers from the Atlantic Ocean. This region has a cold semiarid climate (Bsk, KöppenGeiger climate classification) [12], with annual rainfall being less than 190 mm, strong winds, hot summers and cold winters, great temperature variations between day and night, and low and shrub vegetation. The annual mean temperature range in this region of Patagonia is 4.6-18.2°C. The CAPT region is located in the central part of Argentinean Pampa, Córdoba Province, at 450 meters above sea level, 64° 11'64"82' west longitude, and 31° 18'31" 34' south latitude. It has a temperate semihumid climate (Cwa: KöppenGeiger climate classification) [12], with annual rainfall being 500 mm. The summers have hot days and cool nights, and winters are generally dry, not overly cold. The average temperature is between 16 and 17°C, and the annual amplitude is from 14 to 15°C. Winds from the east and west are rare but in spring strong winds blow from the north. In summer there are frequent storms.



Ocular surface studies

At initiation of the study people from both regions answered to a questionnaire related to diet, work activity, and the wear of eye protection from their early adulthood until that day, and their eyes were examined with a portable handheld slitlamp biomicroscope (Led Slit Lamp XL1, Shin Nipon, Ohira Co., Niigata, Japan) by specialists.

Next, ocular surface tests were performed on 20 CDK patients from PATG region and 20 individuals from the CAPT region selected at random. The first test measured eye blink frequency (EBF) for 1 minute immediately prior to the other test. A second test was fluorescein staining (FS) to evaluate epithelium integrity, followed by breakup time (BUT); those were evaluated as previously described. [5] FS was recorded on a 4point subjective scale

(i.e. 0=no colorant uptake; 1=discrete uptake; 2=moderate uptake; 3=marked uptake). The values of tear production were measured by STTI in sheep or STTII in human as previously described [10,6].

In vivo CLSM structural studies were performed in three patients with different grades of CDK (PATG region), three individuals from CAPT region, and ex vivo CLSM studies were also done in three sheep from each region, selected at random. The central corneas were examined with a Rostock Cornea Module/Heidelberg Retina Tomograph II (Heidelberg Engineering GmbH, Heidelberg, Germany) as previously described [13,14]. Images through all layers of the central cornea were obtained, digitally stored and then analysed using image processing and analysis software programs as previously described [14]. Light microscopy studies were performed in corneal specimens as previously described [13].

Ascorbate serum concentration

The levels of serum ascorbate (sAA) were studied in the same twenty randomly selected participants (humans and sheep) from each region by high performance liquid chromatography [15].

Data analysis

Since there were not significant differences between right and left eyes measurements for all the studies, we performed the analysis with values from the left eyes in order to avoid inflation of the degree of freedom. Mean and standard error of the mean (SEM) were calculated. The ocular surface tests values from the two groups were compared using multivariate analysis of variance, and each variable was then analyzed separately using binomial logistic regression, ManWhitney or Student t test. The sAA data were analyzed using Student t test. The Infostat software 2014 was used to analyse data and the level of statistical significance was set at $p \leq 0.05$.

Results

At initiation of the study, both eyes of the 110 individuals and 90 animals inhabiting in an area of the Patagonia region (PATG), and 102 individuals and 80 animals living in an area of the Pampa region (CAPT), were examined with a portable handheld slitlamp biomicroscope. As it can be seen in table 1, twenty five individuals living in PATG region (22.7%) have CDK characterized by the typical deposits under the epithelium. By contrast, sheep corneas from the same region were transparent and none of them showed sub epithelial opacities, or signs similar to CDK. In addition, no abnormalities were found in corneas from patients or sheep inhabiting in an area of the central Argentinean Pampa (CAPT).

Participants REGION #	People PATG (n=110)	People CAPT (n=102)	Sheep PATG (n=90)	Sheep CAPT (n=80)
Age range (years)	(31-88)	(31-81)	(5-7)	(5-7)
Mean ± SD	56 ± 12	53 ± 11		
Gender (M/F)	(72/38)	(61/41)	0/90	0/80
Corneas with deposits beneath the epithelium	50	0	0	0

Table 1: Abnormal deposits beneath the corneal epithelium.

Ocular surface tests were performed on participants selected at random from each region, and there were not significant differences between right and left eyes measurements for all the studies.

Tests groups	Eye Blinking Frequency (Blink/min)	Breakup time (seconds)	Schirmer tear test I (mm)
Sheep PATG n=20			
(Mean ± SEM)	10.7 ± 0.3 ^a	8.2 ± 0.2 ^b	22.3 ± 0.6 ^c
(range)	(8-15)	(6-10)	(15-30)
Sheep CAPT n=20			
(Mean ± SEM)	9.3 ± 0.2	8.4 ± 0.2	20.4 ± 0.5
(range)	(7-14)	(6-12)	(16-27)
Tests groups	Eye Blinking Frequency (Blink/min)	Breakup time (seconds)	Schirmer tear test II (mm)
People PATG (CDK) n=20			
(Mean ± SEM)	ND	9.2 ± 0.7 ^e	10.1 ± 0.4 ^f
(range)		(6-14)	(8-14)
People CAPT n=20			
(Mean ± SEM)	ND	10.3 ± 0.5	11.6 ± 0.6
(range)		(7-15)	(8-17)

ND: No done. Sheep PATG vs. sheep CAPT. ^a: p= 0.04; ^b: p= 0.60; ^c: p= 0.27. Individuals PATG (CDK) vs. individuals CAPT. ^e: p= 0.33; ^f: p= 0.15.

Table 2: Ocular surface tests.

Each ocular surface tests from the two human and two sheep populations were compared and analyzed separately. All participants showed a FS score > 0 with punctates or linear superficial erosions, but the mean values were significant higher in people and sheep from the PATG region (p <0.001). Table 2 summarized data of the other ocular surface tests from both groups of participants.

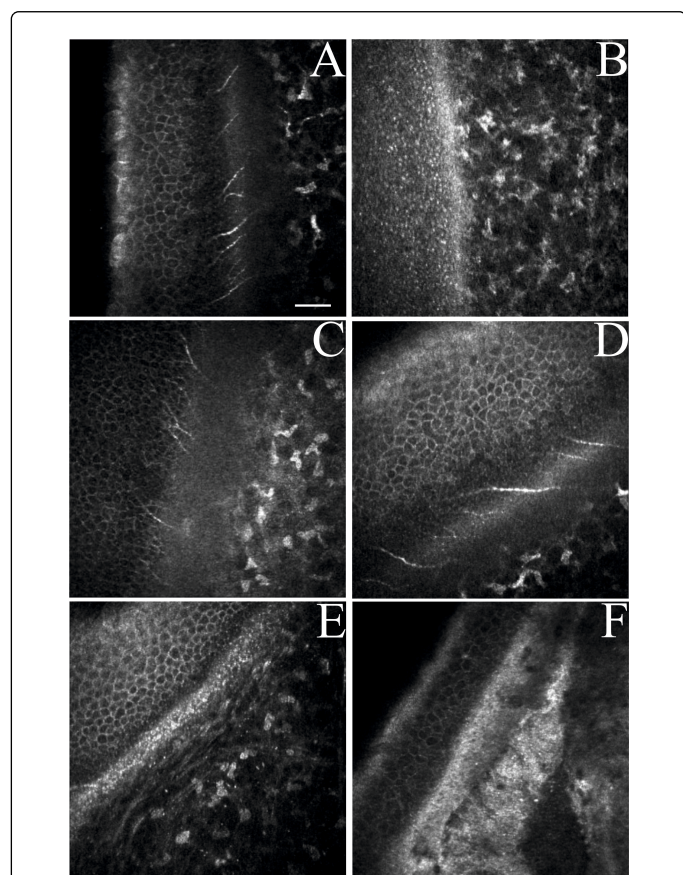


Figure 2: Confocal laser scanning microscopy representative images of oblique sections of sheep and human corneas showing the epithelium, Bowman's layer, and anterior stroma. (A) Normal appearance of the sub epithelial area in sheep pasturing the Argentinean Pampa (CAPT); (B) numerous hiperreflective dots in the epithelium of sheep's cornea pasturing the Patagonia region of Argentina (PATG); (C) Normal human cornea (CAPT) shows absence of sub epithelial hyperreflective deposits; (D) CDK grade 1 shows reflective punctiform or dot like deposits at the Bowman's layer level; (E) CDK grade 2 shows increased density of the hyper reflective punctate deposits in the Bowman's layer and superficial stroma; (F) CDK grade 3 shows condensation of punctiform hyper-reflective deposits and large globular non reflective deposits in the Bowman's layer and superficial stroma. (C, D, and E) are representative images from CDK patients from PATG region. Original magnification: (400 400 m). Bars = 50 m.

Mean for EBF was also significant higher in animals from the PATG region (p=0.04). The means values for BUT and STT1 did not show any significant differences between both groups of animals (p=0.60 and p=0.27, respectively); and between CDK patients and people inhabiting in CAPT region (p=0.33 and p=0.15, respectively).

Representative CLSM oblique images of the epithelium and sub epithelial zones of sheep cornea from PATG and CAPT regions, and of human corneas with and without CDK (PATG and CAPT regions, respectively) are shown in figure 2. The CLSM studies showed differences between both groups of sheep only in the epithelium. The intermediate and basal cell epithelial layers did not show any abnormality in sheep pasturing the CAPT region (Figure 2A), whereas small hyper reflective dots could be seen at this layer in PATG animals (Figure 2B). Deposits in the Bowman's layer and in the superficial stroma were found on CDK human specimens but not in any animals (from both studied areas) or human corneas from CAPT region (Figure 2D, 2E, and 2F). CLSM studies also showed no differences in stroma and endothelium among eyes participants of both groups (data not shown).

Light microscopy studies performed in the same corneas used for CLSM from animals of both regions did not present any abnormal deposits beneath the epithelium, like the ones observed in a CDK corneal specimen. Representative images are shown in figure 3.

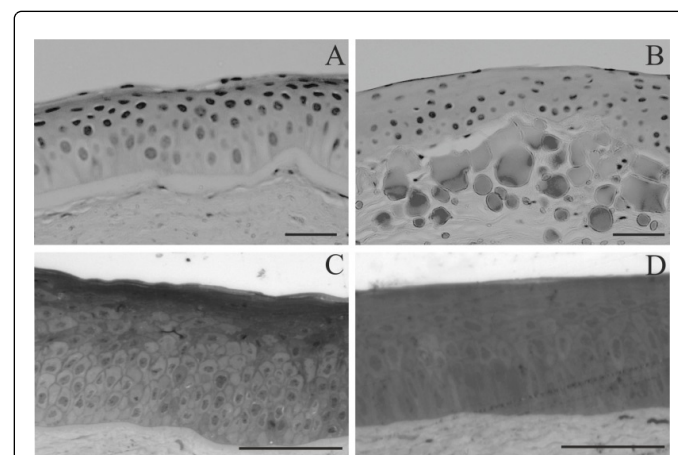


Figure 3: Light microscopy images of corneal epithelium and anterior stroma specimens from: A) Normal human cornea; B) CDK; C) sheep from PATG region; D) sheep from CAPT region. Bars=30 m (A and B); bars=100 m (C and D).

There were not significant differences in the levels of sAA found in the sheep grazing in PATG and CAPT regions (0.64 mg/dl±0.12, and 0.72 mg/dl±0.15, respectively). These amounts of sAA were similar to the concentrations found in individuals leaving in the CAPT region.

As can be seen in table 3 the main dietary habits of individuals in the PATG region are the consumption of mutton and its entrails ingested many times a day, with very scarce amounts of milk, vegetables and fruits taken sporadically. In contrast, individuals

inhabiting CAPT region have a more balanced diet consisting of different animal's meat, vegetables, cereals and its byproducts, dairy products and fruits. Dietary deficiency in foods rich in AA was reflected in the low sAA levels found in the individuals with CDK

living in PATG region $0.21 \text{ mg/dl} \pm 0.09$). These concentrations of sAA differed significantly ($p < 0.05$) from individuals inhabiting in CAPT region ($0.94 \text{ mg/dl} \pm 0.22$).

Diet	Water	Artificial juices	Infusion	Poultry meat, its entrails and/or its byproducts	Beef,	Pork,	Mutton, its entrails and/or its byproducts	Dairy products	Vegetables	Cereals and/or its byproducts	Fruits
People from PATG region	+++	±	++ (Yerba mate)	-	-	-	+++	±	-	-	±
CAPT region	+++	++	++ (Yerba mate, tea, and coffee)	+	++	+	-	++	++	++	++

: Never; ±; Rarely; + : Sometimes; ++: Normally; +++: Always

Table 3: Summary of questionnaire about diet.

Individuals in PATG region are mainly dedicated to sheep farming and sheep shearing during 78 hours per day and throughout the year without wearing any eye protection (hat, cap, sun glasses, while individuals in the CAPT region work 78 hours during 6 days in the week with 45 days of vacations during the year on different jobs but most of them are indoor activities (factories, stores, etc), and they do not wear eye protections any time during the year.

Discussion

The purpose of our study was investigate the presence of CDK and establish the prevalence of this corneal disease in individuals inhabiting two climatically different regions in Argentina and provided a description on the corneal structure and tear film in these individuals as well as in sheep pasturing the same regions. One of the regions is the northwest area of the Patagonia (PATG) which has a cold semiarid climate or steppe climate. The other region is part of the Pampa region (CAPT) which has a Mediterranean climate because it is in a temperate zone of central Argentina.

CDK has been defined as a rural disease in which the clinical presentation and severity of corneal injuries can vary significantly depending on the region and its weather. Although globular deposits in the anterior layer of the corneas with CDK were described many years ago using optical and transmission electron microscopy, [16,17] more recently, these anomalies have been further characterized by us using CLSM. [18] As CDK is an ocular surface disease and the analysis of the tear proteins may result in further understanding of this disease, we studied tears glycoproteins in CDK patients using glycopeptide capture techniques and proteomics. Our results suggest that the enzymatic glycosylation may also be involved in the formation of deposits in CDK, since altered levels of Nglycosylation of certain proteins were observed in the tears of patients with CDK [19].

We have also investigated matrix metalloproteinases (MMPs) and their inhibitors, TIMP, in patients with CDK, because these molecules control the degradation of the corneal epithelium and stroma. We showed increased levels of gelatinases and pro inflammatory cytokines, as well as decreased expression of TIMP1 in tears and biopsies of patients with CDK. Similar results were obtained when corneal epithelial cells were exposed to UVR *in vitro* [20,21]. This data suggests that the pathogenesis of this disease is partly driven by a significant inflammatory response with the poor antiproteolysis shield making the cornea more vulnerable to increased levels of MMPs. We have also shown that in patients with CDK a hypersensitive reaction occurred in the cornea with the initial participation of important pro inflammatory components of the innate immune system [22].

Based upon these results our hypothesis about the genesis of CDK was that in the cornea of those people chronically exposed to unfavorable climatic conditions (dry climate with windy conditions, airborne particle bombardment, and prolong exposure to UVR, an inflammatory processes lead to a progressive degradation and accumulation of proteinaceous material in Bowman's membrane and the superficial stroma.

It is well known that corneal exposure to UVR can induce altered proteins, DNA fragmentation, free radical generation, and lipid peroxidation, affecting primarily the anterior segment of this tissue. But fortunately high content of some proteins, and AA in the corneal epithelium function as a filter, by absorbing a high proportion of UVR dangerous wavelengths [23].

Our studies revealed numerous cases of CDK in individuals inhabiting the PATG region but no cases of the disease in individuals from the CAPT region who are not exposed to harsh environmental conditions. The analysis of individuals' dietary habit from both regions clearly showed a marked difference among them. In contrast to the individuals inhabiting CAPT region who have normal concentration of sAA as the result of a balance diet, people living in PATG region have

low sAA levels since almost exclusively the main food source for them is the sheep meat.

When we studied old adult sheep that graze in the same region of Patagonia where we detected high prevalence of CDK (and therefore these animals were exposed to the same environmental conditions as patients with this disease) it was found that, despite having superficial corneal abrasions, the animals cornea did not have any other structural abnormality such as the sub epithelial proteins accumulation observed in CDK patients. It is worth to note that the sAA levels detected in sheep from both regions of Argentina were similar to the concentrations of this vitamin found in normal human sera. Sheep are able to synthesize AA from the grass they eat and the sAA is concentrated into the animal's cornea where it plays critical and multifaceted roles in protecting this part of the eye from oxidative stress, such as the one produced by prolonged exposure to UVR [23].

Bats, guinea pigs and primate anthropoids, including humans, have lost the ability to synthesize AA as a result of mutations of Lgulonoy-lactone oxidase (GULO) genes, and this powerful anti-oxidant must be incorporated in the diets of these species [24]. This explains why people in the PATG region have very low content of sAA due to the fact that their diet is very restricted and poor in this vital anti-oxidant (Table 3).

This part of the work corroborates evidences (recently reviewed by us) that CDK is a multifactorial disease associated to particular climatic conditions and prolonged exposure to UVR [3]. It is also possible that other contributing factor in the genesis of this corneal degenerative disease is a deficiency of AA. This is support by some data presented here and by other work we did published on September in which we documented the beneficial effect of diets rich in AA and / or an adequate eye protection with sun glasses or hats in preventing development of CDK in different Argentinean human populations exposed to similar climatic conditions and working in outdoor activities most of the day for many years of their life [25].

In the current paper we also investigated different parameters of sheep cornea to search for any abnormality in these animals pasturing regions with different environmental conditions. To the best of our knowledge, there is a scarcity of anatomical and clinical information regarding the anterior segment of the ovine eye. The first description of the orbit, ocular adnexa, eye globe and eyelid in sheep was reported by Prince et al. [7] Galán et al. [26] reported similarities and differences in the ocular fundus between sheep and goat eyes. The use of a topical endoscopic technique allowed Guyomard et al. [9] to view the anterior segment, the iridocorneal angle and the posterior segment in eyes of sheep and other animal species. After the first report of sheep cornea by Prince et al. [7]; Scott and Bosworth [8] provided a comparative biochemical and ultrastructural examination of corneal proteoglycan-collagen interactions between sheep and other species. Recently, the expression levels of the tolllike receptors (TLRs) 110 mRNA in the corneal epithelial cells of various ruminants, including sheep, have been assessed [27]. More recently Reichard et al. [28] studied the cornea anatomy using CCFM of different laboratory animals including only one Pomeranian Coarsewool sheep, and Ghaffari et al. [10] established reference values for Schirmer Test and intraocular pressure in the Sanjabi sheep.

Our initial results using in vivo slitlamp BM examination indicated a transparent cornea in all animals from both regions. BUT mainly evaluates the lipid and the mucous layers of the tear film [29]. The lipid layers have been correlated with this tear film stability with increased

BUT implying a low rate of evaporation [3031]. Since no information about ocular surface mucins in sheep is available, we used the BUT functional test to indirectly evaluate the presence of lipid substances or mucin that would be correlated with evaporation.

Our BUT values did not show any differences between animals grazing in the Pampa and the Patagonia regions, and BUT values were much shorter than those for other species [32]. It could be arguing that this short BUT may have placed sheep at higher risk for corneal ulceration. However, no corneal ulceration was observed in any animals, supporting the fact that sheep have efficient corneal protective mechanisms such as the nictitating membrane and high concentrations of lysozyme [33].

The tear film, composed of lipid, aqueous and mucin, has different roles such as nutritional, protective, and specific antibacterial and immune functions [29,3435]. Royle et al. [36] when comparing the structure of the Olinked glycans derived from the ocular mucins of rabbit, dog and human, demonstrated a speciespecific glycan expression, with implications for the defensive properties when different microbial and environmental challenges are encountered. The blinking activity maintains the physiological thickness of the precorneal surface by homogeneously distributing a tear film over the corneal and conjunctival surface. EBF in dogs is 3–5 times/min; in cats: 1–5 times/ 5 min; in horses: 5–25 times/min, in cattle: 5 times/min, [37] and in pigs 10 times/min. [38] Comparable to cattle, we reported here that sheep blinked 715 times/ min. Moreover we found that in the PATG region animals blink more frequently than in the CAPT region ($p=0.04$). The FS showed more quantity of erosions in eyes corneas from PATG animals ($p<0.001$). The significant differences in FS and EBF could be attributed to the harsh environmental conditions of the Patagonia region, which is characterized by low humidity and strong winds that conveys many of the arid soil particles as opposed to the Pampa region, which is characterized by temperate climate and a higher humidity.

The STTI has been widely used for evaluation of the basal and reflex tear production. Results can vary depending in the location and absorptive capacities of strips and the individual performing [3940]. The STTI mean values were comparable in both groups of Merino sheep grazing in different areas of Argentina ($p=0.27$), and were very similar to those reported in the Sanjabi sheep [10,26].

CLSM has become a useful tool during recent years for cornea examination of human as well as other animal species. [14,28,4142] As far as we know this is the first CLSM study of sheep corneas showing differences in epithelium in animals grazing in an area with extreme environmental conditions such as the Patagonia region in Argentina. As it can be seen in figure 2 (A, and B) only sheep inhabiting in this region displayed small hyper reflective dots. These abnormalities are in agreement with our finding of more quantity of erosions in corneas from PATG animals. In contrast to human corneas with CDK (Figure 2 D, E, F) there were not any abnormalities in the Bowman layer and superficial stroma in sheep from any region or human corneas from CAPT region (Figure 2 A and 2B; figure 3 A, 3C and 3D).

In conclusion our study provides data for prevalence of CDK as well as external eye testing in individuals inhabiting two climatically different Argentinean regions. We also report values for FS, EBF, STTI, and BUT in Argentinean Merino sheep, which will increase the knowledge about the ophthalmological aspect of this animal, allow the establishment of reference values for ocular surface tests, and benefit vets, since it is worth to mention that we have found differences in

some of these tests between sheep pasturing in PATG vs. CAPT regions. Moreover we found that sheep that have lived many years in the same Patagonia region (PATG) and have been exposed to the same environmental conditions that CDK patients, despite having moderate corneal erosions and small hyper reflective dots in the epithelium, did not show any abnormalities at the sub epithelial layers as patients with CDK in the same region. The differences observed between PATG and CAPT sheep could be attributed to environmental conditions, and the lack of proteinaceous aggregated beneath the epithelium could be attributed to the fact that sheep, in contrast to CDK patients, have normal concentrations of AA which contribute to protect their corneas from oxidative stress produced by harsh environmental conditions.

Competing Interests

None of the authors of this paper has a financial or personal relationship with other people or organizations that could inappropriately influence or bias the content of the paper.

Funding Sources

FONCYT PICT: 20111846; CONICET: PIP 11220080101455; SECYTUNC (ARGENTINA).

References

1. Baquis E (1898) Die colloide Degeneration der Cornea. Ein Beitrag zur Kenntniss der Entstehung des Colloids aus epithelialen Elementen. Albrecht von Graefes Arch Klin Exp Ophthalmol 46: 553620.
2. Lugli L (1935) Degeneratio corneae sphaerularis elaioides. Albrecht von Graefes Arch Klin Exp Ophthalmol 134: 211226.
3. Serra HM, Holopainen JM, Beuerman R, Kaarniranta K, Suárez MF, et al. (2015) Climatic droplet keratopathy: an old disease in new clothes. *Acta Ophthalmol* 93: 496-504.
4. Cejková J, Stípek S, Crksovská J, Ardan T, Pláteník J, et al. (2004) UV Rays, the prooxidant/antioxidant imbalance in the cornea and oxidative eye damage. *Physiol Res* 53: 1-10.
5. Urrets-Zavalía JA, Knoll EG, Maccio JP, Urrets-Zavalía EA, Saad JA, et al. (2006) Climatic droplet keratopathy in the Argentine Patagonia. *Am J Ophthalmol* 141: 744-746.
6. Urrets-Zavalía JA, Maccio JP, Knoll EG, Cafaro T, Urrets-Zavalía EA, et al. (2007) Surface alterations, corneal hypoesthesia and iris atrophy in patients with climatic droplet keratopathy. *Cornea* 26: 800804.
7. Prince JH, Diesem CD, Eglitis I, Ruskell G (1960) *Anatomy and Histology of the eye and orbit in Domestic Animals*. Charles C Thomas Publisher, Springfield, Illinois: 182 206.
8. Scott JE, Bosworth TR (1990) A comparative biochemical and ultrastructural study of proteoglycan-collagen interactions in corneal stroma. Functional and metabolic implications. *Biochem J* 270: 491-497.
9. Guyomard JL, Rosolen SG, Paque M, Delyfer MN, Simonutti M, et al. (2008) A low cost and simple imaging technique of the anterior and posterior segments: eye fundus, ciliary bodie, iridocorneal angle. *Invest Ophthalmol Vis Sci* 49: 51685174.
10. Ghaffari MS, Shojaei M, Sabzevari A, Khorami N (2011) Reference values for intraocular pressure and Schirmer tear test in clinically normal Sanjabi sheep. *Small Rumin Res* 97: 101103.
11. Cafaro TA, Suarez MF, Maldonado C, Croxatto JO, Insfrán C, et al. (2014) On the Cornea of Healthy Merino Sheep: A Detailed Ex Vivo Confocal, Histological and Ultrastructural Study. *Anat Histol Embryol*.
12. <http://koeppeengeiger.vuwien.ac.at/shifts.htm>
13. Cafaro TA, Ortiz SG, Maldonado C, Espósito FA, Croxatto JO, et al. (2009) The cornea of Guinea pig: structural and functional studies. *Vet Ophthalmol* 12: 234-241.
14. Al-Aqaba MA, Alomar T, Miri A, Fares U, Otri AM, et al. (2010) Ex vivo confocal microscopy of human corneal nerves. *Br J Ophthalmol* 94: 1251-1257.
15. Serra HM, Cafaro TA (2007) Acido Ascórbico: desde la química hasta su crucial función protectora en ojo. *Acta Bioquímica Clínica Latinoamericana* 41: 525532.
16. Garner A, Morgan G, Tripathi RC (1973) Climate dropley keratopathy. II. Pathologic findings. *Arch Ophthalmol* 89: 198-204.
17. Johnson GJ, Overall M (1978) Histology of spheroidal degeneration of the cornea in Labrador. *Br J Ophthalmol* 62: 53-61.
18. Urrets-Zavalía JA, Croxatto JO, Holopainen JM, Cafaro TA, Esposito F, et al. (2012) In vivo confocal microscopy study of climatic droplet keratopathy. *Eye (Lond)* 26: 1021-1023.
19. Zhou L, Beuerman RW, Chew AP, Koh SK, Cafaro TA, et al. (2009) Quantitative analysis of Nlinked glycoproteins in tear fluid of climatic droplet keratopathy by glycopeptides capture and iTRAQ. *J Proteome Res* 8: 19922003.
20. Holopainen JM, Serra HM, Sánchez MC, Sorsa T, Zalentein WN, et al. (2011) Altered expression of matrix metalloproteinases and their tissue inhibitors as possible contributors to corneal droplet formation in climatic droplet keratopathy. *Acta Ophthalmol* 89: 569574.
21. Holopainen JM, Robciuc A, Cafaro TA, Suarez MF, Kontinen YT, et al. (2012) Pro-inflammatory cytokines and gelatinases in climatic droplet keratopathy. *Invest Ophthalmol Vis Sci* 53: 3527-3535.
22. Serra HM, Cafaro TA, Suarez MF, Croxatto JO, Moro PA, et al. (2011) Participación de componentes inmunológicos en la etiopatogenia de la queratopatía climática esferoidea. *Archivos Argentinos de Alergia e Inmunología Clínica* 42: 4958.
23. Serra HM, Suárez MF, Espósito E, UrretsZavalía JA (2014) Vitamin C functions in the cornea: Ultrastructural features in ascorbate deficiency. In: *The Handbook of Nutrition, Diet and the Eye*. St. Louis, MO: Elsevier Saunders, 311320.
24. Drouin G1, Godin JR, Pagé B (2011) The genetics of vitamin C loss in vertebrates. *Curr Genomics* 12: 371-378.
25. Suárez MF, Correa L, Crim N, Espósito E, Monti R, et al 2015. Climatic Droplet Keratopathy in Argentina: Involvement of Environmental Agents in Its Genesis Which Would Open the Prospect for New Therapeutic Interventions. *Biomed Res Int*.
26. Galán A, Martín-Suárez EM, Molleda JM (2006) Ophthalmoscopic characteristics in sheep and goats: comparative study. *J Vet Med A Physiol Pathol Clin Med* 53: 205-208.
27. Williams KA, Brereton HM, Coster DJ (2009) Prospects for genetic modulation of corneal graft survival. *Eye (Lond)* 23: 1904-1909.
28. Reichard M, Hovakimyan M, Wree A MeyerLindenberg A, Nolte I, et al (2010) Comparative in vivo confocal microscopical study of the cornea anatomy of different laboratory animals. *Curr Eye Res* 35: 10721080.
29. Bron AJ, Tiffany JM, Gouveia SM, Yokoi N, Voon LW (2004) Functional aspects of the tear film lipid layer. *Exp Eye Res* 78: 347-360.
30. Korb DR, Baron DF, Herman JP, Finnemore VM, Exford JM, et al. (1994) Tear film lipid layer thickness as a function of blinking. *Cornea* 13: 354-359.
31. Isreb MA, Greiner JV, Korb DR, Glonek T, Mody SS, et al. (2003) Correlation of lipid layer thickness measurements with fluorescein tear film break-up time and Schirmer's test. *Eye (Lond)* 17: 79-83.
32. Gelatt KN (2007) *Veterinary Ophthalmology*. Oxford: Blackwell, 463465.
33. Gionfriddo JR, Davidson H, Asem EK, Krohne SG (2000) Detection of lysozyme in llama, sheep, and cattle tears. *Am J Vet Res* 61: 12941297.
34. Tiffany JM, Pandit JC, Bron AJ (1998) Soluble mucin and the physical properties of tears. *Adv Exp Med Biol* 438: 229-234.
35. Davidson HJ, Kuonen VJ (2004) The tear film and ocular mucins. *Vet Ophthalmol* 7: 71-77.
36. Royle L, Matthews E, Corfield A, Berry M, Rudd PM, et al. (2008) Glycan structures of ocular surface mucins in man, rabbit and dog display species differences. *Glycoconj J* 25: 763-773.

-
37. Gum GG, Gelatt KN, Ofri O (2012) *Veterinary Ophthalmology. Physiology of the eye* (3rd edn). Lippincott Williams & Wilkins, Philadelphia 151181.
 38. Gum GG (1991) *Veterinary Ophthalmology. Physiology of the eye* (3rd edn) Lippincott Williams & Wilkins, Philadelphia, 124161.
 39. Rothschild CM, Sellon DC, Bryan GM, Gay JM, Hines MT (2004) Effects of trimethoprim-sulfadiazine on tear production and the fluctuations of Schirmer tear test values in horses. *Vet Ophthalmol* 7: 385-390.
 40. Williams DL (2005) Analysis of tear uptake by the Schirmer tear test strip in the canine eye. *Vet Ophthalmol* 8: 325-330.
 41. Patel DV, Ku JY, Johnson R, McGhee CN (2009) Laser scanning in vivo confocal microscopy and quantitative aesthesiometry reveal decreased corneal innervation and sensation in keratoconus. *Eye* (London, England) 23: 586592.
 42. Labbe A, Liang H, Martin C, Brignole Baudouin F, Warnet JM, et al. (2006) Comparative anatomy of laboratory animal corneas with a new generation high resolution in vivo confocal microscope. *Curr Eye Res* 31: 501509.