

Original Investigation

Association of Cone-Rod Homeobox Transcription Factor Messenger RNA With Pediatric Metastatic Retinoblastoma

Ana V. Torbidoni, PhD; Viviana E. Laurent, MSc; Claudia Sampor, MD; Daniela Ottaviani, BS; Valeria Vazquez, PhD; Mariano R. Gabri, PhD; Jorge Rossi, PhD; María T. de Dávila, MD, PhD; Cristina Alonso, PhD; Daniel F. Alonso, MD, PhD; Guillermo L. Chantada, MD, PhD

IMPORTANCE Disseminated retinoblastoma is usually fatal. Identification of small amounts (minimal dissemination [MD]) of tumor cells in extraocular sites might be a tool for designing appropriate treatments.

OBJECTIVE To test cone-rod homeobox (CRX) transcription factor as a lineage-specific molecular marker for metastatic retinoblastoma and for evaluation of MD.

DESIGN, SETTING, AND PARTICIPANTS In a prospective cohort design study, we evaluated CRX messenger RNA (mRNA) by retrotranscription followed by real-time polymerase chain reaction as a diagnostic test in samples obtained from bone marrow, peripheral blood, and cerebrospinal fluid (CSF) at diagnosis, after induction chemotherapy, and during follow-up. The study was conducted from June 30, 2008, to June 30, 2014. Seventeen retinoblastoma primary tumors, 2 retinoblastoma cell lines, and 47 samples of bone marrow from other cancers (controls) were studied. Seventeen patients with metastatic retinoblastoma (9 at diagnosis, 8 at relapse; age range: 18-41 months) were included.

MAIN OUTCOMES AND MEASURES Detection of CRX mRNA as a marker for metastatic retinoblastoma and MD in bone marrow and CSF and its correlation with clinical findings.

RESULTS Cone-rod homeobox mRNA was expressed in all tumors (relative expression levels range, 8.1×10^{-5} to 5.6) and cell lines. In control samples, there was no amplification of CRX; only the housekeeping gene (*GAPDH*) demonstrated amplification. Bone marrow metastatic cells showed expression of CRX mRNA in all 9 children presenting with metastasis at the diagnosis (relative expression levels, 6.0×10^{-5} to 0.67). After induction chemotherapy, no evidence of MD of tumor cells was seen in any of the 8 responding children since only *GAPDH* showed amplification. In the CSF of children who had a metastatic relapse, CRX mRNA detection was positive in 2 patients in whom no conclusive results were reached by immunocytology for disialoganglioside GD2. Minimal dissemination in the CSF was associated with a clinical relapse in 2 cases. No concomitant MD was evident in the bone marrow in any case.

CONCLUSIONS AND RELEVANCE These data suggest that CRX mRNA is a novel marker for retinoblastoma at extraocular sites. In this study among patients with bone marrow metastasis, there was a quick, complete, and sustained molecular response after induction chemotherapy. In all patients with secondary metastasis, CSF relapse occurred independently from the bone marrow, suggesting a sanctuary site.

JAMA Ophthalmol. doi:10.1001/jamaophthalmol.2015.0900
Published online April 30, 2015.

Author Affiliations: Author affiliations are listed at the end of this article.

Corresponding Author: Guillermo L. Chantada, MD, PhD, Hematology-Oncology Service, Pediatric Hospital, Servicios de Atención Médica Integral para la Comunidad, Professor Dr. Juan P. Garrahan, Combate de los Pozos 1881, C1245AAM, Buenos Aires, Argentina (gchantada@yahoo.com).

Disseminated retinoblastoma is the major cause of mortality associated with this tumor worldwide.¹ Retinoblastoma may disseminate to the central nervous system (CNS) through direct optic nerve extension and/or by hematogenous dissemination.² Bone marrow is the most common metastatic site, followed by bones, liver, and other less common organs.^{2,3} Although widely recognized from the clinical point of view, little is known about the kinetics of the dissemination of retinoblastoma.⁴

To study the patterns of dissemination, the study of minimal dissemination (MD) by polymerase chain reaction (PCR) or immunocytology has become a tool in other pediatric cancers⁵; however, there have been few studies on retinoblastoma.^{6,7} One study⁷ reported that MD is more likely at diagnosis in the cerebrospinal fluid (CSF) in children with massive optic nerve invasion and glaucoma. In that study, disialoganglioside GD2 synthase was used as a molecular marker for MD. Immunocytology for disialoganglioside GD2 has been performed in bone marrow and CSF for the diagnosis of retinoblastoma.^{8,9} This technique has been used for MD detection in neuroblastoma as well.¹⁰ However, disialoganglioside GD2 may also be expressed by normal bone marrow stem cells showing background expression, limiting its specificity and sensitivity,¹⁰ and disialoganglioside GD2 is less effective for diagnostic confirmation in specimens with scant cellularity, such as CSF. Because patients with retinoblastoma carry a unique mutation of the *Rb1* gene (NCBI, reference sequence NM_000321.2), identifying cells with this mutation in extraocular sites would be unequivocal evidence of MD.⁶ However, it is more difficult to implement in settings with a high patient volume and limited resources. Since retinoblastoma derives from retinal precursors, lineage-specific markers would be more specific for the detection of tumor cells in nonocular tissues. Among these markers, cone-rod homeobox (CRX), an Otx-like homeobox transcription factor critical for photoreceptor differentiation and for maintenance of normal retinal development, has been reported¹¹⁻¹⁵ as being uniformly expressed in retinoblastoma. Given its restricted expression to photoreceptor precursors, we aimed to investigate CRX messenger RNA (mRNA) as a molecular marker not only for diagnostic evaluation but also for the evaluation of MD.

The aims of this study were to (1) evaluate the usefulness of detection of CRX mRNA using retrotranscription (RT) followed by real-time PCR in bone marrow, peripheral blood, and CSF for identification of infiltrating tumor cells in metastatic retinoblastoma; (2) assess CRX mRNA as a marker for MD to evaluate the kinetics and patterns of response to treatment and relapse; and (3) correlate this information to establish patterns of disease dissemination in different clinical scenarios.

Methods

This study, conducted from June 30, 2008, to June 30, 2014, comprised 2 phases. The first phase was validation of the marker and the detection method; the second phase was evaluation of CRX in patients. The study was approved by our institutional review board (Pediatric Hospital Servicios de Aten-

At a Glance

- Disseminated retinoblastoma is the major cause of mortality for this tumor worldwide.
- We investigated cone-rod homeobox (CRX), a transcription factor for photoreceptor differentiation by real-time polymerase chain reaction as a diagnostic marker and for minimal dissemination in retinoblastoma.
- We confirmed that CRX messenger RNA is a reliable and specific marker for retinoblastoma in extraocular sites.
- Bone marrow disease clears quickly and completely after induction therapy at a molecular level even during cerebrospinal fluid relapse.
- The cerebrospinal fluid would be a sanctuary site for occult retinoblastoma cells.

ción Médica Integral para la Comunidad Professor Dr. Juan P. Garrahan), and all procedures were performed in accordance with ethical standards and the Declaration of Helsinki. Parents/guardians signed a written informed consent form allowing the use of samples and data for research purposes. The participants did not receive financial compensation.

Validation of the Marker and the Detection Method

Expression of CRX mRNA in Retinoblastoma Cell Lines, Retinoblastoma Tumors, and Controls

We evaluated the expression of CRX mRNA in retinoblastoma cell lines Y79 and WERI-Rb1 (ATCC). In addition, we examined 17 primary ocular tumors (obtained during enucleation and stored at -70°C until analysis).

Controls

Bone marrow samples ($n = 47$) from children with cancer other than retinoblastoma that were in complete remission (eg, acute leukemia, Ewing sarcoma, histiocytosis, non-Hodgkin lymphoma, medulloblastoma, and neuroblastoma) were obtained during the same study period and used as controls. The samples were processed and evaluated under the same procedures and conditions described for retinoblastoma samples.

PCR Studies

RNA Extraction and Complementary DNA First-Strand Synthesis | Total RNA from tumors, samples of bone marrow, CSF, and peripheral blood was extracted with the phenol-chloroform method according to the manufacturer's instructions (Sigma-Aldrich). The complementary DNA was obtained by retrotranscription (50 minutes at 50°C) using 2 μg of total RNA, random hexamers, deoxynucleotides, and reverse transcriptase (Superscript III; Life Technologies).

Primers | Primers for real-time PCR were designed using the software Primer Express 1.5 (Applied Biosystems) based on the sequences from GenBank (National Center for Biotechnology Information, reference sequence for CRX mRNA, NM_000554 and for GAPDH mRNA, NM_001256799.1). For target *CRX*, the 5-3 primer forward was GAGGAGGTGGCTCTGAAGATCA and the 5-3 reverse was TTAGCCCTCCGGTTCTTGAA. For *GAPDH*, the

corresponding primers were ATGGAAATCCCATCACCATCTT and CGCCCCACTTGATTTTGG.

Cerebrospinal fluid evaluation included RT and nested PCR for disialoganglioside GD2 synthase (GD2-nested PCR) as previously reported¹⁶ up to May 1, 2012, when it was replaced with RT followed by real-time PCR for CRX.

Real-Time PCR | Reaction components were Power SYBR Green PCR Master Mix (Applied Biosystems), 800 nM of each CRX primer or 200 nM of each GAPDH primer, 100 ng of cDNA, and water (final volume, 20 μ L). Every run included the unknown samples in triplicate, a calibrator sample equivalent to 1000 WERI-Rb1 cells, and a nontemplate control. The housekeeping gene *GAPDH* was used for normalization. The real-time PCR running protocol was a 10-minute step at 95°C, 40 cycles at 95°C for 15 seconds, and 60°C for 1 minute. A melting curve was done (StepOne Real-Time PCR system; Applied Biosystems).

The CRX mRNA expression was analyzed using the $\Delta\Delta$ Ct method, which gives expression values of CRX normalized with GAPDH and relativized to a calibration sample (in this case, 1000 WERI-Rb1 cells). Retrotranscription and real-time PCR experiments were run twice for each bone marrow sample, and the CRX mRNA relative expression values were obtained determining these repetitions.

Limit of Detection of the RT Followed by the Real-Time PCR System |

The sensitivity of the RT followed by real-time PCR was assessed by seeding WERI-Rb1 cells into normal mononuclear cells (MNCs) with a dilution range from 10^{-1} to 10^{-7} . *Sensitivity* was defined as the lowest dilution with specific amplification and SD between replicates lower than 0.5. The *quantitative range* was defined as the lowest dilution to yield a difference between dilutions of approximately 3.34 threshold cycles.

Evaluation of CRX in Patients

Patients

This prospective study included all children with metastatic retinoblastoma at diagnosis or at relapse between June 30, 2008, and June 30, 2014. When curative therapy was attempted, children were considered for an intensive chemotherapy induction regimen followed by consolidation with high-dose chemotherapy and autologous stem-cell rescue for responding patients as previously reported.^{17,18} Patients ranged in age from 18 to 41 months.

Specimen Collection and Preservation

Samples of peripheral blood, bone marrow, and CSF were collected as part of a prospective defined schedule. Bone marrow examination included samples of 2 aspirates and 2 biopsies taken from each posterior iliac crest that were sent for morphologic assessment (cytology), immunocytology for disialoganglioside GD2, and PCR determinations. Each specimen used for PCR was placed into a guanidinium-thiocyanate buffer (1:1.5 ratio of sample to buffer) as previously reported.¹⁶ Bone marrow biopsies were routinely processed using histopathologic testing. Immunocytology for disialoganglioside GD2 was done using the 3F8 antibody as previ-

ously reported.⁸ Samples of CSF (3 mL) and peripheral blood (3 mL) were collected at the same time. Cerebrospinal fluid was analyzed by cytology, by immunocytology for disialoganglioside GD2 (examined only with cell count ≥ 3 cells/mm³), and by PCR. Response-to-treatment evaluation was scheduled after the second induction chemotherapy cycle; however, in cases with bone marrow invasion, evaluation was performed after the first chemotherapy cycle and repeated after each cycle until the results were negative. In all cases, complete examination was done before consolidation, at day 60 of consolidation, and 1 year after diagnosis or in the event of a suspected extraocular relapse.

Data Analysis of CRX Expression

Clinical samples were scored as positive if at least 2 of the 3 replicates had a Ct value lower than 40, with an SD between replicates of less than 0.5. Twice repetitions were performed from each bone marrow sample. The CRX mRNA normalized expression values were obtained through the $\Delta\Delta$ Ct method, as described above.

Patients in whom either CRX mRNA, immunocytology for disialoganglioside GD2, and/or GD2-nested PCR was detected in bone marrow, peripheral blood, or CSF and who did not show tumor cells by standard pathologic criteria were considered as having MD. Survival status was updated to June 30, 2014.

Results

CRX mRNA in Retinoblastoma Tumors, Retinoblastoma Cell Lines, and Controls

In all 17 tumors analyzed as well as in both cell lines, high expression of CRX mRNA was detected. Values of CRX mRNA relative expression in retinoblastoma tumors ranged from 8.1×10^{-5} to 5.6 (mean, 0.86; SD, 1.3) (Figure 1). No CRX mRNA was detected in any of the 47 normal bone marrow samples; only GAPDH amplification was obtained. Therefore, any expression of CRX mRNA was interpreted as a positive result, and no threshold could be established (Figure 1).

Limits of Detection of CRX mRNA

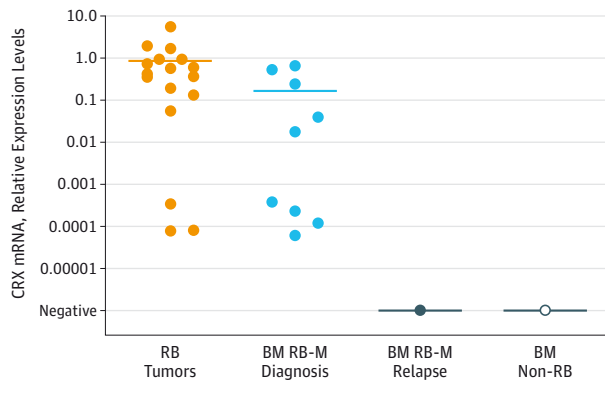
The limit of detection of CRX obtained was equivalent to 1.0 WERI-Rb1 cell in 1.0×10^7 MNCs (10^{-7} or CRX mRNA relative expression level, 3.11×10^{-5}). The quantitative range was from 1.0 WERI-Rb1 cell in 10 MNCs up to 1 WERI-Rb1 cell in 1.0×10^5 MNCs (10^{-1} up to 10^{-5} since the linearity was lost in the last 2 dilutions ($r^2 = 0.9856$) (Figure 2).

Patient Description and Outcome

The study included 17 patients with metastatic retinoblastoma. Nine patients had newly diagnosed metastatic retinoblastoma (Table 1), and the remaining individuals were included upon occurrence of metastatic relapse (Table 2) events after diagnosis of nonmetastatic retinoblastoma.

All patients with newly diagnosed metastatic disease had biopsy-proved bone marrow invasion, and 2 patients had concomitant CNS invasion consisting of chiasmatic involvement with normal CSF through cytologic examination.

Figure 1. Cone-Rod Homeobox Messenger mRNA (CRX mRNA) Relative Expression Levels

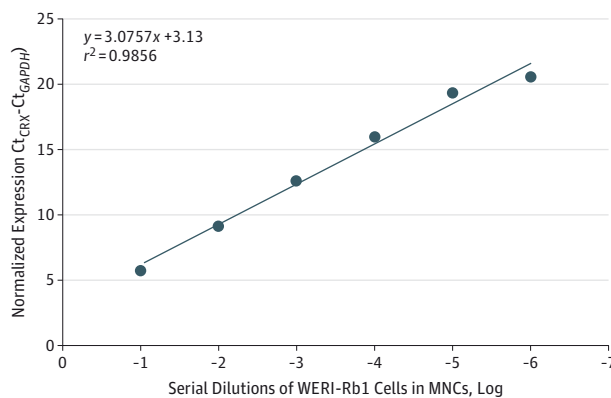


CRX mRNA relative expression levels measured in retinoblastoma (RB) tumors and bone marrow (BM) samples of patients with RB with metastatic disease at diagnosis, patients with metastatic relapse, and patients without RB. Orange circles indicate RB tumors; light blue circles, BM samples of patients with RB with metastatic disease at diagnosis; grey circle, BM samples of patients with RB with cerebrospinal fluid relapse; empty circle, patients without RB; and horizontal lines, mean value of each group. RB-M indicates metastatic retinoblastoma.

Of the 9 patients who had metastatic disease at diagnosis, 1 died of chemotherapy toxic effects, and 7 achieved complete remission with chemotherapy and surgical removal of the primary ocular tumor. Patient outcomes are described in Table 1.

Of the 8 patients included upon metastatic relapse, all presented with nonmetastatic disease but had a CNS relapse occurring at a median of 12 months (range, 6-27 months) after diagnosis (Table 2). Relapse included CSF involvement in 7 patients and a chiasmatic tumor mass with normal CSF in the remaining patient. No bone marrow involvement was evident in any of these cases. Patient outcomes are described in Table 2.

Figure 2. Limit of Detection of Cone-Rod Homeobox (CRX)



Limit of detection of CRX estimated through WERI-Rb1 cell dilutions in normal mononuclear cells (MNCs). The sensitivity was of 1 tumor cell in 10^7 MNCs (10^{-7}), and the quantitative range was from 1.0×10^{-1} to 1.0×10^{-5} ($r^2 = 0.9856$). The equation of the line was $y = 3.0757x + 3.13$. Ct indicates threshold cycle.

CRX in Patients With Histopathologic Evidence of Bone Marrow Invasion

Both CRX mRNA and immunocytology for disialoganglioside GD2 were positive in all 9 cases, confirming neoplastic infiltration. The CRX mRNA relative expression values ranged from 6.0×10^{-5} to 0.67 (mean, 0.17; SD, 0.26) (Figure 1). Peripheral blood in all these patients was also positive for CRX mRNA despite all children having normal counts and no morphologic evidence of circulating blasts. In 7 of the 8 evaluated cases (1 child died), no MD was evident in the bone marrow specimens at any time after the first chemotherapy cycle since the specimens became negative both for CRX mRNA and immunocytology for disialoganglioside GD2 and remained below the level of detection thereafter either before autologous stem-cell rescue and at hematopoietic reconstitution at 2 months and 1 year after transplant. In the remaining child, CRX mRNA was negative after 2 cycles in the bone marrow, but a CSF relapse was observed after the third cycle (performed by GD2-nested PCR). No child had a bone marrow relapse.

MD in Bone Marrow of Patients With CSF Relapse

A total of 11 CSF relapses occurring in 9 patients with retinoblastoma were evaluated. Seven patients were included in the study in the event of the first CSF relapse, and 2 of these children had a subsequent CSF relapse that was also studied. Two patients with metastatic disease at diagnosis had a CSF relapse as their first event, and they were also studied. The bone marrow was evaluated in all of these CSF relapses and was negative on morphologic evaluation. There was no evidence of bone marrow MD since immunocytology evaluation for disialoganglioside GD2 and CRX mRNA was negative in all instances (Figure 1).

In these episodes, typical neoplastic cells were seen by morphologic examination in the CSF in 7 cases that were confirmed as malignant by immunocytology for disialoganglioside GD2. In 3 events, the immunocytology was not conclusive, so neoplastic cells were identified by GD2-nested PCR or CRX mRNA (CRX mRNA relative expression values, 1.5 and 1.8). The CSF was not evaluated in 1 child (Table 2).

MD in CSF of Children With No Clinical CSF Involvement

Three of the 9 children with initial metastatic disease had MD in the CSF at diagnosis (2 studied by GD2-nested PCR and 1 evaluated by RT followed by real-time PCR for CRX (CRX mRNA relative expression level, 1.87). In children with CSF involvement, MD could be evaluated only in the 2 cases for CRX mRNA expression. In one of these cases and in one from the metastatic group, after becoming negative, a positive MD determination heralded a CSF relapse occurring weeks thereafter (CRX mRNA relative expression level, 1.5).

Discussion

We confirmed that CRX is a reliable tumor marker for retinoblastoma in extraocular sites. Our data, obtained with use of

Table 1. Description of Patients Included With Metastatic Disease at Diagnosis

Patient No. (Laterality)	Metastatic Sites at Enrollment	Status at Enrollment					Status After Induction					Treatment	Outcome	
		BM Biopsy/ Cytology	IC for GD2	CRX	CSF Cytology	CRX/GD2 Analysis	BM Biopsy/ Cytology	IC for GD2	CRX	CSF Cytology	CRX/GD2 Analysis			
1 (Unilateral)	BM	+	+	+	-	NE ^a	CR-	-	-	-	-	(GD2-nested PCR)	Intensive induction chemotherapy consolidation with ASCR	Alive in 1 CR (38 mo)
2 (Bilateral)	BM, orbit	+	+	+	-	NE ^a	CR-	-	-	-	-	NE ^a	Intensive induction chemotherapy consolidation with ASCR	Alive in 1 CR (70 mo)
3 (Unilateral)	BM, orbit, and lymph nodes	+	+	+	-	- (GD2-nested PCR)	CR-	-	-	-	-	NE ^a	Intensive induction chemotherapy consolidation with ASCR	CNS relapse; chiasmatic mass with CSF-; BM- with MD-; palliative therapy
4 (Unilateral)	BM, orbit	+	+	+	-	- (GD2-nested PCR)	ND	ND	ND	ND	ND	ND	Intensive induction chemotherapy	Died of toxic effects after first chemotherapy cycle
5 (Unilateral)	BM, orbit	+	+	+	-	+	CR-	-	-	-	-	NE ^a	Intensive induction chemotherapy consolidation with ASCR	Alive in 1 CR (28 mo)
6 (Unilateral)	BM	+	+	+	-	+	CR-	-	-	-	-	(GD2-nested PCR)	Intensive induction chemotherapy consolidation with ASCR	CNS relapse with CSF involvement; BM- with MD-; palliative therapy and death ^b
7 (Unilateral)	BM, orbit	+	+	+	-	- (GD2-nested PCR)	CR-	-	-	-	-	(GD2-nested PCR)	Intensive induction chemotherapy consolidation with ASCR	Alive in 1 CR (1 mo)
8 (Unilateral)	BM, orbit, and CNS (chiasmatic mass)	+	+	+	-	NE ^a	CR-	-	-	-	-	(GD2-nested PCR)	Intensive induction chemotherapy	Died of CNS bleeding in the pretransplant period
9 (Bilateral)	BM, orbit, and CNS (chiasmatic mass)	+	+	+	-	+	CR-	-	-	-	+	(GD2-nested PCR)	Intensive induction chemotherapy discontinued for unacceptable toxic effects and poor family adherence	CNS progression with leptomeningeal dissemination and death

Abbreviations: ASCR, autologous stem cell rescue; BM, bone marrow; CNS, central nervous system; CR, complete remission; CRX, cone-rod homeobox; CSF, cerebrospinal fluid; GD2, disialoganglioside GD2; IC, immunocytology; MD, minimal dissemination; mRNA, messenger RNA; ND, not done; NE, not evaluable; PCR, polymerase chain reaction; REL, relative expression levels; +,

positive; -, negative.

^a Not evaluable because no RNA was isolated or damaged RNA.

^b Positive CSF before clinical relapse.

RT followed by real-time PCR, suggest that high sensitivity and specificity may be achieved and could be applied for evaluation of MD.¹⁹

Our validation of CRX mRNA in bone marrow, analyzed by morphologic examination and immunocytology for disialoganglioside GD2, had no false-negatives. However, the ob-

served wide range of CRX mRNA relative expression levels may be explained by different degrees of tumoral infiltration in each patient.²⁰ Children without retinoblastoma showed no detectable expression of CRX mRNA, with no false-positives in a large control group. These data suggest that we had a specificity of 100% and a sensitivity of 100% for the evaluation of bone mar-

Table 2. Description of Patients Included Upon Metastatic Relapse

Patient No. (Laterality)	Sequence of Prior Therapy	Status at Enrollment					Status After Induction					Treatment of CNS Relapse	Outcome
		BM		CSF			BM		CSF				
		Biopsy/ Cytology	IC for GD2	CRX	Cytology	CRX/GD2 Analysis	Cytology	IC for GD2	CRX	Cytology	CRX/GD2 Analysis		
10 (Unilateral)	Enucleation-adjunct chemotherapy and orbital radiotherapy	ND	ND	ND	+	+	ND	ND	ND	ND	ND	Palliative intrathecal therapy	Died of progressive CNS disease
11 (Bilateral)	Chemo-reduction EBRT enucleation and adjunct therapy	-	-	NE ^a	+	+	ND	ND	ND	ND	ND	Intensive chemotherapy	Died of toxic effects
12 (Unilateral)	Chiasmatic mass at enrollment; neoadjuvant therapy, enucleation-adjunct chemotherapy, and orbital radiotherapy	-	-	-	Doubtful	+	ND	ND	ND	+	+	Intra-venous topotecan hydrochloride	Died of progressive CNS disease
13 (Unilateral)	Enucleation-adjunct chemotherapy	-	-	-	Doubtful	+	-	-	-	-	NE ^a	Intensive chemotherapy and intrathecal topotecan	Died of relapsed disease ^b
14 (Bilateral)	Chemoreduction intra-arterial chemotherapy and enucleation orbital relapse	-	-	-	Doubtful	+	-	-	-	-	-	Systemic chemotherapy, cranial radiotherapy, and intrathecal topotecan	Died of relapsed CSF disease
15 (Unilateral)	Enucleation-adjunct chemotherapy and orbital radiotherapy	-	-	-	+	+	ND	ND	ND	ND	ND	Palliative treatment	Died of progressive CNS disease
16 (Unilateral)	Chiasmatic mass at enrollment; neoadjuvant therapy, enucleation-adjunct chemotherapy, and orbital radiotherapy	-	-	-	-	-	ND	ND	ND	ND	ND	Palliative treatment	Died of progressive CNS disease
17 (Unilateral)	Enucleation-adjunct chemotherapy and orbital radiotherapy	-	-	-	+	+	ND	ND	ND	ND	ND	Palliative treatment	Died of progressive CNS disease

Abbreviations: BM, bone marrow; CNS, central nervous system; CR, complete remission, CRX, cone-rod homeobox; CSF, cerebrospinal fluid; EBRT, external-beam radiotherapy; GD2, disialoganglioside GD2; IC, immunocytology; mRNA, messenger RNA; ND, not done; NE, not evaluable; PCR, polymerase

chain reaction; REL, relative expression levels; +, positive; -, negative.

^a Not evaluable because no RNA was isolated or damaged RNA.

^b Positive CSF before clinical relapse.

row infiltrated with retinoblastoma. Tumor cells from patients with relapse after multiple chemotherapy treatments continued to show CRX mRNA expression, which allows monitoring of treatment response. Nevertheless, mRNA-based analysis is limited by its lower stability compared with DNA determinations.

The use of GD2-nested PCR in the CSF of children with retinoblastoma without CNS involvement has been evaluated,⁷ but the bone marrow was not evaluated. The use of disialoganglioside GD2 synthase as a marker for MD in bone marrow was challenging since we obtained both a lower sensitivity and specificity due to the presence of background expression of disialoganglioside GD2, as other groups have reported for neuroblastoma.¹⁰ Use of CRX mRNA as a marker for MD of reti-

noblastoma compares favorably with disialoganglioside GD2 synthase because of the lack of background expression with higher specificity and sensitivity. Real-time PCR for CRX mRNA was more specific in the evaluation of CSF in 2 cases with inconclusive results of conventional cytology and immunocytology for disialoganglioside GD2. As reported^{7,21} for nested PCR for GD2 synthase, MD could be detected in the CSF with CRX mRNA heralding CSF relapse. However, the use of PCR for determination of MD in the CSF is challenging because of the low yield of RNA from acellular CSF, and more than one technique would be appropriate for a reliable result.⁷

Our study provides data to better understand the kinetics of response to treatment in metastatic retinoblastoma and to infer mechanisms for dissemination. Patients with sys-

temic metastasis can be cured with intensive therapies if there is no CNS involvement. Most treatment failures are related to CNS relapse, even in children with no overt CNS dissemination. The rapid, complete clearance of tumor cells from the bone marrow supports the concept that systemic disease control is optimal with intensive chemotherapy. Even though real-time PCR analysis allows for quantitative assessments, this outcome was not possible in our cohort since all patients with bone marrow response after the first cycle showed values below the detection level, and there was no change throughout the study.

Previous work⁷ found that MD is present in the CSF at diagnosis in a sizable proportion of high-risk children. It would be important to know whether the CSF is seeded concomitantly with systemic dissemination, as reported²² in many cases of childhood acute lymphoblastic leukemia; whether CSF seeding is an isolated event confined to the CNS; and if either of these situations is present at diagnosis or at the time of relapse. With such information, intensification of therapy can be targeted preferentially to the CSF or systemically to improve results. Our data clearly show that bone marrow invasion does not significantly contribute to the occurrence of CSF relapse since no evidence of bone marrow MD was noted in any of the 11 episodes of CNS relapse evaluated in the present study. It is more likely that, in most cases, the CSF is seeded earlier in the disease course and these tumor cells are not com-

pletely eradicated by conventional chemotherapy, leading to CSF relapse acting as a sanctuary site.²¹ Hence, intensifying CSF-directed therapy with intrathecal or intraventricular chemotherapy should be explored to try to improve outcomes.²³ Most groups²⁴ treat retinoblastoma metastatic to the CNS with intensive systemic chemotherapy and no intrathecal chemotherapy, but survival rates are below 30%. Although intrathecal chemotherapy including methotrexate and cytarabine was relatively widely used in the past,^{25,26} most groups discontinued it in favor of a more intensive systemic regimen, mostly because of the relatively low activity of those drugs for retinoblastoma. However, newer drugs already tested for intrathecal chemotherapy and active for retinoblastoma, such as topotecan hydrochloride, may be good candidates in light of our findings.^{27,28}

Conclusions

The data obtained in this study suggest that CRX mRNA is a novel and specific marker for disseminated retinoblastoma of interest for MD determination and as a tool for improving tumor cell identification in extraocular sites. Cerebrospinal fluid relapse is not related to concomitant systemic dissemination of retinoblastoma.

ARTICLE INFORMATION

Submitted for Publication: December 15, 2014; final revision received February 27, 2015; accepted March 1, 2015.

Published Online: April 30, 2015.
doi:10.1001/jamaophthalmol.2015.0900.

Author Affiliations: Hematology-Oncology Service, Pediatric Hospital, Servicios de Atención Médica Integral para la Comunidad, Professor Dr. Juan P. Garrahan, Buenos Aires, Argentina (Torbidoni, Laurent, Sampor, Ottaviani, C. Alonso, Chantada); Pathology Service, Pediatric Hospital Servicios de Atención Médica Integral para la Comunidad Professor Dr. Juan P. Garrahan, Buenos Aires, Argentina (Vazquez, de Dávila); Molecular Oncology Laboratory, Quilmes National University, Bernal, Argentina (Gabri, D. F. Alonso); Immunology Service, Pediatric Hospital Servicios de Atención Médica Integral para la Comunidad Professor Dr. Juan P. Garrahan, Buenos Aires, Argentina (Rossi).

Author Contributions: Drs Torbidoni and Chantada had full access to all the data in the study and take responsibility for the integrity of the data and the accuracy of the data analysis.

Study concept and design: Torbidoni, Gabri, de Dávila, D. F. Alonso, Chantada.

Acquisition, analysis, or interpretation of data: Laurent, Sampor, Ottaviani, Vazquez, Rossi, C. Alonso, D. F. Alonso, Chantada.

Drafting of the manuscript: Torbidoni, Laurent, Sampor, Ottaviani, Rossi, de Dávila, C. Alonso, Chantada.

Critical revision of the manuscript for important intellectual content: Laurent, Vazquez, Gabri, D. F. Alonso.

Statistical analysis: Torbidoni, Laurent, C. Alonso.
Obtained funding: Torbidoni, D. F. Alonso, Chantada.

Administrative, technical, or material support: Laurent, Ottaviani.

Study supervision: Torbidoni, Gabri, de Dávila, D. F. Alonso, Chantada.

Conflict of Interest Disclosures: All authors have completed and submitted the ICMJE Form for Disclosure of Potential Conflicts of Interest. Drs Torbidoni, Gabri, and D. F. Alonso are members of Consejo Nacional de Investigaciones Científicas y Técnicas. No other disclosures were reported.

Funding/Support: This study was supported by the Fund for Ophthalmic Knowledge, the Natalí Dafne Flexer Foundation, Instituto Nacional del Cáncer, and grant BID-PIDI29-PAE37.011 from Agencia Nacional de Promoción Científica y Tecnológica.

Role of the Funder/Sponsor: The funding organizations had no role in the design and conduct of the study; collection, management, analysis, and interpretation of the data; preparation, review, or approval of the manuscript; and decision to submit the manuscript for publication.

Additional Contributions: Xiaoliang Leon Xu, MD, PhD (Department of Surgery, Memorial Sloan Kettering Cancer Center), and Carmen de Torres, MD, PhD (Developmental Tumor Biology Laboratory, Hospital Sant Joan de Déu), provided expert advice on the design of this study. Nai Kong Cheung, MD, PhD (Department of Pediatrics, Memorial Sloan Kettering Cancer Center), supplied the 3F8 antibody. These contributors did not receive financial compensation.

REFERENCES

1. Canturk S, Qaddoumi I, Khetan V, et al. Survival of retinoblastoma in less-developed countries: impact of socioeconomic and health-related indicators. *Br J Ophthalmol*. 2010;94(11):1432-1436.

2. Leal-Leal CA, Rivera-Luna R, Flores-Rojo M, Juárez-Echenique JC, Ordaz JC, Amador-Zarco J. Survival in extra-orbital metastatic retinoblastoma: treatment results. *Clin Transl Oncol*. 2006;8(1):39-44.

3. Gündüz K, Müftüoğlu O, Günalp I, Unal E, Taçyıldız N. Metastatic retinoblastoma clinical features, treatment, and prognosis. *Ophthalmology*. 2006;113(9):1558-1566.

4. MacKay CJ, Abramson DH, Ellsworth RM. Metastatic patterns of retinoblastoma. *Arch Ophthalmol*. 1984;102(3):391-396.

5. Beiske K, Ambros PF, Burchill SA, Cheung IY, Swerts K. Detecting minimal residual disease in neuroblastoma patients: the present state of the art. *Cancer Lett*. 2005;228(1-2):229-240.

6. Dimaras H, Rushlow D, Halliday W, et al. Using *RB1* mutations to assess minimal residual disease in metastatic retinoblastoma. *Transl Res*. 2010;156(2):91-97.

7. Laurent VE, Sampor C, Solernou V, et al. Detection of minimally disseminated disease in the cerebrospinal fluid of children with high-risk retinoblastoma by reverse transcriptase-polymerase chain reaction for *GD2* synthase mRNA. *Eur J Cancer*. 2013;49(13):2892-2899.

8. Chantada GL, Rossi J, Casco F, et al. An aggressive bone marrow evaluation including immunocytology with *GD2* for advanced retinoblastoma. *J Pediatr Hematol Oncol*. 2006;28(6):369-373.

9. Shen H, Tang Y, Xu X, Tang H. Detection of the *GD2*⁺/*CD56*⁺/*CD45*⁺ immunophenotype by flow cytometry in cerebrospinal fluids from a patient with retinoblastoma. *Pediatr Hematol Oncol*. 2013;30(1):30-32.

10. Beiske K, Burchill SA, Cheung IY, et al; International Neuroblastoma Risk Group Task

- Force. Consensus criteria for sensitive detection of minimal neuroblastoma cells in bone marrow, blood and stem cell preparations by immunocytology and QRT-PCR: recommendations by the International Neuroblastoma Risk Group Task Force. *Br J Cancer*. 2009;100(10):1627-1637.
11. Boatright JH, Borst DE, Stodulkova E, Nickerson JM. Endogenous CRX expression and IRBP promoter activity in retinoblastoma cells. *Brain Res*. 2001;916(1-2):136-142.
12. Glubrecht DD, Kim JH, Russell L, Bamforth JS, Godbout R. Differential CRX and OTX2 expression in human retina and retinoblastoma. *J Neurochem*. 2009;111(1):250-263.
13. Santagata S, Maire CL, Idbaih A, et al. CRX is a diagnostic marker of retinal and pineal lineage tumors. *PLoS One*. 2009;4(11):e7932. doi:10.1371/journal.pone.0007932.
14. Terry J, Calicchio ML, Rodriguez-Galindo C, Perez-Atayde AR. Immunohistochemical expression of CRX in extracranial malignant small round cell tumors. *Am J Surg Pathol*. 2012;36(8):1165-1169.
15. Xu XL, Fang Y, Lee TC, et al. Retinoblastoma has properties of a cone precursor tumor and depends upon cone-specific MDM2 signaling. *Cell*. 2009;137(6):1018-1031.
16. Laurent VE, Otero LL, Vazquez V, et al. Optimization of molecular detection of GD2 synthase mRNA in retinoblastoma. *Mol Med Rep*. 2010;3(2):253-259.
17. Palma J, Sasso DF, Dufort G, et al. Successful treatment of metastatic retinoblastoma with high-dose chemotherapy and autologous stem cell rescue in South America. *Bone Marrow Transplant*. 2012;47(4):522-527.
18. Chantada GL, Fandiño AC, Gutter MR, et al. Results of a prospective study for the treatment of unilateral retinoblastoma. *Pediatr Blood Cancer*. 2010;55(1):60-66.
19. Stutterheim J, Gerritsen A, Zappeij-Kannegieter L, et al. Detecting minimal residual disease in neuroblastoma: the superiority of a panel of real-time quantitative PCR markers. *Clin Chem*. 2009;55(7):1316-1326.
20. Stutterheim J, Zappeij-Kannegieter L, Ora I, et al. Stability of PCR targets for monitoring minimal residual disease in neuroblastoma. *J Mol Diagn*. 2012;14(2):168-175.
21. Atlas SW, Kemp SS, Rorke L, Grossman RI. Hemorrhagic intracranial retinoblastoma metastases: MR-pathology correlation. *J Comput Assist Tomogr*. 1988;12(2):286-289.
22. Biojone E, Queiróz RdeP, Valera ET, et al. Minimal residual disease in cerebrospinal fluid at diagnosis: a more intensive treatment protocol was able to eliminate the adverse prognosis in children with acute lymphoblastic leukemia. *Leuk Lymphoma*. 2012;53(1):89-95.
23. Dimaras H, Héon E, Doyle J, et al. Multifaceted chemotherapy for trilateral retinoblastoma. *Arch Ophthalmol*. 2011;129(3):362-365.
24. Dunkel IJ, Chan HS, Jubran R, et al. High-dose chemotherapy with autologous hematopoietic stem cell rescue for stage 4B retinoblastoma. *Pediatr Blood Cancer*. 2010;55(1):149-152.
25. Schwartzman E, Chantada G, Fandiño A, de Dávila MT, Raslawski E, Manzitti J. Results of a stage-based protocol for the treatment of retinoblastoma. *J Clin Oncol*. 1996;14(5):1532-1536.
26. Pratt CB. Topical topic: use of chemotherapy for retinoblastoma. *Med Pediatr Oncol*. 1998;31(6):531-533.
27. Dimaras H, Héon E, Budning A, et al. Retinoblastoma CSF metastasis cured by multimodality chemotherapy without radiation. *Ophthalmic Genet*. 2009;30(3):121-126.
28. Potter SL, Berg S, Ingle AM, Krailo M, Adamson PC, Blaney SM. Phase 2 clinical trial of intrathecal topotecan in children with refractory leptomeningeal leukemia: a Children's Oncology Group trial (P9962). *Pediatr Blood Cancer*. 2012;58(3):362-365.