



Cranial structure and condylar asymmetry of patients with juvenile idiopathic arthritis: a risky growth pattern

Maria Grazia Piancino^{1,2} · Rosangela Cannavale¹ · Paola Dalmaso³ · Ingrid Tonni⁴ · Umberto Garagiola⁵ · Letizia Perillo⁶ · Alma Nunzia Olivieri⁷

Received: 5 May 2018 / Revised: 10 June 2018 / Accepted: 12 June 2018
© International League of Associations for Rheumatology (ILAR) 2018

Abstract

The aim of the study was to evaluate the cephalometric differences and condylar asymmetry between patients with juvenile idiopathic arthritis (JIA) and normal control group. Sixty-two JIA patients with a latero-lateral cephalogram and orthopantomography, seeking for orthodontic therapy, and 62 normal matched subjects were comprised in the study. Cephalometric analysis was used for the evaluation of facial morphology while the method of Habets et al. (J Oral Rehabil 15(5): 465–471, 1988) was used to compare the condyles in orthopantomography. The significance of between-group differences was assessed using the Mann–Whitney test, as appropriate. The results showed a prevalence of the upper maxilla with hypomandibulia (class II), hyperdivergency with short vertical ramus posterior and posterior rotation of the mandible in JIA children (SNB, ANB, NSL/ML, Fh/ML, NL/ML, ArGo, ML $P < 0.0001$, ML/Oc $P < 0.004$, ArGo/GoGn $P = 0.02$, no difference for SNA). The condyles of the JIA group resulted highly asymmetric ($P < 0.0001$). The growth pattern of JIA patients resulted clearly different from normal subjects. This serious impairment of the cranial growth may be considered as an indicator of the need for early and continuous orthognatodontic therapy during the entire period of development for all JIA patients, independently from temporomandibular joint signs or symptoms. To this end, it is important that rheumatologists and orthognathodontists set up a multidisciplinary treatment planned to control the side effects of a deranged growing pattern, to strictly avoid any orthodontic therapies that may worsen function and growth, and to promote treatments improving the physiology and biology of the cranial development.

Keywords Cephalometry · Condylar asymmetry index · Juvenile idiopathic arthritis (JIA) · Orthopantomography (OPT)

✉ Maria Grazia Piancino

¹ Department of Surgical Sciences-Orthodontic division, Dental School, University of Turin, Turin, Italy

² Turin, Italy

³ Department of Public Health and Paediatrics, University of Turin, Turin, Italy

⁴ Orthodontic Division, Dental School, University of Brescia, Brescia, Italy

⁵ Department of Biomedical Sciences, University of Milan, Milan, Italy

⁶ Multidisciplinary Department of Medical-Surgical and Dental Specialties, University of Campania, Luigi Vanvitelli, Italy

⁷ Department of Woman and Child and General and Specialized Surgery, University of Campania, Luigi Vanvitelli, Italy

Introduction

Juvenile idiopathic arthritis (JIA) is an autoimmune chronic inflammation of one or more joints, characterized by an onset before the age of 16 years, during childhood and/or adolescent development [1]. One of the affected joints is the temporomandibular joint (TMJ) that is a bilateral synovial joint with a high degree of movement, bilaterally coordinated, and influenced by cranial structure and occlusion especially during growing.

TMJ involvement by JIA is recognized only in the most severe JIA subtype classification. However, in their everyday clinical practice, rheumatologists know that the TMJ might be involved also in less severe JIA and likely in all affected children, even when symptoms or signs are not detectable with routine clinical examination nor diagnostic imaging. The TMJ involvement may become clear at a later stage of development, when the physiological morphology is now lost

resulting in facial asymmetries and functional impairment, even in the absence of previous or actual pain or clinical signs.

The TMJ shows three special features: first, it is completely immature at birth. The functional reason for this characteristic is due to the fact that sucking is a vital reflex at birth and it is characterized by antero-posterior, linear shifts occurring at the occlusal plane level. For this reason, the joint is completely flat and immature. The entire development of the condyle and TMJ will occur during growing from 0 through 21st year of age. Second, as showed in previous studies, the condylar cartilage is not a primary growth center, as the growth plates of the long bones, but it is characterized by an adaptive type of growth as showed with histological studies [2–4]. The condylar cartilage acts as a secondary cartilage, with the aim to resist intermittent pressure and movements (chewing, swallowing, speaking) and to produce rapid growth during early life [3, 5]. The capability to adapt to functions, loads, cranial development, and vectors makes this a unique joint of its kind. Third, it is a bilateral joint with a high degree of movement and the condylar components (right and left) are part of a rigid structure, which is the mandible, highly influenced by functional movements. It results that the two sides are simultaneously involved during any type of displacement, both in a symmetrical or asymmetrical way depending on the considered movement.

In our previous study [1], it has been clearly shown that the two condyles of children with JIA grow in a severely asymmetrical way with respect to the control group. This means that one of the two condyles, in these children, is growing faster than the contralateral. The inflammatory status of JIA that involves the TMJs might be responsible of the altered growth pattern of the condyles and mandible resulting in a highly unstable and asymmetrical cranial structure. The asymmetry might be due to the altered cranial growth pattern responsible of functional instability and to the fact that the illness mainly involves the joint subjected to the higher and unbalanced load.

It is known from previous cephalometric studies in normal children that the long face hyperdivergent cranial type with prevalent vertical growth and posterior rotation of the mandible is also frequently associated with asymmetrical cranial growth [6, 7]. More specifically, previous cephalometric studies in patients with JIA have claimed that these children are characterized by prevalence of superior maxilla (skeletal class II malocclusion) and long face with posterior rotation of the mandible [8–19]. Cephalometric analysis showed a well-positioned maxilla (SNA near to normal values) and a retruded little mandible (SNB less than normal values). This combination leads to a hyperdivergent skeletal class II with hypomandibulia, posterior rotation of the mandible and augmentation of the anterior facial height (NSL/ML and Fh/ML more than normal).

Based on these considerations, we hypothesized that this type of cranial structure (hyperdivergent class II) might be the consequence of an insufficient growth in length of the vertical ramus of the mandible likely related to the inflammatory status of the TMJ responsible of the hyperdivergent cranial structure and, consequently, of the condylar asymmetry between sides. The aim of this study was the evaluation of the impaired cranial structure growth together with the condylar asymmetry of JIA patients compared to normal subjects.

Material and methods

Subjects

Sixty-two patients with JIA diagnosed according to the ILAR 2003 criteria (58 females 93.5%; 4 males (6.5%), mean age, 11.1 ± 3.8 years; Table 1), referred at the Department of Orthodontics of the University of Turin, University of Naples, University of Brescia and University of Milan, were included in this retrospective study. The treatment was assigned according to American College Rheumatology (ACR) recommendations [20]. Our patients were treated with non-steroidal anti-inflammatory drugs (NSAIDs) or corticosteroids according to juvenile idiopathic arthritis (JIA) subtype at the beginning of the disease. Patients who did not achieve clinical remission [21] were started treatment with methotrexate. A biological drug was associated with methotrexate in non-responders patients.

Inclusion criteria were (1) diagnosed JIA and rheumatologic treatment and (2) orthopantomography and lateral teleradiography.

Exclusion criteria were (1) any previous orthodontic treatment, (2) any maxillofacial surgery, (3) TMJ involvement, (4) history of maxillofacial trauma, and (5) genetic diseases, syndromes, or other congenital deformities.

Patients were referred to the Orthodontics divisions for routine orthodontic and dental screening.

Controls

Sixty-two subjects, age and sex matched with patients with class I occlusion without crossbite, were selected for the study. The inclusion criteria were (1) normal growth and development with no significant medical history, (2) bilateral molar class I with minor or no crowding. Exclusion criteria were (1) crossbite, (2) asymmetrical malocclusion, (3) functional deviation of the mandible, (4) history of maxillofacial trauma, (5) TMJ pathology, and (6) prosthodontic treatment and orthognathic surgery. The age and sex distributions in the two groups are shown in the Table 1.

Table 1 Demographic and occlusal features of JIA patients and control subjects

Gender	JIA patients			Control subjects		
	Females	Males	Total	Females	Males	Total
Number	58 (93.5%)	4 (6.5%)	62 (100%)	58 (93.5%)	4 (6.5%)	62 (100%)
Mean age at OPT (years)	10.8 ± 3.5	15.6 ± 4.5	11.1 ± 3.8	13.1 ± 5.6	13.4 ± 4.5	12.6 ± 5.1
Type of JIA						
Oligoarticular	42	2	44			
Polyarticular	16	1	17			
Others	0	1	1			
Type of occlusion						
Class I	28	3	31	46	4	50
Class II	17	0	17	12	0	12
Class III	3	1	4	0	0	0
Asymmetric	10	0	10	0	0	0
Crossbite						
Dx	11	2	13	0	0	0
Sx	8	0	8	0	0	0
Bilateral	28	2	30	0	0	0
No crossbite	11	0	11	58	4	62

Cephalometric examination

The craniofacial structure was evaluated by cephalometric analysis of the latero-lateral telerradiography.

Tracings of craniofacial structures with angular and linear measurements were performed manually on acetate films on profile radiographs. Landmarks are reported in Fig. 1.

Orthopantomographic examination

The method introduced by Habets et al. [22] was used to quantify asymmetries between the mandibular condyles and the rami. The outlines of the condyle and the ascending ramus of both sides were traced on acetate paper. On the tracing paper, a line (A, the ramus tangent) was drawn between the most lateral points of the condylar image (O1) and of the ascending ramus image (O2). A line perpendicular (B) to the ramus tangent was drawn from the most superior point of the condylar image. The vertical distance on the ramus tangent from B line to the most lateral point of the condyle (O1) was measured. This distance was called condylar height (CH). The distance on the ramus tangent between the two originally marked most lateral points of the image (O1 and O2) was called ramus height (RH) and measured (Fig. 1). To express the symmetry between the condyles and the rami on the OPT image, the following formula $|(\text{R}-\text{L}) / (\text{R} + \text{L})| \times 100\%$ was used. The absolute value of the difference between the measured condylar or rami sizes of the right (R) and left (L) were divided by the sum of the same condylar or rami sizes and respectively expressed in percentages. This calculation allows individual differences in sizes and provides a value for (a)

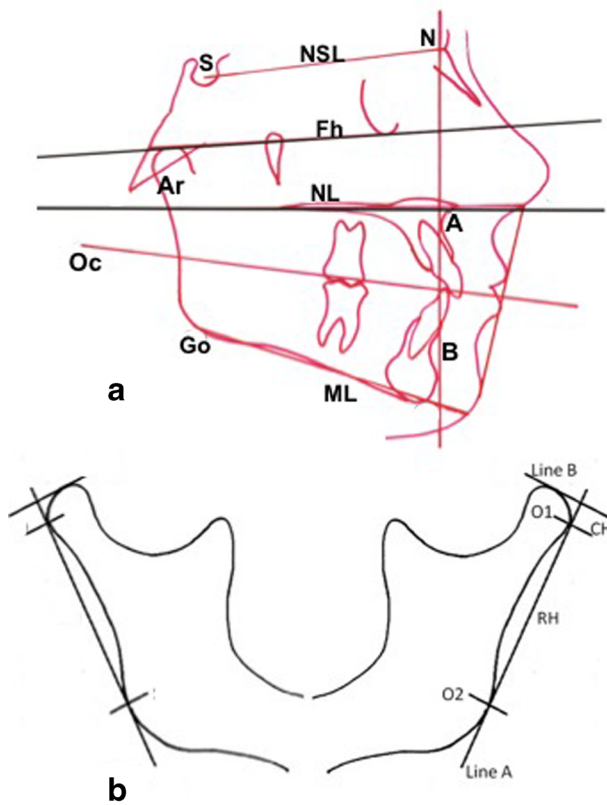
symmetry of each individual. The result of this ratio-formula gives a range of asymmetry from 0% (complete symmetry) to 100%. According to the study by Habets et al. [22], a 6% difference between the condylar vertical sizes in an OPT is an acceptable limit for diagnosing a condylar asymmetry.

Statistical analysis

Data were expressed as mean ± SD and interquartile range. The statistical distribution of the quantitative measures was found to be non-Gaussian (tested by the Shapiro–Wilk test) and the significance of between-group differences were assessed using the Mann–Whitney test. All the tests were two tailed and statistical significant level was set at 5%.

Results

Demographic characteristics, type of JIA, and dental occlusion are presented in Table 1. As regards the type of JIA, 44 patients (70.96%) were diagnosed with oligoarticular type, 17 (27.41%) with polyarticular type, and 1 (1.61%) with other type of JIA. In the JIA group, class I dental malocclusion was observed in 28 females and in 3 males; class II dental malocclusion was observed in 17 females; class III dental malocclusion was observed in 3 females and 1 male while asymmetric dental malocclusion (Class II and Class III) was observed in 10 females. Furthermore, posterior crossbite was present in 51 subjects (79.03%) while no crossbite was present in 11 females.



Angular measurements		
SNA (°)	Sella-Nasion-A	SNA, sagittal cranial relationship (the relationship in the sagittal plane between the cranial base as reference and the upper maxilla), according to Steiner;
SNB (°)	Sella-Nasion-B	SNB, sagittal cranial relationship (the relationship in the sagittal plane between the cranial base as reference and the mandible), according to Steiner;
ANB (°)	A-Nasion-B	ANB, sagittal cranial relationship (the relationship in the sagittal plane between the upper maxilla and the mandible with respect to the cranial base as reference), according to Steiner;
NSL/ML (°)	Sella-Nasion line/Mandibular line	NL/ML, mandibular inclination relative to the cranial base (the relationship in the sagittal plane between the cranial base and the mandibular plane);
Fh/ML (°)	Frankfurt line/Mandibular line	Fh/ML, mandibular inclination relative to the Frankfurt plane (the relationship in the sagittal plane between the Frankfurt plane and the mandibular plane);
NL/ML (°)	Nasal line/Mandibular line	NL/ML, angle between superior maxilla (NL) and the body of the mandible (ML), to evaluate the maxillary divergency, according to Schudy;
ArGo/ML (°)	Articulare point-Gonion/Mandibular line	ArGo/ML, the gonial angle between the ramus (ArGo) and the body (ML) of the mandible;
NL/Oc (°)	Nasal line/Occlusal line	NL/Oc, angle between superior maxilla (NL) and occlusal functional plane (Oc), to evaluate the orientation of the occlusal plane;
ML/Oc (°)	Mandibular line/Occlusal line	ML/Oc, angle between mandibular plane (ML) and occlusal functional plane (Oc), to evaluate the orientation of the occlusal plane;
NL/Fh (°)	Nasal line/Frankfurt line	NL/Fh, angle between superior maxilla (NL) and Frankfurt plane (Fh), to evaluate the orientation of the superior maxilla;
Linear measurements		
ArGo (mm)	Articulare point/Gonion	ArGo, length of the ramus of the mandible;
ML (mm)	Mandibular line	ML, length of the mandibular body;
Wits index (mm)	Distance between point A and point B projection on occlusal plane	Wits index, the distance between the projection of point A and B on the occlusal plane, to evaluate jaw deformity.
Condylar asymmetry		
CI	Condylar asymmetry index	See text
RI	Ramal asymmetry index	See text

Fig. 1 **a** Cephalometric landmarks and planes. **b** Method of Habets/Hansson used to evaluate condylar and mandibular ramal asymmetry. **c** Definition of cephalometric angular and linear measurements considered in the study to compare craniofacial features of JIA patients with the control group

The lateral cephalometric values of the two groups and the statistical analysis are shown in Table 2.

The following angular measurements, ANB, SNB, NSL/ML, Fh/ML, and NL/ML, showed a high significant difference ($P < 0.0001$) as well as ML/Oc ($P = 0.004$) and ArGo/GoGn ($P = 0.02$) comparing JIA patients with controls. As regards linear measurements, ArGo and ML also showed a high significant difference comparing the JIA group with controls ($P < 0.0001$). Any difference was found for SNA, NL/Oc, NL/Fh.

As regards condylar asymmetry, the results showed a high significant difference in the range of asymmetry of the condyle, being the patient group highly asymmetrical ($P < 0.0001$). No differences were found in the range of asymmetry of the ramus between groups ($P = 0.47$).

Discussion

This retrospective study evaluated the cranial structure together with the condylar asymmetry of patients with JIA, compared with normal subjects. The results showed an important

difference between JIA patients and control group for cephalometric angular and linear measurements (SNB, ANB, NSL/ML, Fh/ML, NL/Oc, ArGo, ML, ArGo/GoGn, ML/Oc, and ArGo and ML ($P < 0.0001$)). These findings are in agreement with the literature but the originality of this study is the evaluation in the same sample of the condylar asymmetry that resulted highly asymmetric in JIA patients ($P < 0.0001$). With respect to normal subjects, JIA patients present different cranial features that, together with the condylar asymmetry, lead us to consider that their growth pattern is clearly different from that of normal subjects.

Regarding the cranial structure, the most important result is the reduced value of ArGo ($P < 0.0001$). ArGo is a linear measurement that refers to the height of the vertical ramus of the mandible. Its shortness due to insufficient growth is involved in the hyperdivergent pattern growth of the skull, together with the backward rotation of the mandible (NSL/ML, FH/ML $P < 0.0001$). In fact, the value related to the hyperdivergency of the skull that is represented by the angle between the upper maxilla and the mandible seriously increased (hyperdivergent) in children with JIA (NL/ML $P < 0.0001$). Furthermore, the horizontal body of the mandible

Table 2 Comparison of cranial structure and percent difference of right and left condyles and mandibular rami of JIA patients with control group

Variable	JIA patients	Controls	<i>P</i>
Age	11.1 ± 3.8	12.6 ± 5.1	0.24
Angular measurements			
SNA	79.9 ± 3.5	80.7 ± 4.4	0.27
SNB	75.0 ± 4.0	77.8 ± 4.0	0.0004**
ANB	4.8 ± 2.5	3.0 ± 2.0	< 0.0001**
NSL/ML	38.6 ± 6.8	31.9 ± 4.9	< 0.0001**
Fh/ML	28.0 ± 6.5	22.2 ± 4.7	< 0.0001**
NL/ML	28.5 ± 7.1	24.4 ± 4.0	0.0009**
ArGo/GoGn	128.0 ± 6.6	125.3 ± 3.1	0.02
NL/Oc	10.5 ± 4.9	9.7 ± 2.9	0.3
ML/Oc	17.6 ± 5.3	15.1 ± 3.9	0.004*
NL/Fh	-2.3 ± 6.2	-0.5 ± 3.7	0.27
Linear measurements			
ArGo	36.1 ± 6.1	43.8 ± 4.9	< 0.0001**
ML	63.4 ± 7.4	69.4 ± 6.3	< 0.0001**
Wits	1.2 ± 3.5	0.1 ± 2.3	0.04
Asymmetry index			
Condylar index	18.1 ± 9.5	3.0 ± 1.6	< 0.0001**
Ramal index	3.3 ± 3.8	2.1 ± 1.5	0.12

P* < 0.01; *P* < 0.001

(ML *P* < 0.0001) resulted significantly shorter as well, likely due to the alteration of growth mainly of vectorial origin.

The values of ANB resulted higher (skeletal class II) in JIA patients versus the control group (*P* < 0.0001), in agreement with the literature. ANB is an angular measurement that refers

to the skeletal classification on the sagittal plane; the results showed that the upper maxilla is prevalent with respect to the mandible in JIA patients. Interestingly, the increase of ANB is not due to a bigger growth of the upper maxilla (SNA not significant), but to a decrease of the mandibular growth (SNB *P* < 0.0001). The skeletal class II of JIA patients is due to a severe lack of growth of the mandible likely related to the inflammatory status of the joints and, consequently, to the vectorial unbalance of the mandibular functions and impaired muscular activation. (Fig. 2).

Regarding the condyle, the percent difference between the right and left condylar height in orthopantomography resulted highly different from the control group, being the condyles of JIA children were much more asymmetric than those of normal children [1].

The results of this study showed that the growth pattern of JIA patients is clearly different from normal subjects and that the cephalometric and condylar values are related to the illness and to each other. The growth of the skull is a complex phenomenon due to genetic and environmental factors. Any pathological event will not act on one bone or district only but it will determine the reaction and compensation of all the neighboring structures with the aim to preserve the best function. To this end, the dentoalveolar compensation happens in JIA children to preserve occlusion and function despite the illness effects. Cephalometric characteristics of JIA patients could be explained considering that the condylar contribution to the growth process is hindered by the inflammatory status and that the growth of both the vertical ramus and the horizontal body of the mandible is decreased, requiring a dentoalveolar compensation during dental eruption. This leads

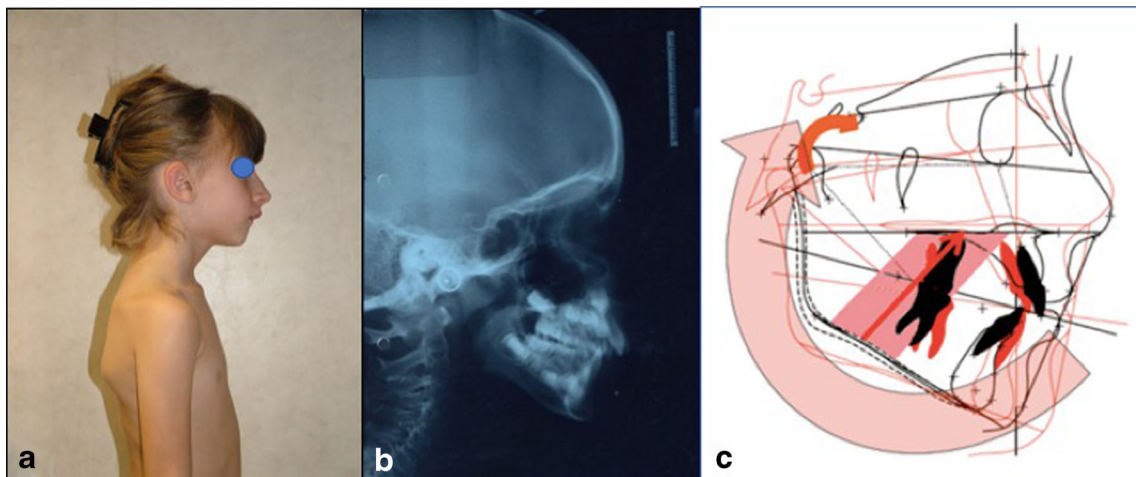


Fig. 2 **a** Image of the right profile of the face of a JIA patient. **b** Latero-lateral teleradiography of the same patient. **c** Cephalometry of the same patient showing in red the altered vectors working on the mandible and on the temporomandibular joint. The forces are carried out during swallowing and chewing. The altered vectors are due to the hyperdivergent cranial structure due to the insufficient growth of the vertical ramus of the mandible, as showed in this study. This is a critical cranial structure in non-JIA patients also; in JIA patients, the altered loads

on the temporomandibular joint are worsened by the inflammatory status of the systemic illness. The aim of the multidisciplinary treatment in JIA patients should be the control of the TMJ loads and mandibular vectors (orthognathodontists) together with the control of the inflammatory status (rheumatologists). Teeth are not the final aim, but a means to improve the functional balance. Any traumatic and anti-physiologic dental therapy, in those patients during growing, must be avoided to prevent a worsening of functional vectors and TMJ loads

to a typical hyperdivergent facial development with a serious backward rotation of the mandible, steep mandibular plane, decrease of the posterior facial height, and increase of the anterior one. The mandibular plane steepness together with the posterior mandibular rotation is due to the insufficient growth of the vertical ramus (ArGo) that resulted shorter with respect to the control group. This type of hyperdivergent craniofacial pattern of growth of JIA patients is related to the effects of the autoimmune disease leading to a hyperdivergent cranial structure that is highly unstable from a functional point of view and that is responsible for a progressive alteration of the neuromuscular coordination between sides. The force vector's alteration during chewing and swallowing changes and worsens the physiological development of facial bones.

But the results of this study also showed, in the same patients, a serious asymmetry of the height of the condyles between sides. It is intriguing to underline that the asymmetry of the condyles has been related to the hyperdivergency of the skull in previous studies of non-JIA subjects [6, 7], as described in the introduction of this article. This can explain part of the condylar asymmetry of JIA patients which severity is likely due to the fact that the effects of the inflammatory processes are more evident on the side where the skeletal instability and the muscular imbalance of the hyperdivergent skull cause the hyperloading.

These serious and undeniable features may be considered as an indicator of the need of early and continuous orthognathodontic therapy during the entire period of development of all JIA patients, independently of the presence of TMJ signs or symptoms. Identifying and diagnosing affected children at an early stage of development and at an early stage of the disease make it possible for an early orthognathodontic therapy aimed not to the repositioning of teeth within the dental arches, but to improving the balance of masticatory function and growth of the condyles during the developmental stages. Teeth alone are not the final aim, but a means to improve the functional balance that is the basic aim of any therapy, especially important for JIA patients.

The limitation of this study could be related to the limited number of patients and matched controls. However, the high significance obtained for all the homogeneous measurements let us clearly conclude that JIA patients undergo a special type of cranial growth that should be known by both the rheumatologists and orthognathodontists in order to set up a multidisciplinary treatment plan from the onset of the illness to reduce and control the side effects of a deranged growing pattern. To this end, it is important to strictly avoid in these patients any orthodontic therapy worsening function and growth; any traumatic, mechanical, and anti-physiologic dental therapy, especially during growing, risks much more than in normal subjects, the worsening of functional vectors; and the enhancement and unbalance of TMJ loads which, in turn, will be further aggravated by the inflammatory status of JIA. The

improvement of physiology and biology of the cranial development during orthognathodontic therapy can readily be obtained when the treatment choice is based on gnathological, non-mechanical concepts as well as the appliances used [23]. The simultaneous control of the unlucky restarts of the illness by rheumatologists is, of course, of utmost importance to avoid irreversible bone defects.

The conclusion of this study is due to the significant differences between children with and without JIA. These results are consistent with the special adaptive type of growth of the temporomandibular joint that is very sensible to the inflammatory environment during growing [24, 25]. This favors a craniofacial morphology with functional vectors at risk for temporomandibular joint derangement. The simultaneous rheumatological and gnathological intervention is important to plan the best multidisciplinary treatment aimed to protect and improve both growth and function of the temporomandibular joint.

Compliance with ethical standards

Disclosures None.

References

1. Piacino MG, Cannavale R, Dalmasso P, Tonni I, Filipello F, Perillo L, Cattalini M, Meini A (2015) Condylar asymmetry in patients with juvenile idiopathic arthritis: could it be a sign of a possible temporomandibular joints involvement? *Semin Arthritis Rheum* 45(2):208–213. <https://doi.org/10.1016/j.semarthrit.2015.04.012>
2. Kjellberg H, Fasth A, Kiliaridis S, Wenneberg B, Thilander B (1995) Craniofacial structure in children with juvenile chronic arthritis (JCA) compared with healthy children with ideal or postnormal occlusion. *Am J Orthod Dentofac Orthop* 107(1):67–78
3. Thilander B, Carlsson GE, Ingervall B (1976) Postnatal development of the human temporomandibular joint. I. A histological study. *Acta Odontol Scand* 34(2):117–126
4. Merida Velasco JR, Rodriguez Vazquez JF, De la Cuadra Blanco C, Campos Lopez R, Sanchez M, Merida Velasco JA (2009) Development of the mandibular condylar cartilage in human specimens of 10–15 weeks' gestation. *J Anat* 214(1):56–64. <https://doi.org/10.1111/j.1469-7580.2008.01009.x>
5. Durkin JF, Heeley JD, Irving JT (1973) The cartilage of the mandibular condyle. *Oral Sci Rev* 2(0):29–99
6. Chen F, Terada K, Wu L, Saito I (2007) Dental arch widths and mandibular-maxillary base width in Class III malocclusions with low, average and high MP-SN angles. *Angle Orthod* 77(1):36–41. <https://doi.org/10.2319/011006-15R.1>
7. Chen F, Wu L, Terada K, Saito I (2007) Longitudinal intermaxillary relationships in class III malocclusions with low and high mandibular plane angles. *Angle Orthod* 77(3):397–403. [https://doi.org/10.2319/0003-3219\(2007\)077\[0397:LIRICI\]2.0.CO;2](https://doi.org/10.2319/0003-3219(2007)077[0397:LIRICI]2.0.CO;2)
8. Fjeld M, Arvidsson L, Smith HJ, Flato B, Ogaard B, Larheim T (2010) Relationship between disease course in the temporomandibular joints and mandibular growth rotation in patients with juvenile idiopathic arthritis followed from childhood to

- adulthood. *Pediatr Rheumatol Online J* 8(13):13. <https://doi.org/10.1186/1546-0096-8-13>
9. Farronato G, Carletti V, Maspero C, Farronato D, Giannini L, Bellintani C (2009) Craniofacial growth in children affected by juvenile idiopathic arthritis involving the temporomandibular joint: functional therapy management. *J Clin Pediatr Dent* 33(4):351–357
 10. Hsieh YJ, Darvann TA, Hermann NV, Larsen P, Liao YF, Bjoern-Joergensen J, Kreiborg S (2016) Facial morphology in children and adolescents with juvenile idiopathic arthritis and moderate to severe temporomandibular joint involvement. *Am J Orthod Dentofac Orthop* 149(2):182–191. <https://doi.org/10.1016/j.ajodo.2015.07.033>
 11. Hu Y, Billiau AD, Verdonck A, Wouters C, Carels C (2009) Variation in dentofacial morphology and occlusion in juvenile idiopathic arthritis subjects: a case-control study. *Eur J Orthod* 31(1): 51–58. <https://doi.org/10.1093/ejo/cjn085>
 12. Kjellberg H, Kiliaridis S, Thilander B (1995) Dentofacial growth in orthodontically treated and untreated children with juvenile chronic arthritis (JCA). A comparison with Angle Class II division 1 subjects. *Eur J Orthod* 17(5):357–373
 13. Kjellberg H (1995) Juvenile chronic arthritis. Dentofacial morphology, growth, mandibular function and orthodontic treatment. *Swed Dent J Suppl* 109:1–56
 14. Kjellberg H (1998) Craniofacial growth in juvenile chronic arthritis. *Acta Odontol Scand* 56(6):360–365
 15. Mericle PM, Wilson VK, Moore TL, Hanna VE, Osborn TG, Rotskoff KS, Johnston LE Jr (1996) Effects of polyarticular and pauciarticular onset juvenile rheumatoid arthritis on facial and mandibular growth. *J Rheumatol* 23(1):159–165
 16. Ronchezel MV, Hilario MO, Goldenberg J, Lederman HM, Faltin K Jr, de Azevedo MF, Naspitz CK (1995) Temporomandibular joint and mandibular growth alterations in patients with juvenile rheumatoid arthritis. *J Rheumatol* 22(10):1956–1961
 17. Ronning O, Barnes SA, Pearson MH, Pledger DM (1994) Juvenile chronic arthritis: a cephalometric analysis of the facial skeleton. *Eur J Orthod* 16(1):53–62
 18. Sidiropoulou-Chatziagianni S, Papadopoulos MA, Kolokithas G (2001) Dentoskeletal morphology in children with juvenile idiopathic arthritis compared with healthy children. *J Orthod* 28(1): 53–58. <https://doi.org/10.1093/ortho/28.1.53>
 19. Stabrun AE (1991) Impaired mandibular growth and micrognathic development in children with juvenile rheumatoid arthritis. A longitudinal study of lateral cephalographs. *Eur J Orthod* 13(6):423–434
 20. Beukelman T, Patkar NM, Saag KG, Tolleson-Rinehart S, Cron RQ, DeWitt EM, Ilowite NT, Kimura Y, Laxer RM, Lovell DJ, Martini A, Rabinovich CE, Ruperto N (2011) 2011 American College of Rheumatology recommendations for the treatment of juvenile idiopathic arthritis: initiation and safety monitoring of therapeutic agents for the treatment of arthritis and systemic features. *Arthritis Care Res (Hoboken)* 63(4):465–482. <https://doi.org/10.1002/acr.20460>
 21. Wallace CA, Ruperto N, Giannini E, Childhood A, Rheumatology Research A, Pediatric Rheumatology International Trials O, Pediatric Rheumatology Collaborative Study G (2004) Preliminary criteria for clinical remission for select categories of juvenile idiopathic arthritis. *J Rheumatol* 31(11):2290–2294
 22. Habets LL, Bezuur JN, Naeiji M, Hansson TL (1988) The Orthopantomogram, an aid in diagnosis of temporomandibular joint problems. II The vertical symmetry. *J Oral Rehabil* 15(5): 465–471
 23. Piacino MG, Kyrkanides S (2016) Understanding masticatory function in unilateral crossbites. John Wiley & Sons Inc, Ames, Iowa USA.
 24. Isola G, Anastasi GP, Matarese G, Williams RC, Cutroneo G, Bracco P, Piacino MG (2017) Functional and molecular outcomes of the human masticatory muscles. *Oral Dis*. <https://doi.org/10.1111/odi.12806>
 25. Lux CJ, Raeth O, Burden D, Conratt C, Komposch G (2004) Sagittal and vertical growth of the jaws in Class II, Division 1 and Class II, Division 2 malocclusions during prepubertal and pubertal development. *J Orofac Orthop* 65(4):290–311. <https://doi.org/10.1007/s00056-004-0336-9>