



Title	Extrapleural pneumonectomy of recurrent thymoma with pleural dissemination
Author(s)	Shiia, Haruhiko; Hida, Yasuhiro; Kaga, Kichizo; Inoue, Rei; Nakada-Kubota, Reiko; Matsui, Yoshiro
Citation	Respirology case reports, 6(4), e00308 https://doi.org/10.1002/rcr2.308
Issue Date	2018-05
Doc URL	http://hdl.handle.net/2115/70891
Rights	Extrapleural pneumonectomy of recurrent thymoma with pleural dissemination, Shiia, H., Hida, Y., Kaga, K., Inoue, R., Nakada Kubota, R., Matsui, Y., Respirology Case Reports, vol.6, issue 4. © 2018 The Authors.
Rights(URL)	https://creativecommons.org/licenses/by-nc/4.0/
Type	article
File Information	Shiia_et_al-2018-Respirology_Case_Reports.pdf



[Instructions for use](#)

Extrapleural pneumonectomy of recurrent thymoma with pleural dissemination

Haruhiko Shiiya , Yasuhiro Hida, Kichizo Kaga, Rei Inoue, Reiko Nakada-Kubota & Yoshiro Matsui

Department of Cardiovascular and Thoracic Surgery, Hokkaido University Graduate School of Medicine, Sapporo, Hokkaido, Japan.

Keywords

Mediastinal tumour, mediastinum, pleural dissemination, thymoma.

Correspondence

Yasuhiro Hida, Department of Cardiovascular and Thoracic Surgery, Hokkaido University Graduate School of Medicine, Kita 15 Nishi 7, Kita-ku, Sapporo, 060-8638, Hokkaido, Japan.

E-mail: yhida@med.hokudai.ac.jp

Received: 19 December 2017; Revised: 29 January 2018; Accepted: 30 January 2018;

Associate Editor: Sjaak Burgers.

Respirology Case Reports, 6 (4), 2018, e00308

doi: 10.1002/rcr2.308

Abstract

Complete surgical resection has been considered the only curable treatment for thymoma. The efficacy of extrapleural pneumonectomy (EPP) for stage IV thymomas remains controversial. In this case report, we utilize EPP for recurrent thymoma with pleural dissemination and describe the resulting outcome. A 39-year-old female with a history of thoracoscopic thymectomy for type B2 thymoma was referred to our hospital for a recurrence of thymoma with pleural dissemination. She underwent EPP as a radical surgery. Histopathological investigation revealed complete resection. The postoperative course was uneventful. She returned to her full-time job and showed no sign of recurrence at 31 months after surgery. EPP for recurrent thymoma with pleural dissemination may be considered to achieve macroscopically complete resection when the patient is young and has a sufficient pulmonary function reservoir without preoperative complications.

Introduction

Complete surgical resection has been considered the only curable treatment for thymoma. Although some reports describe the efficacy of extrapleural pneumonectomy (EPP) for stage IV thymomas in limited cases, its efficacy remains controversial [1–3]. Only a few published reports examined EPP for pleural dissemination following thymectomy [1–4]. Previous studies that examined EPP for recurrent thymomas with pleural dissemination described only recurrence and survival rates after EPP, with no description of the postoperative course or the quality of life. In this case report, we utilize EPP for recurrent thymoma with pleural dissemination and describe the resulting outcome.

Case Report

A 39-year-old asymptomatic female with a history of thoracoscopic thymectomy for type B2 thymoma was referred to a local general hospital for an abnormal left mediastinal shadow detected on a chest X-ray. All of the laboratory tests were normal. A chest computed tomography (CT) scan showed disseminated tumours on the left

parietal, mediastinal, and visceral pleurae, with possible invasion into the lungs and pericardium (Fig. 1). A percutaneous needle biopsy revealed recurrence of the thymoma. A positron emission tomography (PET)-CT scan demonstrated fluorodeoxyglucose (FDG) uptake in disseminated tumours (Fig. 2) and no evidence of distant metastasis. She was referred to our department and underwent EPP. The patient was placed in the right lateral decubitus position, and a left lateral thoracotomy was performed through the seventh rib bed. The third rib and the intercostal muscle, which was used as an access port in a previous operation on the primary tumour 13 years ago, were resected due to a tumour implantation. The left phrenic nerve, the pericardium, and the diaphragm were all resected because of tumour invasion. The pericardium and the diaphragm were reconstructed with a polytetrafluoroethylene patch. The upper and lower mediastinal lymph nodes were dissected, and the EPP was completed with macroscopically complete resection. The operative time was 499 min, and the estimated blood loss was 1090 mL.

Histopathological examination revealed that the tumour was a type B2 thymoma, with direct invasion into the pericardium, the mediastinal fat tissue, the hilar lymph nodes, the third rib, and the intercostal muscle. However,

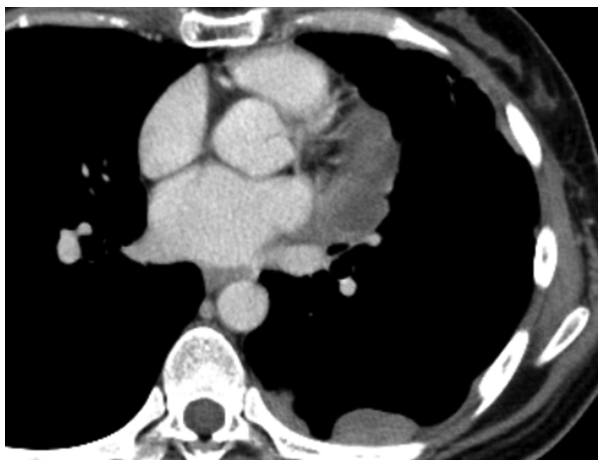

Figure 1. The preoperative chest computed tomography (CT). The CT image shows disseminated nodules in the left pleural cavity. We detected tumours that were adjacent to the pericardium, which indicated the possibility of pericardium invasion.

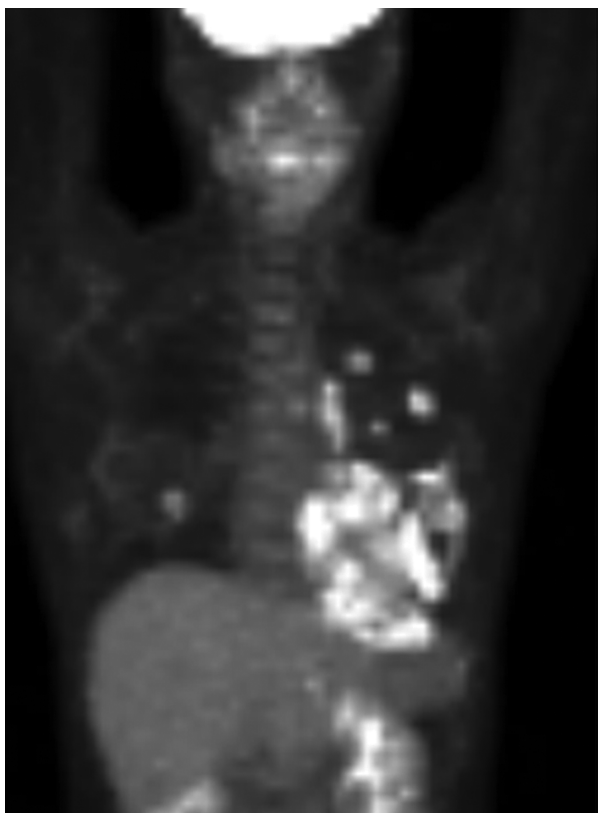


Figure 2. The preoperative fluorodeoxyglucose-positron emission tomography (FDG-PET) scan. The FDG-PET scan showed significant dissemination in the left pleural cavity.

exposure to the pericardial cavity or invasion into the cardiac muscle was not found (Fig. 3). The histopathological analysis also showed that there was no microscopical

positive surgical margin, although it would be impossible to completely deny any positive margin in the specimen where the section was not made.

The postoperative course was uneventful, except for persistent pain that required 37 days of hospitalization. She returned to her full-time job at 9 months after surgery and showed no sign of recurrence at 31 months after surgery.

Discussion

Complete surgical resection is crucial for achieving a good survival outcome in patients with primary or recurrent thymoma [4]. Okuda et al. reported that even in stage IVA thymoma cases with disseminated nodules, macroscopically complete resection yielded a better outcome [5]. A few reports have demonstrated the efficacy of EPP for complete resection of pleural dissemination in selected cases [1–3]. However, the indication of EPP as a radical surgery for pleural dissemination remains controversial. Okuda et al. [5] concluded that EPP should be utilized conservatively because of the high operative mortality and the low postoperative quality of life. Ishikawa et al. [1] and Write [2] claimed that patients undergoing EPP should be young and exhibit excellent cardiopulmonary function. Furthermore, patients with metastatic disease should be excluded, and if myasthenia gravis is present, it must be well controlled. Moreover, Fabre et al. [3] reported that good functional status with a predictive forced expiratory volume in 1 s (FEV_1) value of >50% is required. In this case, the patient was young, lacked preoperative complications, had preoperative high levels of daily physical activity, and her pulmonary functional test was within the normal range.

There have been few reports examining EPP for recurrent thymoma with pleural dissemination [1–4]. Most of the previous reports only described the survival or recurrence rates following EPP. They did not describe postoperative quality of life, general conditions, and daily activity levels in detail. The postoperative course of our patient was uneventful, and she returned to her full-time job 9 months after surgery. This treatment may achieve a better prognosis with an acceptable postoperative quality of life if adequately utilized. As the primary treatment failed over 12 years, longer follow up would be mandatory following the second surgery.

We conclude that young fit patients would tolerate EPP for recurrent thymoma with pleural dissemination.

Disclosure Statement

Appropriate written informed consent was obtained for publication of this case report and accompanying images.

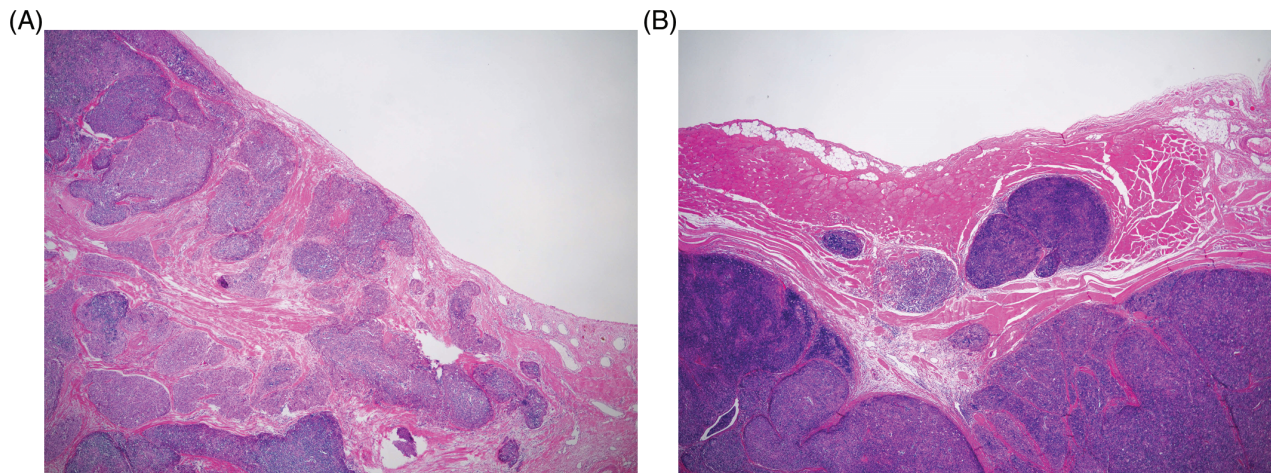


Figure 3. The pathological findings. The haematoxylin and eosin stain shows that the tumour was not exposed to the pericardial space (A) or the peritoneum (B).

References

1. Ishikawa Y, Matsuguma H, Nakahara R, et al. 2009. Multimodality therapy for patients with invasive thymoma disseminated into the pleural cavity: the potential role of extrapleural pneumonectomy. *Ann. Thorac. Surg.* 88:952–957.
2. Wright CD. 2006. Pleuropneumonectomy for the treatment of Masaoka stage IVA thymoma. *Ann. Thorac. Surg.* 82:1234–1239.
3. Fabre D, Fadel E, Mussot S, et al. 2011. Long-term outcome of pleuropneumonectomy for Masaoka stage IVa thymoma. *Eur. J. Cardiothorac. Surg.* 39:e133–e138.
4. Marulli G, Margaritora S, Lucchi M, et al. 2016. Surgical treatment of recurrent thymoma: is it worthwhile? *Eur. J. Cardiothorac. Surg.* 49:327–332.
5. Okuda K, Yano M, Yoshino I, et al. 2014. Thymoma patients with pleural dissemination: nationwide retrospective study of 136 cases in Japan. *Ann. Thorac. Surg.* 97:1743–1748.