

Assessment of the maximum uptake time of ^{99m}Tc -DMSA in renal scintigraphy in rat

Original Article

Kaveh Tanha¹, Hossein Fatemikia², Majid Assadi¹, Mohammad Seyedabadi¹

¹The Persian Gulf Nuclear Medicine Research Center, Bushehr University of Medical Sciences, Bushehr, Iran

²Department of Physiology, School of Medicine, Bushehr University of Medical Sciences, Bushehr, Iran

(Received 25 December 2016, Revised 6 March 2017, Accepted 7 March 2017)

ABSTRACT

Introduction: The optimal imaging time of a radionuclide scintigraphy is the time at which the organ of interest has the maximum uptake of the injected radionuclide. This study was performed to investigate the maximum uptake time of ^{99m}Tc -DMSA in rat renal scan.

Methods: Renal scintigraphy was performed with 3 mCi of ^{99m}Tc -DMSA. Planar images were acquired every 20 minutes for 8 hours post-injection using a small-animal SPECT.

Results: Activity and the count rate per pixel (CRPP) of the kidneys peaked 1 h post-injection, plateaued for about 1 h, and declined time-dependently. Kidney to background ratio (KBR) reached to 61.7% at 1 h after injection and remained almost constant afterwards.

Conclusion: The kidneys had maximum emission and CRPP between 1 to 2 h after ^{99m}Tc -DMSA injection, whereas there was no significant difference between the KBRs after 1 h. Our results showed that image acquisition of 1-2 h post-injection is recommended for renal scintigraphy with DMSA in rat.

Key words: Small animal imaging; Renal scintigraphy; Maximum uptake time; ^{99m}Tc -DMSA

Iran J Nucl Med 2017;25(2):110-114

Published: July, 2017

<http://irjnm.tums.ac.ir>

Corresponding author: Mohammad Seyedabadi, The Persian Gulf Nuclear Medicine Research Center, Bushehr University of Medical Sciences, Moallem St., Bushehr, Iran. E-mail: seyedabadi1981@gmail.com

INTRODUCTION

Radionuclide imaging techniques are widely used in preclinical and clinical studies [1]. Recent development of small-animal SPECT imaging systems can be applied for quantitative in vivo imaging using gamma-emitter radionuclides [2]. Such modalities provide non-invasive methods for the assessment of pharmacological parameters in living animals.

The time course of radionuclide concentration in the organs of interest depends on the tracer itself as well as the organ physiology. The interval between injection and acquisition as well as the duration of acquisition time should be optimized for each radiotracer [3, 4].

Renal scintigraphy using dimercaptosuccinic acid labeled with Technetium-99m (^{99m}Tc -DMSA) is considered as the protocol of choice for the assessment of relative renal function and cortical integrity in clinical practice [5, 6]. It is also implemented for the investigation of renal disorders using animal models in several preclinical studies [2, 7, 8]. Although a period of 2 to 6 hours have been used in different studies [7, 9, 10], the optimal time of imaging is yet to be elucidated. Having a detailed understanding of the distribution of the radionuclide helps find the appropriate time of imaging which would be the time of maximum uptake of the radionuclide in the organ of interest.

In this study we investigated the time of maximum uptake of ^{99m}Tc -DMSA scan in rats with a dedicated dual-headed gamma camera for small-animal radionuclide imaging.

METHODS

Imaging system

Imaging was conducted using HiReSPECT, a small-animal SPECT. The imaging system consisted of two gamma cameras containing two flat panel PSPMTs with an active detection area of about 100 mm \times 50 mm. Each pair of H8500C PSPMTs had been fixed to a CsI(Na) crystal (80 \times 38 pixel) with pixel size of 1mm \times 1mm \times 5 mm. Each head was equipped with a high resolution parallel-hole collimator. The image spatial resolutions and the planar spatial resolution of the system at the head surface were 1.2–1.6 mm and 1.7 mm, respectively. The system sensitivity at the collimator surface and 8 cm from the collimator surfaces were about 1.30 cps/mCi and 1.18 cps/mCi, respectively [11, 14].

Animal scan

Pertechnetate $^{99m}\text{TcO}_4$ was eluted from technetium-99m generator containing molybdenum-99. The extracted 40 mCi of activity was added to ^{99m}Tc -

DMSA kit vial in accordance with the manufacturer's instructions. Briefly, normal saline was added to the vial content to reach a final volume of 2 ml. The vial was then shook vigorously for 1 min, and incubated at room temperature for 10 min. The radiotracer activities in syringe were measured using a dose-calibrator (CRC-25R, Capintec, Inc.) before and after the injection.

Time course of the maximum radionuclide uptake in the kidneys was evaluated by injection of 3 mCi of ^{99m}Tc -DMSA in 3 rats. The tracer was administered through the tail vein under general anesthesia; animals were anaesthetized with Ketamine (100 mg/kg) and Xylazine (10 mg/kg). Imaging was carried out 20 min after DMSA delivery and continued for 8 h post-injection. Two opposed (ventral and dorsal) images were acquired every 20 min.

All Animal experiments performed in accordance to the ethic committee of animal research instructions.

Image analysis

Regions of interest (ROI) were drawn manually around the kidneys and small areas of surrounding tissue as backgrounds for each kidney. After background correction, the distribution of the activity in each kidney calculated by geometric mean of the counts within the ROIs in anterior and posterior images. The sum of calculated left and right kidney counts was assigned as total uptake. Kidney uptakes were expressed as the number of photon counts, count-rate-per-pixel (CRPP) and the relative kidney uptake which calculated as kidney count to background counts ratio (KBR).

RESULTS

Figure 1 depicts the uptake of ^{99m}Tc -DMSA in the kidneys over a time span of 8 h post-injection. The background activity was approximately twice that of the kidneys 20 min post-injection. While the former declined gradually, the latter increased over time (Figure 1a). In particular, kidney counts boomed dramatically over the next 20 min, and continued to increase reaching its peak at 1 h post-injection. Then, it remained almost constant for 60 min, after which it began to decline time-dependently. The CRPP followed a similar pattern (Figure 1b). It increased from 1.89 at 20 min post-injection to 3.17 in 1 h. Then, it remained almost constant for 60 min and decreased to 1.89 at the end of the experiment.

Initial KBR was 37.6%. It climbed significantly to 57% over the next 20 min. then, the slope decreased reaching a plateau after 1 h, and maintained almost the same level over the timespan of study (Figure 1c).

Figure 1 indicates that the activity concentration in the kidney peaked at 60 min after injection and remained unchanged for 1 h.

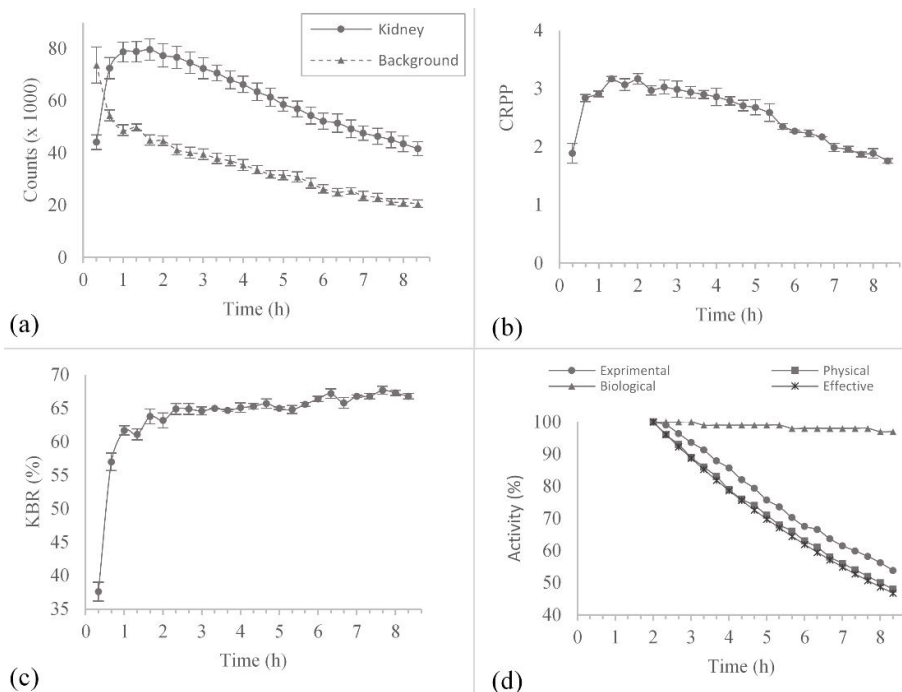


Fig 1. The uptake of ^{99m}Tc -DMSA in the kidneys over a time span of 8 h post-injection.

Hence, the relative activity of the kidney in a specific time was calculated by normalizing the kidney counts at that time to the activity at 2 h post-injection. Physical (T_p) and biological (T_b) half-lives of ^{99m}Tc -DMSA are 6 h and 6.5 days, respectively [15]. Calculated effective half-life (T_e) was obtained from formula 1, and found to be 346.7 min.

$$T_e = \frac{T_p \times T_b}{T_p + T_b} \quad (\text{Formula 1})$$

Radionuclide decay rate was calculated from formula 2. The calculated half-life of ^{99m}Tc -DMSA found to be 408.5 min which is comparable to its physical and effective half-lives (Figure 1d).

$$N = N_0 e^{-\frac{\ln 2}{T_{1/2}} t} \quad (\text{Formula 2})$$

Figure 2 shows the planar images of the rats. As indicated in the figure, the kidneys have maximum uptake at the 2nd hour post-injection. After 2 h kidney counts as well as the background activity declined over the time. This leads to an almost constant KBR which indicated in the Figure 1c.

DISCUSSION

Renal scintigraphy using ^{99m}Tc -DMSA is the preferred method for the assessment of kidney function [16, 17]. However, data about the appropriate time of this radionuclide imaging is limited [2, 7, 8]. The time interval between radionuclide injection and imaging in these studies varies from 2 to 6 h [3, 18, 19]. In this study we aimed to find the appropriate time of imaging

for ^{99m}Tc -DMSA renal scintigraphy using a parallel hole dual-head small-animal imaging system.

The amount of kidney counts increased over time to reach a plateau at 1 h post-injection (Figure 1a). After peaking, kidney count plateaued for about 1 h and declined in a time-dependent manner. The KBR summited at 1 h after injection and remained almost constant over the course of experiment. This implies that after reaching the plateau both the background and kidney counts decreased with the same coefficient. The results of this study are comparable to that of Taylor et al. They studied the biodistribution of DMSA in rats at 0.5, 2, and 24 h after injection. They showed that radionuclide renal uptake reached to its maximum 0.5 h after injection, and remained constant for 24 h. In addition, they found that background activity decreased substantially, and KBR was considerably higher at 24 h than at the other two points [3].

Figure 1a indicates that the kidney count had a peak value at 1 h post-injection and decreased after 2 h. Considering the physical half-life of the ^{99m}Tc (about 6 h), the biological half-life of the ^{99m}Tc -DMSA (about 6.5 days) [15] and calculated effective half-life of this radionuclide (346.7 min), we found an agreement between the decrease of kidney counts over time with the curve of ^{99m}Tc -DMSA physical decay. As depicted in Figure 1d, the amount of kidney count decreased time-dependently with a half-life of close to the physical and effective half-lives, while the ratio of the kidney counts to background counts is constant.

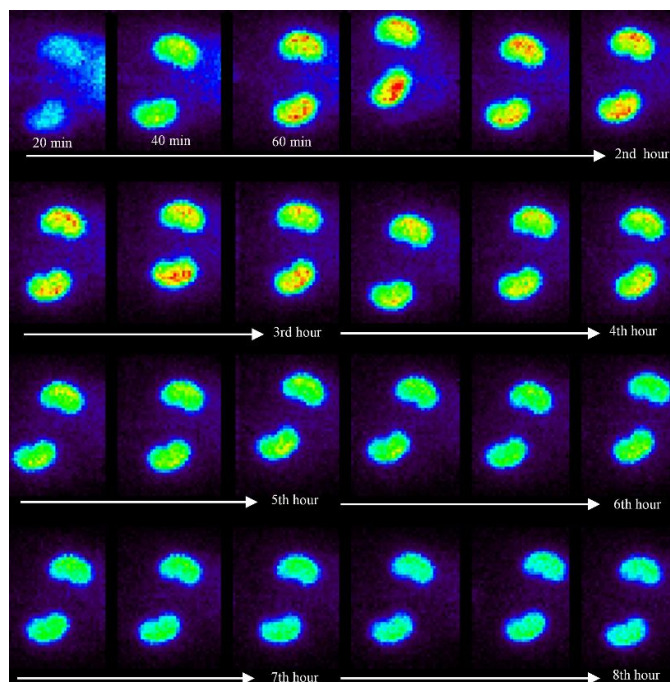


Fig 2. Renal scintigraphy with ^{99m}Tc -DMSA in rats (the planar images).

The results of this experiment are comparable to that of Correia et al. They showed that kidney uptake in mice renal scintigraphy peaked 30 min after ^{99m}Tc -DMSA injection, remained steady for 1 h, and declined quickly over the course of the study. In fact, they acquired images 0.5, 1, 5 and 12 h post-injection [20], whereas we followed each rat and continued to image the animals every 20 min for 8 h post-injection. Hence, our study provides more detailed understanding of the DMSA uptake during the early phase after injection.

Maximum amount of the KBR reflects the contrast between the organ of interest and the surrounding tissue. Hence, the appropriate time for ^{99m}Tc -DMSA scintigraphy is the time at which renal uptake of radionuclide and KBR are at their maximum level. Our results showed that imaging in a time span of 1 to at least 8 h post-injection can produce similar results in terms of kidney to background count ratio. Also, it could be concluded that the appropriate time for ^{99m}Tc -DMSA scintigraphy using low sensitivity imaging systems is between the 1st and the 2nd hours after radionuclide injection, because of the higher activity of the kidneys in this period.

Taken together, the kidneys had maximum emission and CRPP between 1 to 2 h after ^{99m}Tc -DMSA injection. On the other hand, KBR remained constant after 1 h.

CONCLUSION

Image acquisition of 1-2 h post-injection is recommended for renal scintigraphy with ^{99m}Tc -DMSA in rats. We studied the maximum uptake time of ^{99m}Tc -DMSA for 3 rats and more pre-clinical or clinical studies with larger samples are required to confirm the results of this study.

Acknowledgement

This study has been supported by the Deputy of Research, Bushehr University of Medical Sciences [grant number: 5427].

REFERENCES

1. Rudin M, Weissleder R. Molecular imaging in drug discovery and development. *Nat Rev Drug Discov.* 2003 Feb;2(2):123-31.
2. Franc BL, Acton PD, Mari C, Hasegawa BH. Small-animal SPECT and SPECT/CT: important tools for preclinical investigation. *J Nucl Med.* 2008 Oct;49(10):1651-63.
3. Taylor A Jr, Lallone RL, Hagan PL. Optimal handling of dimercaptosuccinic acid for quantitative renal scanning. *J Nucl Med.* 1980 Dec;21(12):1190-3.
4. Duvall WL, Croft LB, Ginsberg ES, Einstein AJ, Guma KA, George T, Henzlova MJ. Reduced isotope dose and imaging time with a high-efficiency CZT SPECT camera. *J Nucl Cardiol.* 2011 Oct;18(5):847-57.
5. Ardelá Díaz E, Miguel Martínez B, Gutiérrez Dueñas JM, Díez Pascual R, García Arcal D, Domínguez Vallejo FJ.

- Comparative study of differential renal function by DMSA and MAG-3 in congenital unilateral uropathies. *Cir Pediatr*. 2002 Jul;15(3):118-21.
6. Piepsz A, Blaufox MD, Gordon I, Granerus G, Majd M, O'Reilly P, Rosenberg AR, Rossleigh MA, Sixt R. Consensus on renal cortical scintigraphy in children with urinary tract infection. Scientific Committee of Radionuclides in Nephrourology. *Semin Nucl Med*. 1999 Apr;29(2):160-74.
 7. Kwak W, Jang HS, Belay T, Kim J, Ha YS, Lee SW, Ahn BC, Lee J, Park KM, Yoo J. Evaluation of kidney repair capacity using ^{99m}Tc-DMSA in ischemia/reperfusion injury models. *Biochem Biophys Res Commun*. 2011 Mar 4;406(1):7-12.
 8. Cabuk M, Gurel A, Sen F, Demircan N. Renoprotective effect of erdosteine in rats against gentamicin nephrotoxicity: a comparison of ^{99m}Tc-DMSA uptake with biochemical studies. *Mol Cell Biochem*. 2008 Jan;308(1-2):35-42.
 9. Silva-Rodríguez J, Cortés J, Pardo-Montero J, Pérez-Fentes D, Herranz M, Ruibal Á, Aguiar P. In vivo quantification of renal function in mice using clinical gamma cameras. *Phys Med*. 2015 May;31(3):242-7.
 10. Forrer F, Valkema R, Bernard B, Schramm NU, Hoppin JW, Rolleman E, Krenning EP, de Jong M. In vivo radionuclide uptake quantification using a multi-pinhole SPECT system to predict renal function in small animals. *Eur J Nucl Med Mol Imaging*. 2006 Oct;33(10):1214-7.
 11. Pashazadeh A, Tanha K, Jafarian-Dehkordi F, Assadi M, Moji V, Zeraatkar N, Ay MR. Experimental evaluation of the performance of HiReSPECT scanner: A high-resolution SPECT system for small animal imaging. *Front Biomed Technol*. 2014;1(3):222-227.
 12. Moji V, Zeraatkar N, Farahani MH, Aghamiri MR, Sajedi S, Teimourian B, Ghafarian P, Sarkar S, Ay MR. Performance evaluation of a newly developed high-resolution, dual-head animal SPECT system based on the NEMA NU1-2007 standard. *J Appl Clin Med Phys*. 2014 Nov;15(6):267-278.
 13. Gerdekoohi SK, Vosoughi N, Tanha K, Assadi M, Ay M. Evaluation of quantitative accuracy of Tc-99m small-animal SPECT imaging in phantom studies. *Eur J Nucl Med Mol Imaging*. 2016;43(Suppl 1):S475.
 14. Gerdekoohi, S. Khorasani; Vosoughi, N.; Tanha K. A Study on the effect of attenuation correction in image quantity in small-animal SPECT system. *Eur J Nucl Med Mol Imaging*. 2016;43(Suppl 1):S220.
 15. Moretti JL, Rapin JR, Saccavini JC, Lageron A, Le Poncin M, Bardy A. 2,3-Dimercaptosuccinic-acid chelates--2. Renal localization. *Int J Nucl Med Biol*. 1984;11(3-4):275-9.
 16. Ajdinović B, Jauković L, Krstić Z, Dopuda M. Technetium-99m-dimercaptosuccinic acid renal scintigraphy in children with urinary tract infections. *Hell J Nucl Med*. 2006 Jan-Apr;9(1):27-30.
 17. Jouret F, Walrand S, Parreira KS, Courtoy PJ, Pauwels S, Devuyt O, Jamar F. Single photon emission-computed tomography (SPECT) for functional investigation of the proximal tubule in conscious mice. *Am J Physiol Renal Physiol*. 2010 Feb;298(2):F454-60.
 18. Groshar D, Frankel A, Iosilevsky G, Israel O, Moskovitz B, Levin DR, Front D. Quantitation of renal uptake of technetium-99m DMSA using SPECT. *J Nucl Med*. 1989 Feb;30(2):246-50.
 19. Carlson SK, Classic KL, Hadac EM, Bender CE, Kemp BJ, Lowe VJ, Hoskin TL, Russell SJ. In vivo quantitation of intratumoral radioisotope uptake using micro-single photon emission computed tomography/computed tomography. *Mol Imaging Biol*. 2006 Nov-Dec;8(6):324-32.
 20. Correia MB, Magnata SS, Silva IM, Catanho MT, Lima FF. Biokinetics and dosimetric studies about ^{99m}Tc(V)-DMSA distribution. *Cell Mol Biol (Noisy-le-grand)*. 2010 May 10;56(2):1-5.