

Eur Spine J (2008) 17:255–261
DOI 10.1007/s00586-007-0558-9

ORIGINAL ARTICLE

Scoliosis correction with pedicle screws in Duchenne muscular dystrophy

Frederik Hahn · Dominik Hauser · Norman Espinosa · Stefan Blumenthal · Kan Min

Received: 3 August 2007 / Revised: 21 October 2007 / Accepted: 15 November 2007 / Published online: 4 December 2007
© Springer-Verlag 2007

Abstract This report describes the spinal fixation with pedicle-screw-alone constructs for the posterior correction of scoliosis in patients suffering from Duchenne muscular dystrophy (DMD). Twenty consecutive patients were prospectively followed up for an average of 5.2 years (min 2 years). All patients were instrumented from T3/T4 to the pelvis. Pelvic fixation was done with iliac screws similar to Galveston technique. The combination of L5 pedicle screws and iliac screws provided a stable caudal foundation. An average of 16 pedicle screws was used per patient. The mean total blood loss was 3.7 l, stay at the intensive care unit was 77 h and hospital stay was 19 days. Rigid stabilisation allowed immediate mobilisation of the patient in the wheel chair. Cobb angle improved 77% from 44° to 10°, pelvic tilt improved 65% from 14° to 3°. Lumbar lordosis improved significantly from 20° to 49°, thoracic kyphosis remained unchanged. No problems related to iliac fixation, no pseudarthrosis or implant failures were observed. The average percentage of predicted forced vital capacity (%FVC) of the patients was 55% (22–94%) pre-operatively and decreased to 44% at the last follow-up. There were no pulmonary complications. One patient with a known cardiomyopathy died intraoperatively due to a sudden cardiac arrest. The rigid primary stability with

pedicle screws allowed early mobilisation of the patients, which helped to avoid pulmonary complications.

Keywords Duchenne muscular dystrophy · Scoliosis · Pedicle screw instrumentation · Pulmonary function · Cardiomyopathy

Introduction

Duchenne muscular dystrophy (DMD) is one of the most common and severe muscular dystrophies [11, 18, 22, 28]. Cardio-respiratory complications lead to death in late adolescence or early adulthood. A progressive scoliosis develops in 50–95% of patients with DMD [9, 19]. The scoliosis is typically a long C-shaped curve involving the thoracic and lumbar spine. The resulting pelvic obliquity together with weakness of the spinal musculature impairs the sitting ability in wheelchair. Bracing is known to be ineffective to stop the progression of scoliosis in these children [9, 28]. Spinal stabilisation is recommended to correct the spinal deformity, pelvic obliquity and to prevent further progression. This improves the sitting ability and the quality of life [22, 28, 42]. The pulmonary function deteriorates progressively in the patients with DMD [17, 25]. Whether the spinal stabilisation reduces the rate of deterioration in lung function is a subject of controversy [24, 30, 36]. Existing reports on the surgical correction of scoliosis mostly deal with the instrumentation of the spine using hooks and wires or hybrid constructs with pedicle screws in lumbar region. The use of pedicle screw constructs in thoracic spine has recently become established in the treatment of idiopathic scoliosis [5, 26, 32]. To date there is no report about the use of pedicle-screw-alone constructs in the treatment of scoliosis in patients with

F. Hahn · D. Hauser · N. Espinosa · K. Min (✉)
Department of Orthopaedics, Balgrist Clinic,
University of Zurich, Forchstrasse 340,
CH-8008 Zurich, Switzerland
e-mail: kan.min@balgrist.ch

S. Blumenthal
Department of Anaesthesiology, Balgrist Clinic,
University of Zurich, Forchstrasse 340,
CH-8008 Zurich, Switzerland

DMD. In the present prospective study we describe the use of a pedicle-screw-alone construct for the posterior correction of scoliosis in patients with DMD. We report the clinical, radiological results and changes in the pulmonary function.

Material and methods

Patients with DMD who had posterior spinal fusion for progressive scoliosis were prospectively followed up and the data of the patients were analysed. Twenty consecutive operated patients with a minimal follow-up of 2 years were analysed. Pedicle-screw-alone constructs using a stainless steel implant were used in all patients. The mean age at operation was 14 (10–19) years. The age at wheel-chair bound averaged 10 (7–14) years. Indication for operation was a progressive scoliosis of more than 20° in Cobb angle.

Preoperative and postoperative clinical and laboratory examinations were documented. Cardiac function was assessed preoperatively by transthoracic echocardiography and electrocardiogram. Pulmonary function was measured preoperatively and at regular intervals during the follow-up using a standard spirometry. All patients were operated by the senior author (K.M). The data analysis and clinical examination at the last follow-up were carried out by others not directly involved in the care of the patient.

The instrumentation was done from T3 or T4 to the pelvis. Fixation of the spine was carried out with pedicle screws in the thoracic as well as in the lumbar spine. Pedicle screws with a diameter of 5 mm and 6 mm were used in the thoracic and the lumbar spine respectively. Anatomical landmarks were used to insert the screws. A C-arm was occasionally used to control the position of the screw. As osteoporosis is a matter of concern in patients with DMD, long screws with a purchase of at least 75% of the vertebral body were inserted. Pelvic fixation was done with a 6 or 7 mm diameter pedicle screw in each iliac wing similar to the Galveston technique [2]. No additional screws were inserted in the sacrum, the sacropelvic fixation being achieved by means of iliac screws alone (Fig. 1A and B). Not all the vertebrae of the curve were instrumented. Every other vertebra in the main lumbar region and every second or third vertebra in the upper thoracic region were instrumented. The average number of pedicle screws used was 16 (14–20) per patient. Locally harvested autologous bone was mixed with allograft for the interarticular and interlaminar fusion including the lumbosacral junction.

Anteroposterior and lateral radiographs of the whole spine in sitting were taken in all patients preoperatively and during the follow-up. The Cobb angle of the scoliosis, the pelvic tilt, the thoracic kyphosis (T4–T12) and the lumbar lordosis (L1–S1) were measured from the radiographs

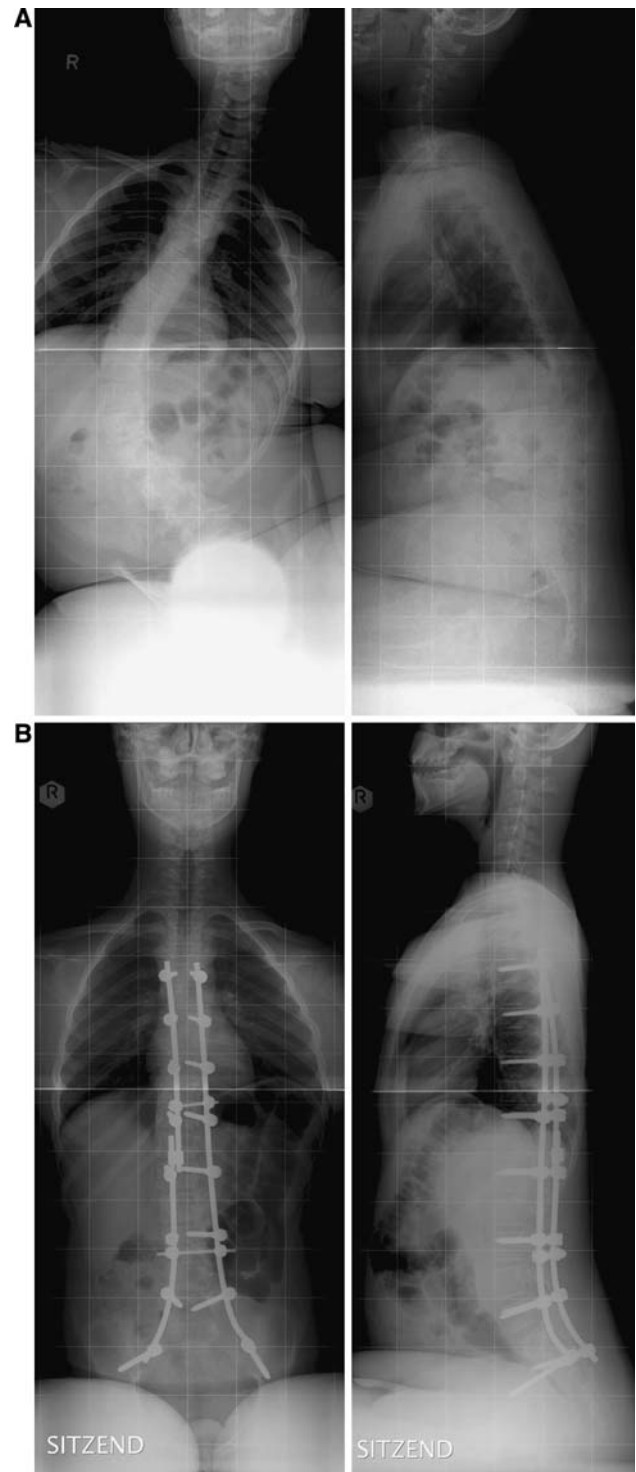


Fig. 1 (a) Sitting ap and lateral radiographs preoperative (b) postoperative

preoperatively, 3 months postoperatively and at the last follow-up.

For statistical analysis standard descriptive analysis and the Wilcoxon Rank Test (level of significance $P = 0.05$) for detection of differences were used.

Results

One patient died. The remaining 19 patients were reviewed with an average follow-up of 5.2 (range 2.3–9.7) years. At time of the data analysis, the average age of the patients was 19.44 (range 14.3–26.3) years. Average operation time from skin incision to application of wound dressing was 307 (205–410) min. Estimated intraoperative blood loss was an average of 2,642 (1,300–5,000) ml. Intraoperative blood loss was collected in cell saver and an average of 853 ml was re-transfused. Blood from the wound drains was not collected for re-transfusion. A total blood loss of 3.7 l (range 2.2–6.5 l) after removal of the drains was measured. An average of 3.2 (1–6) units of donor erythrocyte concentrates were substituted per patient. The average stay on the intensive care unit was 77 (46–152) h. Mobilisation in the wheel chair began on the first postoperative day in all patients except in one in whom a prolonged weaning from the respirator was necessary. The duration of hospitalisation was 19 days (range 11–41). The patients were directly discharged to their homes, not to a rehabilitation clinic.

There was an improvement of the Cobb angle of 77% (range 60–100%, $P < 0.001$, Table 1) with a preoperative average of 44° (range 22–90°) to postoperative 10° (0–25°). The scoliosis at the last follow-up was 9° (range 0–22°). The pelvic tilt improved 65% (range –40–100%, $P < 0.001$) from an average of 14° (range 2–40°) preoperatively to 3° (range 0–8°) postoperatively and 3° (range 0–8°) at the last follow-up. The changes of Cobb angle and pelvic tilt from the 3-month postoperative control to the last follow-up were statistically not significant. There was no loss of correction. Balanced sitting posture was achieved and maintained in all patients. Thoracic kyphosis was statistically unchanged with a preoperative value of 12° (range 0–50°), 16° (5–28°) postoperatively and 17° (8–28°) at last follow-up (Table 2). We did not observe any junctional kyphosis above T4. The lumbar lordosis improved significantly from an average of 20° (0–68°) preoperatively to 49° (35–70°, $P < 0.001$) 3-month postoperatively and to 48° (40–65°) at the last follow-up. There was no pseudarthrosis, implant loosening or implant failure in any patient.

FVC decreased from a preoperative mean of 1.81 L (1–3.5) to 1.72 L (0.4–3.5) at one year follow up and decreased further to 1.58 L (range 0.34–4.88) at the last follow-up (Table 3). However, these changes were statistically not significant. The average percentage of predicted forced vital capacity (%FVC) of the patients was 55% (22–94%) preoperatively, 54% (12–97%) at one year follow-up and 47% (12–122%) at the last follow-up. The decline in %FVC between preoperative and at last follow-up was statistically significant ($P < 0.03$). Before the

Table 1 Radiographic parameters for coronal plane

Pat	Cobb angle (°)				Pelvic tilt (°)			
	preop	postop	f-up	correc tion (%)	preop	Postop	f-up	correc tion (%)
1	42	10	9	76	8	6	3	25
2	24	5	3	79	3	0	0	100
3	90	25	20	72	40	8	7	80
4	60	23	22	62	20	0	0	100
5	30	11	10	63	2	0	6	100
6	70	17	15	76	22	0	0	100
7	45	17	18	62	16	5	8	69
8	25	4	3	84	14	4	5	71
9	64	16	15	75	15	4	0	73
10	51	8	8	84	25	0	5	100
11	35	0	0	100	6	2	2	67
12	22	4	5	82	7	4	0	43
13	64	0	2	100	35	6	1	83
14	30	4	5	87	4	3	5	25
15	43	10	11	77	5	7	4	–40
16	25	10	5	60	15	7	4	53
17	25	10	10	60	3	3	3	0
18	35	7	7	80	15	2	0	87
19	60	7	7	88	10	0	0	100
Mean	44.2	9.9	9.2	77.2	13.9	3.2	2.8	65.0
SD	19	7	6	12	11	3	3	39
Min	22	0	0	60	2	0	0	–40
Max	90	25	22	100	40	8	8	100

operation, none of the patients needed respiratory assistance. During follow-up period four patients required nocturnal non-invasive ventilatory assistance and one patient a permanent ventilatory assistance through a tracheostomy. All patients were alive at the last follow-up.

Complications

One patient died intraoperatively. By the end of the operation a sudden cardiac arrest occurred in this 18.5-year-old patient. Reanimation attempts failed. He had a known cardiomyopathy with a fractional shortening of 21% and ventricular ejection fraction of 45% in the preoperative echocardiography. His %FVC was 63% (2.5 L). In one patient a prolonged weaning from the respirator was necessary, because of an early postoperative pulmonary oedema. He was disconnected from the respirator on the second postoperative day and had no further pulmonary problems. The preoperative %FVC of this patient was 22%. Superficial wound healing problems occurred in one obese patient which caused a lengthy hospital stay of 41 days. In one patient a late implant infection with *Propionibacterium acnes* developed 1.5 years after surgery. On implant

Table 2 Radiographic parameters for sagittal plane (n.f. = not feasible)

Pat	Thoracic-kyphosis (°)			Lumbar-lordosis (°)		
	preop	postop	f-up	preop	postop	f-up
1	30	26	22	18	50	45
2	20	14	16	30	48	53
3	5	8	8	5	50	50
4	8	25	18	60	50	50
5	0	10	8	40	55	50
6	14	13	20	26	45	43
7	22	20	23	10	60	60
8	12	10	10	0	38	40
9	2	5	8	0	35	40
10	5	8	15	25	50	45
11	4	22	20	68	70	65
12	10	28	21	50	52	47
13	20	12	15	10	35	43
14	50	28	28	10	52	50
15	7	20	20	16	55	58
16	3	15	21	0	44	42
17	2	18	25	4	45	45
18	3	15	15	0	45	45
19	17	6	11	4	42	40
Mean	12.3	15.9	17.1	19.8	48.5	47.9
SD	12	7	6	21	8	7
Min	0	5	8	0	35	40
Max	50	28	28	68	70	65

removal a mature bony fusion was observed. The infection healed after implant removal without any loss of correction. There were no other implant related complications.

Discussion

To our knowledge, all reports on the scoliosis correction in patients with DMD deal with instrumentation of the spine using hooks, wires or hybrid instrumentation with pedicle screws in the lumbar spine [6, 12, 15, 20, 22, 28, 38, 43]. This is the first report about the use of pedicle-screw-alone fixation for this pathology. With 77% correction our data show good results for the coronal deformity leaving only a residual deformity of less than 10° (Table 1). No loss of correction was observed. Scoliosis in patients with DMD is a kyphotic deformity, in comparison to other forms of neuromuscular scoliosis with spasticity where lumbar lordosis is usual [45]. The kyphosis of 12° remained statistically unchanged and we did not see any junctional kyphosis cranial to T4. With a mean of 48° a good reconstruction of lumbar lordosis was achieved in our patients.

The lumbar lordosis is important for a good and balanced sitting in the patients with DMD in whom flexion contractures of the hips and knees are usually present. Mubarak et al. reported that fusion distally to L5 can be done in selected patients with a scoliosis of <40° and pelvic obliquity <10° [33] whereas, Alman and Kim recommended routine fusion to the pelvis [3] with the main aim of facilitating sitting. In 1997 Marchesi and co-workers described a modified Luque technique in which they added S1 pelvic screws and a connection bar between the L-rods to improve initial correction and stability of the sacropelvic anchorage [27]. With this technique they achieved a 75% pelvic correction without loss of correction after 36 months. Later, the results of Gaine in 2004 confirmed that fusion to the pelvis allows for better initial correction [15]. Just recently Carroll et al. reported their experience with the ‘MW’ sacropelvic construct, first introduced by Arlet in 1999 [4]. They found a superior correction of the screw based sacropelvic fixation compared with the traditional Galvestone technique (60% vs. 33%) [10]. We prefer taking the L5 pedicle for screw fixation for the caudal foundation, as the L5 pedicles are smaller than the S1 pedicles and thus

Table 3 Pulmonary parameters FVC = forced vital capacity (liter), %FVC = percentage of predicted FVC

Pat	FVC (l)			%FVC		
	preop	postop	f-up	preop	postop	f-up
1	1.6	–	1.0	44	–	22
2	2.2	2.3	2.1	79	97	70
3	1.1	0.4	0.4	29	12	12
4	3.5	–	2.1	89	–	45
5	2.3	–	1.8	68	–	65
6	2.0	–	1.3	56	–	27
7	1.0	–	0.3	22	–	n.f.
8	1.1	1.1	0.6	44	31	18
9	3.4	3.5	4.9	94	90	122
10	1.5	1.5	1.5	56	47	37
11	1.6	1.1	1.0	53	29	24
12	1.2	n.f.	n.f.	30	n.f.	n.f.
13	2.4	2.1	n.f.	43	65	n.f.
14	1.3	1.5	0.8	40	43	23
15	2.4	2.4	2.7	76	76	84
16	1.6	1.7	2.0	62	65	74
17	1.2	–	1.5	37	–	43
18	1.3	1.3	1.0	53	35	29
19	1.7	–	1.8	69	–	61
Mean	1.81	1.72	1.58	54.95	53.64	47.25
SD	0.73	0.83	1.07	20.33	27.05	29.90
Min	1	0.4	0.34	22	12	12
Max	3.5	3.5	4.88	94	97	122

offer better screw fixation. Additionally, the sacrum in most of these children is small and osteoporotic. The combination of iliac screws and L5 pedicle screws provides a stable caudal foundation of the construct. In our patients, the fusion was done routinely to the pelvis regardless of the severity of deformity resulting in 65% correction of the pelvic tilt. A good pelvic balance was achieved without any disadvantages or problems arising from the fixation to the pelvis. None of the patients complained of pain in the region of iliac fixation. A loss of correction was described by some authors with Luque or CD instrumentation [7, 41], but not by others [15, 22]. There was no loss of correction of scoliosis or pelvic tilt in our patients. A windshield wiper type loosening of the pelvic fixation was not observed. Implanted related complications were reported to be as high as 26% [22]. We had no complications related to pedicle screw fixation or secondary implant dislocation. Late implant infections with *Propionibacterium acnes* has been recently recognised as a risk after scoliosis correction using stainless steel implants [21]. One of our patients had a late infection with *Propionibacterium acnes*. As the infection healed after implant removal without any loss of deformity correction this did not change the operation result. He was pain-free at the last follow up.

The scoliosis correction in DMD is challenging because of the primary muscular pathology and the frequently associated cardiac and pulmonary affections. Complications are frequent, mortality rates reported between 2 and 9% [16, 22]. The presence of cardiomyopathy increases the perioperative mortality. Even a normal preoperative echocardiography does not exclude the development of a cardiac incident in patients with DMD during anaesthesia for a major surgery [37]. Our experience shows that cardiomyopathy is the determining risk of mortality in these patients in agreement with the available literature [20, 28, 37]. Our patient with intraoperative cardiac arrest had a slight to moderate reduction of ventricular ejaculatory function. All the other patients with normal preoperative echocardiography did not have any perioperative cardiac complications. Increased intraoperative blood loss is reported for patients with DMD [14, 23, 34, 39]. Despite the fusion to the pelvis, our total blood loss of 3.7 l is well within other published data ranging from 3.1 to 4.9 l [12, 22, 28, 38]. We observed less loss of blood in using pedicle screws compared to sublimbar wires, as the epidural space remained unopened, even though the total blood loss was in the comparable lower range of published data. This may be attributable to multifactorial origin of total blood loss, examples being the extent of muscle dissection, extent of decortication and fusion. Hypotensive anaesthesia was not used in our patients. We were more concerned with hypoperfusion and reduced venous return that might result from hypotension. The measures to ensure good filling of

right ventricle during the operation included soft thorax pillows and free hanging abdomen. In our opinion, avoiding hypotension is a part of these measures.

With the presented study, we are unable to contribute to the controversy whether spinal stabilisation affects the rate of deterioration of the pulmonary function in patients with DMD. Some authors reported stable respiratory function for up to 3 years after operation [17] and a recent paper reported a minor decline after surgery [44]. However, most studies could not document a positive effect of scoliosis correction to the pulmonary function [24, 28, 29, 31, 35, 40]. Two studies explicitly comparing operated and non-operated patients concluded that there was no proof for a salutary effect on respiratory function after scoliosis instrumentation [24, 31]. In our series of 19 patients, there was a statistically significant decrease in %FVC over the time. In the literature, pulmonary complications after surgery of DMD patients were common [22, 28]. Pneumonia, respiratory arrest due to opiate overdosing, pneumothorax [22] as well as difficulties in weaning from the respirator were described [1, 8, 13]. Some of the patients needed respiratory support by specialized ICUs and required temporary tracheotomy. Higher pulmonary complications were reported when the %FVC was less than 35% [29]. In our study, three patients had a %FVC preoperatively of <35%. The patient with the worst respiratory function with a %FVC of 22% needed prolonged weaning from the respirator but was otherwise without pulmonary complications. We did not observe pulmonary problems in any other patients. We believe that the very early mobilisation with sitting in wheel chair on the first postoperative day helps to avoid pulmonary complications. In our experience, a %FVC of <35% alone is not a predisposition to pulmonary complications.

Conclusions

Spinal instrumentation with pedicle screws for scoliosis correction in patients with DMD results in a good correction of the spinal and pelvic deformity. Due to the improvement of lumbar lordosis and pelvic tilt, a good sitting balance is restored. The rigid primary stabilisation resulting from pedicle screw fixation allows immediate and unrestricted mobilisation which is very important in the patients with DMD to avoid postoperative pulmonary complications. %FVC alone is not a predictor for pulmonary complications. Routine stabilisation to pelvis does not increase morbidity. The combination of iliac screws and L5 pedicle screws provides a stable caudal foundation of the construct. The patients with preoperative cardiomyopathy, even if it is slight, carry a higher risk of perioperative cardiac complications and mortality.

References

1. Aldrich TK, Uhrlass RM (1987) Weaning from mechanical ventilation: successful use of modified inspiratory resistive training in muscular dystrophy. *Crit Care Med* 15(3):247–249
2. Allen BL Jr, Ferguson RL (1982) The Galveston technique for L rod instrumentation of the scoliotic spine. *Spine* 7(3):276–284
3. Alman BA, Kim HK (1999) Pelvic obliquity after fusion of the spine in Duchenne muscular dystrophy. *J Bone Joint Surg Br* 81(5):821–824
4. Arlet V, Marchesi D, Papin P, Aebi M (1999) The ‘MW’ sacropelvic construct: an enhanced fixation of the lumbosacral junction in neuromuscular pelvic obliquity. *Eur Spine J* 8(3):229–231
5. Barr SJ, Schuette AM, Emans JB (1997) Lumbar pedicle screws versus hooks. Results in double major curves in adolescent idiopathic scoliosis. *Spine* 22(12):1369–1379
6. Basobas L, Mardjetko S, Hammerberg K, Lubicky J (2003) Selective anterior fusion and instrumentation for the treatment of neuromuscular scoliosis. *Spine* 28(20):S245–S248
7. Bentley G, Haddad F, Bull TM, Seingry D (2001) The treatment of scoliosis in muscular dystrophy using modified Luque and Harrington-Luque instrumentation. *J Bone Joint Surg Br* 83(1):22–28
8. Breucking E, Reimnitz P, Schara U, Mortier W (2000) Anesthetic complications. The incidence of severe anesthetic complications in patients and families with progressive muscular dystrophy of the Duchenne and Becker types. *Anaesthesist* 49(3):187–195
9. Cambridge W, Drennan JC (1987) Scoliosis associated with Duchenne muscular dystrophy. *J Pediatr Orthop* 7(4):436–440
10. Carroll EA, Shilt JS, Jacks L (2007) MW construct in fusion for neuromuscular scoliosis. *Eur Spine J* 16(3):373–377
11. Do T (2002) Orthopedic management of the muscular dystrophies. *Curr Opin Pediatr* 14(1):50–53
12. Forst R, Forst J, Heller KD, Hengstler K (1997) Characteristics in the treatment of scoliosis in muscular diseases. *Z Orthop Ihre Grenzgeb* 135(2):95–105
13. Fowler WM Jr, Abresch RT, Aitkens S, Carter GT, Johnson ER, Kilmer DD, McCrory MA, Wright NC (1995) Profiles of neuromuscular diseases. Design of the protocol. *Am J Phys Med Rehabil* 74(5 Suppl):S62–S69
14. Frischhut B, Krismer M, Stoeckl B, Landauer F, Auckenthaler T (2000) Pelvic tilt in neuromuscular disorders. *J Pediatr Orthop B* 9(4):221–228
15. Gaine WJ, Lim J, Stephenson W, Galasko CS (2004) Progression of scoliosis after spinal fusion in Duchenne’s muscular dystrophy. *J Bone Joint Surg Br* 86(4):550–555
16. Galasko CS, Delaney C, Morris P (1992) Spinal stabilisation in Duchenne muscular dystrophy. *J Bone Joint Surg Br* 74(2):210–214
17. Galasko CS, Williamson JB, Delaney CM (1995) Lung function in Duchenne muscular dystrophy. *Eur Spine J* 4(5):263–267
18. Gayet LE (1999) Surgical treatment of scoliosis due to Duchenne muscular dystrophy. *Chirurgie* 124(4):423–431
19. Gibson DA, Koreska J, Robertson D, Kahn A III, Albisser AM (1978) The management of spinal deformity in Duchenne’s muscular dystrophy. *Orthop Clin North Am* 9(2):437–450
20. Granata C, Merlini L, Cervellati S, Ballestrazzi A, Giannini S, Corbascio M, Lari S (1996) Long-term results of spine surgery in Duchenne muscular dystrophy. *Neuromuscul Disord* 6(1):61–68
21. Hahn F, Zbinden R, Min K (2005) Late implant infections caused by *Propionibacterium acnes* in scoliosis surgery. *Eur Spine J* 14(8):783–788
22. Heller KD, Wirtz DC, Siebert CH, Forst R (2001) Spinal stabilization in Duchenne muscular dystrophy: principles of treatment and record of 31 operative treated cases. *J Pediatr Orthop B* 10(1):18–24
23. Kannan S, Meert KL, Mooney JF, Hillman-Wiseman C, Warrier I (2002) Bleeding and coagulation changes during spinal fusion surgery: a comparison of neuromuscular and idiopathic scoliosis patients. *Pediatr Crit Care Med* 3(4):364–369
24. Kennedy JD, Staples AJ, Brook PD, Parsons DW, Sutherland AD, Martin AJ, Stern LM, Foster BK (1995) Effect of spinal surgery on lung function in Duchenne muscular dystrophy. *Thorax* 50(11):1173–1178
25. Kurz LT, Mubarak SJ, Schultz P, Park SM, Leach J (1983) Correlation of scoliosis and pulmonary function in Duchenne muscular dystrophy. *J Pediatr Orthop* 3(3):347–353
26. Liljenqvist U, Lepsien U, Hackenberg L, Niemeyer T, Halm H (2002) Comparative analysis of pedicle screw and hook instrumentation in posterior correction and fusion of idiopathic thoracic scoliosis. *Eur Spine J* 11(4):336–343
27. Marchesi D, Arlet V, Stricker U, Aebi M (1997) Modification of the original Luque technique in the treatment of Duchenne’s neuromuscular scoliosis. *J Pediatr Orthop* 17(6):743–749
28. Marsh A, Edge G, Lehovsky J (2003) Spinal fusion in patients with Duchenne’s muscular dystrophy and a low forced vital capacity. *Eur Spine J* 12(5):507–512
29. Miller F, Moseley CF, Koreska J (1992) Spinal fusion in Duchenne muscular dystrophy. *Dev Med Child Neurol* 34(9):775–786
30. Miller F, Moseley CF, Koreska J, Levison H (1988) Pulmonary function and scoliosis in Duchenne dystrophy. *J Pediatr Orthop* 8(2):133–137
31. Miller RG, Chalmers AC, Dao H, Filler-Katz A, Holman D, Bost F (1991) The effect of spine fusion on respiratory function in Duchenne muscular dystrophy. *Neurology* 41(1):38–40
32. Min K, Waelchli B, Hahn F (2005) Primary thoracoplasty and pedicle screw instrumentation in thoracic idiopathic scoliosis. *Eur Spine J* 14(8):777–782
33. Mubarak SJ, Morin WD, Leach J (1993) Spinal fusion in Duchenne muscular dystrophy—fixation and fusion to the sacropelvis? *J Pediatr Orthop* 13(6):752–757
34. Noordeen MH, Haddad FS, Muntoni F, Gobbi P, Hollyer JS, Bentley G (1999) Blood loss in Duchenne muscular dystrophy: vascular smooth muscle dysfunction? *J Pediatr Orthop B* 8(3):212–215
35. Ramirez N, Richards BS, Warren PD, Williams GR (1997) Complications after posterior spinal fusion in Duchenne’s muscular dystrophy. *J Pediatr Orthop* 17(1):109–114
36. Rideau Y, Glorion B, Delaubier A, Tarle O, Bach J (1984) The treatment of scoliosis in Duchenne muscular dystrophy. *Muscle Nerve* 7(4):281–286
37. Schmidt GN, Burmeister MA, Lilje C, Wappler F, Bischoff P (2003) Acute heart failure during spinal surgery in a boy with Duchenne muscular dystrophy. *Br J Anaesth* 90(6):800–804
38. Sengupta DK, Mehdiyan SH, McConnell JR, Eisenstein SM, Webb JK (2002) Pelvic or lumbar fixation for the surgical management of scoliosis in Duchenne muscular dystrophy. *Spine* 27(18):2072–2079
39. Shapiro F, Sethna N (2004) Blood loss in pediatric spine surgery. *Eur Spine J* 13(Suppl 1):S6–S17
40. Shapiro F, Sethna N, Colan S, Wohl ME, Specht L (1992) Spinal fusion in Duchenne muscular dystrophy: a multidisciplinary approach. *Muscle Nerve* 15(5):604–614
41. Sink EL, Newton PO, Mubarak SJ, Wenger DR (2003) Maintenance of sagittal plane alignment after surgical correction of spinal deformity in patients with cerebral palsy. *Spine* 28(13):1396–1403
42. Sussman MD (1984) Advantage of early spinal stabilization and fusion in patients with Duchenne muscular dystrophy. *J Pediatr Orthop* 4(5):532–537

43. Thacker M, Hui JH, Wong HK, Chatterjee A, Lee EH (2002) Spinal fusion and instrumentation for paediatric neuromuscular scoliosis: retrospective review. *J Orthop Surg (Hong Kong)* 10(2):144–151
44. Velasco MV, Colin AA, Zurakowski D, Darras BT, Shapiro F (2007) Posterior spinal fusion for scoliosis in duchenne muscular dystrophy diminishes the rate of respiratory decline. *Spine* 32(4):459–465
45. Wilkins KE, Gibson DA (1976) The patterns of spinal deformity in Duchenne muscular dystrophy. *J Bone Joint Surg Am* 58(1):24–32