

Ruptured pseudo-aneurysm of a femoral artery in a drug abuser revealed by post-mortem CT angiography

Katarzyna Michaud · Silke Grabherr ·
Maria del Mar Lesta · Marc Augsburger ·
Francesco Doenz · Patrice Mangin

Received: 27 September 2012 / Accepted: 26 November 2012 / Published online: 12 December 2012
© Springer-Verlag Berlin Heidelberg 2012

Abstract A 35-year-old drug addict was found dead in a public toilet with a ruptured groin, which was later diagnosed to be a leaking pseudo-aneurysm. Investigation at the scene revealed impressive external hemorrhage related to a groin wound. Post-mortem computed tomography angiography demonstrated an aneurysm of the right femoral artery with leak of contrast liquid. Signs of blood loss were evident at autopsy, and histological examination revealed necrosis and rupture of the pseudo-aneurysm. Toxicological analyses were positive for methadone, cocaine, citalopram, and benzodiazepines. This is the first case report in the literature of a ruptured femoral pseudo-aneurysm with a post-mortem radiological diagnosis.

Keywords Parenteral drug abuse · Femoral pseudo-aneurysm · Haemorrhage · Post-mortem angiography

Introduction

Parenteral drug injection can cause a wide range of vascular complications, from simple vascular irritation to severe infections, thrombosis, and the formation of pseudo-aneurysms

K. Michaud (✉) · S. Grabherr · M. d. M. Lesta · M. Augsburger ·
P. Mangin
University Center of Legal Medicine, Lausanne and Geneva,
Rue du Bugnon 21,
1011 Lausanne, Switzerland
e-mail: katarzyna.michaud@chuv.ch

F. Doenz
Department of Diagnostic and Interventional Radiology,
University Hospital of Lausanne,
Rue du Bugnon 46,
1011 Lausanne, Switzerland

[1–3]. These latter complications can be limb- or even life-threatening, with difficult and controversial clinical management [4]. The femoral localization of a pseudo-aneurysm has been reported in clinical practice [5–8], but a post-mortem diagnosis completed with post-mortem computed tomography angiography (PMCTA) has not been presented up to now.

In the University Center of Legal Medicine Lausanne–Geneva, the performance of pre-autopsy PMCTA has become part of the routine investigation for cases in which lesions of the vascular system are suspected. Such cases are investigated using a standardized technique called multi-phase post-mortem CT angiography (MPMCTA) [9].

We present a case of fatal hemorrhage in a drug addict, for whom the source of bleeding was identified and visualized by MPMCTA. To our knowledge, this is the first case report in the literature of a ruptured femoral pseudo-aneurysm with a post-mortem radiological diagnosis.

Case report

Clinical history

A 35-year-old woman was found dead in a public toilet. She was known to have had a borderline personality and to have abused drugs with intravenous injections of cocaine and midazolam. She was HIV-, HBV-, and HCV-positive. Six years before her death, a Thiersch graft [10] was placed in the left inguinal area to treat an abscess. Two years later, she presented with a thrombosis of the right deep femoral vein and post-thrombotic syndrome of the right leg. One month prior to her death, she was admitted to the hospital for Streptococcal bacteremia resulting from drug injections into the right inguinal region. During her stay, a chronic groin wound without

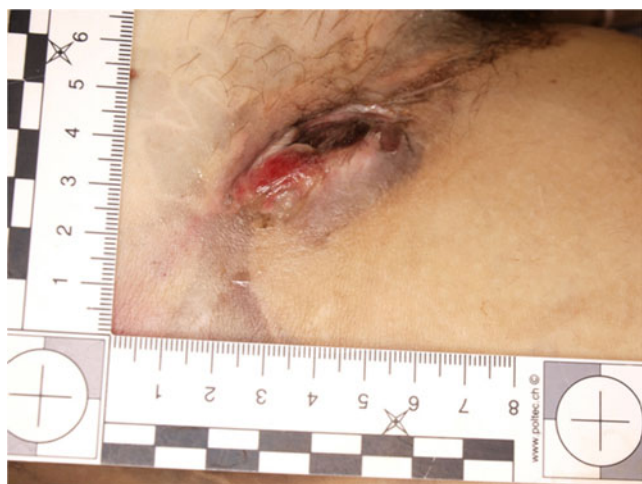

Fig. 1 Large groin wound found on external examination

purulent flow was observed, and a pseudo-aneurysm of the right femoral artery was discovered by Doppler ultrasound. Multiple microemboli of the right leg and foot attributed to probable intra-arterial injections of drugs were observed. The patient was treated with antibiotics over a 3-week period.

Scene investigation

The body was found undressed in a public toilet. Scene investigation revealed large quantities of blood on the floor and walls, suggesting an arterial bleeding. A needle and small knife were found near the body.

External examination

External examination by a board-certified forensic pathologist showed signs of blood loss and a large groin wound on the right side (Fig. 1). Multiple needle tracks were observed. A track on the left forearm had a recent appearance. There was a large scar in the left inguinal area. Multiple old linear transverse scars were present in the left forearm, compatible with automutilation.

Radiological investigation

Post-mortem computed tomography (PMCT) and MPMCTA were performed by a trained forensic radiographer [11] on an

eight-row CT unit (CT LightSpeed 8, GE Healthcare, Milwaukee, WI, USA). The scan parameters used are noted in Table 1. Prior to the performance of MPMCTA, peripheral blood, cerebrospinal and vitreous fluids, and hair samples were collected according to our standard autopsy protocol. The urinary bladder was empty. Samples of bile were obtained under CT guidance as described by Schneider et al. [11]. MPMCTA was performed using a Virtangio® perfusion device with the oily contrast agent Angiofil® (Fumedica AG, Switzerland) mixed with paraffin oil (paraffinum liquidum, obtained in the local pharmacy). The left inguinal region was cannulated.

Radiological interpretation

Interpretation of all images was performed by two board-certified radiologists (one specialized in vascular radiology, the other in neuroradiology) and by one board-certified forensic pathologist trained in forensic imaging. A post-mortem radiological report describing all findings observed in the PMCT and in each phase of MPMCTA was made. Radiological examination revealed subcutaneous infiltration in both inguinal regions (Fig. 2a) and liquid in the small pelvis. During the arterial phase of angiography, an arterio-cutaneous fistula of the right inguinal region with extravasation of contrast agent into the muscular tissue was observed, originating from a pseudo-aneurysmal formation of the right femoral artery measuring approximately 2.5 cm in diameter (Fig. 2b–c).

Conventional autopsy and histological examination

A conventional autopsy was performed 18 h after MPMCTA. Three body cavities were opened, and the organs were dissected according to internal and international recommendations [12]. A visceral pallor was noticed, which was attributed to external hemorrhage from the groin wound.

Dissection of the right femoral area showed an aneurysmal dilatation of the right femoral artery measuring $3 \times 2.3 \times 0.8$ cm, with a gap passing between the fibrotic tissue (Fig. 3a, b). Histological examination revealed a chronic fibro-inflammatory state (Fig. 3c) and iron deposits (Fig. 3d). The arterial wall was thickened, with ruptures of the elastic internal lamina and necrosis.

Table 1 Technical parameters for CT data acquisition

	FOV (cm)	Slice thickness (mm)	Interval (mm)	kV	mA (modulated)	Tube rotation (s)	Pitch
Native	50	1.25	1	120	280	0.8	0.875
Arterial	50	1.25	0.6	120	280	0.8	0.875
Venous	50	2.5	2	120	280	0.8	0.875
Dynamic	50	2.5	2	120	280	0.8	0.875

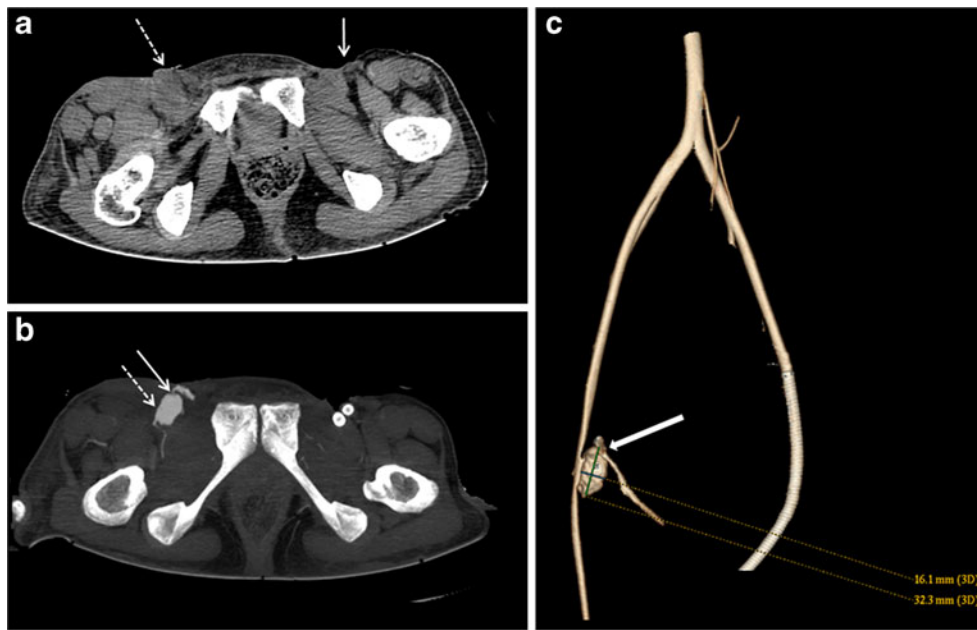


Fig. 2 Radiological images. **a** Native CT revealed the presence of subcutaneous infiltrations in both inguinal regions (*arrows*), essentially on the left side (*dotted arrow*). **b** Maximum intensity projection reconstructed after an arterial phase of MPMCTA showing a pseudo-aneurysm filled with contrast agent (*dotted arrow*) in the right inguinal region.

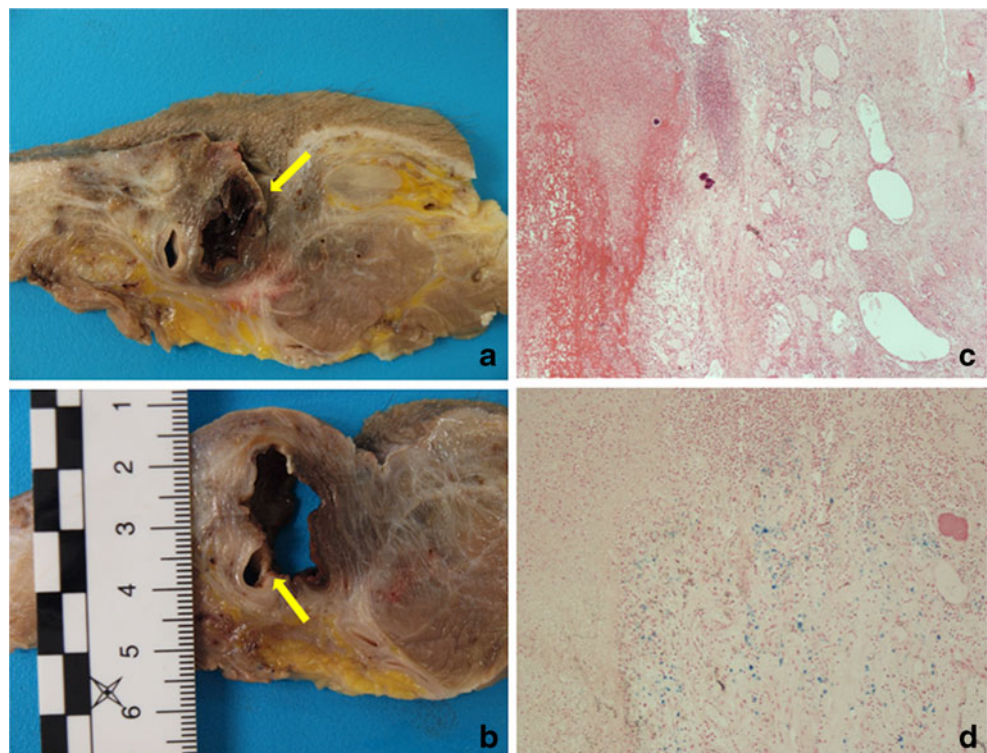
Contrast agent extravasated via an arterio-cutaneous fistula outside the body and in the surrounding tissue (*arrow*). **c** Volume-rendered 3-D reconstruction of the distal aorta, iliac, and femoral arteries of both sides. The aneurysm is visualized and measured. The exact source of bleeding (fistula) can be easily recognized (*arrow*)

Toxicological analyses

Comprehensive drug screenings were performed on the blood by gas chromatography–mass spectrometry (GC–

MS) [13], high-performance liquid chromatography coupled with diode array detection (HPLC), and headspace–gas chromatography–flame ionization for the detection of volatile substances. The confirmation and

Fig. 3 **a** Pseudo-aneurysm formation of the femoral artery and the wound of the right groin with the external rupture (*arrow*). **b** Pseudo-aneurysm and its origin from the artery (*arrow*). Note the fibrous tissue around the arterial wall. **c** Histological examination of the groin wound showing a chronic fibro-inflammatory state with the areas of fresh hemorrhage and an intense neutrophil granulocytic infiltration (H & E, $\times 40$). **d** Detection of iron deposits by Prussian blue reaction compatible with an old hemorrhage of the tissue surrounding the arterial wall ($\times 100$)



quantification of drugs was done by GC–MS, GC–MS/MS, and HPLC–MS/MS.

The toxicological analyses performed on the peripheral blood revealed the presence of cocaine (160 µg/l), benzoylecgonine (700 µg/l), ecgonine methylester (200 µg/l), lorazepam (13 µg/l), nordiazepam (35 µg/l), oxazepam (5 µg/l), methadone (290 µg/l), EDDP (70 µg/l), desmethylcitalopram, acetaminophen, and caffeine. Alcohol was not detected. According to the literature, these concentrations range below the lethal level [14,15].

Toxicological analyses were also performed on hair samples and showed the presence of cocaine (100 ng/mg), benzoylecgonine (32 ng/mg), 6-monoacetyl-morphine (0.4 ng/mg), morphine (0.3 ng/mg), codeine (0.1 ng/mg), and methadone (34 ng/mg), suggesting frequent consumption of cocaine and methadone during the months before the death, and occasional consumption of heroin during the same period.

Discussion

Pseudo-aneurysm formation at the site of injection is a well-known complication of parenteral drug use and had been previously reported in the literature [3,5,6]. This lesion may occur after arterial trauma resulting from accidental or intentional intra-arterial drug injection. This most commonly occurs when peripheral veins are inaccessible [1,8,16]. Repeated punctures of the femoral artery can lead to abscess formation and epithelisation of the arterial wall, resulting in the formation of a pseudo-aneurysm. Hemorrhage, sepsis, limb loss, and death are possible sequelae [2,4].

This is a rare case of a woman with a leaking pseudo-aneurysm presented as ruptured groin wound and external hemorrhage. Although well documented in clinical practice, pseudo-aneurysms of the femoral artery have been rarely reported in post-mortem studies [17]. This may be due to the fact that the majority of deaths in drug addicts are the result of intoxication, and hence, the vascular system of the members is not routinely examined post-mortem. In this case, the scene investigation and external examination suggested an arterial bleeding. Post-mortem CT angiography enabled the visualization and documentation of the lesion, and the autopsy examination provided more details. In our opinion, post-mortem radiological examination of the vascular system is recommended in cases of suspected arterial bleeding, but it would be also interesting in cases with non-ruptured pseudo-aneurysms. Insights gained will be helpful for the understanding on the radiological evaluation of arterial pseudo-aneurysms in the clinical setting. The MPMCTA technique has great advantages over both conventional autopsy and ante-mortem clinical CT angiography for the detection of the source of bleeding in cases of acute

hemorrhage [18]. The detection and visualization of the origin of bleeding is sometimes crucial [19]. The combination of MPMCTA and conventional autopsy may represent a new standard of excellence.

In this case, MPMCTA enabled the visualization of both the source of the hemorrhage (arterio-cutaneous fistula) and the underlying pathological substrate (pseudo-aneurysm). To our knowledge, this is the first case report in which a pseudo-aneurysm was diagnosed by PMCTA.

Acknowledgments The research project of post-mortem angiography was financially supported by the Promotion Agency for Innovation of the Swiss Confederation (KTI Nr. 10221.1 PFIW-IW) and by the Leenards Foundation, Switzerland.

References

1. Woodburn KR, Murie JA (1996) Vascular complications of injecting drug misuse. *Br J Surg* 83(10):1329–1334. doi:10.1002/bjs.1800831005
2. Fiddes R, Khattab M, Abu Dakka M, Al-Khaffaf H (2010) Patterns and management of vascular injuries in intravenous drug users: a literature review. *Surgeon* 8(6):353–361. doi:10.1016/j.surge.2010.07.006
3. McIlroy MA, Reddy D, Markowitz N, Saravolatz LD (1989) Infected false aneurysms of the femoral artery in intravenous drug addicts. *Rev Infect Dis* 11(4):578–585. doi:10.1093/clinids/11.4.578
4. Salimi J, Shojaeefar A, Khashayar P (2008) Management of infected femoral pseudoaneurysms in intravenous drug abusers: a review of 57 cases. *Arch Med Res* 39(1):120–124. doi:10.1016/j.armed.2007.07.004
5. Tsao JW, Marder SR, Goldstone J, Bloom AI (2002) Presentation, diagnosis, and management of arterial mycotic pseudoaneurysms in injection drug users. *Ann Vasc Surg* 16(5):652–662. doi:10.1007/s10016-001-0124-6
6. Ting ACW, Cheng SWK (1997) Femoral pseudoaneurysms in drug addicts. *World J Surg* 21(8):783–787. doi:10.1007/s002689900306
7. Valentine RJ, Chung J (2012) Primary vascular infection. *Curr Probl Surg* 49(3):128–182. doi:10.1067/j.cpsurg.2011.11.004
8. Koželj M, Kobilica N, Flis V (2006) Infected femoral pseudoaneurysms from intravenous drug abuse in young adults. *Wien Klin Wochenschr* 118:71–75. doi:10.1007/s00508-006-0546-9
9. Grabherr S, Doenz F, Steger B, Dirnhofner R, Dominguez A, Sollberger B, Gygax E, Rizzo E, Chevallier C, Meuli R, Mangin P (2010) Multi-phase post-mortem CT angiography: development of a standardized protocol. *Int J Legal Med*:1–12. doi:10.1007/s00414-010-0526-5
10. Boudana D, Wolber A, Coegniet E, Martinot-Duquennoy V, Pellerin P (2010) Une histoire de peau. *Ann Chir Plast Esthet* 55(4):328–332. doi:10.1016/j.anplas.2009.08.003
11. Schneider B, Chevallier C, Dominguez A, Bruguier C, Elandoy C, Mangin P, Grabherr S (2012) The forensic radiographer: a new member in the medicolegal team. *Am J Forensic Med Pathol* 33(1):30–36. doi:10.1097/PAF.1090b1013e31820c31826aa31823
12. Brinkmann B (1999) Harmonisation of medico-legal autopsy rules. *Int J Legal Med* 113(1):1–14

13. Michaud K, Augsburger M, Romain N, Giroud C, Mangin P (1999) Fatal overdose of tramadol and alprazolam. *Forensic Sci Int* 105(3):185–189. doi:10.1016/s0379-0738(99)00118-8
14. Druid H, Holmgren P (1997) A compilation of fatal and control concentrations of drugs in postmortem femoral blood. *J Forensic Sci* 42(1):79–87
15. Winek CL, Wahba WW, Balzer TW (2001) Drug and chemical blood-level data 2001. *Forensic Sci Int* 122(2–3):107–123. doi:10.1016/s0379-0738(01)00483-2
16. Coughlin PA, Mavor AID (2006) Arterial consequences of recreational drug use. *Eur J Vasc Endovasc Surg* 32(4):389–396. doi:10.1016/j.ejvs.2006.03.003
17. Lardi C, Fracasso T (9000) Spontaneous external rupture of femoral pseudoaneurysm: fatal hemorrhage related to drug abuse. *Am J Forensic Med Pathol*. doi:10.1097/PAF.1090b1013e3182518e3182547, Publish Ahead of Print
18. Palmiere C, Binaghi S, Doenz F, Bize P, Chevallier C, Mangin P, Grabherr S (2012) Detection of hemorrhage source: the diagnostic value of post-mortem CT-angiography. *Forensic Sci Int* 222(1–3):33–39
19. Zerlauth JB, Doenz F, Dominguez A, Palmiere C, Uské A, Meuli R, Grabherr S (2012) Surgical interventions with fatal outcome: utility of multi-phase postmortem CT angiography. *Forensic Sci Int*. doi:10.1016/j.forsciint.2012.05.013