

Surg Endosc (2008) 22:1278–1282
DOI 10.1007/s00464-007-9607-z

TECHNIQUE

Totally intracorporeal laparoscopic colorectal anastomosis using circular stapler

Pascal Bucher · Philippe Wutrich · Francois Pugin · Michel Gonzales ·
Pascal Gervaz · Philippe Morel

Received: 16 May 2007 / Accepted: 26 May 2007 / Published online: 18 October 2007
© Springer Science+Business Media, LLC 2007

Abstract

Background A number of surgical techniques for colorectal anastomosis have been described for laparoscopic left-sided colectomies. Due to the complexity of these procedures, open preparation of the proximal bowel for circular stapler anastomosis through a Pfannenstiel incision has become the gold standard. We report a new laparoscopic technique for totally intracorporeal colorectal circular anastomosis (TLCCA) using a circular stapler.

Methods Preliminary experience using TLCCA in three patients scheduled for laparoscopic left colectomies (two) and sigmoidectomy (one).

Results Side-to-end colorectal anastomosis through TLCCA was feasible in all patients scheduled for preliminary experience. Median time from anvil insertion into abdominal cavity to anastomosis was 14 (11–17) minutes. No postoperative complications were recorded.

Conclusion Side-to-end anastomosis can be easily and safely performed using conventional circular stapler through TLCCA. TLCCA is performed using four laparoscopic ports without additional skin incision (except trocars incision) and allows the retrieval of surgical pieces through a specimen bag.

Keywords Colectomy · Colorectal anastomosis · Coloanal anastomosis · Circular stapler · Laparoscopy · Side-to-end anastomosis · Pfannenstiel · Specimen bag

Laparoscopic resections of left-sided colon or rectum have gained increasing importance according to patients recovery and cost advantages [1–3]. Some of the advantages of laparoscopic colorectal surgery over open surgery such as surgical trauma, cosmesis, lower pain, and faster recovery are related to abdominal wall incision [3–5]. While a number of surgical techniques for colorectal or coloanal anastomosis have been described in laparoscopic colectomies, open preparation of the proximal bowel for circular stapler anastomosis, through a Pfannenstiel or left-lower-quadrant incision, has become the gold standard [6, 7]. This technique, which requires an additional skin incision, is favored over others methods described, including transanal bowel exposition for anastomosis preparation, which requires more-extensive colon mobilization, less favorable side-to-side linear colorectal anastomosis, difficult and time-consuming suture, others methods needing large trocars ports, and intracorporeal large opening of colon and rectum [8–15].

We report a new technique for totally laparoscopic colorectal circular anastomosis (TLCCA) using a conventional circular stapler. Colorectal as well as coloanal anastomoses are performed through the same technique. Anastomoses are performed side to end, without additional skin incision (except trocars incision) and allow retrieval of surgical pieces through a specimen bag.

Methods

Preliminary experience with totally intracorporeal circular colorectal anastomosis in patients scheduled for laparoscopic left colectomy (two cases) or sigmoidectomy (one case) is presented. None of the patient had preoperative mechanical bowel preparation. Three patients (median age 63 years) were operated using this anastomosis technique.

P. Bucher (✉) · P. Wutrich · F. Pugin · M. Gonzales ·
P. Gervaz · P. Morel
Visceral Surgery, Department of Surgery, Geneva University
Hospital, 24, Rue Micheli-du-Crest, 1211 Geneva 14,
Switzerland
e-mail: Pascal.Bucher@hcuge.ch

Surgical technique

The colectomy was performed using the standard surgical procedure. After having determined and mobilized the segment of colon to be resected, the distal section (rectum) was performed using endoscopic linear stapler. The proximal bowel segment was tested laparoscopically for length and mobility to ensure the placement of a secure anastomosis in terms of position and low tension. The future line of proximal bowel section was chosen and the colon mesentery dissected to reach the bowel wall (Fig. 1A). A transverse antimesenteric opening of the colon was then carried out on the segment to be resected. Additionally, a small longitudinal 2–3 mm opening on the anti-mesenteric teniae was effected a few centimeters proximal to the future bowel section (Fig. 1A). This opening will be the site of the future proximal side of the anastomosis. For this bowel opening we used the Harmonic ACE™ dissector (Ethicon endo-surgery GmbH, Germany, Norderstedt) [16]. The anvil of the circular stapler was then introduced into the abdominal cavity (not shown in the figure) through a 10-mm trocar incision, usually through the right iliac fossa, after having temporarily removed the trocar to allow anvil passage through the abdominal wall opening. The skin incision needed to be slightly extended to 2 cm to allow the passage of the anvil. The anvil was then recovered with a laparoscopic clamp and passed through the colon opening as shown in Fig. 1B. The connecting extremity of the anvil is exteriorized through the puncture opening on the teniae, for eventual completion of the side-to-end anastomosis, and secured using the laparoscopic anvil clamp (Fig. 1B). Prolene 2/0 purse-string stitches were performed around the anvil opening to secure anvil placement in the bowel wall (Fig. 1C). The specimen opening, which served to allow entry of the anvil into the bowel, can be closed with stitches (not shown in the figure). After the anvil was placed and secured, the colon was transected using an endoscopic linear stapler (Fig. 1D). The colon section was performed between the anvil and the opening used for its introduction, which enabled the removal of the area of bowel opening used for anastomosis preparation (Fig. 1D). After proximal section of the resected bowel segment the surgical piece was placed in a laparoscopy specimen retrieval bag (Fig. 1E). The specimen could easily be recovered at the end of the operation by pulling the mouth of the bag through the right iliac fossa trocar incision, opening the bag, and extracting the specimen through the bag to protect the wound (not shown in the figure). Once the specimen was placed in the bag, the anastomosis was completed after having inserted the stapler transanally (Fig. 1F). This results in a side-to-end colorectal anastomosis as shown in Fig. 1F. The same technique can be used for side-to-end coloanal anastomosis.

Results

TLCCA was feasible in all patients scheduled for preliminary experience (Fig. 2). Median time from insertion of the anvil into the abdominal cavity to completion of the anastomosis was 14 (11–17) minutes. Four laparoscopic ports were used in two cases and five in one (Fig. 3). No preoperative complications were recorded and no intra-peritoneal stool spoilage was encountered. No postoperative complications were recorded and median hospital stay was seven days.

Discussion

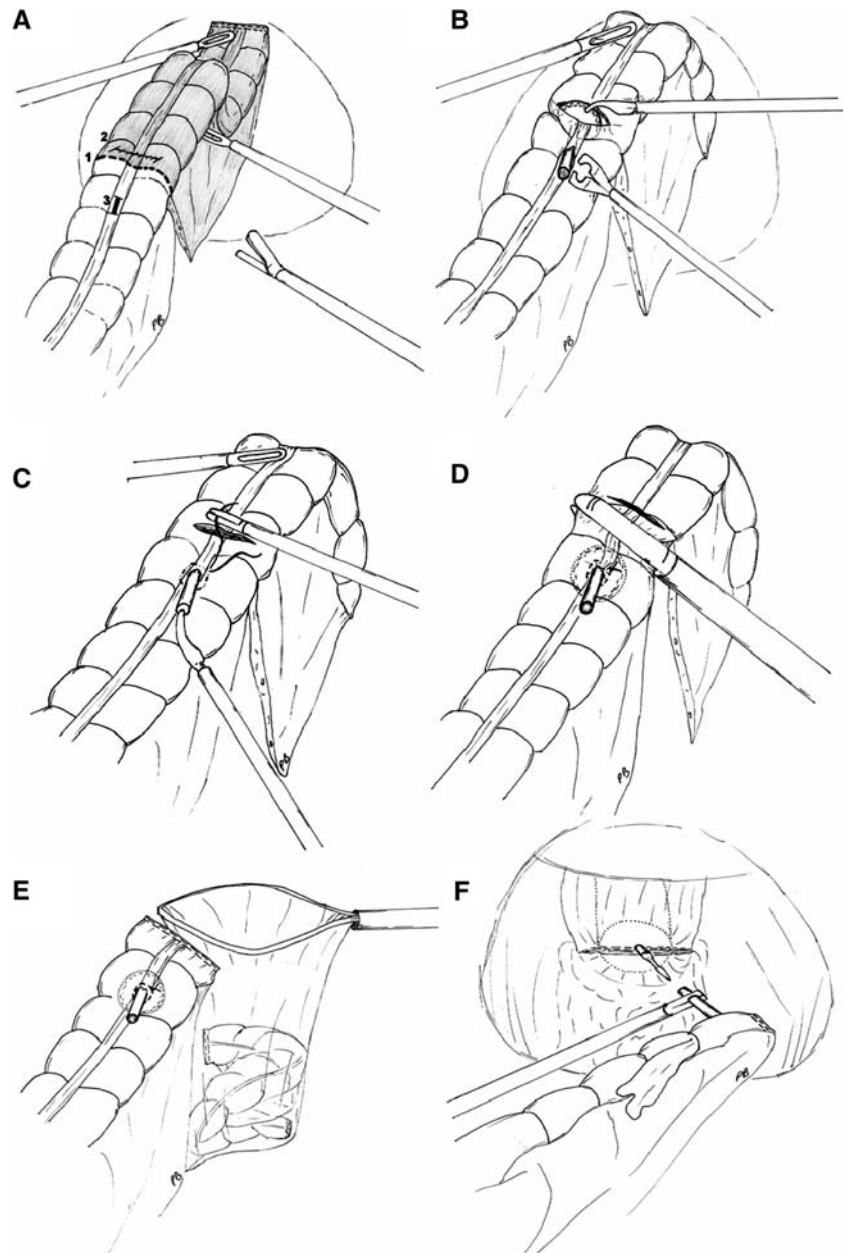
We describe a new surgical technique for totally laparoscopic circular colorectal anastomosis (TLCCA) using a circular stapler for side-to-end anastomosis. This easy surgical technique offers advantages in terms of cosmetic result, operative time, infectious and carcinological security for specimen retrieval, and even instrumentation cost compared to conventional practice through Pfannenstiel or left-lower-quadrant incision for colorectal anastomosis.

Side-to-end colorectal anastomosis is becoming increasingly common due to its functional advantages and safety [17–19]. The present technique of laparoscopic intracorporeal anastomosis necessitates intra-abdominal bowel opening. However, it has been shown that intracorporeal bowel opening for anastomosis completion does not increase infectious surgical risk in bariatric surgery [20] and colorectal surgery during right-sided resection [21, 22]. This technique is easily feasible in nonprepared bowel, which could reduce the risk of peritoneal contamination due to the presence of contaminated liquid stool [23, 24].

Totally laparoscopic circular colorectal anastomosis (TLCCA) according to the present technique is quick and easy to perform for a colorectal surgeon experienced in laparoscopy. Using this surgical technique avoids the need for a Pfannenstiel incision, which is known to be associated with a 0.5–2% incisional hernia incidence [25]. Moreover, nerve entrapment, encountered in 3.7% of Pfannenstiel incisions, could account for disabling postoperative pain [26]. While no additional skin incision except the trocar ports are needed for TLCCA, there is a nonnegligible gain of cosmesis as more sigmoidectomies for diverticular disease are performed in younger patients due to disease epidemiology [27]. The only modification in terms of skin incision is a slight enlargement of the right iliac fossa port opening such as a small McBurney incision, which has the advantage of having a low incisional hernia prevalence of 0.1% [28].

TLCCA does not require more-extensive bowel dissection as is required for complete anastomosis as the bowel

Fig. 1 **A** Colon exposition showing the segment to be resected (grayish distal segment) distal to the bowel section line (1). The transverse bowel opening (2) for anvil insertion is placed distal to the bowel section. The anvil opening on teniae is placed proximal to section line (3). **B** The anvil is inserted into the bowel lumen through the transverse opening. The connecting end of the anvil is exposed through the teniae incision and held with an endoscopic anvil clamp. **C** Pruse-string stitching is done around the teniae incision to secure anvil placement and proximal anastomotic doughnuts. The closing stitch can be placed on the transverse bowel opening to decrease the risk of contamination during manipulation at this time (not shown here). **D** Colon is then transected using an endoscopic surgical linear stapler distal to the anvil placement and proximal to the anvil introduction incision. **E** The colectomy specimen is placed in a specimen bag to be recovered from the abdominal cavity). Completion of the side-to-end colorectal anastomosis with the circular stapler passed transanally



does not have to be extracted extracorporeally. This is an advantage compared to techniques where the bowel is exposed transanally [9, 13] or even through Pfannenstiel or left-lower-quadrant incision, especially in obese patients [29].

When an additional Pfannenstiel or left-lower-quadrant skin incision is used for stapler anvil placement, the bowel specimen is recovered through these opening. Plastic wound protectors are used to prevent wound contamination and infection during bowel exposition. However it has been shown that wound protectors are not efficient for this purpose during laparoscopic colectomies [30]. Moreover, wound protectors only protect the abdominal wall from tumor cells seeding, but do not offer any protection

against cells seeding in the abdominal cavity when the colon is extracted through a small incision for proximal bowel preparation. The use of a laparoscopic retrieval bag for the extraction of the resected specimen has been shown to decrease the incidence of wound infection at the extraction incision and lower the risk of seeding of tumor cells into the abdominal cavity and wound metastasis during specimen manipulation [31–33]. For TLCCA a specimen retrieval bag is used for these reasons and allows easy handling of the resected bowel segment for extraction through the right iliac port incision.

Laparoscopic sigmoidectomy has been shown to be cost-effective compared to the open approach, but this is mainly related to faster recovery as operative cost would

Fig. 2 Intraoperative view during totally intracorporeal laparoscopic colorectal anastomosis preparation

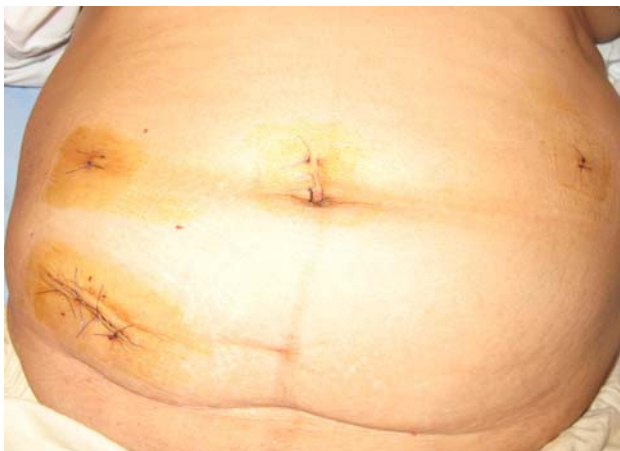
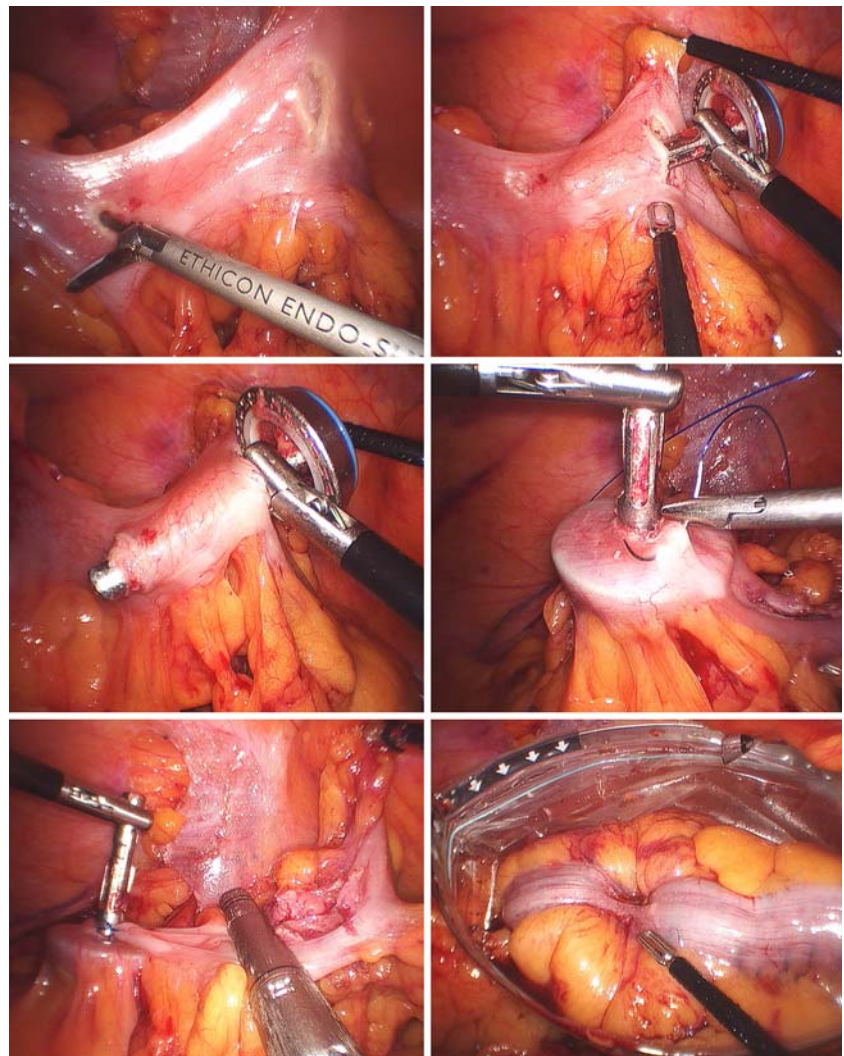


Fig. 3 Skin incision after left colectomy using totally intracorporeal laparoscopic colorectal anastomosis

favor open resection [4, 16]. The use of a stapler could, at least partly, account for the operative cost of laparoscopic

resection. In this regard TLCCA as described herein does not increase operative cost as only an endoscopic linear stapler and a circular stapler are used, without the need for a purse string or conventional linear stapler.

Conclusions

Totally laparoscopic circular colorectal anastomosis (TLCCA) using a circular stapler is easy, safe, and feasible using the described technique. Among the advantages of this technique, cosmetic result is important, although reduced operative time, security of specimen retrieval, and operative cost also have to be considered.

References

1. Braga M, Vignali A, Zuliani W, et al. (2005) Laparoscopic versus open colorectal surgery: cost-benefit analysis in a single-center randomized trial. *Ann Surg* 242(6):890–895

2. Reza M, Blasco J, Andradas E, et al. (2006) Systematic review of laparoscopic versus open surgery for colorectal cancer. *Br J Surg* 93(8):921–928
3. Veldkamp R, Kuhry E, Hop W, et al. (2005) Laparoscopic surgery versus open surgery for colon cancer: short-term outcomes of a randomised trial. *Lancet Oncol* 6(7):477–484
4. Senagore A, Duepre H, Delaney C, et al. (2002) Cost structure of laparoscopic and open sigmoid colectomy for diverticular disease: similarities and differences. *Dis Colon Rectum* 45(4):485–490
5. Braga M, Vignali A, Gianotti L, et al. (2002) Laparoscopic versus open colorectal surgery: a randomized trial on short-term outcome. *Ann Surg* 236(6):759–766
6. Morino M, Parini U, Giraudo G, et al. (2003) Laparoscopic total mesorectal excision. A consecutive series of 100 patients. *Ann Surg* 237(3):335–342
7. Lee S, Yoo J, Dujovny N, et al. (2006) Laparoscopic vs. hand-assisted laparoscopic sigmoidectomy for diverticulitis. *Dis Colon Rectum* 49(4):464–469
8. Francklin MJ (1995) Laparoscopic colon and small bowel surgery. In: Brook DC (ed) *Current review of laparoscopy*. Philadelphia, PA
9. Fukunaga Y, Higashino M, Tanimura S, et al. (2003) novel laparoscopic technique for stapled colon and rectal anastomosis. *Tech Coloproctol* 7(3):192–197
10. Bergamaschi R, Haugstvedt T, Marvik R (1998) Facilitating intracorporeal colorectal anastomoses. *JLS* 2(1):47–49
11. Msika S, Iannelli A, Marano A, et al. (2000) Hand-sewn intra-abdominal anastomosis performed via video laparoscopy during colorectal surgery. *Ann Chir* 125(5):439–443
12. Bergamaschi R, Arnaud J (1997) Intracorporeal colorectal anastomosis following left colon resection. *Surg Endosc* 11(8):800–801
13. Fu C, Muto T, Masaki T (1997) Results of the double stapling procedure in colorectal surgery. *Jpn J Surg*; 27:706–709
14. Hamad M, Mentges B, Buess G (2003) Laparoscopic sutured anastomosis of the bowel. *Surg Endosc* 17(11):1840–1844
15. Darzi A, Super P, Guillou P, Monson J (1994) Laparoscopic sigmoid colectomy: total laparoscopic approach. *Dis Colon Rectum* 37(3):268–271
16. Morino M, Rimonda R, Allaix M, et al. (2005) Ultrasonic versus standard electric dissection in laparoscopic colorectal surgery: A prospective randomized clinical trial. *Ann Surg* 242(6):897–901
17. Jiang J, Yag S, Lin J (2005) Transabdominal anastomosis after low anterior resection: a prospective, randomized, controlled trial comparing long-term results between side-to-end anastomosis and colonic J-pouch. *Dis Colon Rectum* 48(11):2100–2108
18. Rullier E, Laurent C, Garrelon J, et al. (1998) Risk factors for anastomotic leakage after resection of rectal cancer. *Br J Surg* 85(3):355–358
19. Makela J, Kivniemi H, Laitinen S (2003) Risk factors for anastomotic leakage after left-sided colorectal resection with rectal anastomosis. *Dis Colon Rectum* 46(5):653–660
20. Lang R, Hutter T, Winter H, et al. (2005) How safe are laparoscopic intracorporeal anastomoses? *Zentralbl Chir* 130(1):65–70
21. Raftopoulos I, Courcoulas A, Blumberg D (2006) Should completely intracorporeal anastomosis be considered in obese patients who undergo laparoscopic colectomy for benign or malignant disease of the colon. *Surgery* 140(4):675–682
22. Casciola L, Ceccarelli G, Di Zitti L, et al. (2003) Laparoscopic right hemicolectomy with intracorporeal anastomosis. Technical aspects and personal experience. *Minerva Chir* 58(4):621–627
23. Bucher P, Gervaz P, Soravia C, et al. (2005) Randomized clinical trial of mechanical bowel preparation versus no preparation before elective left-sided colorectal surgery. *Br J Surg* 92(4):409–414
24. Bucher P, Gervaz P, Egger J, et al. (2006) Morphological alteration associated with mechanical bowel preparation before elective colorectal surgery. *Dis Colon Rectum* 49(1):109–112
25. Kisielinski K, Conze J, Murken A, et al. (2004) The Pfannenstiel or so called “bikini cut”: still effective more than 100 years after first description. *Hernia* 8(3):177–181
26. Luijendijk R, Jeekel J, Storm R, et al. (1997) The low transverse Pfannenstiel incision and the prevalence of incisional hernia and nerve entrapment. *Ann Surg* 225(4):365–369
27. Zaidi E, Daly B (2006) CT and clinical features of acute diverticulitis in an urban U.S. population: rising frequency in young, obese adults. *AJR Am J Roentgenol* 187(3):389–394
28. Konstantakos A, Zollinger RJ (2000) Repair of McBurney incisional hernias after open appendectomy. *Curr Surg* 57(1):79–80
29. Bruce C, Collier J, Murray J, et al. (1996) Laparoscopic resection for diverticular disease. *Dis Colon Rectum* 39(10 Suppl):S1–S6
30. Kercher K, Nguyen T, Harold K, et al. (2004) Plastic wound protectors do not affect wound infection rates following laparoscopic assisted colectomy. *Surg Endosc* 18(1):148–151
31. Schafer M, Krahenbuhl L, Frei E, Buchler M (2000) Laparoscopic appendectomy in Switzerland. A prospective audit of 2,179 cases. *Dig Surg* 17:1–8
32. Bucher P, Gervaz P, Ris F, et al. (2006) Laparoscopic versus open resection for appendix carcinoid. *Surg Endosc* 20:967–970
33. Hackert T, Uhl W, Buchler M (2002) Specimen retrieval in laparoscopic colon surgery. *Dig Surg* 19(6):502–506