

Evaluation of postmortem MDCT and MDCT-angiography for the investigation of sudden cardiac death related to atherosclerotic coronary artery disease

Katarzyna Michaud · Silke Grabherr ·
Francesco Doenz · Patrice Mangin

Received: 29 September 2011 / Accepted: 2 January 2012
© Springer Science+Business Media, B.V. 2012

Abstract The goal of this study was to evaluate the diagnostic value of postmortem multi-computed tomography (MDCT) and MDCT-angiography for sudden cardiac deaths related to ischemic heart disease. Twenty three cases were selected based on clinical history and the results of native MDCT, multiphase post-mortem CT-angiography and conventional autopsy were compared. Radiological examination showed calcification of coronary arteries in 78% of the cases, most of which were not detailed at autopsy. MDCT-angiography allowed better visualization of the coronary arteries than MDCT and permitted the evaluation of stenoses and occlusions. Of the 14 cases of coronary thrombosis detected at conventional autopsy, 11 were visible as stop of perfusion with CT-angiography and three were found to be partly perfused. One case had an old thrombosis with collateral circulation. One case had a coronary

artery postmortem clot found with MDCT-angiography. Coronary artery calcifications are more easily detected and documented with radiological examination than with conventional autopsy. MDCT is of limited diagnostic value for ischemic heart disease. MDCT-angiography, when correctly interpreted, is a reasonable tool to view the morphology of coronary arteries, rule out significant coronary artery stenoses, identify occlusions and direct sampling for histological examination.

Keywords Postmortem radiology · CT angiography · Ischemic heart disease · Coronary thrombosis

Introduction

Atherosclerosis leading to ischemic heart disease is the most frequent cause of death in industrialized countries [1]. Ischemic heart disease, resulting from impaired cardiac blood supply, is mostly related to atherosclerotic coronary artery stenosis and can manifest as angina pectoris, acute myocardial infarction, chronic ischemic heart disease or sudden death.

The diagnosis of ischemic heart disease is based on the clinical symptoms of the patient, and can be confirmed by electrocardiography, laboratory analyses, and in selected cases, by radiological examinations such as echocardiography and coronary angiography. Invasive coronary angiography is currently the “gold

K. Michaud · S. Grabherr · P. Mangin
University Center of Legal Medicine Lausanne—Geneva,
Lausanne, Switzerland

K. Michaud (✉) · S. Grabherr · P. Mangin
Centre universitaire de médecine légale,
CHUV—University of Lausanne, Rue du Bugnon 21,
1010 Lausanne, Switzerland
e-mail: katarzyna.michaud@chuv.ch

F. Doenz
Department of Diagnostic and Interventional Radiology,
CHUV—University of Lausanne, Rue du Bugnon 46,
Lausanne, Switzerland

standard” for assessing coronary artery stenosis, although it has been associated with serious complications [2]. Cardiac multi-detector computed tomography (MDCT), including contrast-enhanced MDCT coronary angiography, is considered a powerful diagnostic tool for the assessment of coronary disease in acute and in chronic cases [3]. It can also be used as a rule-out test in patients with a low to intermediate likelihood of disease, as shown by Schlattmann et al. [4] in a recent meta-regression analysis.

In post-mortem practice, the diagnosis of ischemic heart disease is made after performing macroscopic examination and standard histology. The latter can be completed with immunostaining and the measurement of cardiac biomarkers, which are both limited by the post-mortem interval [5]. The clinical history can be of relevance in determining the cause of death, but in most cases (especially in forensic practice) very little to no medical history is provided before the autopsy.

In recent years, as a result of the increased availability of computed tomography and magnetic resonance imaging in forensic practice, postmortem radiology is more frequently used [6, 7]. Authors are currently debating if postmortem radiology should be a complementary examination or if it can be considered as a good replacement for conventional autopsy [8–10]. Post-mortem MDCT appears to be very useful in demonstrating traumatic lesions. Recent studies, however, have highlighted its limited application and low accuracy in cases of natural deaths, especially in the field of cardiovascular pathology [10]. At the same time, some pioneer studies involving postmortem MDCT-angiography and cardiac pathologies have recently been published [11–13] describing the potential to overcome these weaknesses. Several authors suggest that the major limitations concerning cardio-vascular pathology could be minimized by the introduction of postmortem angiography [12, 14, 15]. In our practice, native MDCT has become part of the routine investigation. Cases with a suspicion of ischemic heart disease, regularly undergo a pre-autopsy MDCT-angiography using the technique of multiphase post-mortem CT-angiography (MPMCTA) [16]. Previous studies performed on whole body MDCT-angiography focused on vascular injuries in traumatic deaths. To our knowledge, imaging of cardiovascular disease has yet to be evaluated in detail.

The goal of this pilot study was to evaluate the diagnostic potential of MDCT and MPMCTA for the investigation of cases suspected of having ischemic

heart disease by comparing the findings of native post-mortem MDCT, MPMCTA and conventional autopsy (including the histological examination of coronary arteries and myocardium).

Material and method

Subjects

Twenty three cases were retrospectively selected based on their clinical histories that were suggestive of death due to ischemic heart disease (Table 1) The autopsies were performed between 2009 and 2010 in accordance with international guidelines [17, 18] by two forensic pathologists, one in training and one certified by the national board. The age of the subjects ranged from 37 and 89 years with a mean of 52.3 ± 12.2 . There were 21 males and 2 females. The post-mortem interval ranged from a few hours to approximately 3 days.

Radiological examination and interpretation

MDCT-angiography was carried out using the standardized protocol for MPMCTA [12] which was approved by the local ethics committee. Following the protocol, a native CT-scan was performed prior to any manipulation of the body with a 8-row CT-unit (CT LightSpeed 8, GE Healthcare, Milwaukee, WI, USA) using the following scan parameters: field of view (FOV) 50 cm, slice thickness 2.5 mm, interval of reconstruction 2 mm, 120 kVp, 280 mA and 150 s scan time. After the collection of post-mortem liquid samples for toxicological screening and analyses of cardiac biomarkers under CT-guidance [12], cannulation of the femoral vessel on one side was performed using cannulas (MAQUET GmbH & Co. KG, Rastatt, Germany) with a diameter of 16-French for arteries and 18-French for veins. A recently developed pressure-controlled perfusion device (Virtangio[®], Fumedica AG, Maquet[®], Muri, Switzerland) was used to inject a mixture of contrast agent (Angiofil[®], Fumedica AG, Muri, Switzerland) and paraffin oil (liquid paraffin obtained from the local pharmacy) according to the protocol proposed by Grabherr et al. [16]. This oily contrast has an appropriated viscosity for the perfusion of human bodies [19], allowing for optimal perfusion conditions for high-resolution

Table 1 Overview of all findings made during autopsy, native CT and CT-angiography

No	Sex	Age	Clinical history	Body weight (kg)	Heart weight (g)	Coronary arteries	Coronary arteries autopsy and histological examination		Angio CT scan cardiac/coronary findings			Native CT scan		Myocardium (autopsy and findings) other findings
							Vulnerable plaque	Acute thrombosis	Stenosis	Perfusion of coronary arteries	Calcifications of coronary arteries	Other	Calcifications of coronary arteries	
1	M	48	Drowning	83	500	RCA LAD LCX	E	I	++ +++	NP PP	++ ++	++ ++	++	PW: AMI
2	M	46	Found dead at home	79	500	RCA LAD LCX			++ ++	PP PP	++ ++	++ ++	++	PW: AMI
3	F	47	Sudden death a few hours after a chest pain	60	360	RCA LAD LCX	R	I	+++	NP	+	+	+	AW: AMI
4	M	37	Sudden death shortly after abdominal pain	120	420	RCA LAD LCX	E	I		PP				
5	M	42	Sudden death shortly after chest pain	120	480	RCA LAD LCX								PW: AMI
6	M	52	Sudden death after physical effort	76	490	RCA LAD LCX			++ + +++	PP PP PP	++ ++ ++	++		AW: AMI
7	M	56	Dyspnea since a few days	77	490	RCA LAD LCX	O	R	+++ ++	NP PP	++ ++	++	++	AW: SAMI PW: old subendocardial infarct hibernating myocardium AW: AMI
8	M	50	Found dead at home Chest pain the day before	57	450	RCA LAD LCX			+ ++ +	PP PP	++ ++	++	++	AW: myocardial enhancement/ image of pulmonary emboli
9	M	65	Found dead at home, suspicion of poisoning	63	490	RCA LAD LCX	R	I	+ ++	NP			++	P-SW: SAMI

Table 1 continued

No	Sex	Age	Clinical history	Body weight (kg)	Heart weight (g)	Coronary arteries	Coronary arteries autopsy and histological examination			Angio CT scan cardiac/coronary findings			Native CT scan		Myocardium (autopsy and histology findings) other findings
							Vulnerable plaque	Acute thrombosis	Stenosis	Perfusion of coronary arteries	Calcifications of coronary arteries	Other	Calcifications of coronary arteries	Others	
10	M	67	Sudden death at the train station	67	520	RCA LAD LCX	R	I	++	NP ? PP	++	Myocardial enhancement problem of perfusion LAD (plaques or technical problems)	++		PW: SAMI
11	M	52	Found dead at home	65	350	RCA LAD LCX			+++ +	PP PP	+		+		PW: fibrosis alteration postmortem
12	M	52	Found dead at home by his wife Any medical history	73	500	RCA LAD LCX	O + R	I		PP NP					PW: AMI and fibrous scar
13	F	67	Found dead at home thoracic oppression since 1 week	56	300	RCA LAD LCX			+ + ++	PP PP NP	++	Hemopericardium A-SW: enhancement of the myocardium and rupture	++	Hemopericardium	Hemopericardium PW: SAMI and rupture of the myocardium
14	M	42	Found dead at his workplace Any medical history	90	470	RCA LAD LCX			+++ +++ +	PP PP	++	S: enhancement of the myocardium	++		PSW: fibrosis transmural mostly subendocardiac (old infarct scar)
15	M	35	Found dead at home by the police, methadone and alcohol intoxication	80	490	RCA LAD LCX				NP	++		++		Post-mortem fragmentation of fibres
16	M	44	Found dead by his wife in the bed	75	390	RCA LAD LCX	E	I	++ +	NP PP PP	++		++		PW: AMI

Table 1 continued

No	Sex	Age	Clinical history	Body weight (kg)	Heart weight (g)	Coronary arteries	Coronary arteries autopsy and histological examination			Angio CT scan cardiac/coronary findings			Native CT scan			Myocardium (autopsy and histology findings) other findings
							Vulnerable plaque	Acute thrombosis	Stenosis	Perfusion of coronary arteries	Calcifications of coronary arteries	Other	Perfusion of coronary arteries	Calcifications of coronary arteries	Others	
17	M	45	Sudden death while jogging	75	460	RCA LAD LCX		+++		NP	+		+			
18	M	49	Sudden death after chest pain	83	480	RCA LAD LCX		+								LV hypertrophy P-SW: AMI P-SW: small foci of fibrosis LW: contraction bands
19	M	69	Sudden collapse while driving	71	470	RCA LAD LCX	R	++		NP		++	++			
20	M	54	Sudden collapse while driving	80	470	RCA LAD LCX	E	++		NP		++	++			AW: a few contraction bands
21	M	43	Found dead at home, history of palpitations	80	550	RCA LAD LCX		+			+		+			LV hypertrophy mitral floppy valve P-SW: contractions bands
22	M	53	Found dead at home	94	440	RCA LAD LCX	O	++		PP		++	++			P-SW: AMI and subendocardial infarct scar
23	M	89	Collapse followed by a fall	46	285	RCA LAD LCX	O + R	++		NP		++	++			PW: old transmural infarct scar and SAMI

Autopsy diagnosis was based on macroscopic and histologic appearance

RCA right coronary artery, LAD left anterior descending coronary artery, LCX left circumflex coronary artery, LMCA left main coronary artery. Vulnerable plaque: E eroded plaque, R ruptured plaque, O old thrombus. Thrombosis: I present. Stenosis of coronary arteries at autopsy and histological evaluation: + <50%, ++ 50–75%, +++ 75% or more. Perfusion of coronary arteries in CT-angiography: NP not perfused or stenosis more than 75%, PP partly perfused or stenosis <75%. Calcifications of coronary arteries evaluated in postmortem radiological examination: + isolated calcification; ++ multiple calcifications. Histological evaluation of myocardial ischemia: AMI acute myocardial infarct, SAMI subacute myocardial infarct, AW anterior wall, PW posterior wall, S septum, P-SW postero-septal wall, A-SW antero-septal wall

postmortem angiography and simultaneously avoiding histological artifacts. The arterial phase of MPMCTA was carried out using the following scan parameters: field of view 50 cm, slice reconstructed thickness 1.25 mm, interval of reconstruction 0.6 mm, 120 kVp, 280 mA and a scan time of 140 s. Scan parameters of the venous and dynamic phase were: field of view 50 cm; slice reconstructed thickness 2.5 mm; interval of reconstruction 1.2 mm, 120 kVp, 280 mA and a scan time of 140 s.

The radiological interpretations of all images were performed by both a board certified radiologist specialized in vascular radiology and a board certified forensic pathologist trained in forensic imaging. They were both blinded to the autopsy results. Segments of coronary arteries that were deemed to be unperfused or stenosed greater than 75% with CT-angiography were subsequently evaluated histologically as the stenoses greater than 75% or occluded lumen are associated with hemodynamically significant disturbances which lead to myocardial infarction and explain the sudden cardiac death. Above the 75% cut-off, the stenosis is considered as the highly probable cause of death after exclusion of other causes [17].

After CT-angiography, stenoses and occlusions of coronary arteries were further evaluated upon autopsy and histological examination.

Conventional autopsy

During the autopsy procedure a transverse slide of myocardium was systematically taken for histological examination, along with at least five labeled blocks of myocardium: the anterior, lateral and posterior wall of the left ventricle, the interventricular septum and the lateral wall of the right ventricle, in order to correlate the coronary artery pathology with the myocardial findings in the area which it supplies. For most cases the proximal and medial parts of coronary arteries were retained for decalcification prior to dissection. In several cases only the most stenosed fragments were histologically analyzed.

Results

All results are reported in Table 1.

Coronary calcifications

In 78% of the analyzed cases (18/23), calcification of coronary arteries was found on radiological examination. Calcifications were easily detected with both native CT-scan and CT-angiography. The calcifications were associated with coronary thromboses in 12 cases. There were no calcifications found in two cases (cases no 4 and no 5, aged 37 and 42, respectively), but angio-CT revealed a stenosis of 50–75% of one coronary artery, suspected to be related to a vulnerable plaque/thrombosis. Pathological investigation revealed the presence of an acute thrombosis related to an eroded plaque. In another case of a 45 year old jogger (case no 17), only a small calcification of the left anterior descending (LAD) artery was found, and a 75% narrowing in the middle part of the LAD was confirmed by autopsy and histological examination (Fig. 1). A calcium score was not evaluated in this pilot study and the extent of coronary calcification found on radiological examination was not systematically described in the autopsy reports, therefore the correlation between the two was not evaluated in this retrospective study. MDCT or MPMCTA appears to be a more sensitive means of detecting calcifications than conventional autopsy. Radiological examination also provides a simpler means of documenting the calcification status of all coronary arteries.

Coronary stenosis/atherosclerotic vulnerable plaque/thrombosis

Thirteen cases were selected, and a thrombosis was found in 11 of them. In one suspected case (no 15), a postmortem clot was responsible for the stop of perfusion. In another case (no 17), CT-angiography revealed a ~75% stenosis of the LAD that was not initially observed by the forensic pathologist in training upon a longitudinal opening of the vessel. A retrospective morphological exam of the same case permitted detection of a gross intramural plaque with significant stenosis of the lumen. The histological examination of the myocardium demonstrated signs of an early subendocardial infarct (Fig. 1).

In each of two previously mentioned cases (no 4 and no 5), CT-angiography revealed the presence of a 50–75% stenosis of the coronary artery and autopsy demonstrated a thrombosis related to eroded plaques.

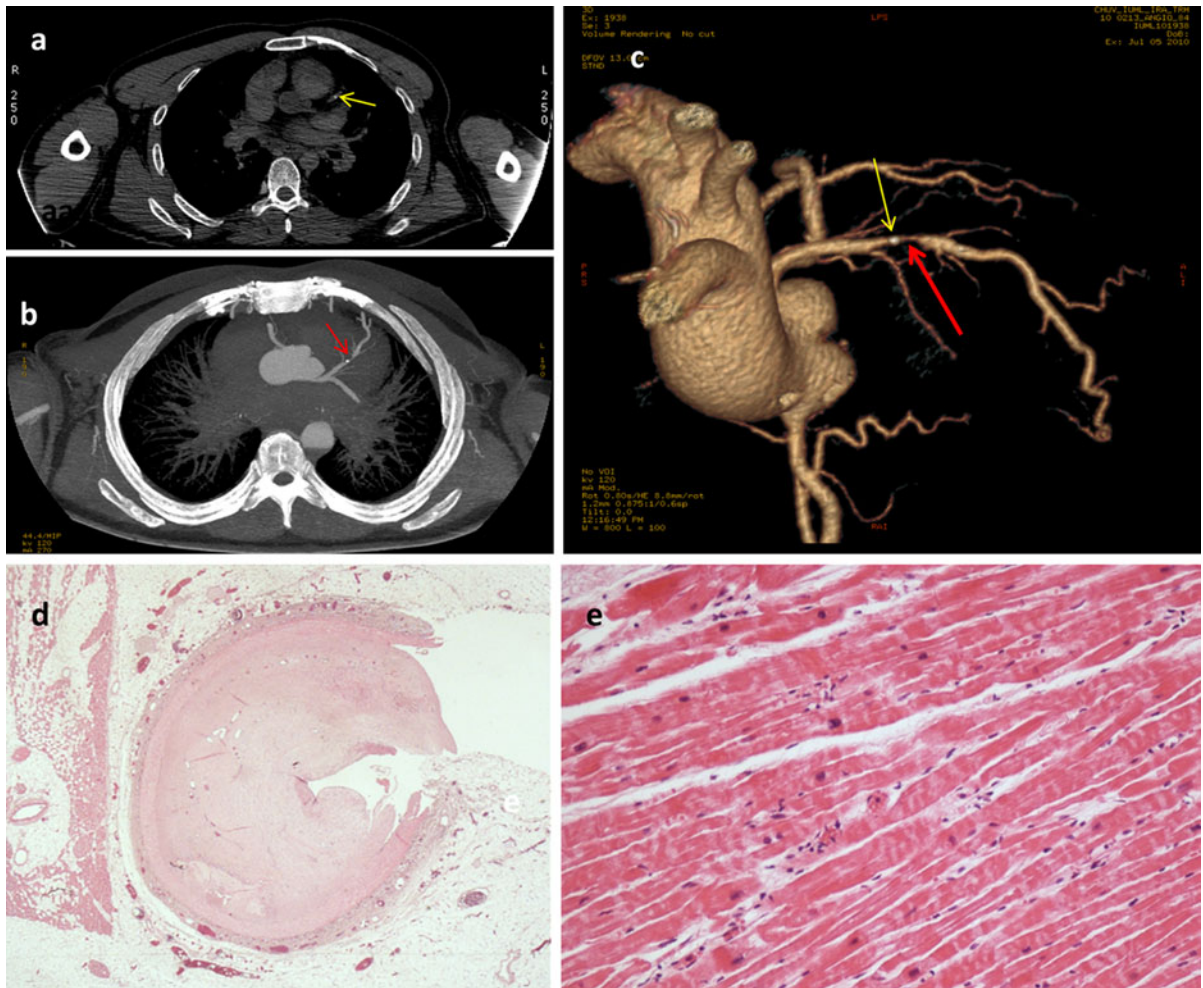


Fig. 1 Case of a 45 year old man who died suddenly while jogging (case no 17): native CT image (a) shows an isolated calcification of the middle part of the LAD artery (arrow). Angio-CT (b) shows a partial occlusion (arrow) of the LAD, immediately distal to the calcification. A 3D-reconstruction performed on the data of the arterial phase of PMPCTA

(c) demonstrates the localization of both lesions: the small calcification (yellow arrow) and the stenosis of LAD (red arrow). Histological examination (d) showed a significant stenosis of the LAD artery and signs of myocardial ischemia as contraction band necrosis (haematoxylin & eosin) (e)

In one case (no 2), the common trunk of the left coronary artery could not be perfused during CT-angiography, likely due to a technical problem (i.e. remaining blood or post-mortem clot inside the vessel). The artery was described to be normal at autopsy. Unfortunately, the common trunk was not collected for histological examination.

A coronary thrombosis was found during autopsy in 14 cases: acute or subacute in 11 cases, of various ages in two cases and old in one case. A ruptured plaque was found in seven cases (Fig. 2) and an eroded plaque in six cases (Fig. 3). The mean age of all 14 cases was 56.7 ± 13.7 , however, upon stratification the mean

age of the victims with ruptured and eroded plaques was 60.5 ± 8.2 and 46 ± 9.7 , respectively. The details are shown in Table 1. An old recanalised thrombus with collateral circulation was detected in three cases (Fig. 4), which was better visualized during the radiological exam than during conventional autopsy. 3D-reconstructions from MPMCTA proved to be a very simple technique to investigate collateral circulation.

In summary, of the 14 cases of coronary thrombosis detected at autopsy, 11 were not perfused during CT-angiography, two acute thromboses related to eroded plaques were visualized as stenosis of $\sim 50\text{--}75\%$ and

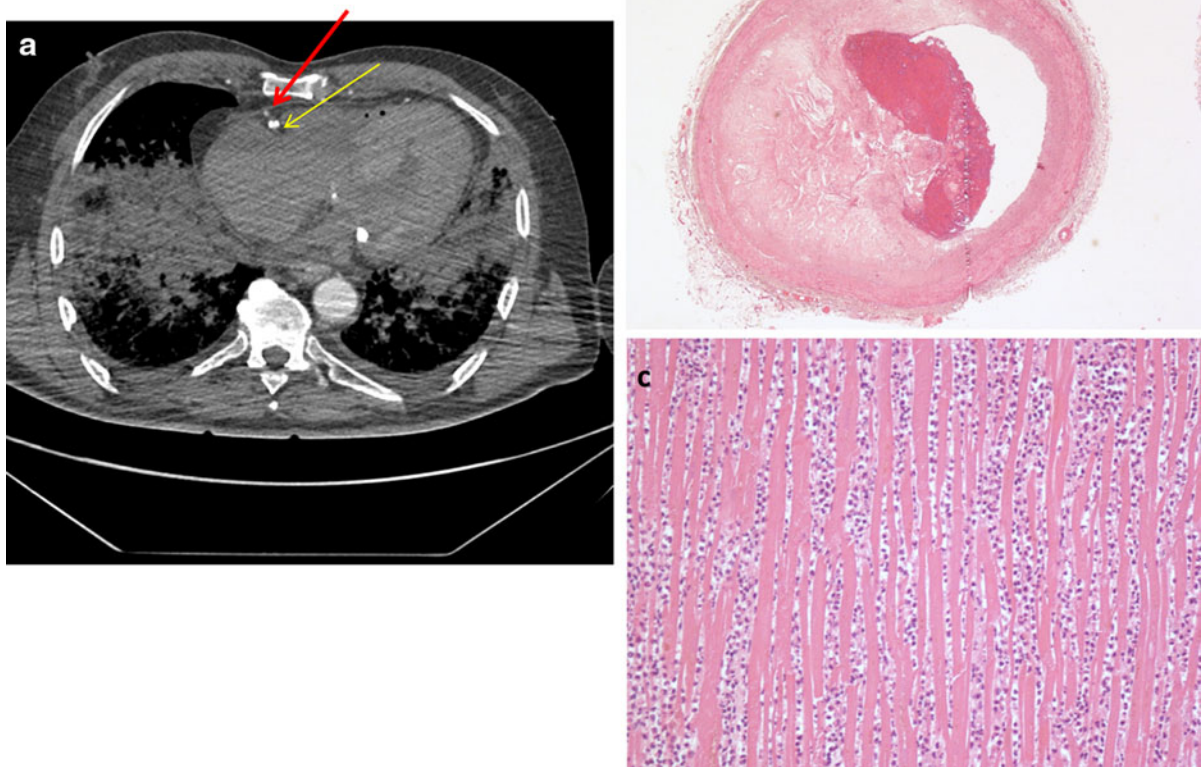


Fig. 2 Sixty-seven year old man who died suddenly while catching the train (case no 10): CT-angiography showed a calcified plaque of the RCA (*yellow arrow*) and a defect of perfusion (*red arrow*) with perihilar oedema (**a**). Histological

examination showed a ruptured plaque of the RCA (**b**) and an infarct of the posterior wall of the left ventricle with diffuse infiltration of polymorphonuclear neutrophil cells (haematoxylin & eosin) (**c**)

one case with an old thrombosis was described as a partial occlusion with collateral circulation.

Positive arterial wall remodeling, which is a well known reaction to plaque formation [20], was seen with CT-angiography in two cases. An increase of the cross sectional area with normal lumen dimension was observed. The remodeling was associated with an acute thrombosis in one case of a 47 year old woman (no 3). There was no description of remodeling in the autopsy report.

Cardiac tamponade

Hemopericardium was described in one case and was observed in the native and angio-CT scans. CT-angiography, however, permitted better visualization

of the ruptured wall situated in the apical part of the left ventricle, as the contrast agent leaked through the rupture (Fig. 5). These findings were confirmed during the conventional autopsy.

Signs of infarction

Histological patterns of infarction vary with infarct dating, ranging from the absence of histological lesion to old myocardial scar. These histological findings cannot be detected with certitude during CT examination. In 5 cases, however, a “pathological enhancement” (mean Hounsfield Units ≥ 100) of the myocardium was observed in regions which correlated with the localization of the infarction. While the arterial phase mostly showed a diffuse enhancement of

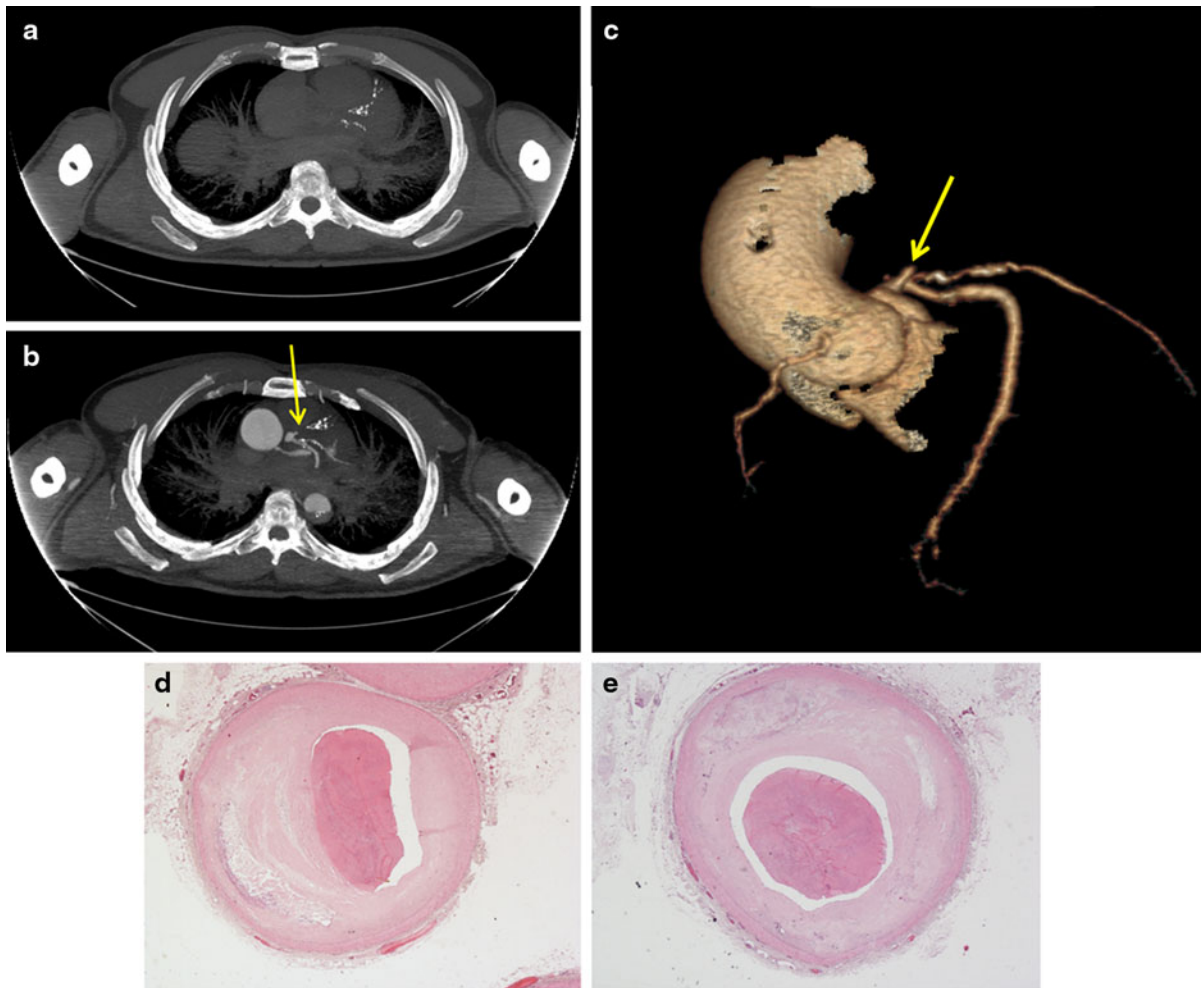


Fig. 3 Sudden collapse while driving in a 54 year old man (case no 20): native CT shows multiple calcifications of LAD (a), angio-CT (b, c) calcifications and an occlusion (*arrow*) of

LAD, histological examination of LAD reveals a thrombosis (haematoxylin & eosin) (d, e)

the concerned myocardium, enhancement increased in the subendocardial layer during the venous and dynamic phase.

Post-mortem clot and other artifacts

In one case, a postmortem clot of a coronary artery was suspected upon radiological imaging (Fig. 6a). The autopsy investigation excluded the presence of a thrombosis and complimentary investigations showed that death was related to acute alcohol and methadone intoxication.

A pulmonary artery embolism was suspected after performing CT angiography in three cases (Fig. 6b), but none of them were confirmed by autopsy investigations.

Discussion

Imaging of ischemic heart disease includes the evaluation of the coronary arteries and myocardium, both in a clinical and postmortem setting [21–25].

In a clinical setting, the myocardium and coronary arteries can be radiologically evaluated with echocardiography, nuclear cardiology, cardiac CT and magnetic resonance techniques. Cardiac CT allows for the non-invasive imaging of coronary arteries and, in selected patients, plays an important role for the diagnosis of coronary artery disease. The visualization of coronary arteries in clinical practice, however, can be difficult as they are small and constantly in motion. The last limitation is not an obstacle in the postmortem setting.

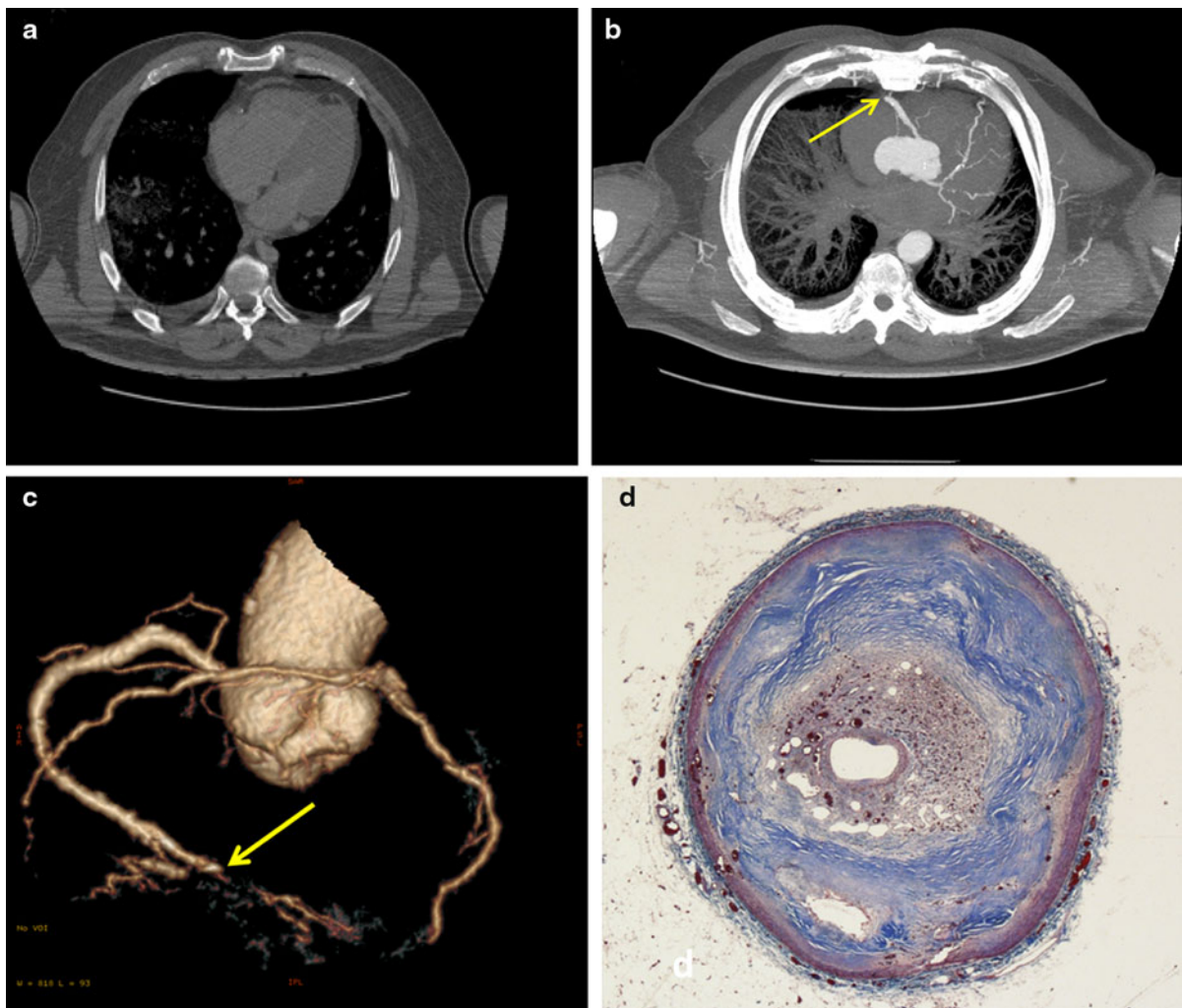


Fig. 4 Old recanalised thrombosis in a 53 year old man found dead at home (case no 22): native CT without significant lesions (a), PMPCTA revealed an occlusion (arrows) in the distal part of RCA (b, c). The histological examination of this region

identified a recanalised thrombus in the late stages after thrombosis, in which many small capillary sized channels are seeded (Masson's trichrome) (d)

In our study the native CT-scan was not very helpful for the diagnosis of ischemic heart disease, as observed in previous studies [10]. Only calcifications of coronary arteries and evident cardiac pathological findings, such as cardiac tamponade, were observed. The most relevant yet subtle lesions such as coronary occlusions, stenoses and myocardial ischemia were not detected with the native CT-scan, despite the fact that post mortem imaging lacks the clinical limitation of coronary artery motion.

Calcifications were observed in 78% of the cases. Focal calcifications in atherosclerotic plaques are very common, particularly in older patients. Calcifications

do not have a direct causal link to thrombosis, with the exception of older individuals when the presence of diffuse intimal calcification is coupled with diffuse dilatation of coronary arteries and intimal tears at the margin of calcium plates. It is accepted that the extent of calcification roughly relates to the amount of atherosclerosis, but not to the degree of coronary artery stenosis [26, 27]. Moreover, clinical observations suggest that lesions responsible for acute thrombotic episodes are generally less calcified than plaques involved with stable angina [28]. This could be one reason why the pathologist did not systematically describe this finding in the autopsy reports.

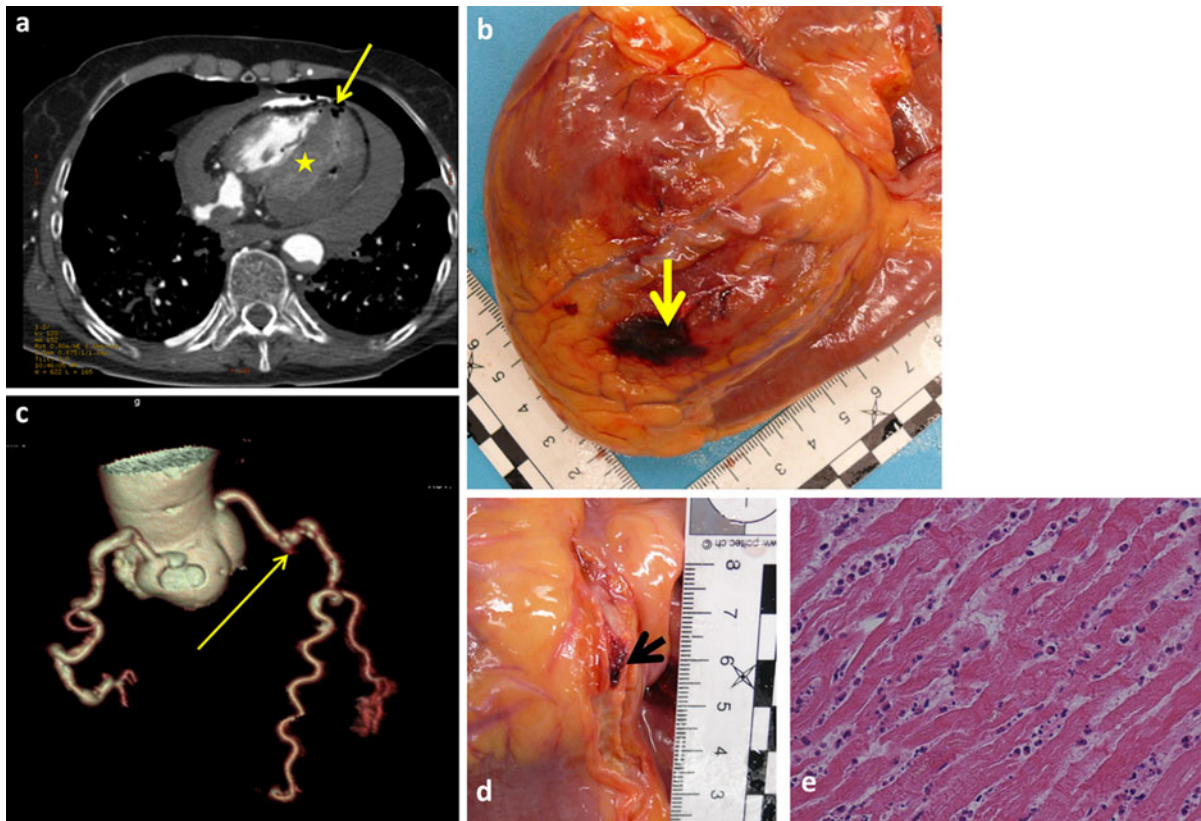


Fig. 5 Subacute infarct related to LCX thrombosis and hemopericardium in a 67 year old woman (case no 13). Rupture of the posterior wall (*arrows*) in CT angiography (**a**) and at autopsy (**b**). An enhancement of the infarcted myocardium is observed (*asterisk* in **a**) during the arterial phase of PMPCTA. 3D-reconstruction (**c**) performed on data of the arterial phase

Radiologically, the presence of calcium is invariably associated with coronary atherosclerosis, especially in its advanced stage. Using cardiac CT, calcium deposits in the coronary arteries can be detected and quantified with low-radiation and non-enhanced image acquisition protocols. A high coronary calcium score, when adjusted for age and gender, is considered to be predictive of coronary adverse events [29]. However, in younger patients, a population which is mostly investigated in the forensic setting, non-calcified plaques have also been linked to episodes of acute chest pain. Kwon et al. [30] showed that CT cannot assess the coronary stenosis of non-calcified plaques in low risk patients suspected of having coronary artery disease because coronary CT angiography coupled with coronary artery calcium has no incremental prognostic value when compared to coronary CT angiography alone. It has been

shows a complete occlusion (*arrow*) of LCX. Autopsy investigation of LCX (**d**) revealed an occlusive thrombosis (*arrow*) and histological examination of the myocardium showed a myocardial infarction (**e**) presented as necrosis of cardio-myocytes and diffuse infiltration of polymorphonuclear neutrophils cells (haematoxylin & eosin)

demonstrated that the amount of calcified plaque may not be associated with an increased risk of future coronary events [31]. In our series, no calcifications were observed in two cases of relatively young patients (aged 37 and 42) and pathological investigations revealed the presence of acute thromboses related to eroded plaques. In others cases, CT-angiography revealed the presence of occlusions thought to be related to acute thromboses or significant atherosclerotic plaques, while only isolated calcifications of coronary arteries were found.

Postmortem CT-angiography enabled better visualization of coronary arteries than native CT and allowed for the evaluation of stenoses and occlusions. Only a few recent studies have addressed this topic [12–14]. Saunders et al. [13] presented the developmental stages for manual targeted in situ postmortem angiography using injections of air/Urografin® and

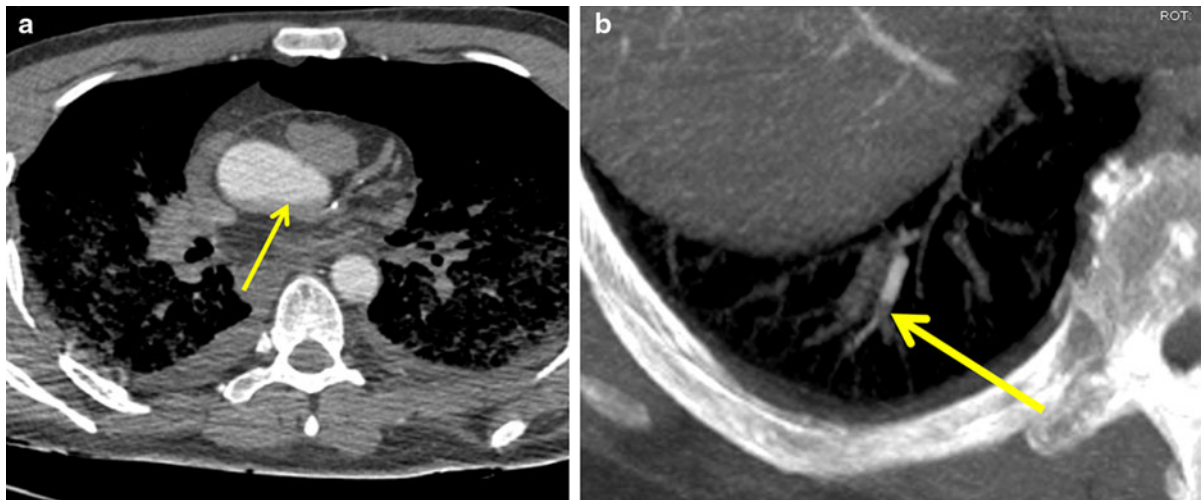


Fig. 6 Artifacts observed during the study: problem of perfusion related to a post-mortem clot (**a**) in case no 15 producing the image of a layer (*arrow*) in the ascending aorta and rendering opacification of the left coronary artery

demonstrated that large volumes of air and contrast can be injected without displacing the thrombi. In a more recent study, Roberts et al. presented a series of 10 cases in which a novel method of postmortem coronary artery CT angiography was used by injecting contrast medium into the left common carotid artery. Their results showed relatively good correlation with autopsy findings. The disadvantage of this technique is related to the repositioning of the catheter after a CT control, often resulting in unsatisfactory filling of coronary arteries which necessitates turning of the patient with further injections and CT scanning [12]. We did not encounter any problems related to the positioning of the catheter or filling of coronary arteries, as the technique of PMPCTA is standardized and coronary arteries are visualized in all cases except those of massive aortic rupture. We performed histological examinations of coronary arteries permitting better evaluation of image-autopsy correlations.

Acute thrombosis is the result of two different pathological processes: plaque disruption and endothelial erosion. In this study, an acute coronary thrombosis was found in 13 cases: seven were related to plaque rupture and six to plaque erosion. CT angiography detected “suspect” segments of coronary arteries in all 13 cases: 11 cases did not have perfused segments and in two cases of young victims partial occlusions were found in non-calcified coronary arteries. The victims were younger in the group of

impossible (**b**): stop of perfusion observed in case no 5 located in a pulmonary artery due to a post-mortem clot (*arrow*), suggesting a pulmonary embolism that could not be confirmed at autopsy

plaque erosion than that of plaque rupture, in accordance with previous pathological studies [32, 33]. The results of this study indicate that MPMCTA is a reasonable tool to rule out coronary artery stenosis and to indicate suspected occlusions in order to direct sampling for histological examination. Clear patterns of vulnerable plaques (rupture versus erosion) were, however, not identified in postmortem CT nor in CT angiography in this series. This is also true in clinical practice as traditional CT-angiography is insensitive for the detection of plaques as the resolution is insufficient to visualize this lipid-rich core and fragile rupture-prone fibrous cap which is responsible for plaque rupture, inflammation, and neovascularisation [2]. The identification of patients with vulnerable plaques is difficult and the combination of several sophisticated imaging methods (i.e. OCT/Backscattered IVUS; IVUS/Raman spectroscopy OCT—optical coherence tomography; IVUS—intravascular ultrasound) may provide the most information on the presence or absence of disease [8]. Many of these methods cannot be used in the post-mortem setting. Also eroded plaques contain no specific features that enable their detection upon radiological examination, with the exception of stenosis. It has recently been suggested that lipid and fibrous coronary plaque attenuation values are significantly modified by differences in lumen contrast densities both in and ex vivo [34]. This hypothesis should be verified by

large autopsy series performed after radiological postmortem examination. A prospective study would enable the evaluation of the degree of stenosis/perfusion and calcifications, as well as the remodeling in the proximal, middle and distal segments of all coronary arteries in both radiological and autopsy examinations. The labeled segments of coronary arteries should be collected and examined histologically. Labeled samples of myocardium should be collected in order to correlate coronary artery pathology with myocardial ischemia.

In our series, no thromboses were found in eight cases: four cases had a stenosis of one coronary artery and two cases had left ventricular hypertrophy. One must question if the pre-existing thrombosis could have been eventually dislodged in some of these cases. Although impossible to exclude this hypothesis, it seems unlikely considering that in this series even very discrete lesions, such as eroded plaques, were visualised with the angiographic CT-examination. The advantage of PMPCTA is that there is no direct mechanical manipulation of the coronary arteries. As the cannulation site is located in one inguinal region with a very low perfusion pressure (1,200 ml in 90 s for the arterial phase), the perfusion flow in the coronary arteries is slower than *in vivo*. It has been shown that coronary artery spasm or myocardial hypertrophy may provoke an ischemic event without any thrombosis, and that sudden death may result from an associated arrhythmia. It is also widely accepted that the diagnosis of death related to chronic ischemic heart disease can be made in the presence of narrowing of 75% or more in at least one of the main coronary arteries as long as other complimentary analyses, such as toxicology or clinical chemistry, are negative.

Coronary CT-angiography, like invasive angiography, is a morphological imaging technique and cannot demonstrate the functional relevance of stenoses. This is particularly relevant in clinical practice for patients with borderline degrees of stenosis [35], where CT and CT angiography are unable to detect myocardial ischemia and necrosis. As shown in the Meijboom study, CT can help rule out coronary stenosis and myocardial ischemia, but even pronounced atherosclerotic changes and stenosis seen on CT do not reliably predict the presence of ischemia that can be visualised by perfusion imaging [35, 36]. In our post-mortem series, pathological enhancement of the myocardium was observed in five cases and is thought

to be an indirect sign of a myocardial lesion. Angiography is a promising soft tissue imaging technique, however, more studies are needed to determine its potential. Post-mortem magnetic resonance imaging does not have this limitation and can identify soft tissue lesions [11], but its accessibility is more limited than MDCT or CT-angiography and its usefulness is still being evaluated for post-mortem examinations. Postmortem CT-angiography and cardiac MRI have their advantages and disadvantages. The biggest advantage of post-mortem CT angiography is the ability to detect stenoses or occlusions although Ruder et al. [37] recently presented a postmortem assessment of coronary artery disease by MRI and suggested that chemical shift artifacts along the coronary arteries may be considered a marker of vessel patency, thus improving the ability of minimal autopsy procedures to detect coronary artery disease. Jackowski et al. [38] presented a case report with a postmortem MRI based diagnosis of sudden coronary artery occlusion and peracute septal myocardial ischemia without the application of contrast agents. More studies are needed to establish the postmortem radiological diagnostic gold standards and to determine their cost-effectiveness. Both methods have been associated with specific postmortem artifacts. At present we have more experience with the postmortem CT-scans than postmortem MRI which was introduced more recently. In regards to the dislodgement of a thrombus, unperfused postmortem MRI has not been shown to do so while the possibility has not been excluded for angiography techniques.

The disadvantage of both postmortem techniques is that angio-CT and cardiac MRI require dedicated technical equipment as well as radiologists experienced in the field of postmortem radiology. MRI equipment is more expensive than CT and radiological norms defining the space required for magnetic shielding are different than that for CT. CT is employed with greater and greater frequency, while postmortem MRI exists in only a few academic research centers. Radiological CT exams are faster and have a higher resolution due to a higher radiation dose and smaller slices. The high radiation dose is of no concern in post-mortem imaging. Although MRI is the method of choice for the investigation of the myocardium, CT-angiography remains the best technique for the investigation of the coronary arteries and any related calcifications which are a weakness of

MRI. CT-angiography perfusion enables the evaluation of the vascular lumen which can often be collapsed or filled with remaining blood or gas bubbles in the cadavers. Without the opacification of the lumen, the interpretation of the presence or absence of stenoses is not possible. At present, MRI can not differentiate between post-mortem clots and pathological thrombi. Postmortem clots can only be identified after reperfusing the vessels and comparing the images of the different phases of post-mortem angiography, thus avoiding any misinterpretation.

At present, histology remains the reference method for the post-mortem diagnosis of ischemic heart disease. According to the current recommendations in the field of autopsy practice and cardiovascular pathology [17, 18, 24, 39–41], histological examination of the myocardium should be performed in order to assess the time dependent histological patterns of ischemia. Some pathological findings, such as acute coronary occlusive thrombosis or myocardial rupture, are practically certain to represent the cause of death, whereas, the interpretation of chronic macroscopic findings, such as those described in ischemic heart disease, is more delicate. Considering the medical responsibility implications and potential third party involvement, an accurate diagnosis and dating are essential. Correlations between autopsy and histological findings with modern post-mortem coronary artery imaging may help us to better understand the clinical and radiological aspects of acute coronary syndromes. The histology of coronary arteries is of particular importance, especially for cases of sudden cardiac death with little to no clinical history. Instant death due to ventricular fibrillation or atrio-ventricular (AV) block is a frequent complication of coronary thrombosis before medical intervention and represents 50% of acute myocardial infarction mortality [4]. Most of these patients are young and have a proximal thrombotic occlusion of the LAD artery [26]. Forensic autopsies of these patients, consisting of radiological and histological examinations, are very important.

Clinically, it is well recognised that there is no relationship between the degree of coronary stenosis and the onset of symptoms, complications and acute coronary-syndrome mortality. A significant proportion of thrombotic occlusions do not develop at sites of pre-existing high-grade stenosis or plaque formation. Up to 75% of vulnerable plaques leading to acute infarction are associated with stenoses having a

previous diameter of less than 50%. Only a minor percentage of occlusions develop on stenoses with a previous diameter greater than 70% [5]. These intricate relationships need to be evaluated in larger case–control studies. The information obtained from post-mortem examinations, including CT angiography and MRI, can help improve the clinical diagnosis and treatment for the most vulnerable patients.

Cardiac tamponade, which is often associated with acute myocardial infarction, can be easily diagnosed with classical autopsy and both native and CT angiography. Although postmortem CT and CT angiography enable visualization of other pathologies, such as pulmonary edema and pericardial or pulmonary effusions, these findings are not specific for ischemic heart disease and may be observed with other cardiac diseases.

Coronary postmortem CT angiography is a reasonable tool to view the morphology of coronary arteries, rule out coronary artery stenosis and occlusion, and direct sampling for histological examination. Radiological cardiac postmortem examination also enables the revision of many cases in which it is impossible to keep the entire heart due to legal restrictions. It is too early to postulate that this technique is sufficient to diagnose that the cause of death was related to an acute or chronic ischemic event. Postmortem cardiac radiology is a new field for both forensic pathologists and radiologists, both of whom have to learn to read the postmortem modified images, including the interpretation of possible artifacts. The visualisation and differentiation of post-mortem artifacts in CT imaging has yet to be studied.

As reported in clinical practice, the diagnostic performance of coronary CT angiography can be improved when read by experienced physicians, but acquiring expertise in coronary CT angiography is slow and may take more than 1 year [10]. The information obtained from both radiology and forensic pathology in post-mortem investigations can help to further the understanding of radiological evaluation in the clinical setting.

Limitations

This pilot study contained a small number of cases and larger studies are needed to find statistical correlations. This study, however, highlights the importance of comparing the radiological data with the autopsy and

histological findings of coronary arteries and myocardium for deaths related to ischemic heart disease. In our opinion, prospective studies should be performed to evaluate the correlations between radiological examination findings as calcium score, myocardial enhancement and autopsy and histological findings.

Acknowledgments This study was partly financially supported by the Promotion Agency for Innovation of the Swiss Confederation (KTI Nr.10221.1 PFIW-IW). We thank the team of the unity of forensic medicine in Lausanne for their assistance and Allison Felley Jacquemont for editing the manuscript.

Conflict of interest None.

References

- Chugh SS, Reinier K, Teodorescu C, Evanado A, Kehr E, Al Samara M, Mariani R, Gunson K, Jui J (2008) Epidemiology of sudden cardiac death: clinical and research implications. *Prog Cardiovasc Dis* 51(3):213–228. doi:[10.1016/j.pcad.2008.06.003](https://doi.org/10.1016/j.pcad.2008.06.003)
- Roberts WT, Bax JJ, Davies LC (2008) Cardiac CT and CT coronary angiography: technology and application. *Heart* 94(6):781–792. doi:[10.1136/hrt.2007.116392](https://doi.org/10.1136/hrt.2007.116392)
- Winchester D, Jois P, Kraft S, Wymer D, Hill J (2011) Immediate computed tomography coronary angiography versus delayed outpatient stress testing for detecting coronary artery disease in emergency department patients with chest pain. *Int J Cardiovasc Imaging (former Cardiac Imaging)* 1–8. doi:[10.1007/s10554-011-9870-x](https://doi.org/10.1007/s10554-011-9870-x)
- Schlattmann P, Schuetz G, Dewey M (2011) Influence of coronary artery disease prevalence on predictive values of coronary CT angiography: a meta-regression analysis. *Eur Radiol* 1–10. doi:[10.1007/s00330-011-2142-2](https://doi.org/10.1007/s00330-011-2142-2)
- Batalis NI, Marcus BJ, Papadea CN, Collins KA (2010) The role of postmortem cardiac markers in the diagnosis of acute myocardial infarction. *J Forensic Sci* 55(4):1088–1091. doi:[10.1111/j.1556-4029.2010.01368.x](https://doi.org/10.1111/j.1556-4029.2010.01368.x)
- Dirnhofer R, Jackowski C, Vock P, Potter K, Thali MJ (2006) VIRTopsy: minimally invasive, imaging-guided virtual autopsy. *Radiographics* 26(5):1305–1333. doi:[10.1148/rg.265065001](https://doi.org/10.1148/rg.265065001)
- Thali M, Dirnhofer R, Vock P (eds) (2009) *The virtopsy approach: 3D optical and radiological scanning and reconstruction in forensic medicine*. CRC Press, New York
- Jeffery AJ (2010) The role of computed tomography in adult post-mortem examinations: an overview. *Diagnostic Histopathology* 16(12):546–551
- O'Donnell C (2010) An image of sudden death: utility of routine post-mortem computed tomography scanning in medico-legal autopsy practice. *Diagn Histopathol* 16(12):552–555. doi:[10.1016/j.mpdp.2010.08.010](https://doi.org/10.1016/j.mpdp.2010.08.010)
- Weustink AC, Hunink MGM, van Dijke CF, Renken NS, Krestin GP, Oosterhuis JW (2009) Minimally invasive autopsy: an alternative to conventional autopsy? 1. *Radiology* 250(3):897–904. doi:[10.1148/radiol.2503080421](https://doi.org/10.1148/radiol.2503080421)
- Jackowski C, Warntjes M, Berge J, Bär W, Persson A (2011) Magnetic resonance imaging goes postmortem: noninvasive detection and assessment of myocardial infarction by postmortem MRI. *Eur Radiol* 21(1):70–78. doi:[10.1007/s00330-010-1884-6](https://doi.org/10.1007/s00330-010-1884-6)
- Roberts ISD, Benamore RE, Peebles C, Roobottom C, Traill ZC Diagnosis of coronary artery disease using minimally invasive autopsy: evaluation of a novel method of post-mortem coronary CT angiography. *Clin Radiol*, corrected proof (in press). doi:[10.1016/j.crad.2011.01.007](https://doi.org/10.1016/j.crad.2011.01.007)
- Saunders S, Morgan B, Raj V, Robinson C, Ruttly G (2011) Targeted post-mortem computed tomography cardiac angiography: proof of concept. *Int J Legal Med* 1–8. doi:[10.1007/s00414-011-0559-4](https://doi.org/10.1007/s00414-011-0559-4)
- Saunders S, Morgan B, Raj V, Ruttly G (2010) Post-mortem computed tomography angiography: past, present and future. *Forensic Sci Med Pathol* 1–7. doi:[10.1007/s12024-010-9208-3](https://doi.org/10.1007/s12024-010-9208-3)
- Grabherr S, Gyax E, Sollberger B, Ross S, Oesterhelweg L, Bolliger S, Christe A, Djonov V, Thali MJ, Dirnhofer R (2008) Two-step postmortem angiography with a modified heart lung machine: preliminary results. *Am J Roentgenol* 190(2):345–351. doi:[10.2214/ajr.07.2261](https://doi.org/10.2214/ajr.07.2261)
- Grabherr S, Doenz F, Steger B, Dirnhofer R, Dominguez A, Sollberger B, Gyax E, Rizzo E, Chevallier C, Meuli R, Mangin P (2010) Multi-phase post-mortem CT angiography: development of a standardized protocol. *Int J Legal Med* 1–12. doi:[10.1007/s00414-010-0526-5](https://doi.org/10.1007/s00414-010-0526-5)
- Basso C, Burke M, Fornes P, Gallagher P, de Gouveia R, Sheppard M, Thiene G, van der Wal A, on behalf of the Association for European Cardiovascular P (2008) Guidelines for autopsy investigation of sudden cardiac death. *Virchows Archiv* 452(1):11–18
- Brinkmann B (1999) Harmonisation of medico-legal autopsy rules. *Int J Legal Med* 113(1):1–14
- Grabherr S, Djonov V, Friess A, Thali MJ, Ranner G, Vock P, Dirnhofer R (2006) Postmortem angiography after vascular perfusion with diesel oil and a lipophilic contrast agent. *Am J Roentgenol* 187(5):W515–W523. doi:[10.2214/ajr.05.1394](https://doi.org/10.2214/ajr.05.1394)
- Glagov S, Weisenberg E, Zarins CK, Stankunavicius R, Kolettis GJ (1987) Compensatory enlargement of human atherosclerotic coronary arteries. *N Engl J Med* 316(22):1371–1375
- Basso C, Rizzo S, Thiene G (2010) The metamorphosis of myocardial infarction following coronary recanalization. *Cardiovasc Pathol* 19(1):22–28
- Davies MJ (2000) The pathophysiology of acute coronary syndromes. *Heart* 83(3):361–366. doi:[10.1136/heart.83.3.361](https://doi.org/10.1136/heart.83.3.361)
- Virmani R, Burke AP, Kolodgie FD, Farb A (2002) Vulnerable plaque: the pathology of unstable coronary lesions. *J Interv Cardiol* 15(6):439–446
- Fineschi V, Baroldi G, Silver MD (2006) *Pathology of the heart and sudden death in forensic medicine*. Taylor & Francis, London, New York
- Campobasso CPPMD, Dell'Erba ASPMD, Addante APMD, Zotti FP, Marzullo AMD, Colonna MFMD (2008) Sudden Cardiac death and myocardial ischemia indicators: a comparative study of four immunohistochemical markers. *Am J Forensic Med Pathol* 29(2):154–161

26. Sheppard M, Davies MJ (2011) Practical cardiovascular pathology. Oxford University Press, London
27. Oudkerk M, Stillman A, Halliburton S, Kalender W, Möhlenkamp S, McCollough C, Vliegenthart R, Shaw L, Stanford W, Taylor A, van Ooijen P, Wexler L, Raggi P (2008) Coronary artery calcium screening: current status and recommendations from the European Society of Cardiac Radiology and North American Society for Cardiovascular Imaging. *Int J Cardiovasc Imaging* (former Cardiac Imaging) 24(6):645–671. doi:[10.1007/s10554-008-9319-z](https://doi.org/10.1007/s10554-008-9319-z)
28. Sanz J, Moreno PR, Fuster V (2010) The year in atherothrombosis. *J Am Coll Cardiol* 55(14):1487–1498
29. Petretta M, Daniele S, Acampa W, Imbriaco M, Pellegrino T, Messalli G, Xhoxhi E, Del Prete G, Nappi C, Accardo D, Angeloni F, Bonaduce D, Cuocolo A (2011) Prognostic value of coronary artery calcium score and coronary CT angiography in patients with intermediate risk of coronary artery disease. *Int J Cardiovasc Imaging* (former Cardiac Imaging) 1–10. doi:[10.1007/s10554-011-9948-5](https://doi.org/10.1007/s10554-011-9948-5)
30. Kwon SW, Kim YJ, Shim J, Sung JM, Han ME, Kang DW, Kim J-Y, Choi BW, Chang H-J (2011) Coronary artery calcium scoring does not add prognostic value to standard 64-section CT angiography protocol in low-risk patients suspected of having coronary artery disease. *Radiology* 259(1):92–99. doi:[10.1148/radiol.10100886](https://doi.org/10.1148/radiol.10100886)
31. Kristensen TS, Kofoed KF, Kühl JT, Nielsen WB, Nielsen MB, Kelbæk H (2011) Prognostic implications of nonobstructive coronary plaques in patients with non-st-segment elevation myocardial infarction: a multidetector computed tomography study. *J Am Coll Cardiol* 58(5):502–509. doi:[10.1016/j.jacc.2011.01.058](https://doi.org/10.1016/j.jacc.2011.01.058)
32. Moreno PR (2010) Vulnerable plaque: definition, diagnosis, and treatment. *Cardiol Clin* 28(1):1–30
33. Sanz J, Moreno PR, Fuster V (2010) The year in atherothrombosis. *J Am Coll Cardiol* 55(14):1487–1498
34. Cademartiri F, Runza G, Palumbo A, Maffei E, Martini C, McFadden E, Somers P, Knaapen M, Verheye S, Weustink AC, Mollet NR, de Feyter PJ, Hamers R, Bruining N (2010) Lumen enhancement influences absolute noncalcific plaque density on multislice computed tomography coronary angiography: ex vivo validation and in vivo demonstration. *J Cardiovasc Med* 11(5):337–344. doi:[10.2459/JCM.2450b2013e3283312400](https://doi.org/10.2459/JCM.2450b2013e3283312400)
35. Zamorano J-L, Bax J, Rademakers F, Knuuti J (eds) (2010) The ESC textbook of cardiovascular imaging. Springer, Dordrecht, Heidelberg, London, New York. doi:[10.1007/978-1-84882-421-8](https://doi.org/10.1007/978-1-84882-421-8)
36. Meijboom WB, Van Mieghem CAG, van Pelt N, Weustink A, Pugliese F, Mollet NR, Boersma E, Regar E, van Geuns RJ, de Jaegere PJ, Serruys PW, Krestin GP, de Feyter PJ (2008) Comprehensive assessment of coronary artery stenoses: computed tomography coronary angiography versus conventional coronary angiography and correlation with fractional flow reserve in patients with stable angina. *J Am Coll Cardiol* 52(8):636–643. doi:[10.1016/j.jacc.2008.05.024](https://doi.org/10.1016/j.jacc.2008.05.024)
37. Ruder TD, Bauer-Kreutz R, Ampanozi G, Roskopf AB, Pilgrim TM, Weber OM, Thali MJ, Hatch GM Assessment of coronary artery disease by post-mortem cardiac MR. *Eur J Radiol*. doi:[10.1016/j.ejrad.2011.06.042](https://doi.org/10.1016/j.ejrad.2011.06.042)
38. Jackowski C, Hofmann K, Schwendener N, Schweitzer W, Keller-Sutter M Coronary thrombus and peracute myocardial infarction visualized by unenhanced postmortem MRI prior to autopsy. *Forensic Sci Int*. doi:[10.1016/j.forsciint.2011.07.010](https://doi.org/10.1016/j.forsciint.2011.07.010)
39. Oliva A, Brugada R, D'Aloja E, Boschi I, Partemi S, Brugada J, Pascali VL (2011) State of the art in forensic investigation of sudden cardiac death. *Am J Forensic Med Pathol* 32(1):1–16. doi:[10.1097/PAF.1090b1013e3181c1092dc1096](https://doi.org/10.1097/PAF.1090b1013e3181c1092dc1096)
40. Sheppard M, Davies MJ (1998) Practical cardiovascular pathology. Arnold, London, Sydney, Auckland
41. Soilleux EJ, Burke MM (2009) Pathology and investigation of potentially hereditary sudden cardiac death syndromes in structurally normal hearts. *Diagn Histopathol* 15(1):1–26. doi:[10.1016/j.mpdhp.2008.11.005](https://doi.org/10.1016/j.mpdhp.2008.11.005)