

Aesth Plast Surg (2012) 36:660–665  
DOI 10.1007/s00266-011-9853-2

CASE REPORT

CRANIOFACIAL/MAXILLOFACIAL

# Maxillofacial Reconstruction Using Polyetheretherketone Patient-Specific Implants by “Mirroring” Computational Planning

Paolo Scolozzi



Received: 28 August 2011 / Accepted: 13 November 2011 / Published online: 19 January 2012  
© Springer Science+Business Media, LLC and International Society of Aesthetic Plastic Surgery 2012

**Abstract** In the vast majority of cases, precise symmetric reconstruction of maxillofacial defects remains an unsolved problem for craniofacial surgeons. Computer-designed alloplastic implants have contributed considerably to improvement in the accuracy and reliability of facial rehabilitation, rapidly becoming an irreplaceable part of the surgical armamentarium. In recent years, the subsequently developed new generation of computational technologies has allowed planning to be done by preoperative “mirroring” using the healthy side as a template to fabricate an ideal prosthesis for reestablishment of facial symmetry. Two cases of facial defects are reported, one of the midface and another of the lower face reconstructed using a computer-designed polyetheretherketone (PEEK) patient-specific implant (PSI) technique based on “mirroring” computational planning.

**Level of Evidence V** This journal requires that authors assign a level of evidence to each article. For a full description of these Evidence-Based Medicine ratings, please refer to the Table of Contents or the online Instructions to Authors at [www.springer.com/00266](http://www.springer.com/00266).

**Keywords** Alloplastic implants · Computer-assisted surgery · Computer-designed implants · PEEK

Anatomic and cosmetic restoration for primary or secondary deformities of the craniomaxillofacial skeleton still

represents by far the most challenging issue in the vast majority of cases. Although several materials such as autografts, allografts, xenograft, and metallic or nonmetallic material alloplastic bone substitutes have been reported for use in reconstruction of such deformities with varying degrees of success in the past 20 years, the ideal solution has not been discovered to date [1–9].

Detailed spatial visualization, surgical planning for correction of maxillofacial defects, and ability to calculate bone volume have been dramatically improved since the 1980s as three-dimensional (3D) computed tomography (CT) scanning techniques have progressed and become more efficient. The recent introduction of individually preformed alloplastic implants allows anatomic 3D shaping, as opposed to conventional implants, which require major intraoperative manipulations [2, 5, 7, 8].

The use of non-custom-made implants often is associated with a less accurate and predictable outcome as well as a longer time required for the operation [4–9]. Moreover, computer-aided design and modeling (CAD/CAM) software also has dramatically contributed to a major improvement in the strategy for bone reconstructive surgery, especially with respect to the prediction of preoperative virtual and ideal bone repositioning for correction of malformations [2, 7, 8].

Currently, efforts are directed toward the development of highly sophisticated CT and computer graphics hardware and image-processing software capable of reproducing, as accurately as possible, computational anatomic templates to facilitate the preoperative 3D bone positioning required for obtaining patient-specific implants (PSI) [7, 8]. Thus, the recent introduction of new software allowing automatic preoperative “mirroring” of the healthy side to the affected side has represented a fundamental step toward the reestablishment of facial symmetry [10–12].

---

P. Scolozzi (✉)  
Division of Maxillofacial and Oral Surgery, Department  
of Surgery, University Hospital and Faculty of Medicine,  
1211 Genève, Switzerland  
e-mail: [paolo.scolozzi@hcuge.ch](mailto:paolo.scolozzi@hcuge.ch)

We report two cases of maxillofacial reconstruction using a computer-designed polyetheretherketone (PEEK)-PSI based on “mirroring” computational planning.

## Patient Reports

### Patient 1

In September 2000, a 29-year-old woman had a bike accident in France. She experienced a comminuted right orbitozygomatic fracture, which was treated by an immediate open reduction and internal rigid fixation with titanium miniplates in a local hospital. Her postoperative course was followed by the progressive development of a right enophthalmos without diplopia as well as a flattening of the malar eminence.

After 1 year, the woman underwent a new surgical procedure to reconstruct the orbital floor using a coral implant. She presented at the Oral and Maxillo-Facial Department of the Hôpitaux Universitaire in Geneva (Switzerland) in January 2009 with an unaesthetic facial asymmetry. Physical examination showed a complex bone contour defect over the right malar eminence centered by a depressed cutaneous star-shaped scar, a lack of projection of the inferior orbital rim, and a discrete enophthalmos (Fig. 1a–d). The ophthalmologic examination was otherwise normal. The 3D CT scan confirmed the extension of the defect.

In September 2009, a computer-designed PEEK-PSI was used to reconstruct the midface bone defect according to the following technical procedure.

### Image Acquisition

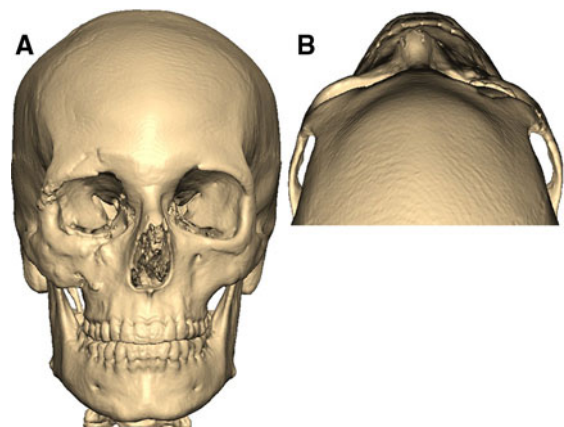
A preoperative 3D CT scan with the following parameters was first obtained from axial images : matrix of  $512 \times 512$

pixels, slice thickness of 1 mm, seed per rotation of 1 mm, reconstructed slice increment of 1 mm, reconstruction algorithm bone or high resolution, and gantry tilt of  $0^\circ$  (Fig. 2a, b).

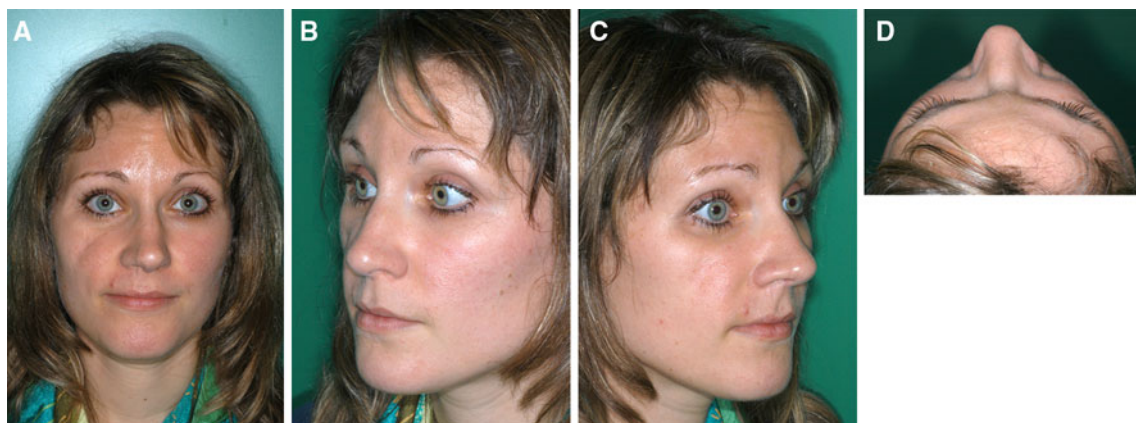### Preoperative Computational Image Analysis and Implant Design

The Digital Imaging and Communications in Medicine (DICOM) data were processed using FreeForm Modeling software (SensAble Technologies, Inc., Wilmington, MA 01887, USA; [www.sensable.com](http://www.sensable.com)) by Synthes (Oberdorf, Switzerland).

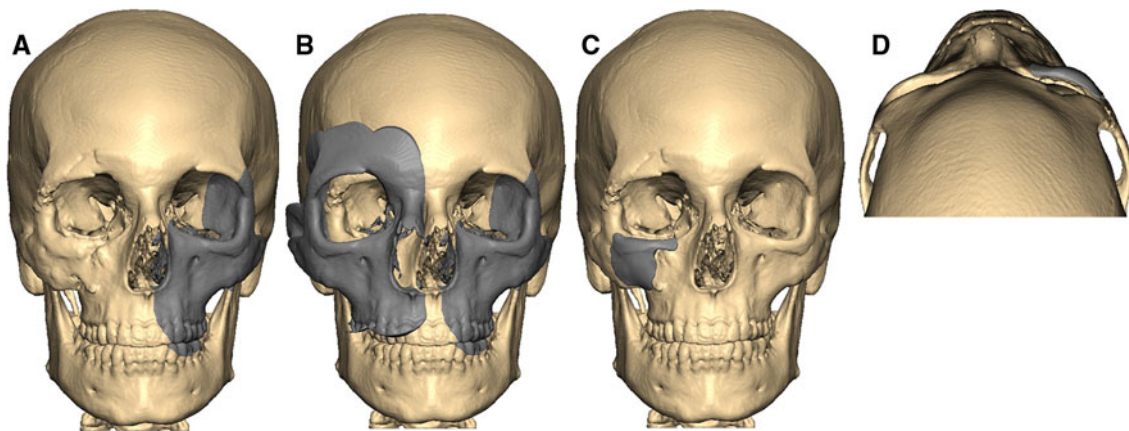
A semiautomatic segmentation of the volumetric region of interest was performed on 3D images windowed into bone-specific Hounsfield units using a specific cursor, thus procuring a 3D template of the healthy side (Fig. 3a). The newly generated template was mirrored and superimposed on the affected side in 3D into the original CT scans



**Fig. 2** Preoperative radiologic documentation. **a** Face and **b** axial three-dimensional computed tomography (CT) scan showing the bony right orbitozygomatic defect



**Fig. 1** Preoperative photographic documentation. **a** Frontal, **b** left oblique, **c** right oblique, and **d** axial views showing a right malar flattening centered by a depressed cutaneous star-shaped scar as well as a discrete enophthalmos



**Fig. 3** Preoperative planning. **a** Semiautomatic segmentation of the volumetric region of interest performed on three-dimensional (3D) images. **b** Digital template on the noninjured side (*gray*) superimposed on the affected side in 3D into the original computed

tomography (CT) scans. **c** Face and **d** axial view of the final computational template resulting in an ideal and symmetric positioning of the bones

(Fig. 3b). The template then was adapted to fit the bony defect as precisely as possible to obtain an ideal and symmetric positioning (Fig. 3c, d).

After the surgeon's approval of the implant design based on the images, data were used to create an anatomically correct skull model and an implant using a rapid prototyping machine (Zcorp Z310). Skull and implant models were sent to the surgeon for review, markup, and/or approval. The resulting skull model as well as the implant had an accuracy to within 0.5 mm. The definitive non-sterile PEEK-PSI12 was thus sent by the manufacturer to the surgeon and sterilized by autoclave before its use in our hospital. Skull and implant models were sent to the surgeon for review, final approval, or both before the definitive manufacturing.

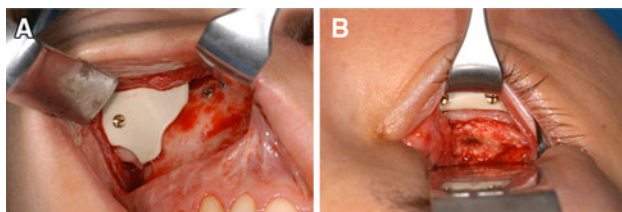
The implant was inserted by a combined right transconjunctival and intraoral approach and perfectly matched the dimensions of the residual bone defect without the need for any further modifications. It was fixed using two AO 1.3 titanium-plate lag screws (Synthes-CH 4436; Oberdorf, Switzerland) (Fig. 4a, b). A follow-up assessment at 2 years showed a stable cosmetic and dimensional reconstruction free of infection and the persistence of a residual

punctiform right malar depression related to the previous retractile cutaneous scar (Figs. 5a–d, 6)

#### Patient 2

A 29-year-old woman had undergone bimaxillary osteotomies and a sliding genioplasty for correction of long-face syndrome in March 2006 at our hospital. At the 1-year follow-up assessment, the patient reported a residual contour defect of the left mandibular body and angle (Fig. 1a, b). The 3D CT scan confirmed the extension of the defect (Fig. 7a, b).

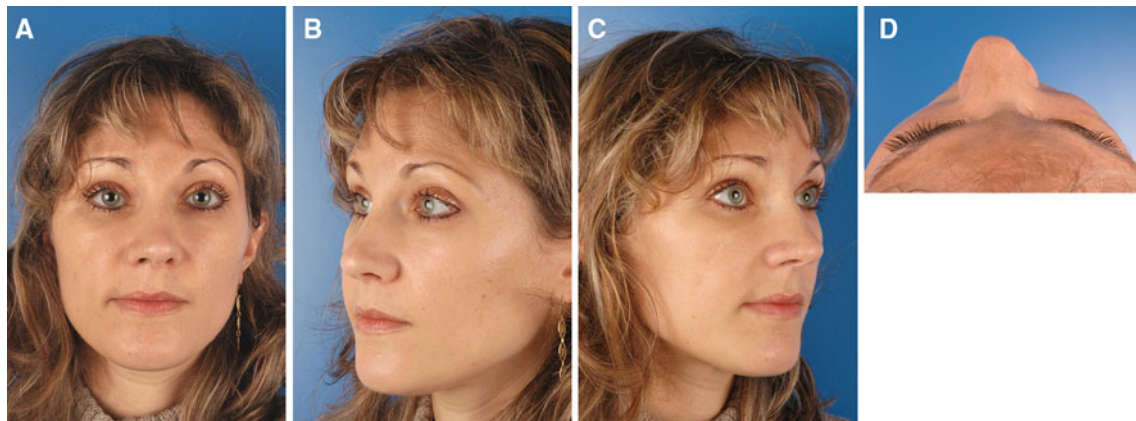In February 2009, a computer-designed PEEK-PSI according to the previously described technical procedure was used to reconstruct the mandibular defect (Fig. 8a, b). The implant was inserted by an intraoral approach and perfectly matched the dimensions of the residual bone defect without the need for any further modifications. It was fixed using two AO 1.3 titanium-plate lag screws (Synthes-CH 4436) (Fig. 9a). A follow-up assessment at 2 years showed a stable cosmetic and dimensional reconstruction free of infection (Fig. 10a, b).



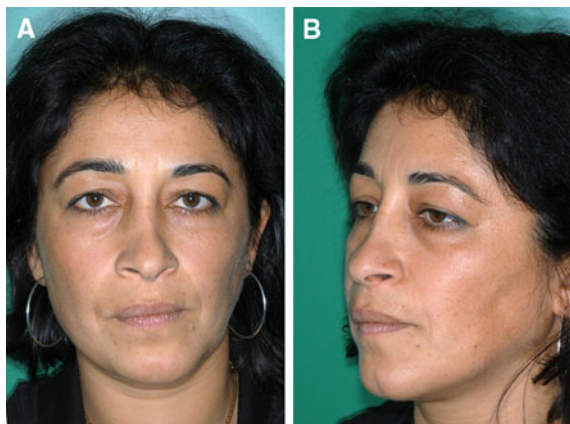**Fig. 4** Intraoperative view showing **a** the patient-specific implant (PSI) perfectly matching the residual defect of the right malar defect by the intraoral approach and **b** the right inferior orbital rim by the transconjunctival approach

#### Discussion

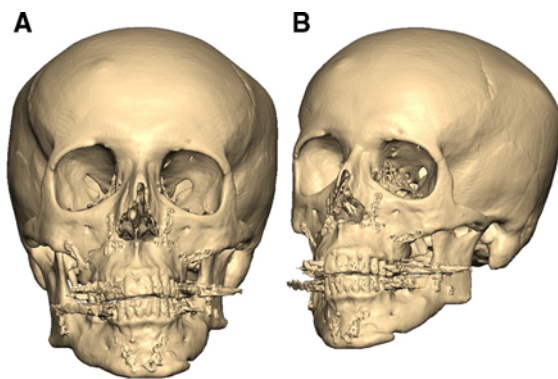
Reestablishment of predeformity, normal, 3D (horizontal, vertical, and transverse) bone contouring is the fundamental prerequisite for complete facial cosmetic and functional recovery and integrity. Although autogenous bone still is considered the gold standard by many craniofacial surgeons, the literature abounds with reports describing the use of many bone substitutes and different reconstructive techniques [1]. The advantages and disadvantages of every reported material have been well



**Fig. 5** Documentation 12 months after surgery. **a** Frontal, **b** left oblique, **c** right oblique, and **d** axial views showing the reestablishment of a satisfactory facial symmetry

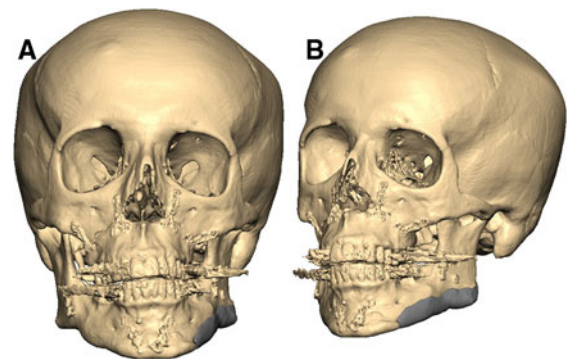


**Fig. 6** Preoperative documentation. **a** Frontal and **b** left oblique views showing a residual contour defect of the left mandibular body and angle

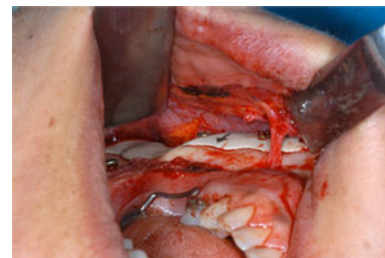

**Fig. 7** Preoperative radiologic documentation. **a** Face and **b** left oblique three-dimensional computed tomography (CT) scan showing the mandibular bony defect

documented in the literature, but the optimal and consensual material for reconstruction of the craniomaxillofacial skeleton still remains controversial and a source of debate [3–6, 9].

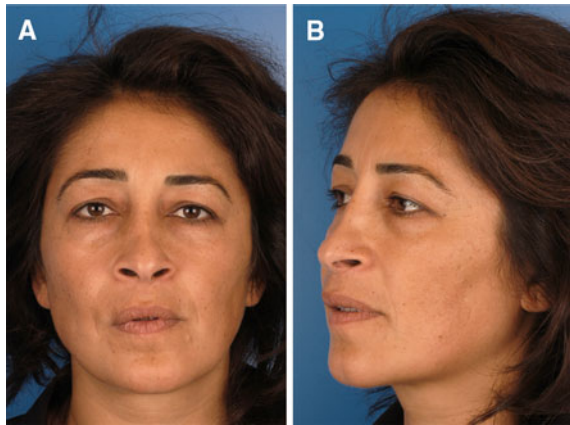

**Fig. 8** Preoperative planning. **a** Face and **b** left oblique view of the final computational template resulting in an ideal and symmetric positioning of the bones



**Fig. 9** Intraoperative documentation showing **a** the patient-specific implant (PSI) perfectly matching the residual defect of the left mandibular body and angle by the intraoral approach

The use of alloplastic implants definitely eliminates the main concern associated with the use of autogenous bone grafts, which is the unpredictable degree of bone resorption [1–9]. Bone graft resorption often is the reason a second surgery is needed [1]. However, the drawback of such implants is related to the potential for postoperative infection.



**Fig. 10** Documentation 12 months after surgery. **a** Frontal and **b** left oblique views showing a satisfactory cosmetic and dimensional reconstruction

Preformed and non-custom-made implants, most of which are porous polyethylene and silicone rubber, still represent the most commonly used facial implants [3–6, 9]. The success with this approach is highly dependent on both the surgeon's capacity and ability to visualize the geometry of the bony defect spatially and to tailor implants so they fit the defect as precisely as possible and the design of the implants.

Computer-designed alloplastic implants have drastically changed the global attitude regarding facial reconstructions and have become a reliable and irreplaceable part of the surgical armamentarium [2, 7, 8]. Given its excellent mechanical and chemical properties, PEEK has rapidly become a solid alternative to the other alloplastic materials for the reconstruction of bone defects in the craniomaxillofacial skeleton [7, 8, 13–15].

Polyetheretherketone is a semicrystalline thermoplastic polymer characterized by excellent mechanical and chemical properties, as well as by biologic safety, which makes this material a reliable alternative to the other alloplastic bone substitutes. Polyetheretherketone polymers were first used in spine surgery (interbody fusion cage implants) and in orthopedic surgery (hip implants) [13–15]. A great advantage with this material is that it can be coupled with CAD/CAM techniques, thus allowing the manufacture of custom-made implants, which can be exactly tailored according to the individual's anatomy [2, 7, 8]. Moreover, this procedure dramatically minimizes the need for major intraoperative manipulations, which often are necessary to fit the non-custom-made implants adequately, thus reducing the operative time.

In 2007, we first reported the use of a custom-made PEEK implant for the reconstruction of a large complex orbitofrontotemporal defect [7]. Since then, computer-designed PEEK implants have progressively gained in popularity, rapidly becoming a standard in calvarial

reconstructive surgery [2, 8]. Nevertheless, the technical difficulty in precisely reproducing the tortuous 3D anatomy of the facial skeleton has made the use of such implants for correcting facial problems more problematic. However, this procedure is particularly attractive for unilateral secondary posttraumatic or congenital maxillofacial deformities. In fact, in these cases, the healthy side can be used as a template and computationally superimposed on the affected side using specific "mirroring" software [10–12]. This allows for the creation of a PSI that has the potential for precise restoration of facial symmetry. To date, Kim et al. [8] have been the only authors to report on maxillofacial reconstruction (4 patients) using a computer-designed PEEK-PSI with excellent postoperative aesthetic and functional results and no complications such as infections or extrusions.

The classical reported postoperative complications related to the most commonly used alloplastic implants (i.e., expanded polytetrafluoroethylene, porous polyethylene, methyl methacrylate, and silicone rubber) are extrusion or displacement, infection, swelling, and foreign body reaction [2–4, 9]. None of these complications have been observed in our experience or reported in the literature with regard to the use of PEEK implants.

The follow-up period of this study was too short to allow definitive conclusions, so long-term studies are necessary. To date, the only patient who has been followed for more than 5 years (6 years) has never presented any complication, and the PEEK implant still is in place with a stable cosmetic result.

Without a doubt, the main and probably unique drawback to the reported approach is financial, with costs that can range from approximately 2,000 euros for prostheses such as those presented in this study to 6,000 euros for the prostheses required in extensive calvarial reconstruction.

In conclusion, although the use of computer-designed PEEK-PSI in the rehabilitation of the maxillofacial area remains restricted for the moment, the first encouraging results suggest that this technique could be an advantageous and promising alternative to the use of other alloplastic materials. Moreover, this technique has the potential not only to achieve predictable correction for congenital or acquired deformities but also to serve a merely cosmetic purpose.

## References

1. Tessier P (1982) Autogenous bone grafts taken from the calvarium for facial and cranial applications. *Clin Plast Surg* 9:531–538
2. Binder WJ (2008) Custom-designed facial implants. *Facial Plast Surg Clin North Am* 16:133–146
3. Binder WJ, Azizzadeh B (2008) Malar and submalar augmentation. *Facial Plast Surg Clin North Am* 16:11–32

4. Quatela VC, Chow J (2008) Synthetic facial implants. *Facial Plast Surg Clin North Am* 16:1–10
5. Terino EO, Edwards MC (2008) Customizing jawlines: the art of alloplastic premandible contouring. *Facial Plast Surg Clin North Am* 16:99–122
6. Terino EO, Edwards MC (2008) Alloplastic contouring for sub-orbital, maxillary, zygomatic deficiencies. *Facial Plast Surg Clin North Am* 16:33–67
7. Scolozzi P, Martinez A, Jaques B (2007) Complex orbitofronto-temporal reconstruction using computer-designed PEEK implant. *J Craniofac Surg* 18:224–228
8. Kim MM, Boahene KD, Byrne PJ (2009) Use of customized polyetheretherketone (PEEK) implants in the reconstruction of complex maxillofacial defects. *Arch Facial Plast Surg* 11:53–57
9. Niamtu J III (2010) Essentials of cheek and midface implants. *J Oral Maxillofac Surg* 68:1420–1429
10. Westendorff C, Gulicher D, Dammann F, Reinert S, Hoffmann J (2006) Computer-assisted surgical treatment of orbitozygomatic fractures. *J Craniofac Surg* 17:837–842
11. Fuller SC, Strong EB (2007) Computer applications in facial plastic and reconstructive surgery. *Curr Opin Otolaryngol Head Neck Surg* 15:233–237
12. Scolozzi P, Terzic A (2010) “Mirroring” computational planning, Navigation Guidance System, and intraoperative mobile C-arm cone-beam computed tomography with flat-panel detector: a new rationale in primary and secondary treatment of midfacial fractures? *J Oral Maxillofac Surg* 69:1697–1707
13. PEEK-OPTIMA (2004) Polymer processing guide. Invibio Ltd., Thornton-Cleveleys, UK, pp 1–14
14. William DF, McNamara A (1987) Potential of polyetheretherketone (PEEK) and carbon-fibre-reinforced PEEK in medical application. *J Mater Science Lett* 6:188–190
15. Schlegel J, Green S (2002) Polyetheretherketones (PEEK): a biocompatible high-performance plastic. *Med Plast* 14:1–10