

## Unilateral widening of the inferior alveolar nerve canal: a rare anatomic variant mimicking disease

Andrej Terzic · Minerva Becker · Benoît Imholz · Paolo Scolozzi

Received: 11 July 2012 / Accepted: 24 September 2012 / Published online: 30 December 2012  
© Japanese Society for Oral and Maxillofacial Radiology and Springer Japan 2012

**Abstract** We report a case of an asymptomatic healthy 49-year-old male patient with an incidental finding of enlargement of the right inferior alveolar nerve (IAN) canal (9 vs. 4 mm). After 2 years, follow-up magnetic resonance imaging (MRI) revealed no change in the findings. In addition, MR-based diffusion tensor imaging with tractography of the right and left mandibular nerves showed that the difference in size between the right and left nerves was caused by an increased number of nerve fibers in the right IAN. During the entire follow-up period of 4 years, the patient remained symptom-free. Therefore, we suggest that the enlargement in our patient was a pure anatomic variant. However, a multitude of conditions are known to produce the identical radiological appearance in conventional radiology, including benign and malignant tumors, vascular malformations, and inflammatory disorders. We describe these pathologies in more detail as well as the possibilities for examinations with different MRI sequences.

**Keywords** Widening · Enlargement · Idiopathic · Inferior alveolar nerve · Tractography

### Introduction

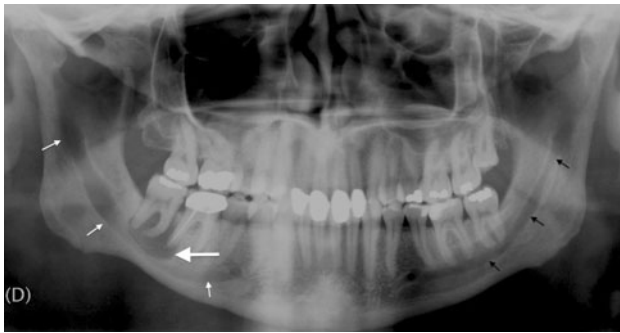Even though there are more modern radiological examinations, panoramic radiographs are still the primary source of information in the daily routine of many dental and maxillofacial practices. These radiographs are readily available and require a lower radiation dose than cone-beam computed tomography (CBCT) and medical computed tomography (CT). Owing to their broad coverage of the maxillofacial skeleton, incidental findings are not rare. In this report, we discuss such an incidental finding, together with its origin and differential diagnoses.

### Case report

An otherwise healthy 49-year-old patient presented with a 4-month history of pain in tooth 47. On clinical examination, the tooth was painful on percussion and had a negative vitality test. Vitality testing was also negative for tooth 46, which had undergone root canal treatment 2 years previously. Apart from slight tenderness of the muscles for mastication, all other clinical findings and inflammatory laboratory parameters (C-reactive protein, full blood count) were normal. The patient had no history of previous surgery, tumor, or trauma. A panoramic X-ray revealed a periapical radiolucent lesion involving both roots of tooth 47 and the distal root of tooth 46 (Fig. 1), suggesting the diagnosis of a radicular cyst. Widening of the entire bony canal of the right inferior alveolar nerve (IAN) was also present (Fig. 1). To further clarify these radiological findings, magnetic resonance imaging (MRI) was performed (Fig. 2a–c). The MRI showed a radicular cyst involving the roots of teeth 46 and 47, and the diagnosis was later confirmed by a pathological analysis. The right IAN canal had

A. Terzic (✉) · B. Imholz · P. Scolozzi  
Service of Maxillo-Facial and Oral Surgery,  
Department of Surgery, University of Geneva Hospitals,  
Rue Gabrielle-Perret-Gentil 4, 1211 Geneva 14, Switzerland  
e-mail: andrej.terzic@hcuge.ch

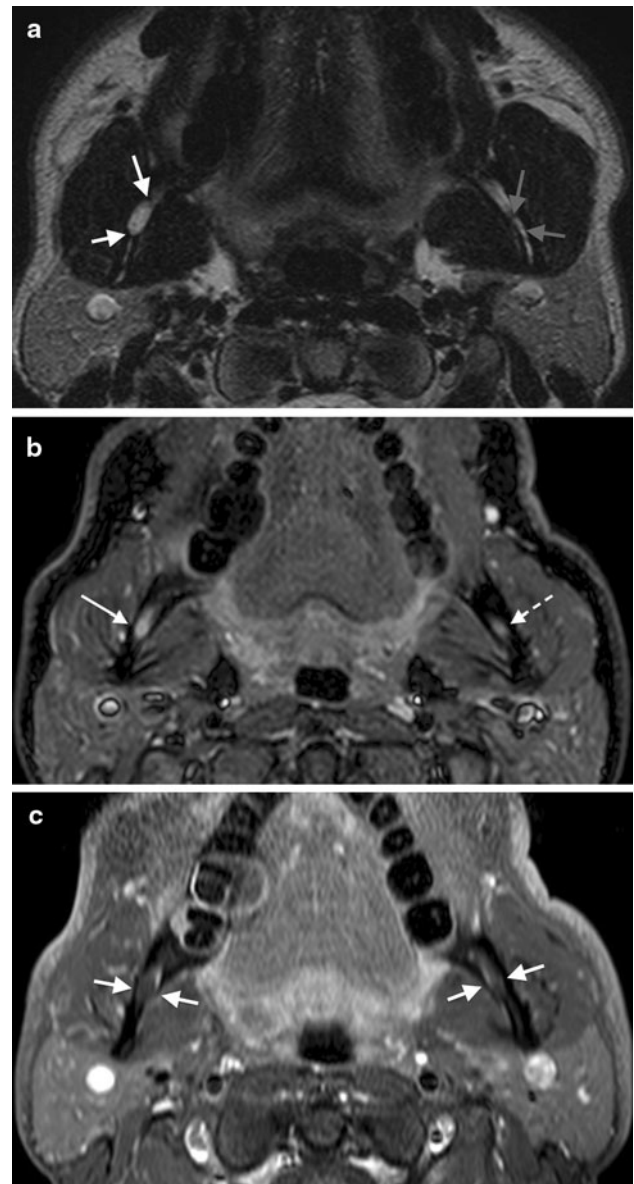
M. Becker  
Head and Neck and Maxillofacial Radiology,  
Department of Radiology, University of Geneva Hospitals,  
Rue Gabrielle-Perret-Gentil 4, 1211 Geneva 14, Switzerland



**Fig. 1** Panoramic X-ray showing a radiolucent lesion (*large arrow*) involving both roots of tooth 47 and the distal root of tooth 46, suggesting a radicular cyst. The entire osseous canal of the right IAN is widened (*thin white arrows*). For comparison, note the normal left IAN canal (*thin black arrows*)

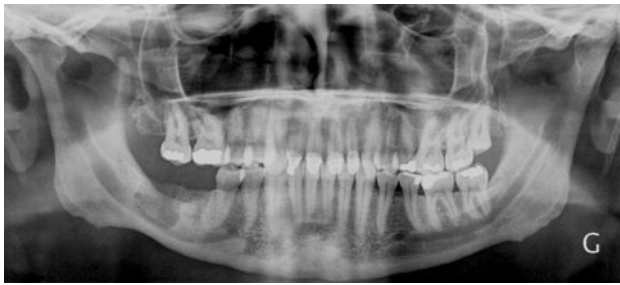a maximum vertical width of 9 mm, whereas the corresponding width of the canal on the contralateral side was only 4 mm. Measurements were performed on sagittal oblique CT reformations and sagittal oblique T1-weighted MR images through the inferior alveolar canal. They were obtained and recorded at multiple levels bilaterally using OsiriX version 4.0 software (64-bit extension; Pixmeo, Geneva, Switzerland). The maximum width was extracted from all available data (20 measurements on each side). On inversion recovery (IR) sequences, the enlarged right IAN signal was slightly hyperintense. After injection of gadolinium, a central non-enhanced nerve surrounded by an enhanced perineural vascular plexus was seen on the right side (Fig. 2a–c). This enhancement pattern was similar to that of the contralateral IAN. The slightly increased signal on the IR sequence in the presence of the absolutely normal nerve enhancement pattern was interpreted to suggest minor edema of the enlarged nerve.

Shortly thereafter, the radicular cyst was completely removed under general anesthesia, and no connection of the lesion with the IAN was observed intraoperatively. On the basis of a prior discussion with the patient, a biopsy of the enlarged IAN was not performed to avoid sensory dysfunction of the otherwise fully functioning IAN. Radiological and clinical controls were planned instead. The first radiological control took place 4 months later. A panoramic X-ray showed no changes in the bony anatomy of the IAN (Fig. 3). After 2 years, follow-up MRI revealed unchanged findings regarding the bony canal and the enlarged IAN. In addition, MR-based diffusion tensor imaging (DTI) with tractography of the right and left mandibular nerves was performed, and clearly revealed that the difference in size between the right and left IANs was caused by an increased number of nerve fibers in the right IAN compared with the left IAN (Fig. 4). Measurements of the fractional anisotropy (FA) and apparent diffusion coefficient (ADC) values of both mandibular nerves

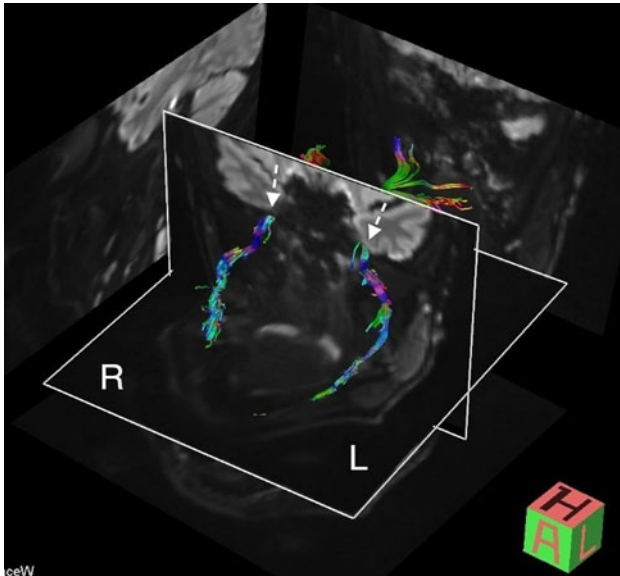


**Fig. 2** High-resolution MRI obtained prior to surgery. **a** Axial 3-mm T2-weighted MRI sequence showing a larger IAN on the right side (*white arrows*) than on the left side (*gray arrows*). **b** Axial 3-mm short time of inversion recovery STIR image showing a high signal for the right IAN fibers, suggesting the presence of edema (*arrow*). The signal for the left IAN is normal (*dashed arrow*). **c** Axial fat-saturated 3-mm T1-weighted image after injection of gadolinium showing a normal enhancement pattern of both IANs (*white arrows*). Note that both nerves show no enhancement, but a thin enhanced rim is seen bilaterally. This rim is caused by the normal vascular plexus surrounding the nerves

at the level of the foramen ovale and below, as well as of the IANs, showed no differences between the right and left sides, thereby strongly suggesting a normal anatomic variant. The patient was symptom-free at that time, and continued to be symptom-free during a follow-up period of 4 years after the initial surgery.



**Fig. 3** Panoramic X-ray showing no change in the appearance of the right IAN canal



**Fig. 4** Follow-up MRI performed after 2 years. 3D tractography from a Stejskal–Tanner DTI sequence shows the mandibular nerves. The *dashed arrows* point at the right and left foramen ovale. Note that the right IAN appears thicker than the left IAN because of an increased number of fibers. The right and left mean ADC values were  $1.59 \times 10^{-3}$  and  $1.61 \times 10^{-3}$  mm<sup>2</sup>/s, respectively, and the corresponding mean FA values were 0.45 and 0.46, suggesting no microstructural abnormality

## Discussion

The etiology of the IAN enlargement in our patient is most probably a rare anatomical variant. To the best of our knowledge, unilateral major enlargement of the IAN as an anatomical variant has not been reported to date, in either cadaver dissection or radiological imaging studies [1–3]. In our patient, both panoramic X-rays and MR images showed neither changes nor progression during 4 years of follow-up and no symptoms developed after the cyst enucleation. Our patient displayed a normal appearance of the IAN on high-resolution contrast-enhanced T1-weighted sequences, including lack of enhancement of the avascular nerve itself and enhancement of the surrounding perivascular plexus, as reported by several authors [4–6]. In addition, DTI with

**Table 1** Etiology of widening of the IAN canal

Neoplasia	Lymphatic tissue	Non-Hodgkin lymphoma	
	Muscular	Leiomyoma	
	Neurogenic		Solitary neurofibroma
			Neurofibromatosis
			Schwannoma
			Malignant peripheral nerve sheath tumor
	Endocrine	Acromegaly	
		Multiple endocrine neoplasias	
	Bone	Osteosarcoma	
	Mucosal	Direct invasion by squamous cell carcinoma	
Malformation	Vascular	Arteriovenous malformation	
	Neurogenic	Localized hypertrophic neuropathy	
	Syndromatic	Proteus syndrome	
Inflammation		Atypical lymphocytic infiltration	
Idiopathic/variant		Our case report	

tractography of the IAN and measurements of the FA and ADC values clearly showed that there was no structural abnormality within the nerve. The enlarged IAN size was found to be caused by an increased number of otherwise normal nerve fibers. DTI with tractography (3D fiber tracking) is a new non-invasive MR technique used to depict the neuronal tract structure and the orientation of axons within white matter tracts, cranial nerves, peripheral nerves, and the brachial or lumbar plexus, allowing quantification of the tissue characteristics beyond normal anatomical resolution [7–9]. DTI is currently the only method that can give an indirect view of the microstructure and fiber trajectory of nerve tissues. The mean FA and ADC values are thought to reflect microstructural changes. On “purely anatomic” MR images, even if high-resolution sequences and intravenous contrast are applied [7–9], these changes may be missed and structures can appear normal. In our case, the measured ADC and FA values did not differ between the left and right sides and were within the normal ranges, further supporting the diagnosis of a normal IAN variant.

Even though we suggest that the enlargement of the IAN canal in our patient was a mere anatomic variant, a multitude of conditions are known to cause this radiological appearance, including benign and malignant tumors, vascular malformations, and inflammatory disorders. Table 1 summarizes the possible etiologies of IAN enlargement. We will now describe these pathologies in more detail.

Benign peripheral nerve sheath tumors include neurofibromas and schwannomas. Neurofibromas occur as either a solitary lesion or multiple lesions, which are the hallmark

of neurofibromatosis type I [10]. In neurofibromatosis type I, the mandible exhibits increased bone density, ramus concavity, increased size of the coronoid notch, enlarged mental foramen, and less commonly tubular widening of the IAN canal [11, 12]. In contrast, solitary IAN neurofibromas [10] typically manifest as localized radiolucent unilocular or multilocular expansive lesions of the bony IAN canal. They may be well circumscribed or scantily delineated, and are classically seen in women around 25 years of age. Solitary neurofibromas have a predilection for the posterior mandible [10, 13]. Patients are symptom-free in the early stages, but pain and dysesthesia eventually appear after further growth and compression [13].

Schwannoma, a benign neoplasm composed of differentiated neoplastic Schwann cells [14, 15], has had various names in the past including neurinoma, neurilem(m)oma, perineural fibroblastoma, or benign peripheral nerve sheath tumor [14, 15]. The characteristic radiological presentation is a well-circumscribed unilocular radiolucency with sclerotic margins with or without root resorption [15–17]. Around 10 % of all cases exhibit fusiform widening of the mandibular canal [15, 17, 18]. IAN schwannomas are usually incidental radiological findings [16, 17], corresponding to asymptomatic swelling of the mandible localized in the posterior body or the ascending ramus in 50 % of cases [15]. The mean age at onset is 34 years and there is a slight female predominance [15, 16]. Overall, however, these tumors are rare. A recent literature review of intraosseous schwannomas found only 46 documented cases [16].

Both neurofibromas and schwannomas of the IAN present characteristic imaging findings on MRI, which allow the correct diagnosis. These findings include rounded or fusiform enlargement of the IAN, homogeneous strong contrast enhancement of the nerve, or alternatively, diffuse nerve enhancement with non-enhanced focal areas corresponding histologically to mucoid degeneration, which is a common feature of schwannomas [5, 6]. On tractography, schwannomas and neurofibromas display an abnormal fiber architecture [7].

The malignant variants of neurofibroma and schwannoma (previously referred to as neurofibrosarcoma, malignant schwannoma, or neurogenic sarcoma) are currently classified as malignant peripheral nerve sheath tumors (MPNST) [14]. MPNST of the mandible are extremely rare and clinically of marginal importance. Only a few cases are known to date [19–21], some of them with localized or fusiform canal widening, or with a widened foramen mentale [20, 22, 23]. Perineural spreading to the intracranial portion of the trigeminal nerve is characteristic, as well as spreading to other trigeminal nerve branches and the skull base [5]. Areas of necrosis, hemorrhage, or diffuse brain stem invasion are typically seen in advanced cases. These features are best delineated with MRI.

Primary mandibular non-Hodgkin lymphoma has a reported incidence of 0.6 % among all malignant non-Hodgkin lymphomas [24]. The most common radiological finding in the mandible is a focal or diffuse osteolytic area, generally without edge sclerosis [25, 26]. Fusiform widening of the mandibular canal [27–29] or the mental foramen may also be observed [25]. In the head and neck, these lymphomas typically present around the age of 40–46 years [26, 30] with bony swelling, pain, and sensory disturbances. Mobility of teeth can be increased if the tumor is situated in a tooth-bearing region [24, 30]. Since the clinical findings mimic dental infection or osteomyelitis [26, 30], the diagnosis is often delayed [26, 31]. On MRI, large bulky masses are seen and ADC measurements typically show very low values [32].

The radiological presentation of osteosarcoma is inconsistent [33]. On a variety of different radiological examinations of 66 patients (CT and plain, panoramic, or occlusal X-rays), these tumors have more or less equally distributed radio-opaque, radiolucent, or mixed appearances with diffuse bony limits in 78 % of cases and periosteal reactions in 48 % of cases. Furthermore, 34 % of involved mandibles have structural changes of the alveolar canal [34] some of them presenting as widening [33, 35]. The triad of widening of the alveolar canal, widening of the periodontal space of teeth, and a sunray effect on plain or panoramic X-rays seems almost pathognomonic for mandibular osteosarcomas [33, 35]. In the majority of cases, the clinical presentation is a painful bony swelling situated posterior to the canine in the body of the mandible [33, 35–37], coupled with sensory disturbances in advanced stages [34, 36]. The estimated incidence is 0.07 in 100,000 [38], and the reported mean age at onset ranges from 34 to 40 years [33, 34, 37, 39]. This is noticeably later than for the rest of the skeleton [40].

There are other infrequent benign and malignant tumors known to produce widening of the alveolar canal. Owing to the pathological growth of the mandible in acromegaly, some 50 % of patients have alterations of the IAN in the form of (diffuse) widening or irregularities. The mental foramen can be enlarged as well [41]. Further sporadic observations are localized/circumscribed widening in the case of vascular leiomyoma [42] or an enlarged and bifurcated canal in multiple endocrine neoplasia IIb [43]. Perineural spreading of squamous cell carcinoma can also result in a widened canal or mental foramen [44].

Owing to the common canal for the inferior alveolar nerve and the inferior alveolar artery [45], alterations of the canal are also attributable to vascular lesions, representing either tumors or arteriovenous malformations. Radiologically, an arteriovenous malformation presents as a unilocular or multilocular cystic lesion with well-defined or undefined borders [46]. It can also result in a widened [47]

or bifid [48] IAN canal. These malformations are rare in the head and neck. Nevertheless, 5 % of cases are located in the mandible, half of them as primary intraosseous lesions [49]. Clinically, they present with swelling, pain, discoloration of the overlying mucosa or skin, increased spontaneous tooth mobility, and immediate massive bleeding after extraction of such teeth [50, 51]. MR angiography with dynamic sequences allows the correct diagnosis as well as pretherapeutic planning [5, 6]. In the case of tumor lesions, vascular leiomyoma [42] or vascular leiomyosarcoma [52] are possible, but only a handful of cases have been reported.

There are a few more rather anecdotal case reports describing widening of the IAN canal. In these reports, atypical lymphocytic infiltration of the alveolar nerve was responsible for a fusiform enlargement of the canal [53], traumatic neuroma caused an oval well-circumscribed unilocular lesion of the canal [54], and localized hypertrophic neuropathy led to a well-circumscribed fusiform enlargement with clearly visible sclerotic margins [55]. Furthermore, widening of the canal and the mental foramen were observed in Proteus syndrome, a rare congenital hamartomatous condition [56].

In conclusion, widening of the IAN canal is a rare finding. When confronted with this finding, a multitude of benign and malignant conditions need to be excluded before diagnosing a simple anatomical variant. Each case has to be evaluated carefully. While an earlier panoramic X-ray was the examination of choice, this should currently be accompanied by CBCT or CT and MRI, the last examination being more accurate for depicting the contents of the mandibular canal at the present time. Tractography of the IAN may be of additional use.

**Conflict of interest** The authors declare that they have no conflict of interest.

## References

- Kieser J, Kieser D, Hauman T. The course and distribution of the inferior alveolar nerve in the edentulous mandible. *J Craniofac Surg.* 2005;1:6–9.
- Olivier E. The inferior dental canal and its nerve in the adult. *Br Dent J.* 1928;49:356–8.
- Juodzbaly G, Wang HL, Sabalys G. Anatomy of mandibular vital structures. Part II: mandibular incisive canal, mental foramen and associated neurovascular bundles in relation with dental implantology. *J Oral Maxillofac Res.* 2010;1:e3.
- Williams LS, Schmalzfuss IM, Sstrom CL, Inoue T, Tanaka R, Seoane ER, et al. MR imaging of the trigeminal ganglion, nerve, and the perineural vascular plexus: normal appearance and variants with correlation to cadaver specimens. *AJNR Am J Neuroradiol.* 2003;24:1317–23.
- Becker M, Kohler R, Vargas MI, Viallon M, Delavelle J. Pathology of the trigeminal nerve. *Neuroimag Clin N Am.* 2008;18:283–307.
- Borges A, Casselman J. Imaging the trigeminal nerve. *Eur J Radiol.* 2010;74:323–40.
- Vargas MI, Viallon M, Nguyen D, Delavelle J, Becker M. Diffusion tensor imaging (DTI) and tractography of the brachial plexus: feasibility and initial experience in neoplastic conditions. *Neuroradiology.* 2010;52:237–45.
- Mori S, Kaneda T, Fujita Y, Kato M, Sakayanagi M, Minami M. Diffusion tensor tractography for the inferior alveolar nerve (V3): initial experiment. *Oral Surg Oral Med Oral Pathol Oral Radiol Endod.* 2008;106:270–4.
- Fujiwara S, Sasaki M, Wada T, Kudo K, Hirooka R, Ishigaki D, et al. High-resolution diffusion tensor imaging for the detection of diffusion abnormalities in the trigeminal nerves of patients with trigeminal neuralgia caused by neurovascular compression. *J Neuroimaging.* 2011;21:e102–8.
- Polak M, Polak G, Brocheriou C, Vigneul J. Solitary neurofibroma of the mandible: case report and review of the literature. *J Oral Maxillofac Surg.* 1989;7:65–8.
- Shapiro SD, Abramovitch K, Van Dis ML, Skoczylas LJ, Langlais RP, Jorgenson RJ, et al. Neurofibromatosis: oral and radiographic manifestations. *Oral Surg Oral Med Oral Pathol.* 1984;58:493–8.
- Lee HH, Lian SL, Huang CJ, Huang MY. Tomotherapy for neurofibromatosis type 2: case report and review of the literature. *Br J Radiol.* 2010;83:e74–8.
- Apostolidis C, Anterriotis D, Rapidis AD, Angelopoulos AP. Solitary intraosseous neurofibroma of the inferior alveolar nerve: report of a case. *J Oral Maxillofac Surg.* 2001;59:232–5.
- Barnes L, Eveson JW, Reichart P, Sidransky D. Pathology and genetics of head and neck tumours. WHO classification of tumours. Lyon: IARC; 2005.
- Chi AC, Carey J, Muller S. Intraosseous schwannoma of the mandible: a case report and review of the literature. *Oral Surg Oral Med Oral Pathol Oral Radiol Endod.* 2003;96:54–65.
- Metwaly H, Maruyama S, Cheng J, Hoshina H, Takagi R, Hayashi T, et al. Central schwannoma of the mandible: report of a case and review of the literature. *Oral Med Pathol.* 2010;15:29–33.
- Park YK, Kim YW, Yang MH, Kim EJ, Ryu DM. Neurilemmoma of the mandible. *Skel Radiol.* 1999;28:536–9.
- Yamazaki H, Kaneko A, Ota Y, Tsukinoki K. Schwannoma of the mental nerve: usefulness of preoperative imaging: a case report. *Oral Surg Oral Med Oral Pathol Oral Radiol Endod.* 2004;97:122–6.
- Robertson I, Cook MG, Wilson DF, Henderson DW. Malignant schwannoma of cranial nerves. *Pathology.* 1983;15:421–9.
- Colmenero C, Rivers T, Patron M, Sierra I, Gamallo C. Maxillofacial malignant peripheral nerve sheath tumours. *J Cranio-maxillofac Surg.* 1991;19:40–6.
- Salla JT, Johann AC, Garcia BG, Aguiar MC, Mesquita RA. Retrospective analysis of oral peripheral nerve sheath tumors in Brazilians. *Braz Oral Res.* 2009;23:43–8.
- Ohnishi M, Tanaka Y, Tutui T, Bann S. Extensive malignant schwannoma of the mandibular nerve. Case report. *Int J Oral Maxillofac Surg.* 1992;21:280–1.
- Martin-Duverneuil N, Auriol M, Behin A, Bertrand JC, Chiras J. Facial malignant peripheral nerve sheath tumors. *J Neuroradiol.* 2006;33:237–49.
- Longo F, De Maria G, Esposito P, Califano L. Primary non-Hodgkin's lymphoma of the mandible. Report of a case. *Int J Oral Maxillofac Surg.* 2004;33:801–3.
- Robbins KT, Fuller LM, Manning J, Goepfert H, Velasquez WS, Sullivan MP, et al. Primary lymphoma of the mandible. *Head Neck Surg.* 1986;8:192–9.
- Bachaud JM, Coppin D, Douchez J. Primary malignant lymphoma of the mandible. A study of 3 cases and a review of the

- literature. *Rev Stomatol Chir Maxillofac*. 1992;93:372–6. (Article in French).
27. Barber HD, Stewart JC, Baxter WD. Non-Hodgkin's lymphoma involving the inferior alveolar canal and mental foramen: report of a case. *J Oral Maxillofac Surg*. 1992;50:1334–6.
  28. Bertolotto M, Cecchini G, Martinoli C, Perrone R, Garlaschi G. Primary lymphoma of the mandible with diffuse widening of the mandibular canal: report of a case. *Eur Radiol*. 1996;6:637–9.
  29. Buric N, Jovanovic G, Radovanovic Z, Buric M, Tijanic M. Radiographic enlargement of mandibular canal as first feature of non-Hodgkin's lymphoma. *Dentomaxillofac Radiol*. 2010;39:383–8.
  30. Gusenbauer AW, Katsikeris NF, Brown A. Primary lymphoma of the mandible: report of a case. *J Oral Maxillofac Surg*. 1990;48:409–15.
  31. Schimming R, Lossnitzer A. Primary non-Hodgkin lymphoma of the mandible—a case report. *Schweiz Monatsschr Zahnmed*. 1999;109:837–43. (Article in French, German).
  32. Maeda M, Kato H, Sakuma H, Maier SE, Takeda K. Usefulness of the apparent diffusion coefficient in line scan diffusion-weighted imaging for distinguishing between squamous cell carcinomas and malignant lymphomas of the head and neck. *AJNR Am J Neuroradiol*. 2005;26:1186–92.
  33. Lindqvist C, Teppo L, Sane J. Osteosarcoma of the mandible: analysis of nine cases. *J Oral Maxillofac Surg*. 1986;44:759–64.
  34. Givol N, Buchner A, Taicher S, Kaffe I. Radiological features of osteogenic sarcoma of the jaws. A comparative study of different radiographic modalities. *Dentomaxillofac Radiol*. 1998;27:313–20.
  35. Yagan R, Radivoyevitch M, Bellon EM. Involvement of the mandibular canal: early sign of osteogenic sarcoma of the mandible. *Oral Surg Oral Med Oral Pathol*. 1985;60:56–60.
  36. Clark JL, Unni KK, Dahlin DC, Devine KD. Osteosarcoma of the jaw. *Cancer*. 1983;51:2311–6.
  37. August M, Magennis P, Dewitt D. Osteogenic sarcoma of the jaws: factors influencing prognosis. *Int J Oral Maxillofac Surg*. 1997;26:198–204.
  38. Garrington GE, Scofield HH, Cornyn J, Hooker SP. Osteosarcoma of the jaws: analysis of 56 cases. *Cancer*. 1967;20:377–91.
  39. Bennett JH, Thomas G, Evans AW, Speight PM. Osteosarcoma of the jaws: a 30-year retrospective review. *Oral Surg Oral Med Oral Pathol Oral Radiol Endod*. 2000;90:323–33.
  40. Slootweg PJ, Muller H. Osteosarcoma of the jaw bones. Analysis of 18 cases. *J Maxillofac Surg*. 1985;13:158–66.
  41. Kunzler A, Farmand M. Typical changes in the viscerocranium in acromegaly. *J Craniomaxillofac Surg*. 1991;19:332–40.
  42. Burkes EJ. Vascular leiomyoma of the mandible: report of a case. *J Oral Maxillofac Surg*. 1995;53:65–6.
  43. Schenberg ME, Zajac JD, Lim-Tio S, Collier NA, Brooks AM, Reade PC. Multiple endocrine neoplasia syndrome—type 2b. Case report and review. *Int J Oral Maxillofac Surg*. 1992;21:110–4.
  44. Hell B, Freitag V. Lower lip carcinoma. Infiltration of the mandible along the mental nerve. *J Craniomaxillofac Surg*. 1988;16:76–9.
  45. Ikeda K, Ho KC, Nowicki BH, Haughton VM. Multiplanar MR and anatomic study of the mandibular canal. *AJNR Am J Neuroradiol*. 1996;17:579–84.
  46. Halazonitis JA, Kountouris J, Halazonitis NA. Arteriovenous aneurysm of the mandible. *Oral Surg Oral Med Oral Pathol*. 1982;53:454–7.
  47. Horswell BB, Holmes AD. Arteriovenous malformation in the mandible of a young child. *Aust N Z J Surg*. 1988;58:73–6.
  48. Mohammadi H, Said-al-Naief NA, Heffez LB. Arteriovenous malformation of the mandible: report of a case with a note on the differential diagnosis. *Oral Surg Oral Med Oral Pathol Oral Radiol Endod*. 1997;84:286–9.
  49. Kohout MP, Hansen M, Pribaz JJ, Mulliken JB. Arteriovenous malformations of the head and neck: natural history and management. *Plast Reconstr Surg*. 1998;102:643–54.
  50. Siu WW, Weill A, Garipey JL, Moret J, Marotta T. Arteriovenous malformation of the mandible: embolization and direct injection therapy. *J Vasc Interv Radiol*. 2001;12:1095–8.
  51. Sakkas N, Schramm A, Metzger MC, Berlis A, Schmelzeisen R, Otten JE, et al. Arteriovenous malformation of the mandible: a life-threatening situation. *Ann Hematol*. 2007;86:409–13.
  52. Vilos GA, Rapidis AD, Lagogiannis GD, Apostolidis C. Leiomyosarcomas of the oral tissues: clinicopathologic analysis of 50 cases. *J Oral Maxillofac Surg*. 2005;63:1461–77.
  53. Vartiainen VM, Siponen M, Salo T, Rosberg J, Apaja-Sarkkinen M. Widening of the inferior alveolar canal: a case report with atypical lymphocytic infiltration of the nerve. *Oral Surg Oral Med Oral Pathol Oral Radiol Endod*. 2008;106:e35–9.
  54. Arribas-Garcia I, Alcalá-Galiano A, Gutierrez R, Montalvo-Moreno JJ. Traumatic neuroma of the inferior alveolar nerve: a case report. *Med Oral Patol Oral Cir Bucal*. 2008;13:E186–8.
  55. Ethunandan M, Weller RO, McVicar IH, Fisher SE. Localized hypertrophic neuropathy involving the inferior alveolar nerve. *J Oral Maxillofac Surg*. 1999;57:84–9.
  56. Becktor KB, Becktor JP, Karnes PS, Keller EE. Craniofacial and dental manifestations of Proteus syndrome: a case report. *Cleft Palate Craniofac J*. 2002;39:233–45.