



## Control of Severe Portal Bleeding by Carrier-Bound Fibrin Sealant

CARLOS APESTEGUI, STEFAN BREITENSTEIN, PHILIPP DUTKOWSKI, and PIERRE-ALAIN CLAVIEN

The Swiss Hepato-Pancreatico-Biliary (HPB) Center, Department of Visceral and Transplant Surgery, University Hospital of Zurich, Ramistrasse 100, 8091 Zurich, Switzerland

### Abstract

Bleeding during liver surgery and liver transplantation (LT) can be caused by coagulation disorders, portal vein hypertension, and adhesions from previous surgical procedures. We describe here how we controlled life-threatening bleeding from a portal vein anastomosis during a third cadaveric LT, by using a carrier-bound sealant (TachoSil). This technique proved effective to control severe anastomotic portal bleeding in this situation. It represents a helpful option in the field of LT, when vascular bleeding cannot be stopped by other methods.

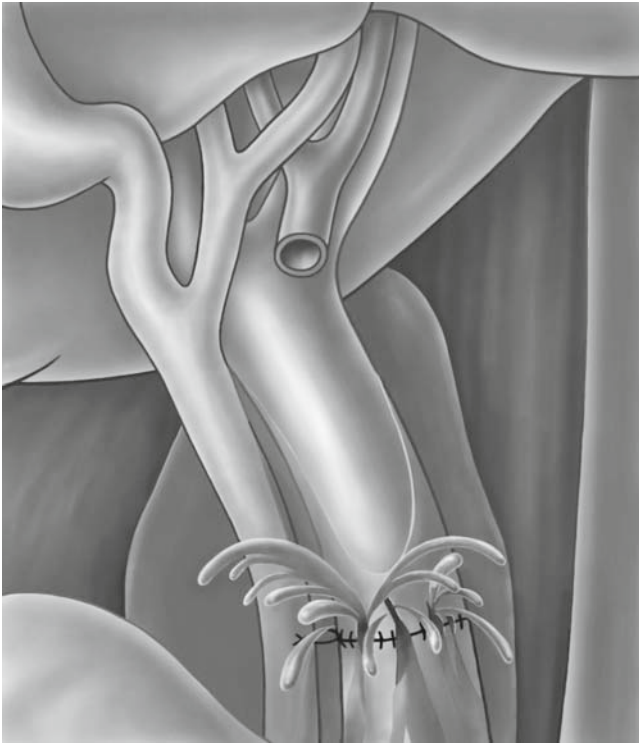
**Key words** Portal vein bleeding · Liver transplantation · Carrier-bound sealant · TachoSil

### Introduction

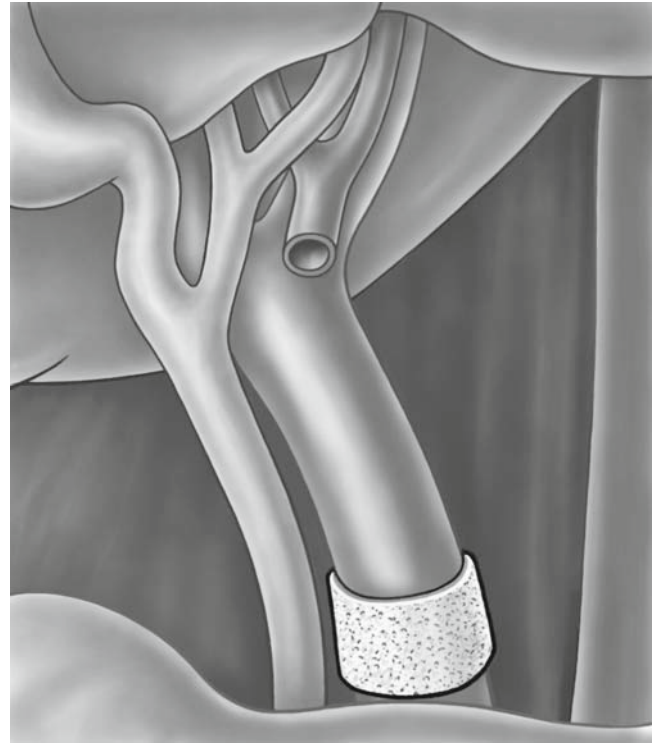
Hemostasis can be challenging during liver transplantation (LT) in patients with underlying coagulation disorders.<sup>1</sup> Several new products consisting of human coagulation factors are now available to assist in the control of bleeding and to attain hemostasis during surgery.<sup>2</sup> We report a case of life-threatening bleeding from a portal vein anastomosis during a third cadaveric LT, aggravated by portal hypertension and a very fragile portal vein. As the bleeding was not able to be stopped by suturing, we used a hemostatic tissue sealant (TachoSil; Nycomed, Zurich, Switzerland), which proved extremely efficient.

### Technique

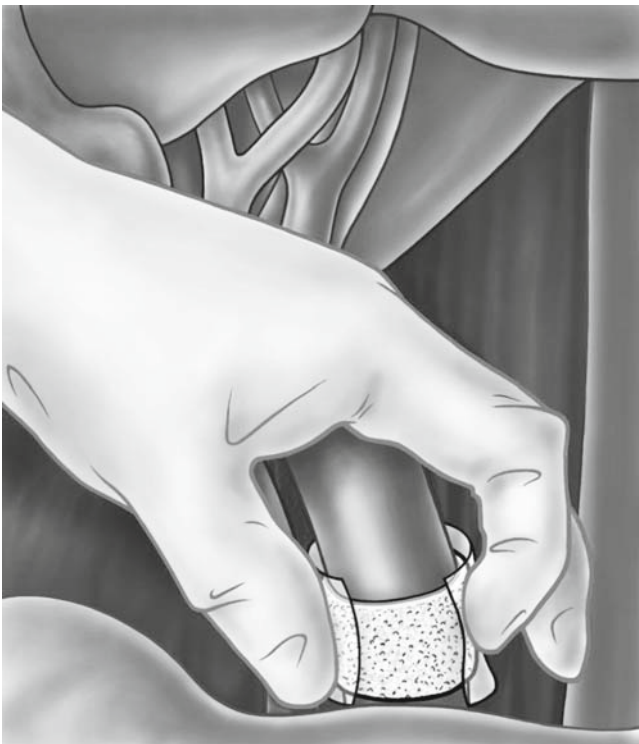A 32-year-old woman underwent a full cadaveric LT for viral hepatitis C (HCV)-related cirrhosis. A recurrence of the HCV led to cirrhosis of the graft, and a retransplantation was done 1 year later. Despite treatment with interferon and ribavirin, HCV recurred 2 years later, necessitating a third LT for cirrhosis. Severe portal hypertension and the adhesions left by the previous surgery made the operation challenging. The portal vein was kinked and dilated to more than 3 cm in diameter, with an extremely fragile and thin wall. The kinking made resection of a segment of the vein necessary. The subsequent portal anastomosis was made technically difficult by the recipient's short and fragile portal vein stump. Thus, we performed the anastomosis with a 6-0 polypropylene running suture with a 1-cm growth factor. After declamping the portal vein, the suture line and holes made by the stitches started bleeding profusely (Fig. 1). Attempts to stop the hemorrhage with stitches exacerbated the bleeding as the thread cut through the fragile portal wall. A new anastomosis or an interposed vascular graft would have been difficult under these conditions. As a feasible option at this critical stage, we decided to place a patch coated with human coagulation factors (TachoSil) around the suture line. First, we cut a single patch of TachoSil, moistened in saline solution, into the appropriate shape (approximately 1.5 cm wide) and placed it around the vein. The active yellow side of the hemostatic device was in contact with the vessel wall, covering the whole anastomotic suture line. Slight manual pressure was applied using a small wet sponge for 5 min (Fig. 2). Afterwards, the clots around the hepatic pedicle were removed carefully, keeping the patch in place without peeling the vein. The bleeding was thereby controlled and the hemorrhage stopped (Fig. 3). The subsequent surgical course was uneventful.



**Fig. 1.** Massive bleeding in the area of the portal anastomosis after declamping



**Fig. 3.** The TachoSil patch in place around the portal vein



**Fig. 2.** Control of the bleeding by a TachoSil patch around the portal vein

### Discussion

To our knowledge, this represents the first report describing the successful control of critical bleeding of a portal vein anastomosis, using TachoSil, a modern biological hemostatic and tissue sealant consisting of an equine collagen fleece patch containing fibrinogen and human thrombin without aprotinin. It delivers fibrinogen and thrombin to the site of bleeding, forming a fibrin network, which glues the collagen sponge to the wound surface.<sup>3</sup> The major concern relates to the risk of HIV or hepatitis transmission associated with the use of human coagulation proteins contained in this sealant. However, no such infections have been reported in 20 years of its use worldwide.<sup>4</sup>

This sealant is a further development of TachoComb and TachoComb H and is applied in several areas of surgery for the control or prevention of bleeding. TachoSil was used initially in thoracic surgery, where it not only controls bleeding, but also prevents pleural adhesions (animal study<sup>5</sup>) and air leaks (randomized control trial in humans<sup>6</sup>). In general surgery, TachoSil has been used mainly to control bleeding of cut surfaces of solid organs. In a randomized controlled trial by Frilling et al., TachoSil was superior to the argon beamer in obtaining fast and effective intraoperative hemostasis of the liver surface after liver surgery.<sup>7</sup> The safety and effectiveness of fibrin sealants has proven effective in

peripheral vascular surgery, particularly for preventing suture hole bleeding of grafts.<sup>3,8</sup> In our patient's third retransplant, the unexpected fragility and bleeding of the portal vein was life-threatening and could not have been controlled by additional surgical stitches. A reanastomosis or an interposed vascular graft would have been very risky because of the fragility of the vein. The effectiveness of TachoSil in this challenging, briefly uncontrolled bleeding from the venous low pressure system was remarkable. Apart from the efficacy of the hemostatic product itself, the role of the surgeon in applying a slight finger pressure to the area of the leak for several minutes was crucial. It is important to note that once the patch is in place, it should not be replaced or removed. In conclusion, surgical coated patches such as TachoSil are useful not only for controlling the bleeding of solids organs in the abdominal surgery, but also for venous vascular bleeding, particularly in the field of abdominal organ transplantation.

## References

1. Lisman T, Leebeek FW. Hemostatic alterations in liver disease: a review on pathophysiology, clinical consequences, and treatment. *Dig Surg* 2007;24(4):250–8.
2. Nakajima K, Yasumasa K, Endo S, Takahashi T, Kai Y, Nezu R, et al. Simple application technique of fibrin-coated collagen fleece (TachoComb) in laparoscopic surgery. *Surg Today* 2007;37(2):176–9.
3. Joseph T, Adeosun A, Paes T, Bahal V. Randomised controlled trial to evaluate the efficacy of TachoComb H patches in controlling PTFE suture-hole bleeding. *Eur J Vasc Endovasc Surg* 2004;27(5):549–52.
4. Joch C. The safety of fibrin sealants. *Cardiovasc Surg* 2003;11 suppl 1:23–8.
5. Getman V, Devyatko E, Wolner E, Aharinejad S, Mueller M. Fleece bound sealing prevents pleural adhesions. *Interact Cardiovasc Thorac Surg* 2006;5(3):243–6.
6. Anegg U, Lindenmann J, Matzi V, Smolle J, Maier A, Smolle-Juttner F. Efficiency of fleece-bound sealing (TachoSil) of air leaks in lung surgery: a prospective randomised trial. *Eur J Cardiothorac Surg* 2007;31(2):198–202.
7. Frilling A, Stavrou G, Mischinger H, De Hemptinne B, Rokkjaer M, Klemplnauer J, et al. Effectiveness of a new carrier-bound fibrin sealant versus argon beamer as haemostatic agent during liver resection: a randomised prospective trial. *Langenbecks Arch Surg* 2005;390(2):114–20.
8. Schenk W, Burks S, Gagne P, Kagan S, Lawson J, Spotnitz W. Fibrin sealant improves hemostasis in peripheral vascular surgery: a randomized prospective trial. *Ann Surg* 2003;237(6):871–6; discussion 876.