

Int Ophthalmol (2013) 33:635–643
DOI 10.1007/s10792-013-9749-z

ORIGINAL PAPER

Comparison of fundus autofluorescence images acquired by the confocal scanning laser ophthalmoscope (488 nm excitation) and the modified Topcon fundus camera (580 nm excitation)

A. Deli · L. Moetteli · A. Ambresin · I. Mantel

Received: 21 September 2012 / Accepted: 22 February 2013 / Published online: 7 March 2013
© Springer Science+Business Media Dordrecht 2013

Abstract To compare autofluorescence (AF) images obtained with the confocal scanning laser ophthalmoscope (using the Heidelberg retina angiograph; HRA) and the modified Topcon fundus camera, in a routine clinical setting. A prospective comparative study conducted at the Jules-Gonin Eye Hospital. Fifty-six patients from the medical retina clinic. All patients had complete ophthalmic slit-lamp and fundus examinations, colour and red-free fundus photography, AF imaging with both instruments, and fluorescein angiography. Cataract and fixation were graded clinically. AF patterns were analyzed for healthy and pathological features. Differences of image noise were analyzed by cataract grading and fixation. A total of 105 eyes were included. AF patterns discovered by the retina angiograph and the fundus camera images, respectively, were a dark optic disc in 72 % versus 15 %, a dark fovea in 92 % versus 4 %, sub- and intraretinal fluid visible as hyperautofluorescence on HRA images only, lipid exudates visible as hypoautofluorescence on HRA images only. The same autofluorescent pattern was found on both images for geographic atrophy, retinal pigment changes, drusen and haemorrhage. Image noise was significantly associated with the degree of cataract and/or poor fixation, favouring the

fundus camera. Images acquired by the fundus camera before and after fluorescein angiography were identical. Fundus AF images differ according to the technical differences of the instruments used. Knowledge of these differences is important not only for correctly interpreting images, but also for selecting the most appropriate instrument for the clinical situation.

Keywords Fundus autofluorescence · Scanning laser ophthalmoscope · Heidelberg retina angiograph · Topcon fundus camera · Lipofuscin

Introduction

Fundus autofluorescence (AF) is a non-invasive imaging examination technique used in various retinal diseases for diagnosis and monitoring of disease progression. By providing fundusoscopic images based on stimulated emission of light from lipofuscin, AF supplies information complementary to that obtained using fundus photography and fluorescein angiography (FA) [1]. Visualising the lipofuscin distribution in the retinal pigment epithelium (RPE) cell monolayer in vivo is believed to reflect some aspect of RPE integrity [1, 2]. However, some AF may also be generated from the outer retina and the subretinal space [3], probably in part attributable to *N*-retinylidene-*N*-retinyl-ethanolamine (A2E) due to disturbed outer photoreceptor segment processing.

A. Deli · L. Moetteli · A. Ambresin · I. Mantel (✉)
Ophthalmology Department of the University of
Lausanne, Jules-Gonin Eye Hospital, 15 Av. de France—
Case postale 133, 1000 Lausanne 7, Switzerland
e-mail: irmela.mantel@fa2.ch

A number of instruments are currently available to document AF. The Heidelberg retina angiograph [HRA] (Heidelberg Engineering, Heidelberg, Germany) and the Topcon fundus camera [TFC] (Topcon, Tokyo, Japan) are both frequently used in clinical settings. A modification of the TFC has been suggested by Spaide, using a filter set to avoid the lens AF [3]. This filter set is commercially available and it defines the modified TFC (mTFC). However, the two instruments use different wavelengths and different techniques for acquiring the AF images. The HRA uses a 488 nm laser for excitation and a >500 nm barrier filter in a confocal scanning laser ophthalmoscope (cSLO), while the mTFC uses a 535–580 nm filter for excitation and a 615–715 nm barrier filter in a digital fundus camera system. Therefore, the AF pattern of the acquired images may vary between the instruments [4, 5], and image quality may show different susceptibility for complicating factors (e.g., stability of eye position, cataract).

Previous comparisons of AF imaging between the HRA and the mTFC showed similar results in cases of geographic atrophy, while the presentation of cystoid macular oedema and the normal fovea showed clear differences [4–7].

The aim of the present study is to systematically compare the images acquired in a routine clinical setting with the HRA and mTFC for (a) similarities and differences in AF patterns in healthy retinal structures (disc and fovea) and a variety of pathological retinal structures (drusen, pigmentary changes, geographic atrophy, subretinal fluid, intraretinal fluid, lipid exudates, subretinal haemorrhage), (b) factors influencing the image quality, and (c) feasibility of AF images after FA.

Methods

Fifty-six consecutive patients (105 eyes) from the medical retina clinic underwent AF imaging with both the HRA and the mTFC.

Each patient underwent a complete ophthalmological examination, which included a history, best-corrected visual acuity (BCVA) on ETDRS charts, slit-lamp examination and dilated fundus ophthalmoscopy (pupil dilation ≥ 6 mm), colour and red-free fundus photography as well as blue filter photography, FA (Topcon TRC50IX; Topcon), spectral domain

optical coherence tomography [SD-OCT] (Cirrus; Carl Zeiss Meditec, Dublin, CA, USA) and AF imaging with both instruments—the HRA (Heidelberg retina angiograph 2, Heidelberg Engineering) and the mTFC (modified Topcon TRC-50X, Topcon), performed by the same photographer. All the participants gave their informed consent prior to their inclusion to the study, which was approved by the ethics committee and was performed in accordance with the ethical standards of the 1964 Declaration of Helsinki.

The fixation was clinically classified as ‘good’ or ‘poor’ during OCT acquisition. A ‘good’ classification indicated that the patient was able to fixate during acquisition of the 512×128 cube = 2.4 s. The degree of cataract was classified as ‘absent’ (clear lens or clear intraocular implant), ‘mild to moderate’ (AREDS classification grade 1–3), or ‘advanced’ (AREDS classification grade ≥ 4) [8].

This study was conducted in accordance with the guidelines of the Declaration of Helsinki. Patients gave informed consent.

Autofluorescence image acquisition

With the HRA, AF image acquisition was performed before FA (impossible after fluorescein injection), while the images were acquired before and after FA with the mTFC, as the filter set excludes the fluorescein spectrum.

For AF imaging, the HRA uses an argon blue laser (488 nm) for excitation and a band-pass filter with a cut-off at 500 nm inserted in front of the detector. Red-free high-speed resolution mode was chosen, the sensitivity was adjusted (85–95 %), and the ametropic corrector was used to correct for refractive error before acquiring the AF image. Fundus AF images were then taken as a movie sequence with 8.8 pictures/sec ($30^\circ \times 30^\circ$ and $55^\circ \times 55^\circ$). Subsequently, 21 single AF images of 768×768 pixels were selected for automatic alignment. A mean image was calculated by the integrated software (automatic real time composite mode), thereby reducing the noise as much as possible.

The mTFC was equipped with an excitation filter of 535–585 nm and a barrier filter of 615–715 nm, as recently suggested by Spaide [3]. In compliance with the manufacturer’s recommendations, the following settings were used: excitation flash light 300 Ws, gain 30–36, and 50° angle of coverage with a laser output of 265 μ W. A single AF image of 2056×1472 pixels

was obtained and, using the programme Imagenet Ibase (Version 3.7.4., Topcon Europe Medical B.V., Capelle a/d IJssel, Netherlands), image brightness was improved and image contrast was adjusted manually in order to maximally enhance the visualisation of AF abnormalities subjectively. This, however, does not improve the noise of the single acquired image.

Image analysis

The grading of the AF pattern for healthy structures (fovea and disc in clinically determined absence of any pathology) or pathological structures (drusen, pigmentary changes, geographic atrophy, subretinal fluid, intraretinal fluid, lipid exudates, subretinal haemorrhage) included only eyes with gradable images on both image modalities. Because of the qualitative character of AF images and the absence of a quantitative scale for AF intensity, the retinal vessels served as reference for hypofluorescence (black on HRA, slightly grey on mTFC). Healthy parts of the retina at 10° from the fovea (maximal AF in normals) served as reference for iso-AF. The grading was performed by a medical retina specialist (IM).

Furthermore, the AF images of each eye (HRA, mTFC before and after FA) were graded according to one of three categories—minimal noise (perfect visibility of details <125 µm), moderate noise (reduced details but grading of fovea and disc possible), or severe noise (grading of retinal structures impossible). Digital adjusting (mTFC) did not alter the gradability of the structures and, therefore, did not influence our grading of image quality/noise.

Statistical analysis

Statistical analysis was performed to assess the influence of cataract and fixation on the degree of image noise. The Chi squared test was used. A *p* value of <0.05 was considered significant. Purely descriptive statistics were used for AF distribution in normal and pathological structures.

Results

Data were collected from 105 eyes (52 right and 53 left) of 56 enrolled patients (17 men, 39 women) with a mean age of 70 years (SD 16, range 18–90 years) and

a mean BCVA of 66 ETDRS letters. The mean pupil size was 7.14 mm (range 6–9 mm). From the 105 eyes, 13 had no retinal abnormality and 92 presented different retinal pathologies, including age-related macular degeneration (56 eyes), central serous retinopathy (12 eyes), diabetic retinopathy (10 eyes), vitelliform foveomacular dystrophy (5 eyes), idiopathic juxtafoveolar telangiectasia (2 eyes), myopic choroidal neovascularisation (1 eye), idiopathic choroidal neovascularisation (1 eye), central retinal vein occlusion (1 eye), branch retinal venous occlusion (1 eye), solar maculopathy (1 eye), toxoplasmosis (1 eye), and idiopathic polypoidal choroidal vasculopathy (1 eye).

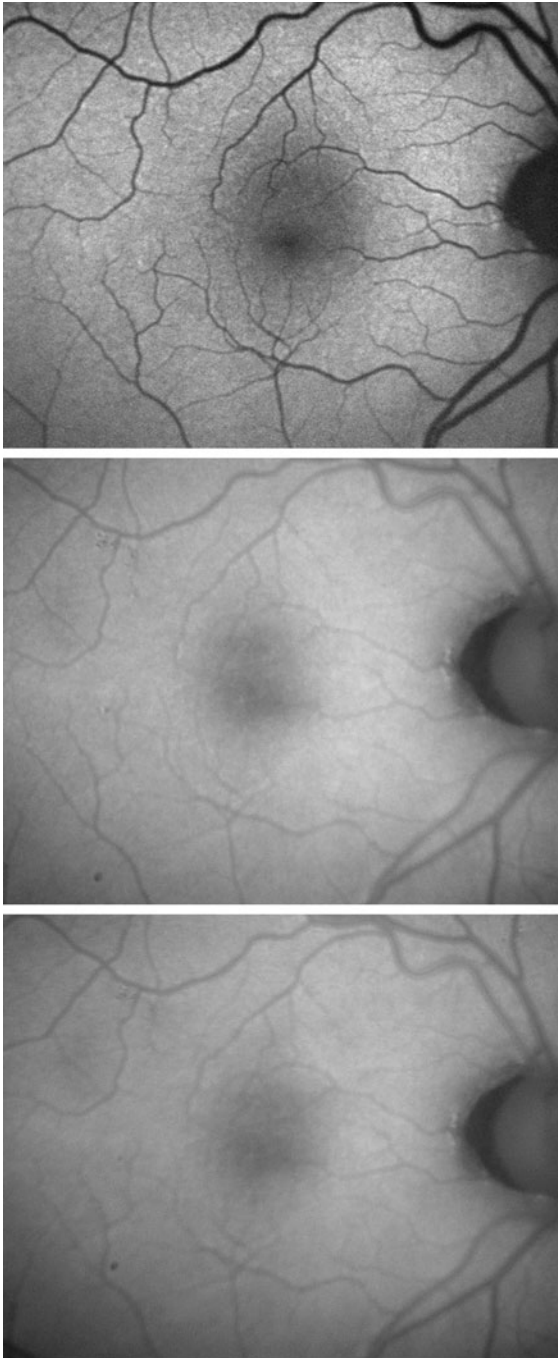
Findings of healthy retinal structures (Fig. 1, Table 1)

The disc was clinically healthy (absence of any pathology) and gradable on both image modalities in 92 eyes. Of these, 72 and 15 % were as dark as the retinal vessels on the HRA and the mTFC, respectively. A mild degree of AF (more than the retinal vessels but less than the healthy retina at 10° from the fovea) was found in 28 and 81 % on the HRA and the mTFC, respectively. A degree of AF as found in the healthy retina at 10° from the fovea was found in 4 % of eyes with the mTFC.

The fovea was clinically healthy (absence of any pathology) and gradable on both image modalities in 47 eyes. The results were significantly different ($p < 0.001$) 92 and 4 % were dark (at least as the retinal vessels) on the HRA and the mTFC, respectively. A mild and strong degree of AF (iso-AF with reference at 15° from fovea) was found with the HRA in 8 and 0 % of eyes, while the mTFC revealed the same in 43 and 53 % of eyes, respectively.

Findings in retinal pathologies (Fig. 2)

Geographic atrophy ($n = 23$ eyes, gradable AF images $n = 21$) showed identical AF behaviour in all gradable eyes on both image modalities, in terms of both the hypo-AF of the atrophy itself ($n = 21$), and the hyper-AF lesions ($n = 20$) at the border of the geographic atrophy. Choroidal vessels were visible with mild AF in the centre of the atrophy in two eyes on both image modalities, and in one eye on the mTFC only.



◀ **Fig. 1** Fundus autofluorescence of the right eye without any retinal pathology in a 63-year-old male patient. (*Top*) The image acquired with the Heidelberg retina angiograph 2 (Heidelberg Engineering) showed the typically dark optic disc, brightest autofluorescence between 7 and 15° around the fovea, and foveal hypo-autofluorescence due to macular pigment. (*Middle and bottom*) The images acquired with the modified Topcon fundus camera (TRC-50X, Topcon) were graded identical before fluorescein angiography (*middle*) and after fluorescein angiography (*bottom*). However, compared with the Heidelberg retina angiograph image (*top*), the noise was graded as increased. With the retinal vessels serving as reference for hypo-autofluorescence because of overall poorer contrast of the images from the modified Topcon fundus camera, the optic disc showed mild autofluorescence (*middle and bottom*), and the fovea was hypoautofluorescent. All images were acquired by the same photographer on the same day and after pupil dilatation

patterns. Soft drusen (identified on colour and red-free fundus images) were found and gradable in 28 eyes. On fundus AF images, they were either invisible or showed very mild hyperfluorescence on both image modalities. Reticular drusen ($n = 26$ eyes) showed the same hyperfluorescent network around hypofluorescent spots on both image modalities. Small hard drusen ($n = 3$ eyes) showed mild hypofluorescence on both image modalities.

Intra- and subretinal haemorrhage ($n = 10$) revealed identical hypo-AF on both image modalities in all cases.

Subretinal fluid ($n = 10$) was visible as a hyperfluorescent zone in nine eyes on the HRA, but only in 4 eyes on the mTFC (in one eye with a very recent occurrence of exudation, HRA only revealed a hypofluorescent zone).

Cystoid macular oedema ($n = 12$) showed some hyper-AF of the cystoid spaces in all 12 eyes on the HRA and in 2 eyes on the mTFC.

Lipid exudates ($n = 10$) showed a blockage phenomenon with hypo-AF, which was visible on HRA in all 10 eyes, while barely visible ($n = 1$) or absent ($n = 9$) on the mTFC.

Comparison of image noise (Table 2)

Images acquired by the mTFC before and after FA showed no difference and were identical in all cases (100%). In fact, it was impossible to determine whether the mTFC image was acquired before or after FA. However, no AF image can be obtained after FA with the HRA.

The most prominent difference between the two image modalities was the higher contrast on the HRA

Pigmentary changes of the RPE ($n = 65$ eyes, gradable AF images $n = 64$) were identical (hypo-AF and hyper-AF) on both image modalities in 62 eyes, and only visible on mTFC in two eyes.

Drusen ($n = 40$ eyes, gradable AF images $n = 36$) showed a variety of hypo-, iso- or hyperfluorescent

Table 1 Comparison of the autofluorescence pattern of the healthy disc and the healthy fovea between the Heidelberg retina angiograph and the modified Topcon fundus camera

Autofluorescence	Healthy disc		Healthy fovea	
	HRA	mTFC (%)	HRA	mTFC (%)
Absent AF	66 (72 %)	14 (15)	43 (92 %)	2 (4)
Hypo-AF	26 (28 %)	74 (81)	4 (8 %)	20 (43)
Iso-AF	0	4 (4)	0	25 (53)
Total	92 (100 %)	92 (100)	47 (100 %)	47 (100)

HRA Heidelberg retina angiograph, *mTFC* modified Topcon fundus camera, *AF* autofluorescence, *Absent AF* autofluorescence as retinal vessels, *Hypo-AF* autofluorescence, on grey scale in between the retinal vessels and healthy retina at 10° from fovea, *Iso-AF* autofluorescence as the healthy retina at 10° from the fovea, *Healthy* clinically absent pathology

images, compared with the mTFC images, despite digital enhancement of the latter. Most structures that appeared black on the HRA image still showed as dark grey on the mTFC image. As explained in the “Methods” section, we chose the retinal vessels as reference for hypo-AF.

Minimal, moderate and severe image noise, respectively, was found in 63, 26, and 11 % of the HRA images ($n = 105$) and in 49, 49, and 2 % of the mTFC images ($n = 105$). A difference in noise grading between the two image modalities was found in 45 % of eyes, favouring the image quality of HRA in 17 %, and of the mTFC in 28 %.

The presence of cataract (grade absent, mild or moderate, advanced) was associated with a significant higher chance of unequal image quality grading ($p = 0.001$), with significantly better image quality from the mTFC ($p = 0.03$ for Chi squared 3×2) for the groups of unequal image quality. Table 2 shows the distribution.

The presence of poor fixation was associated with a significantly higher chance of unequal image quality grading ($p = 0.009$), with significantly better image quality from the mTFC ($p = 0.03$ for Chi squared 2×2) (Table 2).

Discussion

AF images are increasingly used in research, as well as in clinical practice. These images play an important role in diagnosis, classification, prognosis and follow-up of retinal disorders. In research, AF images are mostly acquired with a cSLO system (HRA). In clinical practice, the modified Topcon camera is used as well, and offers ease of use and the possibility of

equipping an existing TFC with the filter set for AF post hoc. To enable the correct interpretation of the images, a definition of differences and agreements between the two systems is needed.

The present study compares the AF patterns and image quality of the HRA and mTFC instruments obtained for both healthy and pathological structures, in a clinical routine setting. Both devices were developed to image fundus AF from lipofuscin, mainly found in the RPE. However, the two instruments use very different technical approaches. The HRA (excitation 488 nm laser/barrier >500 nm) uses a confocal technique, in which only conjugate points on the fundus are imaged. The resultant AF signal is weak. By averaging several images together, the AF signal is increased and the noise reduced proportionately to the square root of the images averaged. The mTFC, however, with its excitation band pass filter at 535–580 nm and barrier filter at 615–715 nm, acquires the AF images in a conventional non-confocal fundus camera system, which produces less noise but relies on single images. The filters were developed to avoid lens AF [3]. Images from both instruments show relative AF values, which are digitally modified with image processing software. In the HRA, an integrated software program scales the images so that the histogram of the grey scale values better fits the available range. Images from the TFC, however, are manually adjusted for contrast and luminosity.

The differences in the excitation and barrier wavelengths may explain several differences between the resulting images.

First, lutein and zeaxanthin, the macular pigments located in the outer and partly in the inner plexiform layer in highest density in the foveal area, show absorption spectra ranging between 400 and 540 nm

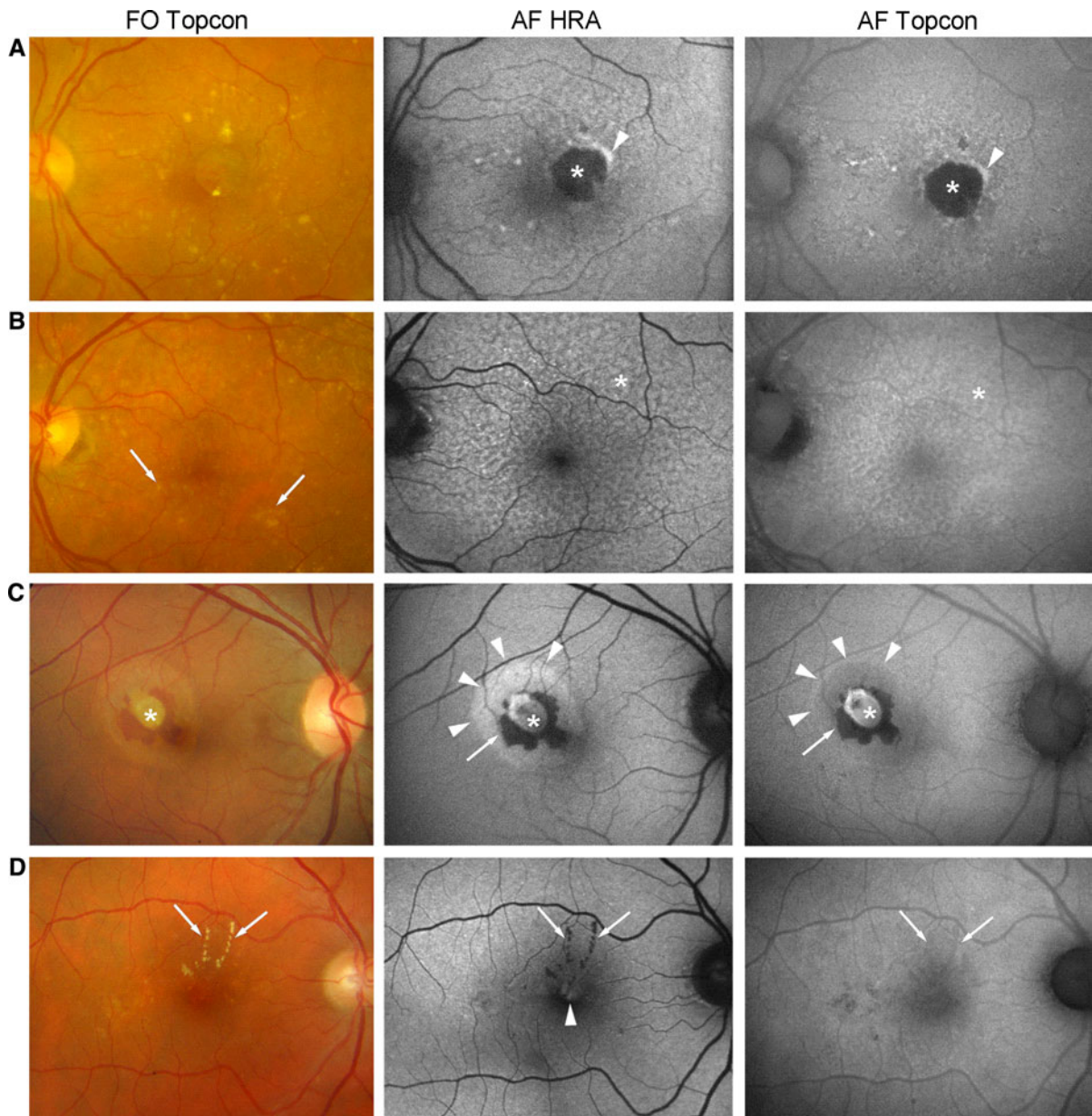


Fig. 2 Colour photographs and fundus autofluorescence with the Heidelberg retina angiograph 2 (AF HRA) and the modified Topcon fundus camera (AF Topcon) in four different eyes with a variety of pathological features. *Line A* An 80-year-old female patient with juxtafoveal geographic atrophy (*asterix*) in age-related macular degeneration of the left eye. Fundus autofluorescence behaviour was identically hypo-autofluorescent for the atrophy, and identically hyper-autofluorescent for its margin (*arrowhead*). *Line B* An 85-year-old female patient with drusen in age-related macular degeneration. Reticular drusen were found all over the posterior pole, but mainly visible on the two fundus autofluorescence images (*asterix*), with identical behaviour in terms of hyper-autofluorescent network and

hypo-autofluorescent dots. In contrast, large soft drusen were only identified on the colour photograph (*arrowhead*), but not visible on either fundus autofluorescence image. *Line C* A 34-year-old female patient with idiopathic choroidal neovascularisation (*asterix*) in her right eye. Identical blocking phenomenon by blood on both autofluorescence images (*arrow*), while the area of subretinal exudation appeared hyper-autofluorescent on the HRA image only (*arrowheads*). *Line D* A 72-year-old male patient with diabetic maculopathy in his right eye. Lipid exudation (*arrows*) was hypo-autofluorescent on the HRA image only, while barely visible on the Topcon image. Cystoid macular oedema (*arrowhead*) showed hyper-autofluorescence on the HRA image only

Table 2 Comparison of AF image noise between the Heidelberg retina angiograph and the Topcon fundus camera by transparency of the lens

	No difference in noise (image quality grading)	Less noise on HRA (better image quality grading)	Less noise on mTFC (better image quality grading)	Total
Total (%)	58 (55)	18 (17)	29 (28)	105 (100)
Transparency of the media				
Clear/IOL	41	13	10	64
Mild cataract (AREDS 1–3)	15	3	7	25
Moderate/advanced (AREDS \geq 4)	2	2	12	16
Fixation quality				
Good fixation	55	17	19	91
Poor fixation	3	1	10	14

HRA Heidelberg retina angiograph, *mTFC* modified Topcon fundus camera, *IOL* intraocular lens, *AREDS* classification system for cataracts established by the Age-Related Macular Degeneration Study

with a peak of 460 nm [9], therefore reducing the AF signal mainly on the HRA images [4, 10]. The same mechanism may account for the better visibility of cystoid macular oedema on HRA-generated AF images—the cystic spaces may displace the blocking macular pigment and create a window effect [4]. However, the possibility exists that the cystoid spaces contain fluorophores that are excited by 488 nm but not by 580 nm light.

Second, the different appearance of areas with subretinal fluid may be attributable to the difference between the wavelengths used. Recent findings have shown that some of the AF signal might also be measured from the precursors of lipofuscin located in the outer segment of photoreceptors such as A2PE, A2PE-H2, and A2-rhodopsin [11, 12] with a much narrower emission spectrum toward shorter wavelengths (from \sim 500 to 630 nm, with a peak of 570 nm) and an excitation spectrum from 300 to 500 nm [13]. Spaide described fundus AF from the subretinal space (often associated with subretinal exudation), which might be generated by an incompletely digested outer accumulation of A2E [3].

Third, the difference in wavelengths between the HRA and mTFC instruments explains why Topcon images can also be acquired after performing FA, according to our study even with identical quality as compared to before FA—the excitation spectrum (excitation filter) lies beyond the one of fluorescein, contrary to the excitation wavelength used in the HRA.

Fourth, the different wavelengths may account for a different susceptibility to advanced cataract. Although

the HRA bypasses the lens AF by its confocal technique, measuring only emission from the fundus, its reliance on short wavelengths may cause strong absorption by advanced cataracts, which might significantly degrade the resulting image. However, compared with the old set of AF filters for the TFC, the confocal capacity still resulted in superiority of HRA in cases of cataract, as shown in a study by Schmitz-Valckenberg et al. [6]. However, the new pair of filters [3], which are now integrated in the mTFC and used in the present study, apparently reduce the susceptibility of the TFC to cataract.

However, the different image acquisition mode—confocal technique versus conventional fundus camera—may also account for some differences in observations.

First, the single image acquisition of the mTFC appears to have some advantages in cases of poor fixation, according to our results, although the HRA is equipped with an eye tracker for image stabilisation.

Second, the lower contrast on the mTFC images may be explained by incomplete bypassing of the lens AF, which may generate some diffuse overlying AF. In the absence of completely black normal retinal structures on the mTFC, we chose the retinal vessels as a reference for absent AF. However, even with this reference, the optic disc often showed some AF on the mTFC, contrary to the HRA. Therefore we conclude that this disc-AF on the mTFC is not attributable to diffuse lens AF. However, it may be attributable to either different wavelengths that detect unspecified fluorophores other than lipofuscin, or to scattered light reflected by the optic nerve head

and sent back toward the detector, as recently suggested [6].

Despite many differences, the images are remarkably comparable when visualising geographic atrophy [6], pigmentary changes of the RPE, and drusen (soft, small hard or reticular). The main fluorophore in these cases is lipofuscin in the RPE, for which both instruments have been developed. However, additional fluorophores may play a role in drusen imaging [14], which needs higher resolution images in order to visualise these small structures and potential differences between the HRA and the mTFC images.

The timely order of acquisition of the images is essential for HRA AF images, which need to be taken before any FA. However, the AF images of both machines, the HRA and the mTFC showing relative AF values rather than absolute values, a potential diffuse influence of the AF by any previous light exposure due to retinal imaging (without fluorescein injection) would not become apparent, although in mice a mild increase of AF is found during the first 1.5 s of blue light exposure, whereas prolonged blue light exposure is needed in order to reduce slightly the AF response [15].

We acknowledge several limitations of this study. Clinical routine circumstances may have reduced the overall image quality and noise. We attempted to compensate for this by using the same experienced photographer for both AF images. Second, the image analysis was performed manually by a single retina specialist without specialised software. Third, we acknowledge the limited sample size and the limited number of pathological features coming from various underlying retinal pathologies. Therefore our observations are not exhaustive, and additional differences between the AF images of the two instruments may exist. And fourth, the influence of the degree of dilatation was not included in this study because all patients were well dilated. Poor dilatation would most likely result in better AF images from the HRA.

In conclusion, the AF images acquired by the HRA and the mTFC show many differences that may be attributed to the technical differences between the instruments. The HRA is the most commonly used machine in retinal research and results in better contrast of the AF images. HRA is superior to the mTFC when visualising cystoid macular oedema, lipid exudates, and AF from the subretinal space including serous exudation. Furthermore, it is an interesting tool

for imaging macular pigment [8]. However, the AF images obtained with the mTFC are less influenced by macular pigment and therefore reveal the macular content of lipofuscin better. When screening for foveal atrophy, this might be a significant advantage. Furthermore, the mTFC appears to have some advantages in terms of image quality, in cases of advanced cataract and poor fixation. It is very convenient that the images may be acquired even after FA.

However, in terms of AF changes, similar results are obtained by both instruments when visualising geographic atrophy, RPE changes, drusen, and retinal haemorrhage.

Additional studies are needed to increase our understanding of all factors that contribute to the final fundus AF image, whether acquired with the confocal SLO (HRA) or the fundus camera (mTFC).

Conflict of interest The authors declare that they have no conflict of interest. *Funding:* None. *Financial disclosure:* None

References

1. Delori FC, Dorey CK, Staurenghi G, Arend O, Goger DG, Weiter JJ (1995) In vivo fluorescence of the ocular fundus exhibits retinal pigment epithelium lipofuscin characteristics. *Invest Ophthalmol Vis Sci* 36:718–729
2. Von Ruckmann A, Fitzke FW, Bird AC (1995) Distribution of fundus autofluorescence with a scanning laser ophthalmoscope. *Br J Ophthalmol* 79:407–412
3. Spaide R (2008) Autofluorescence from the outer retina and subretinal space: hypothesis and review. *Retina* 28:5–35
4. Bessho K, Gomi F, Harino S, Sawa M, Sayanagi K, Tsujikawa M et al (2009) Macular autofluorescence in eyes with cystoid macula edema, detected with 488 nm-excitation but not with 580 nm-excitation. *Graefes Arch Clin Exp Ophthalmol* 247:729–734
5. Yamamoto M, Kohno T, Shiraki K (2009) Comparison of fundus autofluorescence of age-related macular degeneration between a fundus camera and a confocal scanning laser ophthalmoscope. *Osaka City Med J* 55:19–27
6. Schmitz-Valckenberg S, Fleckenstein M, Gobel AP, Sehmi K, Fitzke FW, Holz FG et al (2008) Evaluation of autofluorescence imaging with the scanning laser ophthalmoscope and the fundus camera in age-related geographic atrophy. *Am J Ophthalmol* 146:183–192
7. Waldstein SM, Hickey D, Mahmud I, Kiire CA, Charbel Issa P, Chong NV (2012) Two-wavelength fundus autofluorescence and macular pigment optical density imaging in diabetic macular oedema. *Eye* 26(8):1078–1085
8. The Age-Related Eye Disease Study Research Group (2001) The age-related eye disease study (AREDS) system for classifying cataracts from photographs: AREDS report no. 4. *Am J Ophthalmol* 131:167–175

9. Wustemeyer H, Jahn C, Nestler A, Barth T, Wolf S (2002) A new instrument for the quantification of macular pigment density: first results in patients with AMD and healthy subjects. *Graefes Arch Clin Exp Ophthalmol* 240:666–671
10. Spaide RF (2003) Fundus autofluorescence and age-related macular degeneration. *Ophthalmology* 110:392–399
11. Fishkin N, Jang YP, Itagaki Y, Sparrow JR, Nakanishi K (2003) A2-rhodopsin: a new fluorophore isolated from photoreceptor outer segments. *Org Biomol Chem* 1:1101–1105
12. Framme C, Schule G, Birngruber R, Roider J, Schutt F, Kopitz J et al (2004) Temperature dependent fluorescence of A2-E, the main fluorescent lipofuscin component in the RPE. *Curr Eye Res* 29:287–291
13. Bui TV, Han Y, Radu RA, Travis GH, Mata NL (2006) Characterization of native retinal fluorophores involved in biosynthesis of A2E and lipofuscin-associated retinopathies. *J Biol Chem* 281:18112–18119
14. Marmorstein AD, Marmorstein LY, Sakaguchi H, Hollyfield JG (2002) Spectral profiling of autofluorescence associated with lipofuscin, Bruch's Membrane, and sub-RPE deposits in normal and AMD eyes. *Invest Ophthalmol Vis Sci* 43:2435–2441
15. Charbel Issa P, Singh MS, Lipinski DM, Chong NV, Delori FC, Bernard AR et al (2012) Optimization of in vivo confocal autofluorescence imaging of the ocular fundus in mice and its application to models of human retinal degeneration. *Invest Ophthalmol Vis Sci* 53:1066–1075