

Trochanteric osteotomy in primary and revision total hip arthroplasty: risk factors for non-union

Karl Wieser · Patrick Zingg · Claudio Dora

Received: 14 September 2011 / Published online: 7 January 2012
© Springer-Verlag 2012

Abstract

Background Trochanteric osteotomies (TO) facilitate exposure and “true hip reconstruction” in complex primary and revision total hip arthroplasty (THA). However, non-union represents a clinically relevant complication. The purpose of the present study was to identify risk factors for trochanteric non-union.

Methods All cases of THA approached by TO during the past 10 years were analyzed with respect to potential risk factors for non-union.

Results In 298 cases complete data were available for analysis. Trochanteric union occurred in 80.5%, fibrous union in 5.4% and non-union 14.1%. Risk factor analysis revealed a four times higher risk for non-union in anterior trochanteric slide osteotomies compared to extended trochanteric osteotomies and a three times higher risk in cemented versus non-cemented stems. Multiple logistic regression analysis revealed patient’s age and use of cement to be independent risk factors for non-union.

Conclusions Femoral cementation and increasing age negatively influence the union of trochanteric osteotomies.

Keywords Trochanteric osteotomy · Non union · Risk factor analysis

Introduction

The use of trochanteric osteotomy (TO) in total hip arthroplasty (THA) was initially advocated by Sir John Charnley

[1, 2], who believed that this approach helped to facilitate access to the joint, achieve correct alignment of the prosthetic components, permit the ability to favorably influence the abductor lever arm, and thereby perform a true “hip reconstruction” rather than simple replacement of articular surfaces.

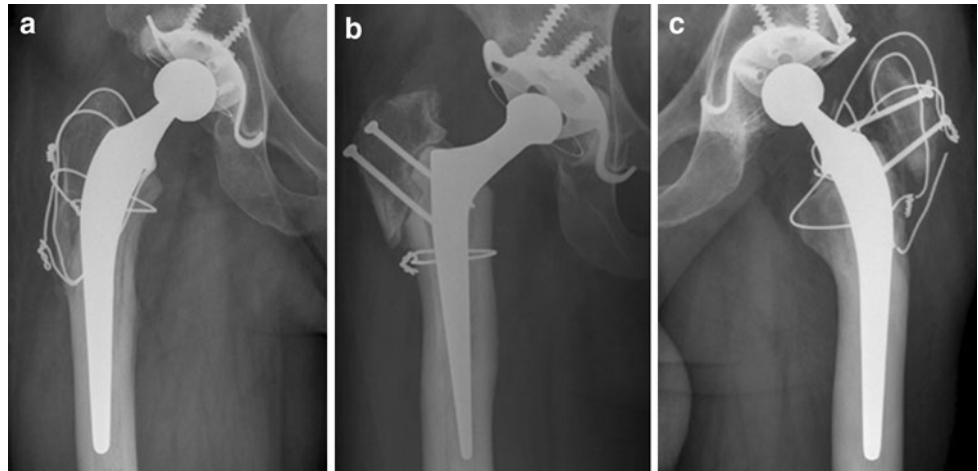
Due to prolonged surgical time, increased blood loss, wire-related bursitis [3, 4] and the rate of non-union ranging from 0 to 37.5% [2, 5–12], the utilization of TO has declined and is no longer a standard procedure in primary THA.

Nevertheless, in order to facilitate dislocation and exposure, TO or modifications of it, may still be used in cases of ankylosis or fusion, severe protrusio acetabuli, proximal femoral deformities and severe developmental dysplasia. In revision THA, TO might be useful for removal of cemented or non-cemented well-fixed femoral components, in cases of difficult acetabular exposure, or severe varus remodeling of the proximal femur.

Shortcomings of the standard single plane trochanteric osteotomy, have lead to many modifications, particularly the anterior trochanteric slide osteotomy (ATSO) [13, 14] and the extended trochanteric osteotomy (ETO) [15, 16]. Both are modifications of Charnley’s traditional osteotomy, which facilitates excellent exposure of the hip while preserving the hip abductors and vastus lateralis musculature in continuity. The vastus is thought to counteract the pull of the abductors in coronal plane, stabilizing the osteotomized trochanter by creating compressive forces and avoiding proximal migration if a non-union develops [17–20]. A three-dimensional biomechanical model of the hip musculature has shown that in the flexed hip, the gluteus medius is primarily an internal rotator and secondarily a flexor and abductor [21]. Previous clinical reports highlight this, showing that the displacement forces on the trochanteric

K. Wieser (✉) · P. Zingg · C. Dora
Department of Orthopaedics, University of Zurich,
Balgrist Hospital, Forchstrasse 340, CH 8008 Zurich, Switzerland
e-mail: karl.wieser@balgrist.ch

Fig. 1 Rating of trochanteric union: **a** bony union, **b** fibrous union and **c** non-union



fragment are a combination of abduction and anteriorly oriented forces [22], and that the vastus lateralis in fact does counteract the proximally directed forces.

Over the last 10 years, both the ATO and ETO have been adopted and occasionally used for complex primary THA and revisions in our institution. However, we observed that these were associated with non-unions in some cases. It was our anecdotic impression that patient-related factors such as age and nicotine use, as well as technical factors such as use of cemented stems, potentially negatively impact the union rate of our TO. Hence it was our aim to review all our primary and revision THA's approached through a trochanteric osteotomy in order to identify possible risk factors for non-union.

Materials and methods

Our prospectively collected database on THA was retrospectively searched for primary and revision THA approached by trochanteric osteotomy between January 2000 and October 2009.

From all cases the following information was recorded from patient's charts: (1) patient related factors such as gender, age, body mass index (BMI), and nicotine use; (2) indication for THA; (3) surgical technique related factors such as type of femoral component, femoral side cementation, distal trochanteric advancement, type of TO and fixation-technique; (4) patient's surgical history such as previous TO (healed or not healed), and cementation of a previous femoral component and (5) occurrence of intraoperative and postoperative complications.

Based on a general permit issued by the responsible state agency, our institutional review board allows retrospective analysis of patient data relating to standard diagnostic or therapeutic procedures without individual informed consent.

Trochanteric union was analyzed by one orthopedic surgeon on anteroposterior and axial (cross-table lateral) X-rays 6 weeks, 3 and 6 months postoperatively and rated as follows [10, 11, 13, 17]: (a) bony union, if there was continuity of bone trabeculae between the trochanter fragment and the site of attachment, (b) fibrous union, if a continuous radiolucent line between the trochanter fragment and the site of attachment was present with migration less than <math><15\text{ mm}</math> and (c) non-union, if more than 15 mm migration of the greater trochanter was measured (see Fig. 1). The initial postoperative X-rays served as a baseline to which all subsequent radiographs were compared.

Statistical analyses were performed by an independent biostatistician. Since patients had observations either on both hips and/or repeatedly on the same hip, we looked at clustered data and accounted this clustering. For binary responses, generalized linear marginal models for clustered data were computed, each including the variable of interest and side. By including side we adjusted for this variable and checked whether there was any influence based on the side. The significance of all factors on influencing non-union of the trochanteric osteotomy was statistically verified. All tests were performed at a significance level of $\alpha = 0.05$ and confidence intervals were computed at a level of 95%.

In order to adjust for possible confounding, a multiple logistic regression model was used, again using the generalized linear marginal model method. Because the model became unstable if all variables were considered, we omitted variables which had observations only in a limited group of patients from multiple logistic regression model analysis.

External funding

There was no external funding for the purpose of this study.

Table 1 Indications for trochanteric osteotomy

	<i>n</i>
Primary	130
Severe developmental dysplastic hips	63
Post perthes with high riding greater trochanter	7
After intertrochanteric osteotomy in slipped capital femoral epiphysis	5
Hip ankylosis after childhood septic arthritis	12
Posttraumatic disturbed anatomy	23
Primary osteoarthritis with severe varus morphology	16
Avascular necrosis	4
Revision	168
Aseptic loosening	93
Acetabular component revision	(22)
Femoral component revision	(12)
Total revision arthroplasty	(59)
Septic	61
Instability	14
Acetabular component revision	(8)
Femoral component revision	(2)
Total revision arthroplasty	(4)

Results

From 3,067 THA (2,400 primary and 667 revisions) performed between January 2000 and October 2009, 338 (11%) were approached through a TO in 310 patients. Forty TO were excluded from this investigation because of the following reasons: 11 patients were deceased (mean 17 months after index procedure, SD 20, range 0–49) and had no

follow-up X-rays, 10 patients were lost shortly after the index surgery and could not be located, 14 patients refused follow-up X-rays but had not had subsequent surgery, and 5 patients had early revisions due to other prosthetic complications (mean 2.8 months after index surgery, SD 2.1, range 1–5) (2 recurrent hip dislocations; 1 periprosthetic fracture; 1 aseptic loosening; 1 acute periprosthetic infection).

From the remaining 270 patients, 21 had THA approached by TO on both sides and 7 had repeated THA approached by TO on the same side resulting in 298 TO available for evaluation. There were 143 females and 127 males. Average age was 58 years (SD 16, range 17–89) and BMI 26.2 (SD 5, range 15–43). Nicotine use was encountered in 84 patients.

An anterior trochanteric slide osteotomy was performed in 247 cases (126 complex primary THA and 121 revision THA) and an extended trochanteric osteotomy in 51 cases (4 complex primary THA and 47 revisions THA). Indications are summarized in Table 1.

In 195 hips a cemented femoral stem fixation technique and in 103 a non-cemented fixation technique were used. In 90 cases distal advancement of the trochanteric fragment was performed.

In 75 hips a pre-existing TO was present, which showed non-union in 28 of them. In 60 of the 166 revision THA the previous femoral component was cemented.

The technique of fixation of the greater trochanter was performed using four different methods which were chosen by the operating surgeon according to the intraoperative estimation of stability and biology. Techniques are summarized in Fig. 2 and Table 2. The postoperative regime in all patients included abduction pillows and restricted weight bearing of 15 kg with crutches or a walker for 8–12 weeks.

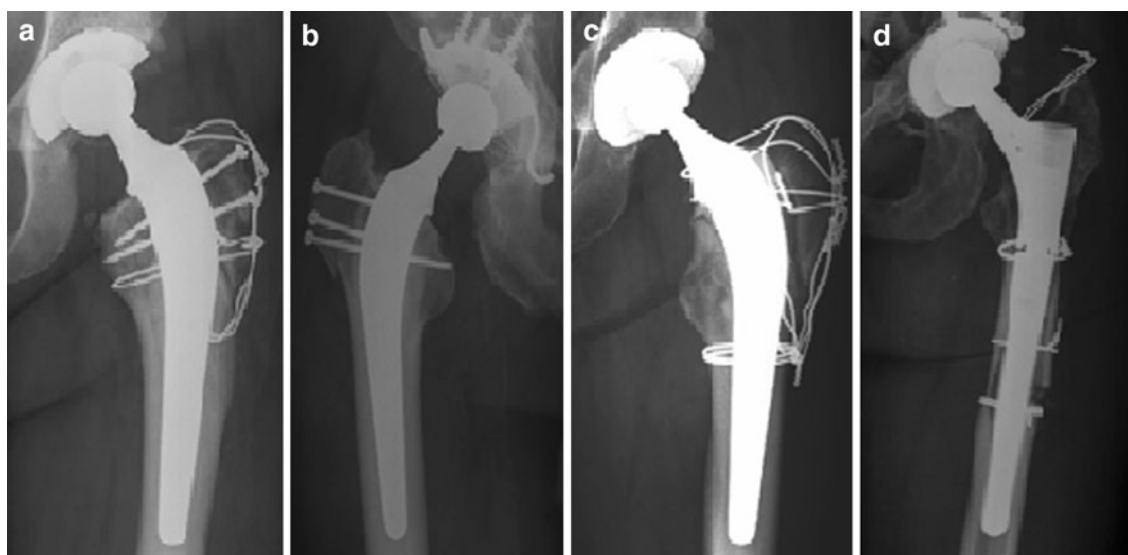


Fig. 2 Fixation of trochanteric osteotomy: **a** wires and screws, **b** screws only, **c** circular and longitudinal wires, **d** circular wires only

Table 2 Fixation technique of the greater trochanter

	ATSO	ETO	Total
1.5-mm circular wires and 3.5-mm screws	25	1	26
3.5-mm screws only	41	1	42
1.5-mm circular and vertical wires	171	13	183
1.5-mm circular wires only	10	36	46

Index surgery was complicated by a fracture of the trochanter fragment in two cases (1 ASTO, 1 ETO) making additional fixation necessary. In both cases the fracture and the osteotomy healed uneventfully. Hip dislocation complicated the postoperative course in 12 cases (4%). In 5 of them non-union of the TO occurred but it remained indeterminate if dislocation was favoured by pre-existing non-union or vice versa. We therefore did not analyze dislocation as a risk factor for non-union. No additional complications were encountered.

After a minimum radiological follow-up of 6 months (mean 28.5, SD 22, range 6–116) bony union of the trochanter occurred in 240 hips (80.5%), fibrous union in 16

hips (5.4%) and non-union in 42 hips (14.1%). The rate of non-unions in different subgroups is summarized in Figs. 3 and 4. Surgical revision because of non-union was performed in 20 cases (6.7%). In addition, 49 cases (16.4%) underwent hardware removal.

Risk factor analysis for non-union using a linear marginal model is summarized in Table 3 and revealed that ATSO (non-union rate: 40/247, 16.2%) bears a four times higher risk (odds 4.25; *p* value 0.037) for non-union than ETSO (non-union rate: 2/51, 3.9%) and cementation of the stem (non-union rate: 35/195, 17.9%) a three times higher risk (odds 3; *p* value 0.01) than using non-cemented stems (non-union rate: 7/103, 6.8%). Stem cementation in a previous surgery showed a similar trend (non-union rate: 21.7 vs. 12.3%) but was statistically not significant (odds 1.9; *p* value 0.13). In addition, each additional year of patient’s age showed to increase the population’s averaged odds ratio for non-union by factor 1.028 (*p* value 0.016). Due to small numbers and few events (non-union) in respective subgroups, testing parameters such as indication for THA, fixation technique of the TO and femoral component designs were not valid. All other analyzed factors (gender,

Fig. 3 Proportion of non-unions in different subgroups of patients

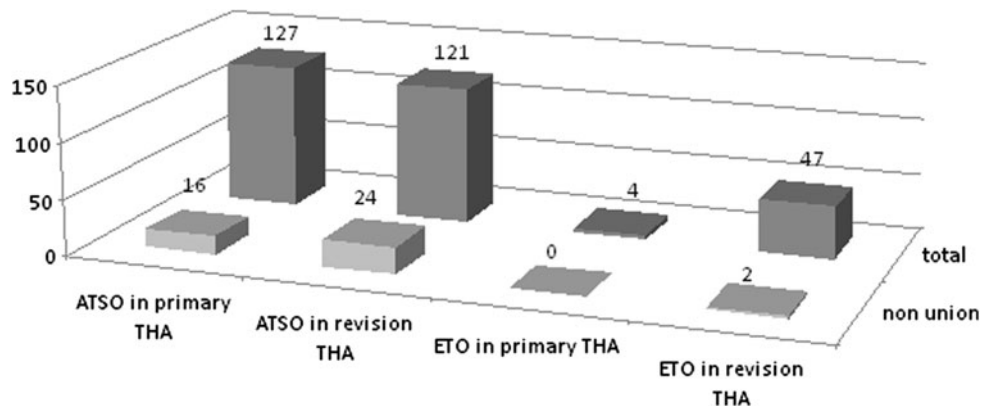


Fig. 4 Proportion of non-union in different subgroups of patients in relation to cemented and non-cemented stems

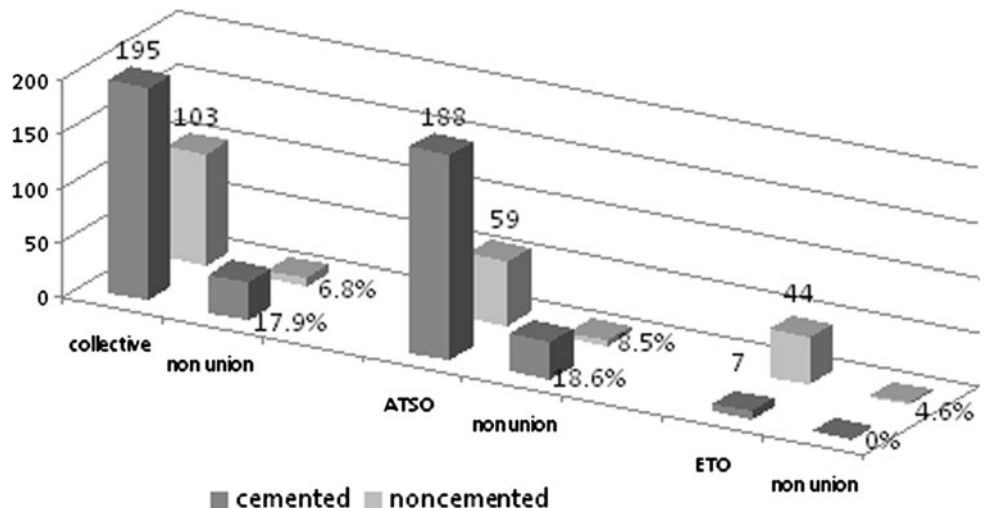


Table 3 Study group analysis (linear marginal model)

Variable	Level	<i>n</i>	Non union	<i>p</i> value global	<i>p</i> value side	Odds ratio	95% CI	<i>p</i> value
Gender	Female	159	21	0.57	0.27	1.2	[0.63, 2.27]	0.57
	Male	139	21					
Nicotine	No	211	32	0.45	0.27	0.75	[0.36, 1.57]	0.45
	Yes	84	10					
	Missing data	3	0					
THA	Primary	130	16	0.45	0.26	1.29	[0.67, 2.51]	0.45
	Revision	168	26					
Trochanteric osteotomy	ATSO	247	40	0.037	0.3	4.25	[1.09, 16.57]	0.037
	ETO	51	2					
Trochanter distalisation	No	208	32	0.3	0.31	0.669	[0.31, 1.44]	0.3
	Yes	90	10					
Femoral component	Non-cemented	103	7	0.01	0.26	3	[1.30, 6.93]	0.01
	Cemented	195	35					
Previous femoral component	Non-cemented	108	13	0.13	0.15	1.9	[0.83, 4.35]	0.13
	Cemented	60	13					
	Missing data (prim. THA)	130						
Previous TO	No	233	29	0.43	0.28	1.33	[0.65, 2.74]	0.43
	Yes	75	13					
Previous TO	Healed	34	5	0.38	0.29	1.12	[0.40, 3.18]	0.82
	Not healed	28	7					
	Not judgeable	13	1					

Table 4 Study group analysis (results for nominal variables)

Variable	<i>n</i>	# response	<i>p</i> value side	Odds ratio	95% CI	<i>p</i> value
Age	298	42	0.32	1.028	[1.01, 1.05]	0.016
BMI	265	37	0.62	0.957	[0.89, 1.03]	0.21

BMI, nicotine, primary- or revision THA, distal advancement of the trochanter, and previous TO) did not turn out to be a significant factor for non-union.

Multiple logistic regression analysis is summarized in Table 4 and identified age (odds ratio 1.03; *p* value 0.0061) and cementation of the femoral component (odds ratio 3.03; *p* value 0.02) to be the only independent risk factors of non-union. Previous TO and cementation of previous femoral components were not included in the multiple logistic regression model, because these values were not available in all TO making the multiple logistic regression model unstable.

Discussion

During the past 10 years 11% of our primary and revision THA were approached by a trochanteric osteotomy. This rather high proportion might be explained by the fact that,

being a former institute for crippled children, there is high proportion of patients treated at our centre with osteoarthritis secondary to pediatric hip disease with severe deformities, many of which have had previous pelvic and/or femoral osteotomies.

Although most orthopedic surgeons nowadays prefer other less invasive approaches in routine primary THAs, the trochanteric osteotomy remains an effective and safe approach in certain instances, particularly revision surgery [23–25], or severe hip dysplasia [26, 27].

Even if only 6.7% of patients required surgical revision because of a trochanteric non-union, our reported non-union rate of 14.1% was high. The lower revision rate may be considered an advantage of preserving the vastus lateralis muscle in continuity with the abductor muscles, thus counteracting dislocating forces and avoiding gross trochanteric displacement and poor function. A positive correlation between the amount of separation and hip abductor weakness has been demonstrated by Amstutz [6], especially if it exceeds 2 cm.

Nevertheless, the high non-union rate justifies efforts to identify risk factors for non-union. Patient's age was the only, but very moderate patient-related risk factor for non-union in the present series; each additional year of age increased the risk for non-union by 1.028. Unfortunately, in our collective series we did not analyse the bone quality of the trochanteric bed, with regards to osteopenia or osteoporosis. This, however, has been reported to influence union rates by others [6] and may explain the effect of age found in our investigation. Other patient-related factors such as a pre-existing trochanteric osteotomy did not negatively influence the union rate and is in keeping with Lakestein's [28] study comparing repeated osteotomies with a matched control group without previous osteotomies.

Astonishingly, despite a number of 84 patients with nicotine use, the latter was not identified as a risk factor for non-union in our investigation. This is in contrast with other investigations showing nicotine use to negatively influence the bony healing [29].

Among technical factors, the use of cement on the femoral side clearly was identified as a risk factor for non-union. It is known that temperatures over 56°C lead to coagulation of protein and cell necrosis [30] and that polymerization temperature of bone cement can reach temperatures over 120°C. PALACOS (Zimmer, Warsaw, IN, USA) reached a temperature of 108 in an in vitro study, where the authors came to the conclusion that bone cement which is put in living tissues, must lead to thermo-necrosis [31]. The effect of compromising the trochanteric bed by extrusion of pressurized cement in the cancellous bone is repeatedly [6, 18, 32, 33] mentioned in the literature but has never been identified as an independent risk factor for non-union.

Compared to the ETO, the ATSO had a significantly higher non-union rate in the linear marginal model, however, this significance disappeared in the multiple logistic regression model, indicating that the ATSO is not an independent risk factor. The most likely explanation of this finding is that cemented femoral components were much more frequently used in ATSO than in ETO (Fig. 4) confounding results using the linear marginal model.

The present investigation has several limitations. First, radiographs were evaluated by a single observer. However, in any case of doubt the senior author was consulted. Second, it would have been preferable to test all variables in a multiple logistic regression model. However, this was not possible because at least ten times as many events (non-unions) as variables are required for a meaningful analysis. Therefore, parameters such as indication for THA, fixation techniques of the TO and femoral component designs, showing no significant influence in a pre-test analysis, were not valid in the multiple regression analysis due to our sample size and parameters analyzed. In addition, screw fixations were used in some of our TO. According to

Kampshoff et al. [34] bicortical screw insertion may cause cracks in the periprosthetic cement mantel, which eventually induces loosening of the construct. According to Bowmann et al. [35] not only the amount of weight bearing but also gait speed relevantly influences forces acting on the joint and thus on the osteotomy. However, patient's compliance remains an unknown influencing factor for trochanteric non-union.

Finally, we defined non-union of the greater trochanter as primary outcome measure and did not monitor the clinical impact of either non-union or fibrous union. However, several other reports show that fibrous union is often without relevant clinical significance [2, 8, 17, 36].

Despite these limitations, we conclude that femoral cementation and older age negatively influence union of trochanteric osteotomies. Our findings have changed our current practice as we now restrict the use of trochanteric osteotomies in older patients if possible. In addition, our priority is now to use non-cemented femoral reconstructions in cases where a trochanteric osteotomy appears unavoidable for adequate reconstructions in complex primary and revision THA.

References

1. Charnley J (1970) Total hip replacement by low-friction arthroplasty. *Clin Orthop Relat Res* 72:7–21
2. Charnley J (1972) The long-term results of low-friction arthroplasty of the hip performed as a primary intervention. *J Bone Joint Surg Br* 54(1):61–76
3. Wiesman HJ Jr, Simon SR, Ewald FC, Thomas WH, Sledge CB (1978) Total hip replacement with and without osteotomy of the greater trochanter. Clinical and biomechanical comparisons in the same patients. *J Bone Joint Surg Am* 60(2):203–210
4. Mallory TH (1974) Total hip replacement with and without trochanteric osteotomy. *Clin Orthop Relat Res* 103:133–135
5. Teanby DN, Monsell FP, Goel R, Faux JC, Hardy SK (1996) Failure of trochanteric osteotomy in total hip replacement: a comparison of two methods of reattachment. *Ann R Coll Surg Engl* 78(1):43–44
6. Amstutz HC, Maki S (1978) Complications of trochanteric osteotomy in total hip replacement. *J Bone Joint Surg Am* 60(2):214–216
7. Harris WH, Crothers OD (1978) Reattachment of the greater trochanter in total hip-replacement arthroplasty. A new technique. *J Bone Joint Surg Am* 60(2):211–213
8. Dall DM, Miles AW (1983) Re-attachment of the greater trochanter. The use of the trochanter cable-grip system. *J Bone Joint Surg Br* 65(1):55–59
9. Ritter MA, Eizember LE, Keating EM, Faris PM (1991) Trochanteric fixation by cable grip in hip replacement. *J Bone Joint Surg Br* 73(4):580–581
10. Wroblewski BM, Shelley P (1985) Reattachment of the greater trochanter after hip replacement. *J Bone Joint Surg Br* 67(5):736–740
11. Gottschalk FA, Morein G, Weber F (1988) Effect of the position of the greater trochanter on the rate of union after trochanteric osteotomy for total hip arthroplasty. *J Arthroplast* 3(3):235–240

12. Bal BS, Maurer BT, Harris WH (1998) Trochanteric union following revision total hip arthroplasty. *J Arthroplast* 13(1):29–33
13. English TA (1975) The trochanteric approach to the hip for prosthetic replacement. *J Bone Joint Surg Am* 57(8):1128–1133
14. Glassman AH, Engh CA, Bobyn JD (1987) A technique of extensile exposure for total hip arthroplasty. *J Arthroplast* 2(1):11–21
15. Peters PC, Head WC, Emerson RH (1993) An extended trochanteric osteotomy for revision total hip replacement. *J Bone Joint Surg Br* 75(1):158–159
16. Younger TI, Bradford MS, Magnus RE, Paprosky WG (1995) Extended proximal femoral osteotomy. A new technique for femoral revision arthroplasty. *J Arthroplast* 10(3):329–338
17. Nicholson P, Mulcahy D, Fenelon G (2001) Trochanteric union in revision hip arthroplasty. *J Arthroplast* 16(1):65–69
18. Archibeck MJ, Rosenberg AG, Berger RA, Silverton CD (2003) Trochanteric osteotomy and fixation during total hip arthroplasty. *J Am Acad Orthop Surg* 11(3):163–173
19. McGrory BJ, Bal BS, Harris WH (1996) Trochanteric osteotomy for total hip arthroplasty: six variations and indications for their use. *J Am Acad Orthop Surg* 4(5):258–267
20. Plausinis D, Haddad FS, Oxland TR, Duncan CP (2001) Trochanteric slide osteotomy: biomechanical considerations. *Instr Course Lect* 50:247–252
21. Dostal WF, Andrews JG (1981) A three-dimensional biomechanical model of hip musculature. *J Biomech* 14(11):803–812
22. Charnley J (1979) *Low friction arthroplasty of the hip*. Springer, New York
23. Lim SJ, Moon YW, Park YS (2011) Is Extended trochanteric osteotomy safe for use in 2-stage revision of periprosthetic hip infection? *J Arthroplasty* 26(7):1067–1071
24. Stuchin SA, Millman JS (2011) Oblique posterior trochanteric osteotomy in revision total hip arthroplasty. *J Arthroplast* 26(3):472–475
25. Lakstein D, Kosashvili Y, Backstein D, Safir O, Gross AE (2010) Modified extended trochanteric osteotomy with preservation of posterior structures. *Hip Int* 20(1):102–108
26. Hartofilakidis G, Babis GC, Georgiades G, Kourlaba G (2011) Trochanteric osteotomy in total hip replacement for congenital hip disease. *J Bone Joint Surg Br* 93(5):601–607
27. Van der Grinten M, Reijman M, Van Biezen FC, Verhaar JA (2011) Trochanteric osteotomy versus posterolateral approach: function the first year post surgery. A pilot study. *BMC Musculoskelet Disord* 12:138
28. Lakstein D, Kosashvili Y, Backstein D, Safir O, Gross AE (2010) Trochanteric slide osteotomy on previously osteotomized greater trochanters. *Clin Orthop Relat Res* 468(6):1630–1634
29. Sloan A, Hussain I, Maqsood M, Eremin O, El-Sheemy M (2010) The effects of smoking on fracture healing. *Surgeon* 8(2):111–116
30. Lehnartz E (1959) *Chemische physiologie*. Springer, Berlin-Göttingen-Heidelberg
31. Hupfauer W, Ulatowski L (1975) The temperature evolution of different bone cements during polymerisation. *AOTS* 72(2):174–184
32. Hellman EJ, Capello WN, Feinberg JR (1998) Nonunion of extended trochanteric osteotomies in impaction grafting femoral revisions. *J Arthroplast* 13(8):945–949
33. Bal BS, Kazmier P, Burd T, Aletto T (2006) Anterior trochanteric slide osteotomy for primary total hip arthroplasty. Review of nonunion and complications. *J Arthroplast* 21(1):59–63
34. Kampshoff J, Stoffel KK, Yates PJ, Erhardt JB, Kuster MS (2009) The treatment of periprosthetic fractures with locking plates: effect of drill and screw type on cement mantles: a biomechanical analysis. *AOTS* 130(5):627–632
35. Bowman KF Jr, Fox J, Sekiya JK (2010) A clinically relevant review of hip biomechanics. *Arthroscopy* 26(8):1118–1129
36. Charnley J, Cupic Z (1973) The nine and ten year results of low-friction arthroplasty of the hip. *Clin Orthop Relat Res* 95:9–25