

U. Berlemann  
P. Heini  
U. Müller  
C. Stoupis  
O. Schwarzenbach

## Reliability of pedicle screw assessment utilizing plain radiographs versus CT reconstruction

Received: 12 March 1997  
Revised: 31 May 1997  
Accepted: 24 June 1997

U. Berlemann (✉) · P. Heini · U. Müller  
O. Schwarzenbach  
Department of Orthopaedic Surgery,  
Inselspital, University of Bern,  
Freiburgstrasse, CH-3010 Bern,  
Switzerland  
Tel. +41-31-632 2111;  
Fax +41-31-632-3600

C. Stoupis  
Department of Diagnostic Radiology,  
Inselspital, University of Bern, Bern,  
Switzerland

**Abstract** The position of 119 pedicle screws was assessed on plain antero-posterior and lateral radiographs taken immediately post-operatively and at 3 months' follow-up. The readings of five independent observers were compared with the "gold standard" of CT reconstructions. The position of only 41% of implants (range 14%–56%) was assessed correctly on the plain radiographs (47% on follow-up films). Two-thirds of CT-detectable perforations were missed. As shown with

perforations of the anterior cortex, detectability increased significantly with magnitude of perforation. No specifically difficult anatomic level or direction of malplacement could be identified. Interobserver variation was considerable. Plain radiographs were shown to be of limited use in assessing the position of pedicle screws.

**Key words** Pedicle screw · Placement · Accuracy · Plain radiographs · CT reconstruction

### Introduction

Transpedicular screw fixation of spinal segments has gained widespread acceptance over the last years for various indications including spondylosis, degenerative disc disease, segmental instability, fracture, and others. Previous studies investigating complications of this technique have outlined the importance of properly placed screws with respect to the pedicle and the anterior vertebral cortex. Accurate localization of the intraosseous position is essential to facilitate improvement of pedicle-screw-insertion aids and techniques. Intra-operative image intensification and post-operative plain radiographs are currently the standard. However, previous studies have questioned the accuracy of conventional imaging techniques when compared to CT [3, 5] or in vitro investigation of specimens [18]. Differences between observers may also be considerable [3]. This study was designed to investigate the accuracy of assessment of pedicle screw position on plain radiographs. Specific attention was focused on the inter- and intra-observer reliability as well as on the deter-

mination of vertebral levels and screw directions, which may be particularly difficult to assess.

### Materials and methods

Twenty-one patients undergoing posterior transpedicular stabilization for spondylosis with degenerative disc disease (18 cases), stenosis of the spinal canal (2 cases) and tumor instability (1 case) were included in the study. The position of 119 USS titanium pedicle screws was assessed. The implants were predominantly inserted in the lower lumbar and lumbosacral area (L4: 35 screws, L5: 32, S1: 28); however, other levels were also included (L3: 16, L2: 2, T12: 4). Following a standard midline approach a computer-assisted image guidance system was utilized as the only visualization aid for the insertion of 105 screws [1, 11]. Fourteen screws were inserted conventionally under fluoroscopic control. All patients involved underwent a post-operative CT investigation to assess the position of the pedicle screws accurately [14]. Conventional antero-posterior and lateral radiographs were obtained immediately post-operatively for all patients and again after a 3-month follow-up for 18 patients (106 screws). During this period none of the patients had to be revised for any implant-related problems. No post-operative neurological deficit occurred. Three patients were subsequently lost for follow-up.

**Table 1** Screw perforations as detected by CT reconstruction (*upper line*) and by post-operative radiograph (different observers, *lower line*)

	0–2 mm	2–4 mm	4–6 mm	> 6 mm	Total
Medial	2 0/0/0/0/2	3 0/0/0/0/0	–	–	5 0/0/0/0/2
Lateral	6 0/0/1/0/0	2 0/0/1/0/0	1 0/0/1/0/0	–	9 0/0/3/0/0
Superior	–	–	–	–	–
Inferior	1 0/0/0/0/1	–	–	–	1 0/0/0/0/1
Anterior	30 7/2/6/15/4	19 10/4/9/13/9	12 9/5/9/10/7	4 3/3/4/4/2	65 29/13/28/42/22
Total					80 29/13/31/42/25

Plain radiographs were evaluated by five independent observers including an experienced spine surgeon, a spine fellow, a neuroradiologist, and two orthopedic residents. The observers were asked to assess the position of the pedicle screw in five directions: “medial, lateral, superior, and inferior” with respect to the pedicular cortex and “anterior” with respect to the anterior cortex of the vertebral body. Apparent violation of the cortical bone in any of these directions was to be noted. Cortical perforations were graded in 2-mm increments according to Gertzbein and Robbins [6]. If a cortical perforation was questionable the observers were asked to include the screw in the “0–2 mm” perforation group. Post-operative and follow-up radiographs were assessed independently. All observations were made in a blinded fashion, without knowledge of the readings made by other observers or the findings on CT.

The assessments were subsequently compared with the results of the post-operative CT scans. These had been previously analyzed by two independent observers who had to come to a common conclusion concerning the screw positions. According to this “gold standard”, the readings of the five observers in this study were rated into one of four categories for all mentioned orientations:

*True-positive*: screw was assessed “out” on radiograph and CT

*True-negative*: screw was assessed “in” on radiograph and CT

*False-positive*: screw was assessed “out” on radiograph, but “in” on CT

*False-negative*: screw was assessed “in” on radiograph, but “out” on CT

## Results

### CT reconstructions

On CT reconstructions 14 pedicle cortex violations in the transverse plane were detected, 9 of them lateral (Table 1). One screw perforated the pedicle inferiorly. The rate of screws perforating the pedicle by more than 2 mm was 5%. In only one case was the pedicular cortex penetrated by more than 4 mm.

Anteriorly 65 violations of the vertebral cortex were observed (54.6% of all screws). Thirty-five screw tips were located more than 2 mm out of the vertebral body.

### Plain radiographs

The observer’s readings of the plain radiographs are summarized in Table 2. The number of screws found to perfo-

**Table 2** Screw perforations as detected on post-operative radiographs (*upper line*) and follow-up radiographs (*lower line*). Second number indicates the screws with perforation > 4 mm. (Observer 1: spine surgeon; observer 2: resident; observer 3: resident; observer 4: spine fellow; observer 5: neuroradiologist)

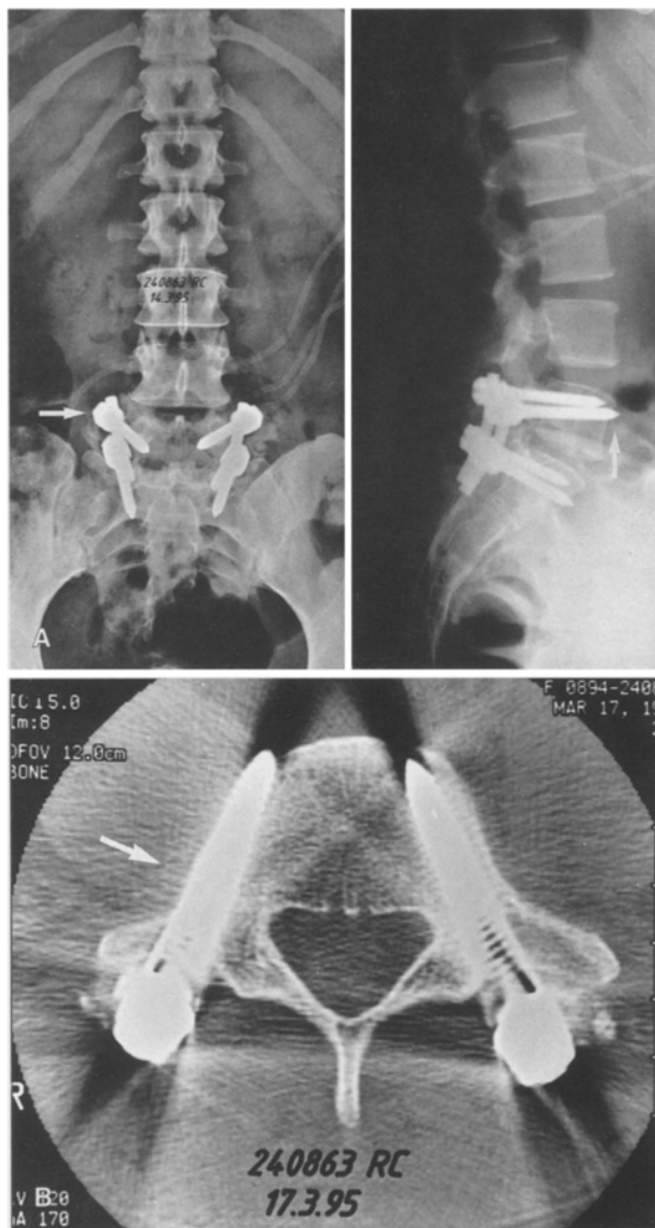
	Medial	Lateral	Superior	Inferior	Anterior	Total
Obs 1	–	3/–	1/–	4/–	33/6	41/6
	–	1/–	2/2	2/1	25/3	30/6
Obs 2	1/–	–	–	6/1	23/6	30/7
	–	–	1/–	1/–	20/6	22/6
Obs 3	1/–	18/1	5/–	16/1	35/5	75/7
	–	5/–	4/1	5/–	20/2	34/3
Obs 4	–	–	–	8/2	41/5	49/7
	–	–	4/–	2/2	35/2	41/4
Obs 5	35/1	2/–	22/–	34/1	33/3	126/5
	44/–	–	23/2	31/–	42/–	140/2

rate cortical bone varied considerably amongst the different observers. Only a small proportion of perforations were thought to be of a magnitude greater than 4 mm. More perforations were seen on the post-operative films.

Amongst all observers, 16 screws were assessed equivalently. All others were rated differently in at least one direction by at least one observer. One single observer assessed 61.5% of screws (range 34%–76.4%) the same on both the post-operative and the follow-up films; 30.7% of screws (range 20.8%–41.5%) were rated differently in one direction; 5.8% (range 0.9%–16.0%) in two; and 1.9% (range 0%–8.5%) in three.

### Correct assessments

Overall, 84.7% (range 73.8%–90.4%) of the readings were correct, i.e. true-positive or true-negative, on the post-operative and 86.0% (range 72.8%–90.4%) on the follow-up films (Table 3). This difference was not statistically significant ( $P = 0.13$ ). On the post-operative films, 40.8% of implants were assessed correctly in all directions (range 14.3%–56.3%) and on the follow-up films



**Fig. 1** A Antero-posterior and lateral plain radiographs and B L5 CT scan slice of a patient having undergone monosegmental L5-S1 posterior stabilization. Four of the five observers did not recognize the lateral perforation of the left L5 screw (arrow) but four out of five saw the perforation of the anterior cortex. Interestingly, at the level below (S1) the left screw tip was thought to be not perforating by two observers

47% (range 17.9%–60.4%) (Table 4). Under the hypothesis of a higher accuracy on the follow-up films a one-tailed *t*-test analysis was used. This showed that follow-up films provided a significantly higher precision of implant assessment than immediate post-operative films ( $P < 0.03$ ).

Perforations, as observed on the CT reconstructions, were recognized in 35.6% of cases (range 17.5%–53.3%)

**Table 3** Percentage of correct reading of all five assessed directions (*pos* perforations, *neg* bony integrity)

		Post-op	Follow-up
Obs 1	Total	89.4	90.2
	Pos	36.3	34.9
	Neg	97.7	98.5
Obs 2	Total	85.9	87.7
	Pos	17.5	18.8
	Neg	96.5	98.0
Obs 3	Total	84.2	89.0
	Pos	38.8	31.9
	Neg	91.3	97.6
Obs 4	Total	90.4	90.4
	Pos	53.3	42.0
	Neg	96.0	97.6
Obs 5	Total	73.8	72.8
	Pos	32.5	49.3
	Neg	80.2	76.4

**Table 4** Percentage of screws that were assessed correctly in all five directions

	Post-op	Follow-up
Obs 1	56.3	57.5
Obs 2	37.8	45.3
Obs 3	39.5	53.8
Obs 4	56.1	60.4
Obs 5	14.3	17.9

on the post-operative plain radiographs. The corresponding figure of these true-positive findings on the follow-up films was 35.4% (range 18.8%–49.3%). Neither the direction of malplacement nor the vertebral level correlated with the accuracy of assessment.

Screw tips violating the anterior vertebral cortex were recognized in 22.7% of plain radiographs (range 6.7%–50%) when perforations were 2 mm or less. The rate of detection increased to 47.4% (range 21.1%–68.4%) with perforations between 2 and 4 mm, 66.7% (range 41.7%–83.3%) with perforations between 4 and 6 mm, and 80% (range 50%–100%) with perforations of more than 6 mm. A highly significant correlation between the magnitude of perforation and its detectability was shown ( $r^2 = 0.9826$ ; corresponding  $P < 0.01$ ).

## Discussion

### Value of CT reconstruction

The importance of pre-operative CT scanning for the analysis of pedicle morphology is doubtless. Good correlation has been shown between CT scans and direct macroscopic findings in *in vitro* studies [3, 8, 10]. The determination of the transverse pedicle angulation and the

selection of the appropriate screw diameters are thereby of particular interest [2, 12].

Post-operative CT investigations have been performed to assess malplacement rates for pedicle screws with the implant in situ [3, 6, 12]. These studies and further comparisons with in vitro specimens have shown that CT scanning is a reliable tool to document pedicle screw position. Our study therefore did not further analyze or question the CT readings. Occasionally, however, pedicular integrity assessment may be difficult owing to artifacts around stainless steel implants. Accordingly, some authors have investigated the bony structures after metal removal [7, 15]. In the present study only titanium screws have been analyzed to minimize the effects of scatter artifacts. Nevertheless, some screws in this study with a "0 to 2-mm perforation" should be regarded as only questionably "out". In these cases the integrity of the cortical bone could not be determined conclusively either owing to rest artifacts or very small pedicles. However, the clinical significance of such minimal perforations seems also somewhat questionable.

#### Malplacement rate on CT reconstructions

This study is characterized by a small number of malplacements, with only one screw (0.8%) violating the pedicular cortex by more than 4 mm. The 4-mm range is of special interest, as a canal encroachment by this margin has been regarded as tolerable due to the "safe zone" of epidural and subarachnoidal space [6]. Other CT-based studies have reported rates of medial displacement by more than 4 mm of between 6.6% and 10.6% [3, 6]. The improved accuracy in our study is primarily due to computer-assisted visualization of the pedicle canal preparation [1, 14]. Accordingly, for the purpose of the present study, a selection bias may have been introduced, the low perforation rate decreasing the change of a "true-positive" or "false-negative" finding.

The perforation rate of the anterior vertebral cortex in our study was 54.6%. This may be ascribed to the fact that 28 screws were placed in S1, where the anterior cortical bone is intentionally engaged. Biomechanical studies have shown that purchase of the anterior sacral cortex can increase the pull-out strength of the screw by up to 60% [18]. The relatively high perforation rate at other levels, however, reflects the fact that computer assistance at this stage may be less accurate in determining the precise depth of canal preparation [1].

#### Comparison of accuracy on conventional radiographs and CT

For intra-operative assessment, routine antero-posterior radiographs have been shown unreliable in defining pedicle screw position [17]. Accordingly, oblique images along the pedicle axis have been proposed to increase accuracy [16]. Leach et al. [9] found that 45° of oblique films did

not supply any additional information. Shallow oblique films were regarded as more useful as they approximate more closely the transverse pedicle axis.

Additional studies have used post-operative conventional radiographs for accuracy assessment. The malplacement rates reported in these studies were between 5% and 10% and appeared to be underestimating when compared to CT scan assessments [4, 13]. Our study confirms these findings. Only one-third of all CT-detectable perforations were recognized on the plain films (true-positive findings). Farber et al. [5] found that screws with medial penetration were difficult to identify on plain radiographs. Three of our observers found between none and three screws perforating the pedicular cortex in the transverse plane (Table 1). In addition, these screws were all different than those 14 actually injuring the pedicle cortex according to the CT reconstructions. Furthermore, it appears quite difficult to assess correctly the magnitude of cortical perforation. Accordingly, the data presented here reflect whether a screw was recognized simply as "perforating".

Detection of anterior vertebral cortical perforation correlated significantly with the magnitude of perforation. Vertebral shape and size have to be taken into account. Due to the anterior convexity of the vertebra, a screw not placed in the midsagittal plane may perforate the anterior cortex without detection on lateral radiographs. With 80% apparent penetration of the vertebral body on a true lateral radiograph 30% probability of actual anterior cortex penetration exists at L4. A true lateral roentgenogram therefore has been regarded as inaccurate for determining the penetration of an anterior cortex by a screw tip [19].

The inter-observer variability in this study was considerable. Only 13.8% of screws were assessed equivalently by all observers. This figure is even lower than comparable data given in literature [5, 17]. However, the mentioned studies considered a smaller number of observers and assessed one criterion only, namely, whether a pedicle screw was "in" or "out". Our study analyzed five potential directions of malplacement separately. This also partly explains the large intra-observer variability between post-operative and follow-up films.

#### Conclusion

Plain antero-posterior and lateral radiographs taken post-operatively and at 3 months' follow-up insufficiently assess pedicle screw placement. In the medio-lateral direction, only a fraction of perforating screws is recognized. Differences amongst observers are considerable. The detection of anterior cortical screw perforation depends directly on the magnitude of perforation. Such magnitude can not be properly assessed on plain radiographs.

In cases where accurate information regarding screw position is vital, e.g., patients with post-operative neurological deficits, CT scans should be performed.

## References

- Berlemann U, Monin D, Arm E, Nolte LP, Ozdoba C (1997) Planning and insertion of pedicle screws with computer assistance. *J Spinal Disord* 10: 117–124
- Bernard TN, Seibert CE (1992) Pedicle diameter determined by computed tomography. *Spine* 17: S160–163
- Castro WHM, Halm H, Jerosch J, Malms J, Steinbeck J, Blasius S (1996) Accuracy of pedicle screw placement in lumbar vertebrae. *Spine* 21: 1320–1324
- Esses SI, Sachs BL, Dreyzin V (1993) Complications associated with the technique of pedicle screw fixation. *Spine* 18: 2231–2239
- Farber GL, Place HM, Mazur RA, Casey Jones DE, Damiano TR (1995) Accuracy of pedicle screw placement in lumbar fusions by plain radiographs and computed tomography. *Spine* 20: 1494–1499
- Gertzbein S, Robbins S (1990) Accuracy of transpedicular screw placement in vivo. *Spine* 15: 11–14
- Haaker RG, Eickhoff U, Schopphoff E, Steffen R, Jergas M, Krämer J (1997) Verification of the position of pedicle screws in lumbar spinal fusion. *Eur Spine J* 6: 125–128
- Krag MH, Weaver DL, Beynon BD, Haugh LD (1988) Morphometry of the thoracic and lumbar spine related to transpedicular screw placement for surgical spine fixation. *Spine* 13: 27–32
- Learch T, Massie JB, Pathria M, Ahlgren B, Garfin SR (1996) Evaluation of pedicle screw placement utilizing plain x-rays and computed tomography. Proceedings of the International Society for the Study of the Lumbar Spine, 23rd Meeting, Burlington, VT, USA, p 199
- Misenheimer GR, Peek RD, Wiltse LL, Rothman SLG, Widell EH (1989) Anatomic analysis of pedicle cortical and cancellous diameter as related to screw size. *Spine* 14: 367–372
- Nolte LP, Zamorano LJ, Jiang Z, Wang Q, Langlotz F, Berlemann U (1995) Image guided insertion of transpedicular screws – a laboratory set-up. *Spine* 20: 497–500
- Odgers CJ, Vaccaro AR, Pollack ME, Cotler JM (1996) Accuracy of pedicle screw placement with the assistance of lateral plain radiography. *J Spinal Disord* 9: 334–338
- Roy-Camille R, Saillant G, Mazel C (1986) Internal fixation of the lumbar spine with pedicle screw plating. *Clin Orthop* 20: 7–17
- Schwarzenbach O, Berlemann U, Jost B, Visarius H, Arm E, Langlotz F, Nolte LP, Ozdoba C (1997) Accuracy of computer-assisted pedicle screw placement – an in vivo computed tomography analysis. *Spine* 22: 452–458
- Sjöström L, Jacobsson O, Karlström G, Pech P, Rauschnig W (1993) CT analysis of pedicles and screw tracts after implant removal in thoracolumbar fractures. *J Spinal Disord* 6: 225–231
- Steinmann JC, Herkowitz HN, El-Kommos H, Wesolowski P (1993) Spinal pedicle fixation: confirmation of an image-based technique for screw placement. *Spine* 18: 1856–1861
- Weinstein JN, Spratt KF, Spengler D, Brick C, Reid S (1988) Spinal pedicle fixation: reliability and validity of roentgenogram-based assessment and surgical factors on successful screw placement. *Spine* 13: 1012–1018
- Weinstein JN, Rydevik BL, Rauschnig W (1992) Anatomic and technical consideration of pedicle screw fixation. *Clin Orthop* 284: 34–46
- Whitecloud TS, Skalley TC, Cook SD, Morgan EL (1989) Roentgenographic measurement of pedicle screw penetration. *Clin Orthop* 245: 57–68

## REVIEWER'S COMMENT

Debate continues on the clinical effectiveness and safety of pedicular screw fixation for spinal disorders. In this contemporary study, the authors have found that plain radiographs were unreliable to detect correct pedicle screw positioning and that interobserver variance in interpreting the radiographs was considerable. Although these findings are well supported by the data provided, this investigation necessitates some comments to avoid misunderstandings and misinterpretation of the data.

The fact that 80 out of 119 screws (67%) have perforated the pedicle or the vertebra should rise some con-

cerns on the safety of these implants. Pedicle screws can jeopardize neural structures particularly when they perforate the pedicle at its medial and inferior border, because of the existing nerve root. In this study, 15 screws (13%) violated the pedicle, six of those perforated at the medial or inferior border. Only one screw was out of the pedicle for more than 4 mm which occurred at the lateral border of the pedicle where neural compromise is less frequently found. The authors did not observe any neurological compromise which suggests that minor perforations of the pedicle (<2 mm) remain without clinical consequences.

The most frequent perforation site was anterior, where 65 screws (55%) violated the anterior cortex. At this site, penetrating screws can lacerate the great abdominal vessels which would present as a disastrous complication. As mentioned in the paper, screw placement through the anterior cortex is often intentionally performed in the light of an increased pull-out strength. However, a perforation of more than 4 mm which occurred in 13% was most likely not intended by the surgeons. Although there is in general a safety margin of about 5–10 mm, the surgeon should be well aware that the penetration depth of the screw can