

Age-related changes in human cervical, thoracal and lumbar intervertebral disc exhibit a strong intra-individual correlation

C. Weiler · M. Schietzsch · T. Kirchner ·
A. G. Nerlich · N. Boos · K. Wuertz

Received: 11 July 2011 / Accepted: 11 July 2011 / Published online: 12 August 2011
© Springer-Verlag 2011

Abstract

Introduction Intervertebral disc (IVD) degeneration is characterized as a multifactorial disease, in which the hereditary background is thought to be of high importance. Accordingly, one would expect all spinal levels (lumbar/cervical/thoracal) to be affected by above-average disc degeneration in genetically predisposed individuals. The aim of this study, therefore, was to analyze the amount of degenerative changes in different spine levels in humans from different ages.

Materials and methods In detail, the presence, localization and abundance of histomorphological changes in the annulus fibrosus (AF) and nucleus pulposus (NP) in the cervical (C5/C6), thoracic (T2/T3) and lumbar (L2/L3) spine were investigated in complete autopsy IVD specimens (47 individuals) covering a complete age range (0–95 years).

Results Results indicate that the highest degree of histodegenerative changes were observed in the NP in all spine levels and showed an age-related expression pattern. With regard to the different spine levels, lumbar disc specimen

showed significantly more degenerative changes compared to cervical and thoracic discs, whereas no statistical difference was observed between cervical and thoracic discs. In summary, highest grades of degeneration were observed in lumbar discs (especially in the NP). Intra-individual correlations between the degeneration score in the different levels showed a significant individual concordance.

Conclusions The intra-individual correlation of degenerative changes in all three examined spine regions further supports the notion that individual, i.e. genetic factors are strong predisposing factor for the development of age-related disc alterations.

Keywords Disc degeneration · Histological degeneration score (HDS) · Cervical, thoracic and lumbar spine · Aging · Intra-individual correlation

Introduction

While mechanical loading was considered the major cause for degeneration of the intervertebral disc (IVD) in the 1970s, intensified research activities in the last two decades strongly indicate a multifactorial etiology [1]. Numerous studies have been performed trying to identify the most important factor(s) causing accelerated or advanced signs of aging and ultimately structural failure. Large genetic studies have been able to prove the importance of heredity in the development of disc degeneration [3–5, 12, 28, 29, 60, 61]. However, while disc degeneration usually manifests in a pronounced manner later in life, polymorphic variations in susceptibility genes are congenital, indicating that genetic inheritance is only a risk factor, but additional factors or events are needed to trigger aggravating disc degeneration. As the lumbar level is specifically susceptible to disc

C. Weiler · M. Schietzsch · T. Kirchner
Institute of Pathology, University of Munich, Munich, Germany

A. G. Nerlich
Institute of Pathology, Academic Clinic Munich-Bogenhausen,
Munich, Germany

N. Boos · K. Wuertz (✉)
Spine Research Group, Competence Center for Applied
Biotechnology and Molecular Medicine (CABMM),
University of Zurich, Winterthurerstrasse 190 (17L28),
8057 Zurich, Switzerland
e-mail: karin.wuertz@cabmm.uzh.ch

N. Boos · K. Wuertz
AOSpine Research Network, Duebendorf, Switzerland

degeneration, mechanical load and nutritional deficits may be factors that have to be weighed again.

In order to further elucidate the role of intra-individual factors in the development of disc degeneration, investigations on the extent of degenerative histological changes in the cervical, thoracic and lumbar spine could provide useful data. To the best of our knowledge, no such data is yet available. The aim of this study, therefore, was to investigate the intra-individual histomorphological changes in the IVD in the cervical, thoracic and lumbar spine during the process of aging. Thus, the presence, localization and abundance of histomorphological changes in the annulus fibrosus (AF) and the nucleus pulposus (NP) were investigated in complete autopsy IVD specimens of all ages and these findings were correlated with age, region and disc level.

Materials and methods

Cadaver specimens

For the purpose of this study, IVDs from the cervical (C5/C6), thoracic (T2/T3) and lumbar (L2/L3) spine were harvested during routine autopsy from 47 individuals (21 females/26 males) without any known spinal disorders. This level pattern was prompted by the accessibility during routine autopsy. The age ranged from 25 days (newborn) to 95 years (senile), median age was 62 years. Available medical reports showed no history of relevant back pain in terms of previous back-related treatment, hospitalization, surgery or invalidity.

Tissue processing

All IVDs were removed using an anterior approach. Posterior structures were removed by pedicle osteotomy, leaving the posterior longitudinal ligaments intact. One mid-sagittal slice of each segment was obtained, including parts of the adjacent vertebral body. This sagittal slice (of approx. 5 mm thickness) of the complete motion segment was fixed in 4–6% buffered formaldehyde (pH 7.4), subsequently decalcified (0.1 M EDTA, pH 7.4) and finally embedded in paraffin wax as routinely performed [8, 42].

Data evaluation

Determination of the macroscopic grade of disc degeneration

All samples were evaluated macroscopically by two of the authors (A.G.N. and C.W.) with a special interest in musculoskeletal pathology. The extent of disc degeneration was graded from grade 1 (juvenile disc) to grade 5 (severe

degeneration) according to the grading system by Thompson et al. [54].

Determination of the degree of histological degeneration

In all samples, the histological degree of disc tissue degeneration was determined in the outer AF (OA), inner AF (IA) and the NP as previously described in detail [8]. Briefly, the parameters cellularity, occurrence and extent of cleft and tear formation, granular and/or mucoid matrix degeneration and cell necrosis were ranked, forming the “histological classification system” (HDS) with a maximum score of 22 points. All histomorphologic gradings were assessed independently. For the purpose of this study, we use the terms “age-related changes” and “degenerative changes” synonymously because a clear distinction is not possible.

Statistical analysis

Interrater reliability for the degree of histological degeneration was determined on a subset of 10 specimens and for the macroscopic degeneration for all IVD using kappa statistics. The agreement was graded as follows: 0.00 was regarded as poor, 0.00–0.20 as slight, 0.21–0.40 fair, 0.41–0.60 moderate, 0.61–0.80 substantial and 0.81–1.00 almost perfect [33]. Correlation between the HDS score, age, spine level, gender and macroscopic disc degeneration was explored by using a Spearman rank test. Differences between age-groups, and macroscopic grades of disc degeneration were explored by a non-parametric Kruskal–Wallis test. After testing (Kolmogorov–Smirnov test) for normal distribution for the parameters age, BMI and NP-HDS (cervical, thoracic and lumbar) a Pearson correlation analysis was performed to explore intra-individual correlations between the HDS score in the different spine levels. In a second step, a partial Pearson correlation was performed with age as control factor to diminish the effect of aging. The level of significance was set to 0.05, two-tailed.

Results

Relation between histological classification system (HDS) and the macroscopic grade of disc degeneration (Thompson grade)

The extent of histological changes—especially in the NP—showed a direct proportionality to the amount of macroscopic alterations (Thompson grade) (Fig. 1), with a high statistical significance ($p = 0.001$). As expected, the interdependency was highest for histological changes in the NP and the macroscopic degeneration grade. Generally, lower macroscopic grades were obtained if matrix

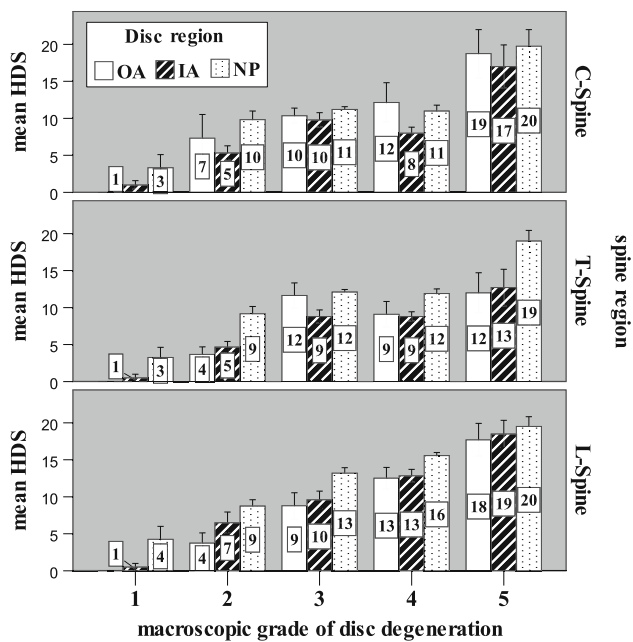


Fig. 1 Interrelation of the outer annulus fibrosus (OA), inner annulus fibrosus (IA) and the nucleus pulposus (NP) HDS in the three different spine regions with regard to the macroscopic grade of disc degeneration (mean \pm SEM)

alterations were mostly restricted to the AF, while the NP showed only minor changes.

Reliability of the histologic and macroscopic assessment

Interrater reliability for the assessment of the histological parameter showed substantial rater agreement (Cohen's κ 0.714) and almost perfect rater agreement for the macroscopic assessment (Cohen's κ 0.893).

Semiquantitative assessment of the histologic degeneration score (HDS)

The HDS for the 47 individuals with regard to spine level, anatomic compartment and age are presented in Table 1. Figure 2 showed the mean HDS scores with regard to anatomic subcompartment (OA/IA/NP) and spine level (C5/6; T2/3; L2/3) with highest values for the NP in the lumbar region. For further analyses, the individuals were categorized into four age groups (0–15 years/16–45 years/46–65 years/66–95 years). The extent of histological changes significantly increased with age ($p = 0.001$). Changes were most pronounced in the NP and the lumbar disc (Fig. 3). The differences in the amount of histodegenerative changes between the four age groups were statistically highly significant ($p = 0.001$).

In general, the following histological signs of disc degeneration are observed:

- Cell density with clones of chondrocytes (hypertrophic chondrocytes) as an indicator of cellular proliferation.
- Granular changes with eosinophilic granular material within the fibrocartilage matrix.
- Mucous degeneration with cystic oval or irregular areas with an intense deposition of acid mucopolysaccharides staining dark blue with Alcian blue-PAS.
- Concentric and radial tears and clefts as indicators for tissue disruption.
- Cell death and amorphous fibrous tissue without any differentiation (scar formation).

Age group I

0–15 years (n = 4) In the newborn, no alteration of the IVD is seen. Focally remnants of notochordal cells are detectable. In contrast, the 3- and 7-year-old individuals showed already minor histological changes mostly in the NP and to a lesser extent in the IA, especially with increased cellularity, sporadic tears, cell death, granular and mucoid changes.

Age group II

16–45 years (n = 6) In this age group, a dramatic increase in all histological alterations can be observed with a minimal focus on increased cell proliferation. There are few rim lesions associated with neovascularization. Changes are enhanced in the NP and there is a slight preference for these changes in the lumbar IVD.

Age group III

46–65 years (n = 10) This stage is characterized by a continued increasing frequency in cell and matrix alterations with minor emphasis on cell proliferation. Adjacent to clefts and tears, huge clones of hypertrophic chondrocytes are detectable. Numerous clefts and tears are filled with granular material (granular matrix degeneration). Histological alterations are most pronounced in the lumbar spine and in the cervical spine.

Age group IV

66–95 years (n = 27) This stage showed the highest amount of tissue alterations, sometimes with severe matrix deterioration, tissue disruption or scar tissue (burn out appearance). Again, these changes are most pronounced in the lumbar spine and to a lesser extent in the cervical and thoracic spine. There is a substantial interindividual variation with some individuals showing only moderate histological changes in the IVD.

Table 1 Patient sample data

Specimen number	Age	Sex	Cervical spine C5/6				Thoracic spine T2/3				Lumbar spine L2/3			
			HDS			Macro-grade	HDS			Macro-grade	HDS			Macro-grade
			OA	IA	NP		OA	IA	NP		OA	IA	NP	
1	0	F	0	0	0	1	0	0	0	1	0	0	0	1
2	3	M	–	–	–	–	0	0	2	1	0	0	3	1
3	3	F	0	1	6	1	0	0	6	1	0	0	8	1
4	7	M	0	2	4	1	0	2	5	1	0	2	6	1
5	17	M	–	–	–	–	1	3	8	2	2	3	9	2
6	19	M	2	4	8	2	4	5	10	2	5	7	13	3
7	36	M	5	3	7	2	1	3	9	3	1	2	9	3
8	38	F	4	6	11	2	6	5	10	2	7	9	11	2
9	43	M	4	5	14	4	6	9	13	4	6	10	13	4
10	44	M	1	3	7	2	3	3	6	2	5	4	8	2
11	47	F	14	8	11	3	4	8	10	4	5	7	11	4
12	48	M	4	7	12	3	1	4	8	2	1	4	7	2
13	54	F	7	10	15	3	7	9	12	3	22	22	22	5
14	54	M	22	8	13	2	7	8	13	2	12	13	15	3
15	56	M	7	8	12	3	22	8	14	3	8	10	13	3
16	57	M	12	9	10	3	22	6	13	3	8	9	11	3
17	61	M	11	7	13	3	13	7	14	4	6	9	16	4
18	63	F	16	11	13	3	7	6	15	3	12	12	16	4
19	64	F	9	6	13	3	9	11	12	4	9	9	14	4
20	65	F	9	6	10	3	5	6	12	3	9	13	15	4
21	66	F	10	8	13	2	12	11	15	5	22	15	16	4
22	67	M	7	9	9	4	7	10	12	3	10	14	15	4
23	68	M	8	8	8	3	22	9	10	3	6	10	12	3
24	68	F	9	11	13	3	–	–	12	3	10	15	17	3
25	69	F	7	5	9	3	5	8	10	3	7	7	12	3
26	69	M	9	8	9	3	6	6	12	4	9	10	15	4
27	70	M	7	7	10	3	3	11	14	4	6	10	16	4
28	71	M	5	11	15	3	10	10	12	4	6	11	15	4
29	71	M	22	6	12	4	8	7	12	3	22	22	22	5
30	72	M	9	11	9	4	22	7	13	3	11	12	15	4
31	74	M	22	22	22	5	22	22	22	5	22	22	22	5
32	76	M	7	7	9	3	5	8	22	5	22	22	22	4
33	78	F	6	8	11	3	8	8	13	3	22	22	22	5
34	79	M	22	22	8	3	10	10	10	3	9	10	15	3
35	84	F	11	8	13	4	8	8	14	3	13	12	15	4
36	84	F	10	8	11	3	8	14	13	3	10	13	22	5
37	84	F	12	9	11	3	10	11	9	4	22	13	15	3
38	85	F	22	22	11	3	22	22	13	3	13	15	15	4
39	86	M	10	10	9	4	7	8	11	3	22	13	16	4
40	86	F	22	22	11	3	22	22	14	5	6	9	14	4
41	86	M	10	10	13	3	9	8	16	5	8	11	16	5
42	87	M	22	13	22	5	8	11	22	5	22	22	22	5
43	87	F	22	7	11	4	8	9	12	3	22	22	17	4
44	93	F	6	6	10	3	8	9	9	4	12	13	15	4
45	94	M	9	11	13	5	22	6	14	4	22	22	14	5
46	95	F	22	22	22	5	6	7	22	5	22	22	22	5
47	95	F	8	9	12	3	22	9	12	3	22	13	16	4

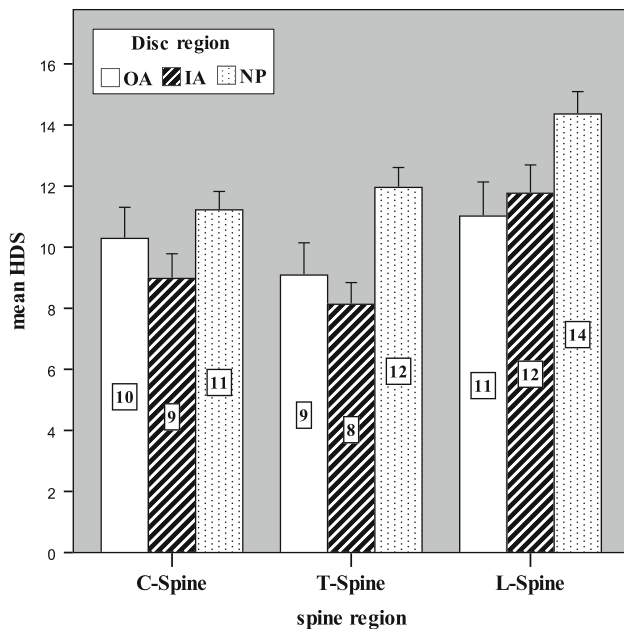


Fig. 2 Histological classification system (HDS) of all patients in regard to outer annulus fibrosus (OA), inner annulus fibrosus (IA), the nucleus pulposus (NP) in the three different spine regions (mean \pm SEM)

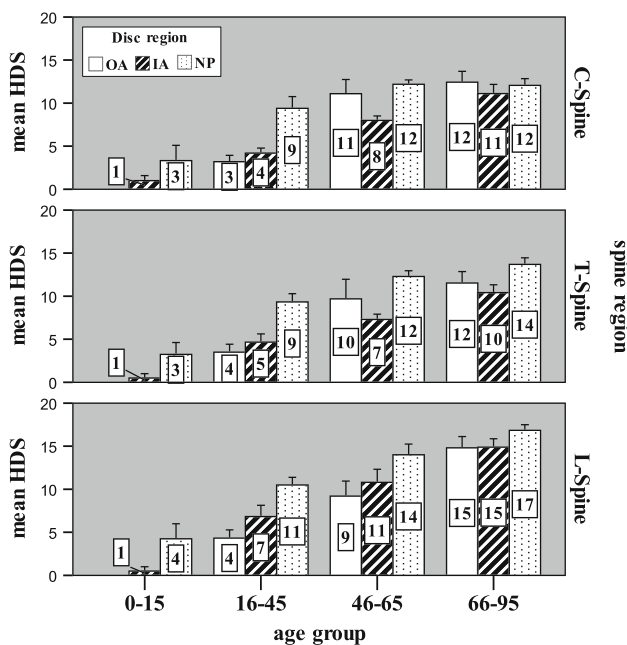


Fig. 3 Histological classification system (HDS) of all patients in regard to outer annulus fibrosus (OA), inner annulus fibrosus (IA), the nucleus pulposus (NP) in relation to different age groups (mean \pm SEM)

Intra-individual relation between histological classification system (HDS) in the NP and spine level

The HDS showed a statistical significant topographic variation pattern with highest values in the lumbar spine ($p = 0.001$) (Fig. 4). Overall, the histological changes in

the thoracic spine were slightly more pronounced in comparison to the cervical spine, these differences showed a statistical significance ($p = 0.004$).

Correlative analyses

Spearman's rank correlation

A Spearman's rank correlation coefficient (for details see Table 2) showed a high statistical significance between the amount of histological changes (HDS grade), age and spine level ($p = 0.001$).

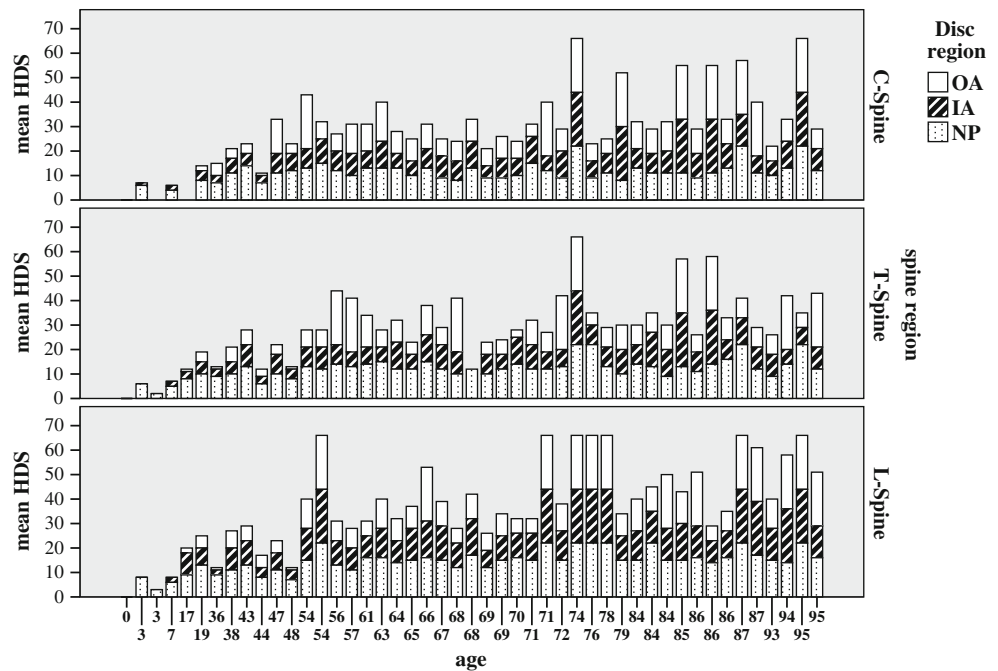
Pearson and partial Pearson correlation test Intra-individual correlations between the HDS score in the different spine levels showed a statistical significant high individual concordance ($p = 0.01$) with medial correlation coefficients (for details see Table 3). Although there is a drop of the correlation power after partial correlation with age as control variable the resulting highly significant correlation coefficients substantiate the high intra-individual correlation for the different spine level.

Discussion

This is the first study that provides a semiquantitative assessment of the intra-individual temporo-spatial course of histological changes in complete cross-sections of IVDs in the cervical, thoracic and lumbar spine. The amount of histological changes in each anatomic subcompartment (OA/IA/NP) of the IVD was evaluated for every spine level (C5/6; T2/3; L2/3) in 47 individuals (age range 0–95 years). In summary, the highest levels of histodegenerative changes were observed in the NP in all spine levels, with most pronounced changes in the lumbar discs and an age-related expression pattern. Our data also provides additional evidence for a high intra-individual correlation of degenerative changes in all three examined spinal regions.

The last decade has broadened our understanding of the process of disc degeneration [1, 24, 50, 67]. In the past, disc degeneration was viewed as a result of mechanical imbalance and/or repeated injury. Nowadays, it is characterized as a multifactorial disorder with a strong hereditary background [4, 28, 29]. If genetic inheritance (for example, collagen I polymorphism [45]) constitutes the driving force for the degeneration of the IVD, one would expect above-average degeneration in all spine regions (lumbar/thoracic/cervical) in the presence of an unfavorable heredity background. A thorough literature review did not show any study which focused on a detailed macroscopical and microscopical analysis of disc degeneration in different spine level in humans.

Fig. 4 Individual histological classification system (HDS) for every patient with regard to anatomic subcompartment and spinal region



As the majority of the histological, biochemical and cellular investigations focused on the lumbar spine, due to the high susceptibility for disc degeneration in this region, temporo-spatial changes in the lumbar discs are well explored [7–10, 14–16, 25, 27, 35, 40, 41, 47, 48, 55–57, 64]. In contrast, histological description of degenerative changes in the thoracic spine are rare and only very few investigations are available using MRI technique [20, 49, 59]. Girard et al. [20] characterized the temporal changes in disc-related disorders of thoracic spine using MRI imaging, showing predominantly disc degeneration and herniation in the lower part of the spine (T6–T10), which can rapidly evolve, but tends to remain unchanged after occurrence. One important limitation of this study is the lack of a reference or “gold standard”, for example, discography [66]. In particular, there is good experimental evidence that the assessment of disc morphology by radiology alone tends to under-diagnose the real disc pathology [13, 30, 46, 65]. Similarly, with regard to the cervical spine, the majority of investigations used radiology imaging to assess the amount of disc changes [13, 17, 30–32, 34, 43, 44, 52, 53, 62, 63], while only few histological studies exist [2, 13, 18, 32]. In general, it is believed that degeneration of the cervical disc is common [21, 22] and that the same matrix degradation processes occur as in the lumbar spine. These investigations focused mainly on material from disc herniation and to a lesser extent to cervical spondylosis. The authors describe the resorption-process of herniated disc material, which is similar to the action in the lumbar disc [2, 18, 32]. Furthermore, they speculate about the influence of nutrient deprivation as an underlying cause for

spondylosis. There are numerous MR and plain radiographic classifications for cervical disc degeneration in use, but to our knowledge, only one investigation by Christe et al. [13] tried to validate their radiological classification on the basis of the underlying histology. Results of this study showed that discs from patients over 50 years of age are histologically severely degenerated, which is very similar to our findings. In addition, they could demonstrate that MR was only a moderate indicator of advanced disc pathology and poorly detected lesser degrees of pathology when compared with histology.

By analyzing discs from all spine level (cervical/thoracic/lumbar) in each of the 47 individuals, we found a highly significant intra-individual correlation for degenerative lesions in the NP for all examined spine levels. Of course, aging has a profound effect on degenerative changes in NP, but our statistical analysis (even after partial correlation with age as control variable) revealed a robust correlation coefficient between the different spine levels. These results corroborate the presumption of an individual predisposition for degenerative disc lesion. This distinct individual disposition for degenerative lesions in the disc could be attributed to underlying genetic preposition, for example genetic polymorphisms of collagens or inflammatory mediators [3–5, 28, 61]. Additionally, we observed the highest amount of histo-degenerative changes in the NP of lumbar discs, which can be caused either by malnutrition of disc cells in this region or by mechanical loading. The relevance of the nutrition is supported by previous studies, indicating that disturbances of the nutrient supply (e.g. prolonged diffusion distances as present in the

Table 2 Spearman rank correlation coefficients and significance levels for the correlation of the HDS score in the different spine levels versus age, sex, BMI and macroscopic grade of disc degeneration

Spearman's rho correlation coefficient													
Variables	Age	Sex	BMI	Grade	OA_C	IA_C	NP_C	OA_T	IA_T	NP_T	OA_L	IA_L	NP_L
Age	1.000	-0.181	-0.014	0.612**	0.565**	0.626**	0.319*	0.615**	0.608**	0.530**	0.736**	0.708**	0.670**
Sex	-0.181	1.000	-0.074	-0.026	-0.100	0.009	-0.119	-0.030	-0.206	0.027	-0.241	-0.165	-0.156
BMI	-0.014	-0.074	1.000	0.290*	0.116	0.013	0.308*	-0.084	0.181	0.141	-0.039	-0.038	0.133
Grade	0.612**	-0.026	0.290*	1.000	0.450**	0.465**	0.521**	0.481**	0.627**	0.694**	0.467**	0.494**	0.555**
OA_C	0.565**	-0.100	0.116	0.450**	1.000	0.661**	0.447**	0.540**	0.483**	0.547**	0.564**	0.507**	0.531**
IA_C	0.626**	0.009	0.013	0.465**	1.000	0.498**	0.498**	0.665**	0.531**	0.563**	0.534**	0.551**	0.505**
NP_C	0.319*	-0.119	0.308*	0.521**	0.447**	1.000	1.000	0.414**	0.413**	0.648**	0.477**	0.527**	0.528**
OA_T	0.615**	-0.030	-0.084	0.481**	0.540**	0.665**	0.414**	1.000	0.617**	0.541**	0.537**	0.500**	0.416**
IA_T	0.608**	-0.206	0.181	0.627**	0.483**	0.531**	0.413**	0.617**	1.000	0.483**	0.514**	0.551**	0.571**
NP_T	0.530**	0.027	0.141	0.694**	0.547**	0.563**	0.648**	0.541**	0.483**	1.000	0.579**	0.625**	0.686**
OA_L	0.736**	-0.241	-0.039	0.467**	0.564**	0.534**	0.477**	0.537**	0.514**	0.579**	1.000	0.932**	0.814**
IA_L	0.708**	-0.165	-0.038	0.494**	0.507**	0.551**	0.527**	0.500**	0.551**	0.625**	0.932**	1.000	0.865**
NP_L	0.670**	-0.156	0.133	0.555**	0.531**	0.505**	0.528**	0.416**	0.571**	0.686**	0.814**	0.865**	1.000

** Correlation is significant at the 0.01 level (two-tailed)

* Correlation is significant at the 0.05 level (two-tailed)

Table 3 Pearson and partial Pearson correlation coefficients and significance levels for the correlation of the HDS score (NP) in the different spine levels versus age and BMI

Pearson correlation coefficient					
Control variables	NP_C	NP_T	NP_L	BMI	Age
None ^a					
NP_C	1.000	0.806**	0.691**	0.265	0.542**
NP_T	0.806**	1.000	0.823**	0.148	0.672**
NP_L	0.691**	0.823**	1.000	0.128	0.746**
BMI	0.265	0.148	0.128	1.000	0.063
Age	0.542**	0.672**	0.746**	0.063	1.000
Age					
NP_C	1.000	0.710**	0.513**	0.276	
NP_T	0.710**	1.000	0.652**	0.142	
NP_L	0.513**	0.652**	1.000	0.121	
BMI	0.276	0.142	0.121	1.000	

^a Cells contain zero-order (Pearson) correlations

** Correlation is significant at 0.01 level

lumbar area) will ultimately lead to improper cell function and cell death with resulting disc degeneration [6, 8, 23, 26, 51, 58]. Although cervical and thoracic disc height measurements showed conflicting results with considerable individual variation [11, 36, 39], lumbar discs are thought to possess approximately twice the height of cervical discs [19]. This increase in disc height is paralleled by a rise in diffusion distances up to 8 mm. However, the accelerated occurrence of disc degeneration in the lumbar NP can potentially also be explained by mechanical loading, which is highest in the lumbar spine [37–39]. Cervical rotation with resulting torsion stress to fibers of the AF may explain the more pronounced histological changes in the AF of the cervical spine, therefore, further supporting the role of mechanical loading. However, it has to be noted that these local changes in the AF are not well detected by the macroscopic classification system, which is more focused on changes in the NP.

There are important limitations of this investigation: first with regard to patient population (mean 62 years), an inclusion of more patients between 16 and 45 years would be desirable, because in this age group the degenerative processes gain momentum. Secondly—although we were able to present a risk evaluation for the investigated parameters (age/spine level/disc compartment/individual disposition)—we were not able to calculate the absolute power of these factors because they are interconnected. Finally, from our statistical analysis, we can state that spine level, disc compartment, age and intra-individual predisposition are important factors to influence the degeneration process of the IVD. We are fully aware that a predisposition not necessarily promotes pathology and that other

intervening factors are required to orchestrate the degeneration process.

In conclusion, this study demonstrated that the level of histo-degenerative changes was highest in the NP in all spinal regions with its maximum in the lumbar spine. The intra-individual correlation of degenerative changes in all three examined spine regions (especially after partial correlation for age) further supports the notion that individual, i.e. genetic factors are predisposing factors for the development of age-related disc alterations.

Acknowledgments This study was made possible by grants from AOSpine (SRN 02/103 and AOSBRC-07-03). Its contents are solely the responsibility of the authors and do not necessarily represent the official views of AOSpine. The investigation was undertaken in accordance with the local ethic committee guidelines.

Conflict of interest None.

References

- Adams MA, Roughley PJ (2006) What is intervertebral disc degeneration, and what causes it? *Spine* 31:2151–2161
- Baba H, Maezawa Y, Furusawa N, Fukuda M, Uchida K, Kokubo Y, Imura S (1997) Herniated cervical intervertebral discs: histological and immunohistochemical characteristics. *Eur J Histochem* 41:261–270
- Battie MC, Videman T (2006) Lumbar disc degeneration: epidemiology and genetics. *J Bone Joint Surg Am* 88(Suppl 2):3–9
- Battie MC, Videman T, Kaprio J, Gibbons LE, Gill K, Manninen H, Saarela J, Peltonen L (2009) The Twin Spine Study: contributions to a changing view of disc degeneration. *Spine J* 9:47–59
- Battie MC, Videman T, Levalahti E, Gill K, Kaprio J (2007) Heritability of low back pain and the role of disc degeneration. *Pain* 131:272–280
- Bibby SR, Urban JP (2004) Effect of nutrient deprivation on the viability of intervertebral disc cells. *Eur Spine J* 13(8):695–701
- Boos N, Nerlich AG, Wiest I, von der Mark K, Aebi M (1997) Immunolocalization of type X collagen in human lumbar intervertebral discs during ageing and degeneration. *Histochem Cell Biol* 108:471–480
- Boos N, Weissbach S, Rohrbach H, Weiler C, Spratt KF, Nerlich AG (2002) Classification of age-related changes in lumbar intervertebral discs: 2002 Volvo Award in basic science. *Spine* 27:2631–2644
- Buckwalter JA (1995) Aging and degeneration of the human intervertebral disc. *Spine* 20:1307–1314
- Buckwalter JA, Roughley PJ, Rosenberg LC (1994) Age-related changes in cartilage proteoglycans: quantitative electron microscopic studies. *Microsc Res Tech* 28:398–408
- Busscher I, Ploegmakers JJ, Verkerke GJ, Veldhuizen AG (2010) Comparative anatomical dimensions of the complete human and porcine spine. *Eur Spine J* 19:1104–1114
- Chan D, Song Y, Sham P, Cheung KM (2006) Genetics of disc degeneration. *Eur Spine J* 15(Suppl 3):S317–S325 (epub:2006 Jul 4)
- Christe A, Laubli R, Guzman R, Berlemann U, Moore RJ, Schroth G, Vock P, Lovblad KO (2005) Degeneration of the cervical disc: histology compared with radiography and magnetic resonance imaging. *Neuroradiology* 47:721–729
- Coventry MB, Ghormley RK, Kernohan JW (1945) The intervertebral disc: its microscopic anatomy and pathology. Part I. Anatomy, development, and physiology. *J Bone Joint Surg Am* 27:105–112
- Coventry MB, Ghormley RK, Kernohan JW (1945) The intervertebral disc: its microscopic anatomy and pathology. Part II. Changes in the intervertebral disc concomitant with age. *J Bone Joint Surg Am* 27:233–247
- Coventry MB, Ghormley RK, Kernohan JW (1945) The intervertebral disc: its microscopic anatomy and pathology. Part III. Pathological changes in the intervertebral disc. *J Bone Joint Surg Am* 27:460–474
- Dai L (1998) Disc degeneration and cervical instability. Correlation of magnetic resonance imaging with radiography. *Spine (Phila Pa 1976)* 23:1734–1738
- Furusawa N, Baba H, Miyoshi N, Maezawa Y, Uchida K, Kokubo Y, Fukuda M (2001) Herniation of cervical intervertebral disc: immunohistochemical examination and measurement of nitric oxide production. *Spine* 26:1110–1116
- Gilad I, Nissan M (1986) A study of vertebra and disc geometric relations of the human cervical and lumbar spine. *Spine (Phila Pa 1976)* 11:154–157
- Girard CJ, Schweitzer ME, Morrison WB, Parellada JA, Carrino JA (2004) Thoracic spine disc-related abnormalities: longitudinal MR imaging assessment. *Skeletal Radiol* 33:216–222
- Gore DR (2001) Roentgenographic findings in the cervical spine in asymptomatic persons: a ten-year follow-up. *Spine (Phila Pa 1976)* 26:2463–2466
- Gore DR, Sepic SB, Gardner GM (1986) Roentgenographic findings of the cervical spine in asymptomatic people. *Spine (Phila Pa 1976)* 11:521–524
- Guehring T, Wilde G, Sumner M, Grunhagen T, Karney GB, Tirilapur UK, Urban JP (2009) Notochordal intervertebral disc cells: sensitivity to nutrient deprivation. *Arthritis Rheum* 60:1026–1034
- Hadjipavlou AG, Tzermiadianos MN, Bogduk N, Zindrick MR (2008) The pathophysiology of disc degeneration: a critical review. *J Bone Joint Surg Br* 90:1261–1270
- Haefeli M, Kalberer F, Saegesser D, Nerlich AG, Boos N, Paesold G (2006) The course of macroscopic degeneration in the human lumbar intervertebral disc. *Spine* 31:1522–1531
- Horner HA, Urban JP (2001) 2001 Volvo Award Winner in Basic Science Studies: effect of nutrient supply on the viability of cells from the nucleus pulposus of the intervertebral disc. *Spine* 26:2543–2549
- Johnson WE, Roberts S (2003) Human intervertebral disc cell morphology and cytoskeletal composition: a preliminary study of regional variations in health and disease. *J Anat* 203:605–612
- Kalichman L, Hunter DJ (2008) The genetics of intervertebral disc degeneration. Associated genes. *Joint Bone Spine* 75:388–396
- Kalichman L, Hunter DJ (2008) The genetics of intervertebral disc degeneration. Familial predisposition and heritability estimation. *Joint Bone Spine* 75:383–387
- Kettler A, Rohlmann F, Neidlinger-Wilke C, Werner K, Claes L, Wilke HJ (2006) Validity and interobserver agreement of a new radiographic grading system for intervertebral disc degeneration. Part II. Cervical spine. *Eur Spine J* 15:732–741
- Kettler A, Wilke HJ (2006) Review of existing grading systems for cervical or lumbar disc and facet joint degeneration. *Eur Spine J* 15:705–718
- Kokubo Y, Uchida K, Kobayashi S, Yayama T, Sato R, Nakajima H, Takamura T, Mwaka E, Orwotho N, Bangirana A, Baba H (2008) Herniated and spondylotic intervertebral discs of the human cervical spine: histological and immunohistological findings in 500 en bloc surgical samples. Laboratory investigation. *J Neurosurg Spine* 9:285–295

33. Landis JR, Koch GG (1977) The measurement of observer agreement for categorical data. *Biometrics* 33:159–174
34. Matsumoto M, Okada E, Ichihara D, Watanabe K, Chiba K, Toyama Y, Fujiwara H, Momoshima S, Nishiwaki Y, Hashimoto T, Takahata T (2010) Age-related changes of thoracic and cervical intervertebral discs in asymptomatic subjects. *Spine (Phila Pa 1976)* 35:1359–1364
35. Miller JA, Schmatz C, Schultz AB (1988) Lumbar disc degeneration: correlation with age, sex, and spine level in 600 autopsy specimens. *Spine (Phila Pa 1976)* 13:173–178
36. Moroney SP, Schultz AB, Miller JA, Andersson GB (1988) Load-displacement properties of lower cervical spine motion segments. *J Biomech* 21:769–779
37. Nachemson A (1975) Towards a better understanding of low-back pain: a review of the mechanics of the lumbar disc. *Rheumatol Rehabil* 14:129–143
38. Nachemson A, Elfstrom G (1970) Intravital dynamic pressure measurements in lumbar discs. A study of common movements, maneuvers and exercises. *Scand J Rehabil Med Suppl* 1:1–40
39. Nachemson AL, Schultz AB, Berkson MH (1979) Mechanical properties of human lumbar spine motion segments. Influence of age, sex, disc level, and degeneration. *Spine (Phila Pa 1976)* 4:1–8
40. Nerlich AG, Boos N, Wiest I, Aebi M (1998) Immunolocalization of major interstitial collagen types in human lumbar intervertebral discs of various ages. *Virch Arch* 432:67–76
41. Nerlich AG, Schleicher ED, Boos N (1997) 1997 Volvo Award winner in basic science studies. Immunohistologic markers for age-related changes of human lumbar intervertebral discs. *Spine* 22:2781–2795
42. Nerlich AG, Weiler C, Zipperer J, Narozny M, Boos N (2002) Immunolocalization of phagocytic cells in normal and degenerated intervertebral discs. *Spine* 27:2484–2490
43. Okada E, Matsumoto M, Ichihara D, Chiba K, Toyama Y, Fujiwara H, Momoshima S, Nishiwaki Y, Hashimoto T, Ogawa J, Watanabe M, Takahata T (2009) Aging of the cervical spine in healthy volunteers: a 10-year longitudinal magnetic resonance imaging study. *Spine (Phila Pa 1976)* 34:706–712
44. Petren-Mallmin M, Linder J (2001) Cervical spine degeneration in fighter pilots and controls: a 5-yr follow-up study. *Aviat Space Environ Med* 72:443–446
45. Pluijm SM, van Essen HW, Bravenboer N, Uitterlinden AG, Smit JH, Pols HA, Lips P (2004) Collagen type I alpha1 Sp1 polymorphism, osteoporosis, and intervertebral disc degeneration in older men and women. *Ann Rheum Dis* 63:71–77
46. Quint U, Wilke HJ (2008) Grading of degenerative disk disease and functional impairment: imaging versus patho-anatomical findings. *Eur Spine J* 17:1705–1713
47. Roberts S, Evans EH, Kletsas D, Jaffray DC, Eisenstein SM (2006) Senescence in human intervertebral discs. *Eur Spine J* 15(Suppl 3):S312–316
48. Roberts S, Evans H, Trivedi J, Menage J (2006) Histology and pathology of the human intervertebral disc. *J Bone Joint Surg Am* 88(Suppl 2):10–14
49. Ross JS, Perez-Reyes N, Masaryk TJ, Bohlman H, Modic MT (1987) Thoracic disk herniation: MR imaging. *Radiology* 165:511–515
50. Roughley PJ (2004) Biology of intervertebral disc aging and degeneration: involvement of the extracellular matrix. *Spine* 29:2691–2699
51. Shirazi-Adl A, Taheri M, Urban JP (2010) Analysis of cell viability in intervertebral disc: effect of endplate permeability on cell population. *J Biomech* 43:1330–1336
52. Siivola SM, Levoska S, Tervonen O, Ilkko E, Vanharanta H, Keinänen-Kiukaanniemi S (2002) MRI changes of cervical spine in asymptomatic and symptomatic young adults. *Eur Spine J* 11:358–363
53. Sohn HM, You JW, Lee JY (2004) The relationship between disc degeneration and morphologic changes in the intervertebral foramen of the cervical spine: a cadaveric MRI and CT study. *J Korean Med Sci* 19:101–106
54. Thompson JP, Pearce RH, Schechter MT, Adams ME, Tsang IK, Bishop PB (1990) Preliminary evaluation of a scheme for grading the gross morphology of the human intervertebral disc. *Spine* 15:411–415
55. Trout JJ, Buckwalter JA, Moore KC (1982) Ultrastructure of the human intervertebral disc: II. cells of the nucleus pulposus. *Anat Rec* 204:307–314
56. Trout JJ, Buckwalter JA, Moore KC, Landas SK (1982) Ultrastructure of the human intervertebral disc. I. Changes in notochordal cells with age. *Tissue Cell* 14:359–369
57. Urban JP, Roberts S (2003) Degeneration of the intervertebral disc. *Arthritis Res* 5:120–130
58. Urban JP, Smith S, Fairbank JC (2004) Nutrition of the intervertebral disc. *Spine* 29:2700–2709
59. Vanichkachorn JS, Vaccaro AR (2000) Thoracic disk disease: diagnosis and treatment. *J Am Acad Orthop Surg* 8:159–169
60. Videman T, Battie MC, Parent E, Gibbons LE, Vainio P, Kaprio J (2008) Progression and determinants of quantitative magnetic resonance imaging measures of lumbar disc degeneration: a five-year follow-up of adult male monozygotic twins. *Spine* 33:1484–1490
61. Videman T, Saarela J, Kaprio J, Nakki A, Levalahti E, Gill K, Peltonen L, Battie MC (2009) Associations of 25 structural, degradative, and inflammatory candidate genes with lumbar disc desiccation, bulging, and height narrowing. *Arthritis Rheum* 60:470–481
62. Viikari-Juntura E, Raininko R, Videman T, Porkka L (1989) Evaluation of cervical disc degeneration with ultralow field MRI and discography. An experimental study on cadavers. *Spine (Phila Pa 1976)* 14:616–619
63. Walraevens J, Liu B, Meersschaert J, Demaerel P, Delye H, Depreitere B, Vander SJ, Goffin J (2009) Qualitative and quantitative assessment of degeneration of cervical intervertebral discs and facet joints. *Eur Spine J* 18:358–369
64. Weiler C, Nerlich AG, Zipperer J, Bachmeier BE, Boos N (2002) 2002 SSE Award Competition in Basic Science: expression of major matrix metalloproteinases is associated with intervertebral disc degradation and resorption. *Eur Spine J* 11:308–320
65. Wilke HJ, Rohlmann F, Neidlinger-Wilke C, Werner K, Claes L, Kettler A (2006) Validity and interobserver agreement of a new radiographic grading system for intervertebral disc degeneration. Part I. Lumbar spine. *Eur Spine J* 15:720–730
66. Wood KB, Schellhas KP, Garvey TA, Aeppli D (1999) Thoracic discography in healthy individuals. A controlled prospective study of magnetic resonance imaging and discography in asymptomatic and symptomatic individuals. *Spine* 24:1548–1555
67. Zhao CQ, Wang LM, Jiang LS, Dai LY (2007) The cell biology of intervertebral disc aging and degeneration. *Ageing Res Rev* 6:247–261