

Virchows Arch (2007) 450:665–670
DOI 10.1007/s00428-007-0418-3

ORIGINAL ARTICLE

Acute interstitial nephritis of HIV-positive patients under atazanavir and tenofovir therapy in a retrospective analysis of kidney biopsies

Simone Schmid · Milos Opravil · Michael Moddel · Milo Huber · Rahel Pfammatter · Gerald Keusch · Patrice Ambuhl · Rudolf P. Wuthrich · Holger Moch · Zsuzsanna Varga

Received: 12 January 2007 / Revised: 22 March 2007 / Accepted: 4 April 2007 / Published online: 27 April 2007
© Springer-Verlag 2007

Abstract We performed a retrospective analysis on kidney biopsies of 30 human immunodeficiency virus (HIV)-positive patients. Twenty-two of them received highly active antiretroviral therapy (HAART). Tenofovir containing HAART together with atazanavir, a new protease inhibitor, was administered to three patients. All of them developed acute renal failure. The kidney biopsies of these patients showed an acute interstitial nephritis or a chronic interstitial nephritis with an acute component. Withdrawal of atazanavir and tenofovir resulted in recovery of renal function in all three patients. Acute interstitial nephritis was observed only in 1 of 19 patients without atazanavir or tenofovir treatment. We conclude that acute interstitial nephritis and consecutive acute renal failure is a relevant side effect of atazanavir and tenofovir therapy in HIV-positive patients.

Keywords HIV · Interstitial nephritis · Kidney biopsy · Atazanavir

Introduction

Renal disease has become increasingly prevalent in human immunodeficiency virus (HIV)-positive patients [2, 3, 25]. This can be explained by prolonged survival due to improved treatment, resulting in increased long-term complications from the underlying disease [20, 24]. Kidney disease can be caused directly through HIV, opportunistic infections, or drug-related effects [20]. Acute renal failure in HIV infection overall is rare but may be caused by the toxic effects of antiretroviral therapy or nephrotoxic antimicrobial substances used in the treatment of opportunistic infections [2, 24]. Chronic renal disease can be caused by multiple pathophysiological mechanisms, leading to HIV-associated nephropathy (NP), a form of collapsing focal glomerulosclerosis, thrombotic microangiopathy, and various forms of immune complex glomerulonephritis (GN) [20].

HIV-infected patients frequently develop resistance patterns of their virus. Therefore, various new antiretroviral agents were introduced in recent years. Although these medications are effective, they may have unknown side-effect profiles that are discovered only during post-marketing surveillance. Acute renal failure induced by antiretroviral therapy has been described for zidovudine, delavirdine (rhabdomyolysis with myoglobinuria), tenofovir, ritonavir (direct tubular toxicity), and indinavir (crystal NP, acute interstitial nephritis) [20, 23, 24]. Atazanavir is a new protease inhibitor that shows a high specificity for HIV-1 protease. This protease inhibitor was released in

S. Schmid (✉) · H. Moch · Z. Varga
Department of Pathology, Institute of Surgical Pathology,
University Hospital Zurich,
Schmelzbergstrasse 12,
CH-8091 Zurich, Switzerland
e-mail: simone.schmid@usz.ch

M. Opravil · M. Huber
Department of Internal Medicine, Division of Infectious Diseases,
University Hospital Zurich,
Zurich, Switzerland

M. Moddel · R. Pfammatter · G. Keusch
Department of Nephrology, City Hospital Waid,
Zurich, Switzerland

P. Ambuhl · R. P. Wuthrich
Clinic of Nephrology, University Hospital Zurich,
Zurich, Switzerland

2004 [1, 20]. So far, two cases of acute interstitial nephritis under atazanavir therapy have been published in the literature [1, 17]. Consequently, we investigated the frequency of kidney pathology, especially the occurrence of acute interstitial nephritis in kidney biopsies of 30 HIV-positive patients, with special emphasis on atazanavir therapy.

Materials and methods

Patients

The reports of all kidney biopsies in the archives of the Institute of Surgical Pathology, University Hospital Zurich, between 1990 and 2006 were screened for HIV-infected patients (see also “Discussion”). The information on HIV infection came from the clinicians. There were kidney biopsies of 30 HIV-positive patients, 15 of which were performed because of renal function impairment (Table 1). Histological slides and ultrastructural findings were reevaluated in each patient (S.S, Z.V). There were 21 male and 9 female patients with an age of 23 to 63 years (median 35 years). Three patients were of African origin. Twenty-two patients received highly active antiretroviral therapy

(HAART). Four patients received tenofovir-containing HAART, three of them together with atazanavir. Three other patients received indinavir-containing HAART.

Clinical data are summarized in Tables 1, 3, and 4.

Histology and light microscopy

Tissue specimens had been routinely fixed in 4% formaldehyde and embedded in paraffin. Sections were cut (2 μ m thick) and attached to polylysine-coated glass slides. Routine hematoxylin and eosin stains were performed as well as special staining procedures: periodic acid-Schiff (PAS), acid fuchsin-Orange G (SFOG), Elastin–van Gieson (EVG), and silver on all slides. Renal diseases were diagnosed according to criteria by textbooks [4, 6, 13, 15, 22]. The diagnosis of acute interstitial nephritis required interstitial edema, increased lymphocytes, and tubulitis. Eosinophilic granulocytes were present in two of three cases.

Immunofluorescence/immunohistochemistry

In all cases, stains for IgA (1:30 dilution, Dako, Glostrup, Denmark), IgG (1:25 dilution, Dako), IgM (1:40 dilution, Dako), and C3 (1:80 dilution, Dako) and, in some cases, also for C1q (1:20 dilution, Dako), kappa (1:20 dilution, Dako), and lambda (1:30 dilution, Dako) were performed on frozen sections by using the standardized Ventana Benchmark system (Ventana Medical Systems, Tucson, AZ). The reaction products were visualized with the iVIEW DAB detection kit on the Ventana Benchmark system according to the manufacturer’s recommendations. If no fresh tissue was available, immunohistochemical reactions for IgA, IgG, IgM, and C3 were carried out on paraffin sections via the same procedure.

Following markers were tested immunohistochemically on paraffin sections on the cases with acute interstitial nephritis: T cell and B cell markers: CD4 (1:10 dilution, Novocastra, Newcastle, UK), CD8 (1:100 dilution, Dako), CD20 (1:400 dilution, Dako); Granzyme B (1:25 dilution, Dako), Fas (1:20 dilution, Novocastra), TIA-1 (1:400 dilution, Immunotech S.A., Marseille, France), FoxP3 (1:50 dilution, Abcam, Cambridge, UK).

Electron microscopy

Specimens were processed according to standard procedures as follows: The kidney biopsy was fixed in phosphate-buffered 2.5% glutaraldehyde and 2% osmium tetroxide, dehydrated in alcohol and propylene oxide, and embedded in Epon. Ultrathin sections were cut, contrasted

Table 1 Summary of clinical data

	Values
Age	23–63
Gender	
Male/female	21/9
Antiviral therapy	22/30
Atazanavir	3
Tenofovir	4
Ritonavir	8
Lopinavir	6
Lamivudine	11
Emtricitabine	1
Didanosine	3
Zidovudine	7
Efavirenz	2
Abacavir	4
Indinavir	3
Nelfinavir	2
Stavudine	2
Foscarnet	1
Clinical symptoms	
Proteinuria	21
Hematuria	13
Renal insufficiency	15
Acute renal failure	5
Nephrotic syndrome	3

with uranyl acetate and lead citrate, and examined by transmission electron microscope.

Results

A variety of histopathological lesions were diagnosed in the 30 kidney biopsies (Table 2).

Immune complex GN was the most common histological finding, identified in 13 patients: 4 membranous GN, 3 membranoproliferative GN (1 type 1 and 2 type 3), 2 IgA NP, 1 postinfectious GN, 1 immunotactoid GN, 1 anti-GBM-GN, 1 immune complex GN not otherwise specified. Two of three patients with membranoproliferative GN were coinfecting with hepatitis C virus, and one had visceral leishmaniasis.

Interstitial nephritis was diagnosed in six patients. Five patients were treated with antiretroviral therapy, the combination of atazanavir and tenofovir was taken by three of them. These latter three patients all showed acute interstitial nephritis (Fig. 1), two of them also signs of chronicity (interstitial fibrosis and tubular atrophy). Withdrawal of atazanavir and tenofovir resulted in recovery of renal function in all three patients.

Only in one of these three patients, there was a focal acute tubular necrosis as a minor component, which is the typical described manifestation of tenofovir on the kidney. One additional patient, who was administered foscarnet without anti-HIV therapy, also exhibited acute interstitial nephritis. Chronic interstitial nephritis was observed in two patients (one patient had received no antiretroviral therapy, the other patient had been treated with zidovudine, lamivudine, indinavir). The majority of the infiltrating interstitial lymphocytes were CD8 positive T cells, to lesser extent CD4 positive T cells were also present. There were a few CD20 positive B cells mixed within the T cell population. Lymphocytes in all cases showed focal positivity for Granzyme B, TIA-1, and FoxP3. Stains for Fas were not conclusive.

Table 2 Summary of renal changes

Diagnosis	Number of patients (<i>n</i>)
Immune complex glomerulonephritis	13
Interstitial nephritis	6
Acute tubular necrosis	5
Thrombotic microangiopathy	4
Focal segmental glomerulosclerosis	5
Vascular changes	2
Pyelonephritis	1
HIV-associated nephropathy	2
Indinavir crystal nephropathy	1
Amyloidosis	1

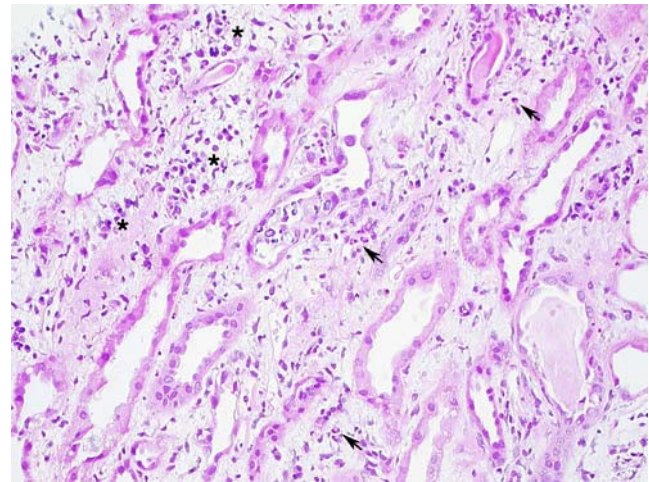


Fig. 1 Acute interstitial nephritis. The renal tubuli are separated through interstitial edema and increased inflammatory cells, as lymphocytes and plasma cells (*asterisk*) as well as eosinophilic granulocytes (*arrows*). HE, $\times 200$

Details of patients' medication with acute interstitial nephritis are summarized in Tables 3 and 4.

Acute tubular necrosis was seen in five patients. Only one patient showed acute tubular necrosis without other findings during treatment with tenofovir, didanosine, lopinavir, ritonavir, esomeprazole, paracetamol. This patient had additionally received a contrast medium 1 month earlier. Acute tubular necrosis was observed as an epiphenomenon in the other four patients accompanying IgA NP, membranous GN, or interstitial nephritis.

Focal segmental glomerulosclerosis (FSGS) was observed in five patients. Two of these patients had a collapsing variant of FSGS (classical HIV-associated NP), both patients were of African origin.

Thrombotic microangiopathy was seen in four patients. Two biopsies with mainly vascular changes included one diabetic NP and one hypertensive NP. Renal changes caused by opportunistic infections were not observed in any of the cases in our series.

Tubuloreticular aggregates, which can be found in glomerular endothelium cells of HIV-positive patients and patients with systemic lupus, were detected by ultrastructural examination in 13 patients. They were less frequent in patients treated with HAART (30%) than in patients without antiretroviral therapy (75%).

Discussion

In this study, we identified three patients who presented with acute renal failure and acute interstitial nephritis in the

Table 3 Patients with acute renal failure and acute interstitial nephritis

Patients	Diagnosis	Drugs
51-year-old man	Acute interstitial nephritis	Atazanavir, tenofovir, ritonavir, lamivudine (all since 3 months); amoxicillin/clavulanic acid, oxazepam, methadone, esomeprazole
44-year-old woman	Chronic interstitial nephritis with acute component	Atazanavir, tenofovir, ritonavir, emtricitabine (all since 6 weeks)
63-year-old man	Chronic interstitial nephritis with acute component and focal tubular necrosis	Atazanavir (since 4 months), lopinavir/ritonavir (since 4.5 years), tenofovir (since 17 months), lamivudine (since 4 years), didanosine (since 4 months), acidum salicylicum, clopidogrelum, calcium acetate, spironolactone, metoprolol succinas, epoetin beta, insuline, atorvastatine, rosiglitazone
31-year-old man	Acute to subacute interstitial nephritis with focal acute tubular necrosis	Foscarnet, aluminii oxidum hydricum/magnesii hydroxidum, ranitidine, calcium acetate, sucralfate

biopsy while receiving atazanavir and tenofovir containing HAART. These were the only three patients who presented with acute interstitial nephritis while receiving an antiretroviral therapy.

Improved survival of patients with HIV infection was reached with antiretroviral therapy, but may result in side effects of medication, especially in HAART-associated complications [20, 24]. Since the introduction of HAART, a wide range of renal side effects and adverse drug reactions have been recognized, varying from proteinuria to acute renal failure [20, 23, 24]. Not much data are available on side effects and kidney pathology arising under atazanavir therapy [20]. Only two patients with acute interstitial nephritis have been reported in the literature so far, one of them is a patient in our study [1, 17]. According to our knowledge, no systematic clinicopathological case

series has analyzed the incidence of acute interstitial nephritis under atazanavir therapy up to now.

In our series, the three cases of acute interstitial nephritis during HAART occurred during concomitant therapy with atazanavir and tenofovir, and the kidney function normalized after both atazanavir and tenofovir were stopped. Based on treatment history, we cannot attribute this phenomenon to one of the drugs alone. In all three patients, the acute interstitial nephritis occurred between 6 and 16 weeks after starting ritonavir-boosted atazanavir. Two of these patients had initiated tenofovir together with atazanavir, while the third patient had been receiving tenofovir already for 17 months without previous increase in serum creatinine. This time course, thus, favors atazanavir to be the causative agent, which is also supported by the histological picture of interstitial nephritis without tubular

Table 4 Clinical data and time course of three patients with acute interstitial nephritis under atazanavir and tenofovir

	51-year-old man	44-year-old woman	63-year-old man
CDC stage	C2	C3	A3
Actual CD4 (count/ μ l)	269	160	415
Duration anti-HIV therapy	13 months	6 weeks	9.5 years
Duration atazanavir	3 months	6 weeks	4 months
Duration tenofovir	3 months	6 weeks	17 months
Other illnesses	Alcohol abuse, emphysema	i.v. drug use	Diabetes mellitus, coronary heart disease
Serum creatinine before start of atazanavir (μ mol/l)	Normal	68	96
Peak serum creatinine (μ mol/l)	913	302	622
Calculated GFR (ml/min, Cockcroft)	8	14	11
Urine protein (g/l)	0.75	0.5	1.0
Other abnormal urine results	Erythrocytes \uparrow	Leucocytes \uparrow , erythrocytes (\uparrow)	Glucose \uparrow
Urine eosinuria	nd	nd	nd
Blood eosinophils (/ μ l)	200	50	240
Subsequent HAART with normalization of serum creatinine	Nevirapine, abacavir, lamivudine	Lopinavir/ritonavir, zidovudine, lamivudine	Lamivudine (monotherapy)

Histology and complete list of medication is given in Table 3

nd Not done

necrosis. Although there are several reports of renal insufficiency associated with tenofovir, the overall occurrence is rare, and only few of these patients had kidney biopsies [14, 19, 21]. The typical picture of tenofovir NP was extensive acute tubular necrosis [14, 19, 20]. There are no published reports of acute interstitial nephritis due to tenofovir; however, the European Medicines Agency recently included acute interstitial nephritis as one of the possible adverse reactions to tenofovir [5].

We cannot exclude a potential additive effect of atazanavir and tenofovir on the development of NP. In addition, atazanavir and tenofovir given together display significant interactions, with lowering of atazanavir and increasing of tenofovir plasma levels [18]. Ritonavir also increases the plasma concentrations of tenofovir. Interestingly, the combination of tenofovir with protease inhibitors seems to impair the kidney function at a higher magnitude than tenofovir with non-nucleoside reverse transcriptase [8, 9].

In the Zurich site of the Swiss HIV Cohort Study, which covers the majority of patients whose kidney biopsies would be sent to our hospital, 670 patients have received atazanavir, and 1,230 received tenofovir since their first use in 2000. Because not all treated patients in our area participate in the Swiss HIV Cohort Study, we estimate the risk of acute interstitial nephritis to be less than 0.57% (3 of 524 patients) among those who received both atazanavir and tenofovir within the framework of the Cohort Study in the last 6 years.

Atazanavir was registered in 2004. It is known to bear a favorable side-effect profile with significantly fewer lipid changes as compared to other protease inhibitors [7, 12, 16, 20]. The underlying mechanism of acute interstitial nephritis caused by atazanavir is not clear. Brewster and Perazella [1] speculate on a hypersensitivity reaction as a possible explanation for this phenomenon. The presence of eosinophilic granulocytes in two of our three cases would support this theory. We demonstrated a prevailing subset of CD8 positive T cells and some CD4 positive T cells in the interstitial lymphocytes, which supports a potential role of cell mediated mechanisms in the pathogenesis of tubulointerstitial nephritis in our patients [13]. A granulomatous reaction, usually occurring in delayed type hypersensitivity reactions caused by CD4 positive lymphocytes, could not be detected in our series. A cytotoxic T cell injury, mediated by CD4 and CD8 positive T cells, does not require prior sensitization, which is therefore a potential underlying mechanism of the tubulointerstitial injury [13]. The presence of activated cytotoxic T cells in our patients may point to this pathomechanism.

Acute renal failure as a side effect of antiretroviral therapy has been described in the literature [20, 23, 24]. Rhabdomyolysis with myoglobinuria was reported under zidovudine and delavirdine therapy [20, 23, 24]. Indinavir-

induced crystal NP and acute tubular damage due to tenofovir and ritonavir are well-known side effects of drugs used for HIV treatment [20, 23, 24]. Tenofovir was administered together with atazanavir in all three patients; nevertheless, an extensive acute tubular necrosis, as a known side effect of tenofovir therapy, did not occur; we could demonstrate only a focal acute tubular necrosis in one of these patients.

Tubulointerstitial injuries, as inflammation, fibrosis, or tubular atrophy, are common features in interstitial nephropathies. If the underlying tubular or interstitial damage cannot be eliminated, these changes can give rise to chronic interstitial nephritis [13]. Furthermore, acute and chronic changes in the same tubulointerstitial compartment can coexist if etiologic factors become repeatedly manifest [13].

The frequency of interstitial nephritis in HIV infection varies in the literature. Diversity in its occurrence is mainly due to patient selection after and before antiretroviral therapies [10, 22]. In a recent study of Han et al. [11], 615 HIV-positive patients, all of them without antiretroviral therapy, were screened for proteinuria. Thirty patients were selected and underwent renal biopsy. Interstitial nephritis was only seen in 3 of 30 patients (10%). In an earlier autopsy study, Hailemariam et al. [10] determined the percentage of interstitial nephritis in Swiss HIV-positive patients, not treated with HAART, and reported a low prevalence with 14 of 239 patients (5.9%). However, of these 239 patients, 64% did not show clinical signs of NP before death. Therefore, the prevalence of interstitial nephritis might be higher in the group with clinical signs of NP.

Our study includes a time span after the introduction of HAART therapy. This might explain the higher prevalence of interstitial nephritis as compared to Han et al. and Hailemariam et al. [10].

The real frequency of interstitial nephritis arising under atazanavir and tenofovir therapy is, however, unclear. One reason is the patient selection. Not all patients receiving atazanavir and tenofovir will undergo kidney biopsy during the disease course. Subclinical or clinical acute interstitial nephritis, therefore, cannot be diagnosed and could be well missed in a subset of patients receiving this medication. Prospective studies with clearly defined patient collectives and protocol kidney biopsies will be necessary to address the incidence of acute interstitial nephritis under atazanavir and tenofovir therapy.

Interestingly, our study confirms that HIV-associated NP, a collapsing variant and secondary form of FSGS, is predominantly a disease of black patients, because we have observed this NP only in the black patients of our group. A variety of other glomerular diseases have been described in HIV-infected patients, as thrombotic microangiopathy and various forms of immune complex GN. According to the

literature [3, 4, 22], one of the most common immune complex-mediated glomerular lesion is membranoproliferative GN, particularly in HIV-infected patients coinfecting with hepatitis C virus. These patients develop membranoproliferative GN type 1 or type 3 (with mixed membranous features). IgA NP, membranous GN, lupus-like GN, and immunotactoid GN are other immune complex-mediated glomerular lesions found in HIV-positive patients. The glomerular changes seen in our series correlate well with these data in the literature. Membranoproliferative GN, membranous GN, and IgA NP were the most commonly diagnosed immune complex-mediated glomerular diseases. In addition, in our study, membranoproliferative GN was particularly observed in HIV-infected patients coinfecting with hepatitis C virus. It consisted of type 1 and type 3 membranoproliferative GN. Besides immune complex GN, thrombotic microangiopathy was a frequent lesion.

In summary, our findings show that acute interstitial nephritis can occur under atazanavir and tenofovir therapy. This side effect of antiretroviral medication should be considered in treatment planning for HIV-positive patients.

Acknowledgments The technical assistance of Mrs. Juliane Bigott and Mrs. Doris Guntersweiler is highly appreciated. Mr. N. Wey helped in the illustration. The study complies with the current ethical laws of the involved institutions.

References

- Brewster UC, Perazella MA (2004) Acute interstitial nephritis associated with atazanavir, a new protease inhibitor. *Am J Kidney Dis* 44:e81–e84
- Cho ME, Kopp JB (2004) HIV and the kidney: a status report after 20 years. *Curr HIV/AIDS Rep* 1:109–115
- D'Agati V, Appel GB (1998) Renal pathology of human immunodeficiency virus infection. *Semin Nephrol* 18:406–421
- D'Agati V, Jennette J, Silva F (2005) Non-neoplastic kidney diseases. ARP Press, Silver Spring, MD
- European Medicines Agency (2006) <http://www.emea.eu.int/humandocs/PDFs/EPAR/viread/351001en8b.pdf>; accessed on 8 Mar 2007
- Fogo A, Kashgarian M (2005) Diagnostic atlas of renal pathology, 1st edn. Elsevier, Saunders
- Friedland G, Andrews L, Schreiber T, Agarwala S, Daley L, Child M, Shi J, Wang Y, O'Mara E (2005) Lack of an effect of atazanavir on steady-state pharmacokinetics of methadone in patients chronically treated for opiate addiction. *Aids* 19:1635–1641
- Fux C, Simcock M, Wolbers M, Bucher H, Cavassini M, Opravil M, Vernazza P, Hirschel B, Bernasconi E, Furrer H, Swiss HIV Cohort Study S (2007) Tenofovir treatment is associated with a decrease in calculated glomerular filtration rates in a large observational cohort. In: 14th Conference on retroviruses and opportunistic infections, Los Angeles, USA, 25–28 February
- Goicoechea M, Liu S, Best B, Sun S, Jain S, Kemper C, Witt M, Diamond C, Haubrich R, Louie S, California Collaborative Treatment Group CT (2007) Increased renal impairment in patients receiving TDF+PI vs TDF+NNRTI. In: 14th Conference on retroviruses and opportunistic infections, Los Angeles, USA, 25–28 February
- Hailemariam S, Walder M, Burger HR, Cathomas G, Mihatsch M, Binswanger U, Ambuhl PM (2001) Renal pathology and premortem clinical presentation of Caucasian patients with AIDS: an autopsy study from the era prior to antiretroviral therapy. *Swiss Med Wkly* 131:412–417
- Han TM, Naicker S, Ramdial PK, Assounga AG (2006) A cross-sectional study of HIV-seropositive patients with varying degrees of proteinuria in South Africa. *Kidney Int* 69:2243–2250
- Izzedine H, Launay-Vacher V, Peytavin G, Valantin MA, Deray G (2005) Atazanavir: a novel inhibitor of HIV-protease in haemodialysis. *Nephrol Dial Transplant* 20:852–853
- Jennette JC, Olson JL, Schwartz M, Silva F (2007) Heptinstall's pathology of the kidney, 6th edn. Lippincott Williams & Wilkins
- Karras A, Lafaurie M, Furco A, Bourgarit A, Droz D, Sereni D, Legendre C, Martinez F, Molina JM (2003) Tenofovir-related nephrotoxicity in human immunodeficiency virus-infected patients: three cases of renal failure, Fanconi syndrome, and nephrogenic diabetes insipidus. *Clin Infect Dis* 36:1070–1073
- Kern W, Laszik Z, Nadasdy T, Silva F, Bane B, Pitha J (1999) Atlas of renal pathology. Saunders, Philadelphia
- Kim RJ, Wilson CG, Wabitsch M, Lazar MA, Steppan CM (2006) HIV protease inhibitor-specific alterations in human adipocyte differentiation and metabolism. *Obesity (Silver Spring)* 14:994–1002
- Moddel M, Pfammatter R, Varga Z, Keusch G (2006) Acute tubulointerstitial nephritis in HIV infection. *Schweiz Rundsch Med PRAXIS* 95:949–951
- Panel on Antiretroviral Guidelines for Adult and Adolescents (2006) Guidelines for the use of antiretroviral agents in HIV-infected adults and adolescents. Department of Health and Human Services, October 10, 2006. Available at <http://www.aidsinfo.nih.gov/ContentFiles/AdultandAdolescentsGL.pdf>. Accessed 8 Mar 2007, pp 1–113
- Peyriere H, Reynes J, Rouanet I, Daniel N, de Boever CM, Mauboussin JM, Leray H, Moachon L, Vincent D, Salmon-Ceron D (2004) Renal tubular dysfunction associated with tenofovir therapy: report of 7 cases. *J Acquir Immune Defic Syndr* 35:269–273
- Roling J, Schmid H, Fischereder M, Draenert R, Goebel FD (2006) HIV-associated renal diseases and highly active antiretroviral therapy-induced nephropathy. *Clin Infect Dis* 42:1488–1495
- Scott JD, Wolfe PR, Bolan RK, Guyer B (2006) Serious renal impairment occurs rarely with use of tenofovir DF. *HIV Clin Trials* 7:55–58
- Striker G, Striker L, D'Agati V (1997) The renal biopsy, 3rd edn. Saunders
- Szeto CC, Chow KM (2005) Nephrotoxicity related to new therapeutic compounds. *Ren Fail* 27:329–333
- Valle R, Haragsim L (2006) Nephrotoxicity as a complication of antiretroviral therapy. *Adv Chronic Kidney Dis* 13:314–319
- Wyatt CM, Klotman PE (2006) Antiretroviral therapy and the kidney: balancing benefit and risk in patients with HIV infection. *Expert Opin Drug Saf* 5:275–287