

Int Ophthalmol (2007) 27:105–115
DOI 10.1007/s10792-007-9052-y

PERSPECTIVES & EXPERT OPINIONS

Work-up, diagnosis and management of acute Vogt-Koyanagi-Harada disease

A case of acute myopization with granulomatous uveitis

Alessandro Mantovani · Anna Resta · Carl P. Herbort ·
Ahmed Abu El Asrar · Tatsushi Kawaguchi · Manabu Mochizuki ·
Annabelle A. Okada · Narsing A. Rao

Received: 14 December 2006 / Accepted: 6 February 2007 / Published online: 5 May 2007
© Springer Science+Business Media B.V. 2007

Abstract

Purpose In its typical form and when seen at onset, Vogt-Koyanagi-Harada (VKH) is characterized by easily recognizable signs that allow diagnosis without difficulty. In cases that do not have acute onset, that are seen at a later stage or that do not show the complete set of signs, appraisal is more difficult and diagnosis may cause difficulties. We present here a

case of bilateral granulomatous uveitis compatible with VKH disease in order to allow several experts to give their opinion on the most appropriate manner to confirm or reject the diagnosis and their approach to the management of the case.

Case presentation A 17-year-old female patient consulted her ophthalmologist for blurred vision OU following an episode of a flu-like disease with malaise, fever and headaches. A bilateral anterior granulomatous uveitis with a right papillitis was diagnosed and the patient presented with a bilateral acute myopization. Fluorescein angiography showed right disc hyperfluorescence with late leakage and slight left disc hyperfluorescence. The patient was given a course of one week of peroral corticosteroid therapy followed by an intramuscular injection of Bentelan[®] twice weekly. In the absence of significant improvement the patient was sent six weeks later to a

This section is devoted to updates in controversial or hot clinical or scientific issues or to the publication of opinions in the management of practical clinical situations. In “Perspectives” controversial or hot topics are addressed by leaders or experts in a field either by giving their perspective on the topic, or by revisiting the appraisal of a topic. Usually more than one author is invited. In “Expert Opinions” a clinical case is presented and different experts in the field are solicited to express their expert opinion in the management of a given clinical situation.

A. Mantovani · A. Resta
Unit of Ophthalmology, Ospedale Valduce, Como, Italy

C. P. Herbort (✉)
Inflammatory and Retinal Eye Diseases, Center for
Ophthalmic Specialized Care, Avenue des Bergières 2,
1004 Lausanne, Switzerland
e-mail: carl-herb@bluewin.ch

C. P. Herbort
University of Lausanne, Lausanne, Switzerland

A. Abu El Asrar
Department of Ophthalmology, King Abdulaziz
University Hospital, Riyadh, Saudi Arabia

T. Kawaguchi · M. Mochizuki
Department of Ophthalmology & Visual Science, Tokyo
Medical and Dental University Graduate School of
Medicine, Tokyo, Japan

A. A. Okada
Department of Ophthalmology, Kyorin University School
of Medicine, Mitaka, Tokyo, Japan

N. A. Rao
Doheny Eye Institute, Los Angeles, USA

specialized center where a complete work-up was performed.

Expert opinion The diagnostic work-up, investigational tests, and differential diagnosis to confirm or reject the diagnosis of VKH as well as the management of the case will be described by the experts.

Keywords Bilateral anterior granulomatous uveitis · Papillitis · Acute myopization

Introduction

Vogt-Koyanagi-Harada disease, when presenting in its typical clinical expression and when occurring in a geographic area where the disease is prevalent, is a well-characterized disease not causing major diagnostic problems either because it is sufficiently typical or because clinicians are used to diagnose it [1]. Diagnostic criteria were defined back in 1980 but are difficult to use as they mix signs and symptoms of acute and chronic disease that do not usually coexist [2]. To diagnose acute VKH disease bilateral exudative retinal detachments without any known history of ocular trauma are needed following these diagnostic criteria. In 2001 the first workshop on VKH at Lake Arrowhead, California published revised diagnostic criteria for VKH that distinguish between acute and chronic signs and are useful for reporting cases in studies but are still unsatisfactory for practical use as they do not include new, more-sensitive diagnostic modalities such as indocyanine green angiography [3]. In cases of suspected VKH disease that do not have acute onset, that are seen at a later stage or that do not show the complete set of signs, diagnosis of VKH becomes more difficult. In atypical cases clinicians should use all possible diagnostic means to reach a diagnosis without delay, as early and appropriate therapy is essential for this disease [4]. Another reason to use more invasive diagnostic modalities to reach a high probability of correct diagnosis is that the proposed therapy will be heavy and prolonged.

Case report

A 17-year-old female patient consulted her ophthalmologist for blurred vision OU following an episode of a flu-like disease with malaise, fever and headaches. A bilateral granulomatous anterior uveitis with a right

papillitis was diagnosed and the patient presented bilateral acute myopization. The patient was given a course of one week of peroral corticosteroid followed by intramuscular injections of Bentelan[®] (betamethasone sodium bi-phosphate 4 mg) twice a week. In the absence of significant improvement the patient was sent six weeks later to the ophthalmology unit of the Ospedale Valduce in Como, Italy and the patient was also seen in the Center for Inflammatory Eye Diseases, Centre for Ophthalmic Specialized Care, La Source, Lausanne, Switzerland. When the patient was seen, she had been again under peroral prednisone (50 mg/day) for one week and systemic Aulin[®] (nimesulfide), a nonsteroidal anti-inflammatory agent. Locally the therapy consisted of dexamethasone phosphate 0.1% drops QID and dilating drops. Visual acuity on the right was 0.2 without correction, improving to 0.9 with a correction of sph. -2.25 . Visual acuity on the left was 0.1 without correction, improving to 0.6 with a correction of sph. -2.5 . There were granulomatous keratic precipitates (KPs) on the endothelium on both sides. The anterior chamber showed a 2+ flare OU and 1+ cells in the anterior chamber. Laser flare photometry showed appreciable inflammation with values of 49.2 ph/ms OD and 84.6 ph/ms OS. Intraocular pressure was 6–7 mmHg OU. There was a vitreous cellular infiltration of 2+ OU. Examination of the fundus showed disc swelling OD and the maculas were radially wrinkled OU (Fig. 1). The visual fields showed

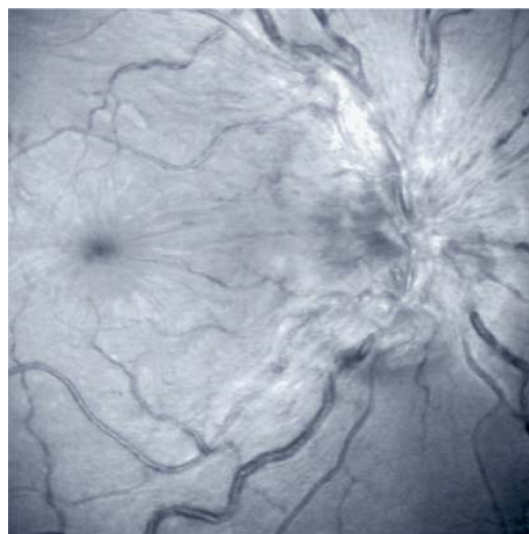


Fig. 1 Red-free photograph of the posterior pole of the right eye showing disc swelling

relative scotomas and a decrease of the mean sensitivity OU (Fig. 2). Fluorescein angiography showed right disc hyperfluorescence with massive late exudation and slight left disc hyperfluorescence (Fig. 3a, b). Optical coherence tomography performed with the scanning laser ophthalmoscope-optical coherence tomography (SLO/OCT) system produced by Ophthalmic Technologies (OTI, Toronto, Canada) clearly showed the wrinkles of the retina-vitreous interface on the coronal C-scans as well as a probable fine layer of subretinal fluid OU (Fig. 4a, b). Ultrasound biomicroscopy (UBM) examination of the ciliary body showed supraciliary effusion, explaining the myopization noted since the beginning of the inflammatory episode (Fig. 5a, b).

In summary, this 17-year-old girl presented a bilateral granulomatous anterior uveitis with supraciliary effusions OU, bilateral vitritis, prominent right papillitis and slight left papillitis resistant to a systemic dose of 50 mg of prednisone per day. A complete re-evaluation of the situation was decided. At this point expert opinion is solicited on the diagnostic work-up, investigational tests, differential diagnosis to confirm or invalidate the potential diagnosis of VKH as well as on the management of the case.

Expert opinions

1. Ahmed Abu El Asrar (Saudi Arabia)

A 17-year-old female who presented with blurred vision of both eyes following an episode of flu-like

disease, bilateral granulomatous anterior uveitis, vitreous cells, optic nerve head swelling and retinal folds in the macular area (Fig. 1). Fluorescein angiography showed optic nerve head early leakage and late staining in both eyes, which was more intense in the right eye and multiple pinpoint areas of leaks in the peripapillary area in the right eye (Fig. 3). Optical coherence tomography revealed very shallow bilateral exudative retinal detachment (Fig. 4). Ultrasound biomicroscopy examination showed supraciliary body effusion (Fig. 5).

Vogt-Koyanagi-Harada disease should be considered. The hallmark of active uveitis in Vogt-Koyanagi-Harada disease is bilateral exudative retinal detachments associated with hyperemia and edema of the optic nerve head. The patient's ethnic background is important, as Asians, Native Americans, Hispanics, Asian Indians and Middle Easterners are affected most frequently [1]. The patient should be questioned and examined carefully for the presence of poliosis of the eyebrows, eyelashes, and scalp hair, alopecia, and vitiligo. She should also be asked about hearing loss. At this point, I would suggest routine laboratory studies including complete blood cell count, erythrocyte sedimentation rate, chest X-ray, venereal disease research laboratory test, fluorescent treponemal antibody absorption test, blood chemistry, urinalysis, and tuberculin skin testing. In addition, I would do indocyanine green angiography, and ultrasonography, and order full audiologic assessment. In an active disease, ultrasonography shows diffuse thickening of the choroids [2]. Indocyanine green angiography is useful in delineating the pattern of choroidal involvement and to monitor the effect of

Fig. 2 Computerized visual fields performed with the Octopus[®] instrument, showing decrease of mean sensitivity and relative scotomata bilaterally

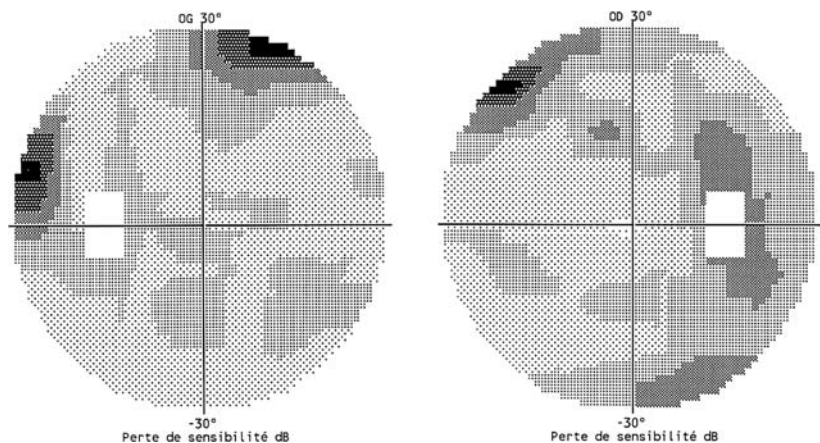
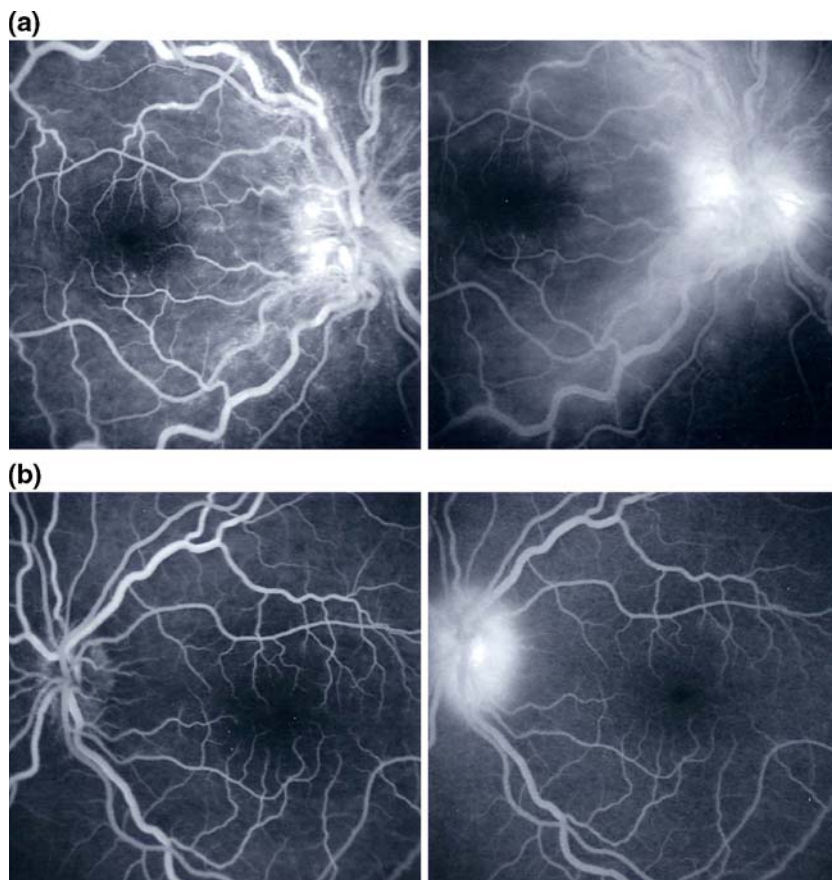


Fig. 3 (a) Fluorescein angiography OD: disc hyperfluorescence and profuse leakage along the temporal arcade on the right side. (b) Fluorescein angiography OS: late disc hyperfluorescence



treatment [5, 6].¹ In our patients with Vogt-Koyanagi-Harada disease, sensory hearing loss was documented in about 50% of patients after full audiologic assessment including pure-tone audiogram, tympanogram, auditory brain-stem response, autoacoustic emission, and caloric test [3]. In our setting, lumbar puncture is rarely necessary as history, clinical examination, ultrasonography, and fluorescein angiography are usually sufficient to establish the diagnosis of Vogt-Koyanagi-Harada disease. However, lumbar puncture is a useful adjunctive test in cases of atypical Vogt-Koyanagi-Harada disease to confirm the diagnosis.

Early and aggressive high-dose systemic corticosteroid therapy has become the mainstay of therapy in Vogt-Koyanagi-Harada disease [4, 5]. It is clear that this patient was not adequately treated with corticosteroids. I would recommend treatment with intrave-

nous methylprednisolone 1 g daily for three days followed by oral prednisone 1 mg/kg/day with slow tapering over 9–12 months depending on the clinical response. Our study identified a significant association between final visual acuity of 20/20 and use of systemic corticosteroid therapy for longer than nine months. In addition, we demonstrated a significant association between rapid tapering of systemic corticosteroid therapy and worse final visual acuity, and recurrent episodes of inflammation [3].

References

1. Read RW, Rao NA, Cunningham ET Jr (2000) Vogt-Koyanagi-Harada disease. *Curr Opin Ophthalmol* 11:437–442
2. Forster DJ, Cano MR, Green RL, Rao NA (1990) Echographic features of the Vogt-Koyanagi-Harada syndrome. *Arch Ophthalmol* 108:1421–1426
3. Al-Kharashi AS, Aldibhi H, Al-Fraykh H, Kangave D, Abu El-Asrar AM Prognostic factors in

¹ List of references after the case report.

Fig. 4 (a) Optical coherence tomography (OCT): coronal C-scan performed with the OTI SLO/OCT optical coherence tomograph in the right eye, showing the wrinkled surface of the retina. (b) OCT: sagittal B-scan-mode section performed with the OTI SLO/OCT optical coherence tomograph in the right eye, showing a hyporeflective layer between retina and retinal pigment epithelium, indicating subretinal fluid not seen on fluorescein angiography

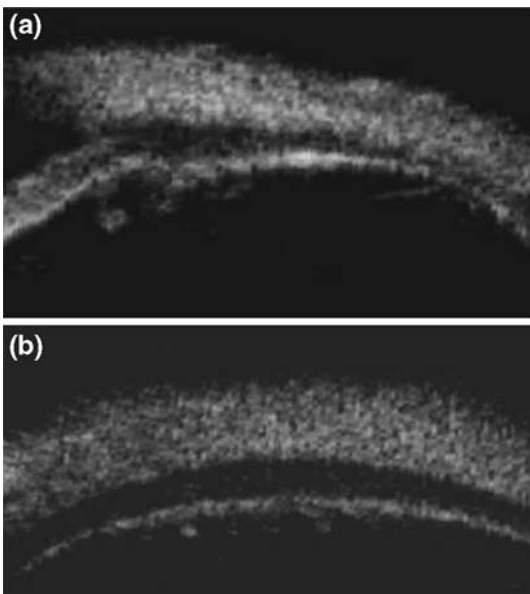
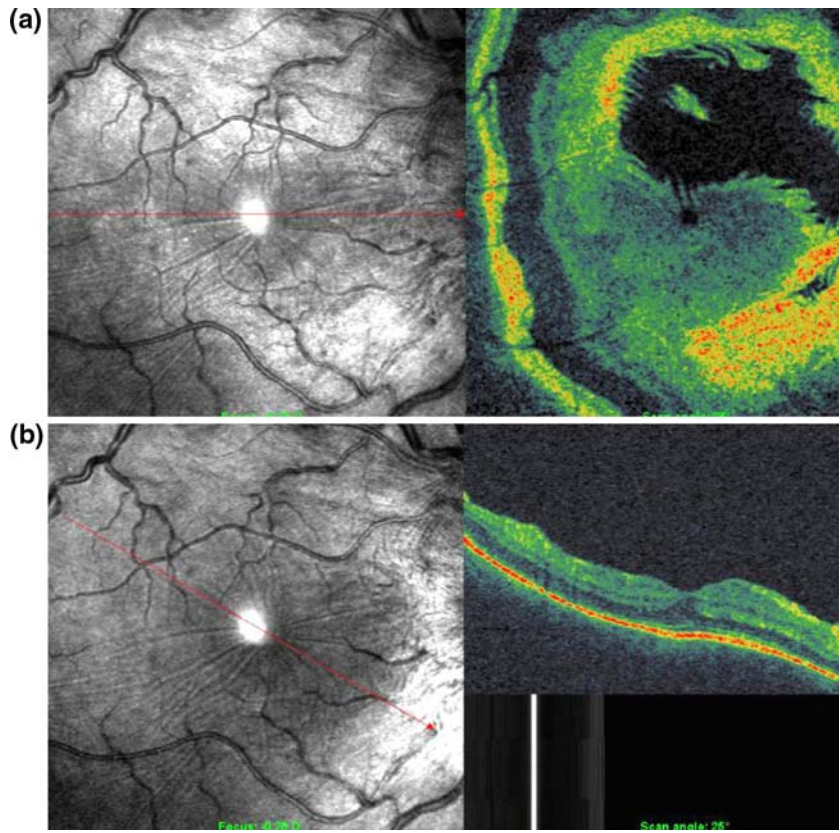


Fig. 5 (a) Ultrasound biomicroscopy (UBM) showing supraciliary effusion on a radial scan. (b) UBM: scan parallel to the limbus at the level of the ciliary body situated slightly posterior to the pars plicata, showing supraciliary fluid

Vogt-Koyanagi-Harada disease. *Int Ophthalmol* (in press)

4. Rubsamen PE, Gass DM (1991) Vogt-Koyanagi-Harada syndrome. Clinical course, therapy, and long-term visual outcome. *Arch Ophthalmol* 109:682–687
5. Ohno S, Minakawa R, Matsuda H (1988) Clinical studies of Vogt-Koyanagi-Harada's disease. *Jpn J Ophthalmol* 32:334–343
6. Bouchenaki N, Herbort CP (2001) The contribution of indocyanine green angiography to the appraisal and management of Vogt-Koyanagi-Harada disease. *Ophthalmology* 108:54–64

2. Tatsushi Kawaguchi and Manabu Mochizuki (Japan)

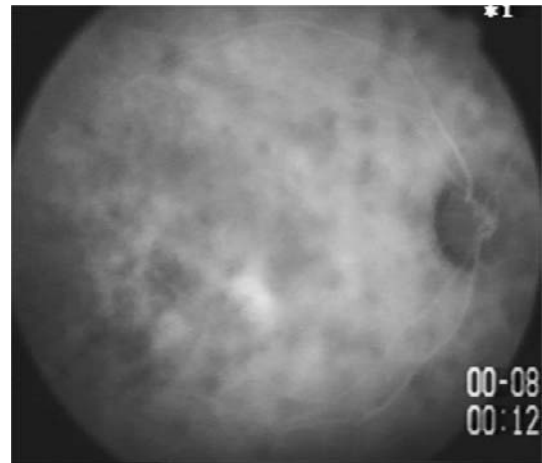
Clinical features of this patient are compatible with Vogt-Koyanagi-Harada (VKH) disease although ocular signs of the patient are atypical for VKH disease. It is known that some proportion of VKH disease

sufferers exhibit bilateral papillitis with minimal exudative retinal detachment; this is classified as papillitis-type VKH disease in Japan. Acute myopization accompanied by a shallow anterior chamber at the active stage of VKH disease has been previously reported [1, 2] and is a common ocular manifestation of the disease in Japan. Ultrasound biomicroscopy (UBM) is useful for the assessment of anterior chamber depth and exudative detachment of the ciliary body [3, 4], which can cause shallow anterior chamber and acute myopization.

Considering bilateral granulomatous anterior uveitis concomitant with papillitis, sarcoidosis, multiple sclerosis and chronic idiopathic anterior uveitis in young girls might be listed as differential diagnosis. Required investigational tests in this patient are serum ACE, serum lysozyme and chest X-ray for sarcoidosis. Cerebrospinal fluid (CSF) examination and magnetic resonance imaging (MRI) examination of the central nervous system and an audiogram should be done to differentiate VKH disease and multiple sclerosis. CSF examination in patients with VKH disease shows pleocytosis with mononuclear cells and/or melanin-laden macrophages [5].

As for ophthalmic examinations, indocyanine green angiography (ICGA) should be done to examine whether the choroidal inflammatory lesions are present, despite the fact that ophthalmoscopic examination and fluorescein angiography revealed minimal changes in the ocular fundus. In the acute stage of VKH disease, ICGA demonstrates filling delay of choroidal vessels at early phase, followed by multiple dark spots in the choroid at late phase (Figure). Multiple dark spots at late phase are considered to reflect the granulomatous choroidal lesions. These ICGA findings can be used as signs of active choroidal inflammation.

Because moderate dosage of systemic corticosteroid was not sufficient in this patient, intensive treatment is recommended, such as steroid pulse therapy (1,000 mg of methylprednisolone for three days), followed by a daily dosage of 1 mg/kg for one week at least, and slow dose reduction for 6–8 months. Of course, careful assessments for the inflammatory activities, including ICGA, UBM and OCT, should be performed during the treatment, in addition to assessment for general adverse events of systemic corticosteroid.



Indocyanine green angiography in a Japanese patient with VKH disease. Multiple dark spots in the choroid were seen at the intermediate phase (12 min)

References

1. Tomimori S, Uyama M (1977) Shallow anterior chamber and transient myopia as initial signs of Harada's disease. *Jpn J Clin Ophthalmol* 31:1271–1273
 2. Kimura R, Sasaki M, Okabe H (1981) Transient shallow anterior chamber as initial symptom in Harada's syndrome. *Arch Ophthalmol* 99:1604–1605
 3. Kawano Y, Tawara A, Nishioka Y et al (1996) Ultrasound biomicroscopic analysis of transient shallow anterior chamber in Vogt-Koyanagi-Harada syndrome. *Am J Ophthalmol* 121:720–723
 4. Gohdo T, Tsukahara S (1996) Ultrasound biomicroscopy of shallow anterior chamber in Vogt-Koyanagi-Harada syndrome. *Am J Ophthalmol* 122:112–114
 5. Nakamura S, Nakazawa M, Yoshioka M et al (1996) Melanin-laden macrophages in cerebrospinal fluid in Vogt-Koyanagi-Harada syndrome. *Arch Ophthalmol* 114:1184–1188
3. Annabelle A Okada (Japan)

This case highlights the not infrequent phenomenon of transient myopic shift in patients with acute onset panuveitis, particularly seen in VHK disease. The

myopic shift is presumably due to acute ciliary-body inflammation and secondary swelling or even accumulation of subciliary body fluid (supraciliary effusion), resulting in anterior movement of the lens diaphragm. Ultrasound biomicroscopy of the ciliary body is diagnostic of this condition. Ciliary body swelling and/or subciliary body fluid may also occasionally be observed in eyes immediately after pars plana vitrectomy (**ref. a**), presumably due to postoperative inflammation.

This case is also characterized by difficulty in obtaining a diagnosis. The clinical features of VKH disease may often appear atypical if the patient presents late in the course of disease or receives inadequate treatment early on. The typical finding of acute bilateral serous retinal detachments in VKH disease will subside without treatment, however chronic and/or recurrent granulomatous inflammation often ensues in these cases with various complications resulting. The avoidance of ocular complications such as cataract, glaucoma, chorioretinal atrophy, subretinal fibrosis, choroidal neovascularization and retinal detachment is the primary reason for using prompt and aggressive systemic therapy in acute VKH disease. The diagnosis is often aided by lumbar puncture, which may reveal pleocytosis in up to 80% of Japanese patients (**ref. b**) and may persist for as long as eight weeks (**ref. c**). Furthermore, thorough questioning of this particular patient may have revealed ciliary-pattern bulbar conjunctival injection in the early stages coincident with her flu-like symptoms. Despite not being included in the current international VKH disease diagnostic criteria (**ref. d**), transient bilateral ciliary injection in the absence of discharge is a frequent early manifestation and would increase one's clinical suspicion. Of course, it may be helpful to note the patient's ethnicity, since VKH disease occurs much more frequently in individuals with mongoloid heritage such as Asians, American Eskimos, American Indians and certain Hispanic groups.

Since the patient in this case report had characteristic systemic symptoms early in the course of the disease and presented with bilateral granulomatous panuveitis, VKH disease would be high on the list of differential diagnoses. As mentioned above, a lumbar puncture even a few weeks after the onset of symptoms may still have been positive and would have supported aggressive therapy. The ethnicity of

the patient was not stated, however I would consider checking for the HLA-DR4 phenotype, present in up to 93% of VKH disease patients in some areas of the world (**ref. e**). Finally, given a young healthy adult with presumably no contraindications, studies have shown good visual outcomes with aggressive initial systemic corticosteroid therapy (**ref. f**). This patient responded inadequately to oral prednisone at a dose of roughly 1 mg/kg/day with persistent and quite active papillitis in both eyes. Therefore I would consider pulse doses (1,000 mg/day) of methylprednisolone given intravenously for three days followed by continuation of oral corticosteroids tapered over 6–12 months, depending on the clinical response to the pulse therapy. In a young healthy adult, steroid-sparing agents will probably not be necessary as long as posterior pole recurrences are not observed. If the latter occur, steroid-sparing agents should be considered early on, since a longer course of systemic treatment will likely be necessary.

Additional references

- a. Kusaka S, Okada AA, Hayashi A et al (2000) Ciliary body detachment associated with transient myopic shift after pars plana vitrectomy. *Retina* 20:417–418
- b. Inomata H, Kato M (1989) Vogt-Koyanagi-Harada disease. *Handbook Clin Neurol* 12:611–625
- c. Sugiura S (1978) Vogt-Koyanagi-Harada disease. *Jpn J Ophthalmol* 22:9–35
- d. Read RW, Holland GN, Rao NA, Tabbara KF, Ohno S, Arellanes-Garcia L, Pivetti-Pezzi P, Tessler HH, Usui M (2001) Revised diagnostic criteria for VKH disease; report of an international committee on nomenclature. *Am J Ophthalmol* 131:647–652
- e. Islam SMM, Numaga J, Fujino Y et al (1994) HLA class II genes in Vogt-Koyanagi-Harada disease. *Invest Ophthalmol Vis Sci* 35:3890–3896
- f. Sasamoto Y, Ohno S, Matsuda H (1990) Studies on corticosteroid therapy in Vogt-Koyanagi-Harada disease. *Ophthalmologica* 201:162–167

4. Narsing A. Rao (USA)

The present case presents a diagnostic challenge since it reveals few clinical features in favor of

diagnosis of VKH disease and others that are against such a diagnosis. The patient's prodromal symptoms support the diagnosis of VKH disease, but it is unusual for this disease to present with signs of granulomatous anterior uveitis (AGU) at such an early phase. This AGU typically appears during the chronic or chronic recurrent phases of the disease. Moreover the asymmetric optic disc changes and the fluorescein angiographic findings do not favor a diagnosis of VKH disease. Since several of the clinical findings are atypical for VKH, it is essential that the patient undergo additional investigation to rule out other causes of granulomatous panuveitis associated with optic disc changes such, as sarcoidosis, tuberculosis, syphilis or cat scratch disease. In addition to obtaining an in-depth medical history and a systemic review, laboratory investigations such as angiotensin converting enzyme levels, serology for syphilis, PPD, chest X-ray and anti-B henselae antibodies will be required to establish the diagnosis.

Although evaluation of cerebrospinal fluid (CSF) for pleocytosis can be helpful in the diagnosis of VKH disease, in the present case, the CSF may be negative. In about 20% of patients with VKH, lumbar puncture results are found to be negative [1]. Moreover, about 88% of patients with sarcoidosis involving the optic nerve may show lymphocytic pleocytosis and/or elevated protein in the CSF [2]. Thus a lumbar puncture may not unequivocally confirm the diagnosis of VKH disease in the present case. Since (HLA) DRB1 0405 is strongly associated with VKH disease, detection of such class II molecules may aid in the diagnosis of VKH disease [3].

Since none of the above investigations can provide a definitive diagnosis or rule out VKH disease, a noninvasive ultrasound examination of the retina-choroid should be undertaken. This procedure can either support the diagnosis of VKH or refute the possibility. Since the patient exhibits granulomatous panuveitis, if an ultrasound finding of diffuse choroidal thickening, more prominent in the juxtapapillary area with a gradual reduction in thickness toward the equator and anterior choroid would support a diagnosis of VKH disease [4]. Such choroidal thickening is typically seen in both VKH and sympathetic ophthalmia. Since there is no history of penetrating ocular injury in the present case, the above findings, if noted, could support the diagnosis of VKH disease. In contrast, should the choroid

reveal thickening without the above unique features, a diagnosis of sarcoidosis or another granulomatous uveitis entity should be entertained. In addition to ultrasonography, indocyanine green angiography may prove useful in arriving at the diagnosis.

In summary, further investigation is required to arrive at a definitive diagnosis. The ultrasound examination, along with the described investigation, may either support or refute the diagnosis of VKH disease and pave the way for establishing a proper diagnosis.

References

1. Kitamura M, Takami K, Kitachi N et al (2005) Comparative study of two sets of criteria for the diagnosis of Vogt-Koyanagi-Harada's disease. *Am J Ophthalmol* 139:1080–1085
2. Frohman LP, Guirgis M, Turbin RE, Bielory L (2003) Sarcoidosis of the anterior visual pathway: 24 cases. *J Neuroophthalmol* 23:190–197
3. Yamaki K, Hara K, Sakuragi S (2005) Application of revised diagnostic criteria for Vogt-Koyanagi-Harada disease in Japanese patients. *Jpn J Ophthalmol* 49:143–148
4. Foster DJ, Cano MR, Green RL, Rao NA (1990) Echographic features of the Vogt-Koyanagi-Harada Syndrome. *Arch Ophthalmol* 108:1421–1426

Actual management of case

Indocyanine green angiography was performed, showing evenly distributed and evenly sized bilateral hypofluorescent dark dots, indicating the widespread choroidal stromal granulomas typically seen in VKH disease (Fig. 6a, b). With this information it was decided to perform a lumbar puncture that showed 80 lymphocytic cells per mm³, confirming the diagnosis of VKH disease. A therapy consisting of an infusion of 500 mg of methylprednisolone per day during three days was decided followed by peroral prednisone (1.5 mg/kg) and the introduction of azathioprine (2.8 mg/kg) was decided. Three days later ICGA showed clear regression of the hypofluorescent dark dots in the posterior pole (Fig. 7a) when compared to the situation 4 days earlier before the administration

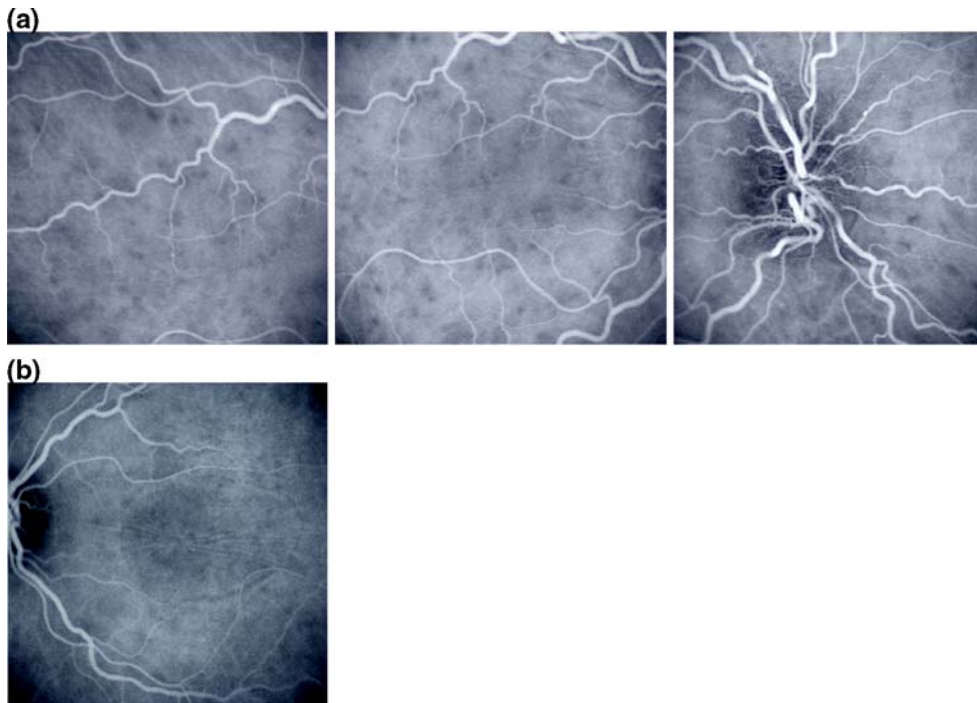


Fig. 6 (a) Indocyanine green angiography (ICGA) OD: numerous evenly sized and evenly distributed hypofluorescent dark dots indicating stromal granulomata in the right eye. (b)

ICGA OS: numerous hypofluorescent dark dots indicating stromal granulomata in the left minimally inflamed eye

of intravenous methylprednisolone (Fig. 7b), giving further credit to the diagnosis of VKH disease. Visual acuity increased to 1.0 (OD) and 0.9 (OS) with a bilateral spherical best correction that decreased to -0.75 diopters. Wide-angle ICGA however showed persistence of hypofluorescent dark dots in the periphery (Fig. 8).

Discussion

This is a case of VKH disease that presented atypically because the inflammatory involvement was anterior at the very onset of disease with only a unilateral posterior involvement not including clinical and angiographic serous retinal detachments. One of the reasons that the case still presented atypically six weeks later when seen in a specialized center was that the administration of systemic corticosteroid therapy, even though given at an insufficient dosage and for too short a course, masked the full expression of the disease. In the case of

atypical clinical presentation and suspicion of VKH disease, clinicians should not hesitate to use all diagnostic modalities at their disposal to compensate for the absent clinical signs. One of the new diagnostic modalities that has substantially refined our capacity to diagnose VKH disease, especially in asymmetric or clinically unilateral cases or with a reduced degree of severity, is indocyanine green angiography (ICGA) [5–9]. ICG angiography here gave the most useful information, typically showing the numerous evenly distributed hypofluorescent dark dots in the choroidal stroma, indicating the presence of choroidal stromal granulomata. These essential ICGA findings in turn strengthened the probability of the diagnosis of VKH disease justifying the more-invasive lumbar puncture that finally unmistakably confirmed the diagnosis. The certainty of the diagnosis justified the administration of very high-dose intravenous corticosteroids and the immediate introduction of an immunosuppressive agent. A further utility of ICGA was to monitor the significant decrease of the hypofluorescent dark dots after

Fig. 7 (a) ICGA OD after three days of intravenous infusion of methylprednisolone: hypofluorescent dark dots are nearly completely erased in the posterior pole. (b) ICGA OD before methyl prednisolone IV therapy: in comparison to Fig. 7a the hypofluorescent dark dots are more numerous and better delineated in the posterior pole

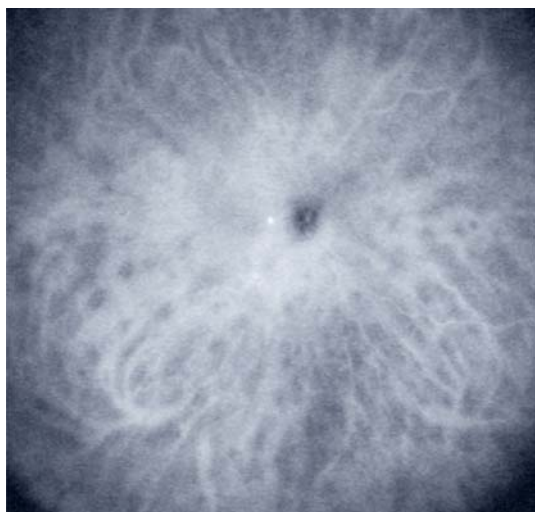
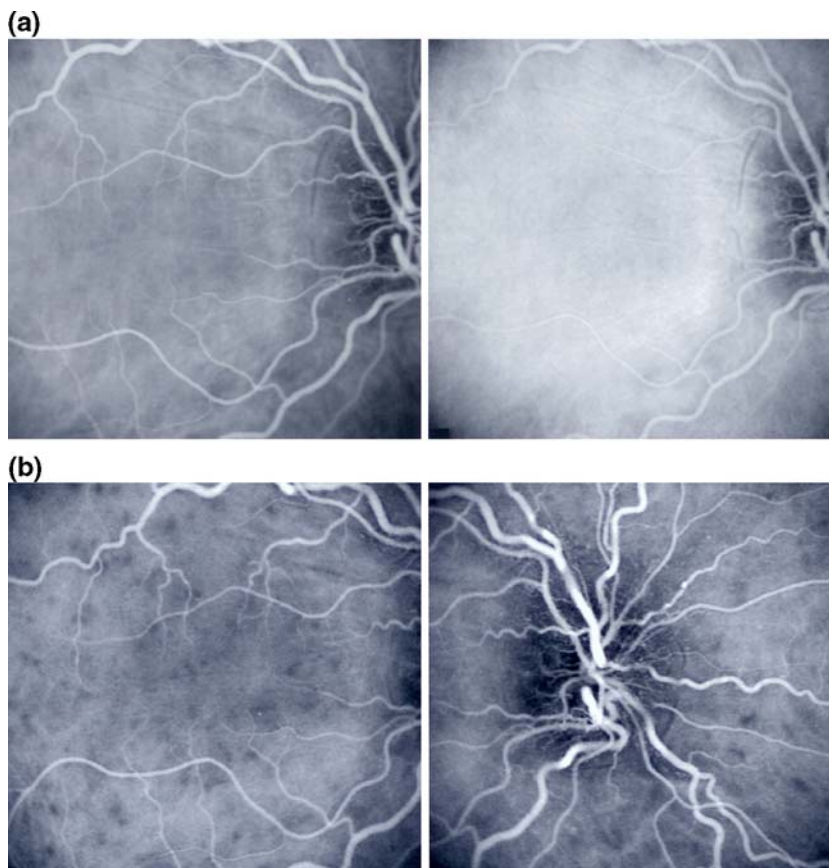


Fig. 8 Wide-angle ICGA OD: this wide-angle ICGA frame clearly shows that the hypofluorescence is still present in the periphery after three days of IV methylprednisolone therapy

three days of megadose intravenous corticosteroids. Interesting but less-specific information was given by OCT, which showed wrinkling of the retinal surface

especially well shown with the instrument manufactured by Ophthalmic Technologies that allows coronal scanning (C-sections) cutting through the posterior pole. The classical longitudinal/sagittal (B-scan-mode) sections showed subretinal liquid that was not evidenced by fluorescein angiography. The use of high-frequency ultrasound (UBM) nicely showed supraciliary effusion explaining the acute onset of myopia [10–12].

Conclusion

Vogt-Koyanagi-Harada (VKH) disease is a primary stromal choroiditis [13]. In contrast to other choroiditides, such as choroiditis caused by sarcoidosis where the choroid is an innocent host and where choroidal lesions are the result of random involvement by a systemic process, in VKH the islets of stromal melanocytes are the primary target of the inflammatory reaction. Therefore the initial inflammatory events such as the formation of stromal

choroidal granulomata take place in the choroidal stroma and the inflammatory reaction of adjacent structures such as the retina or optic disc only occur secondarily to the primary choroidal stromal events. Until the introduction of indocyanine green angiography (ICGA) the choroidal compartment could not be explored in a sensitive manner and only secondary inflammatory signs involving neighboring structures were recorded in VKH disease. It has been shown that ICGA is a sensitive method to detect the primary stromal inflammatory events that often preceding clinically detectable signs and it is obvious that ICGA represents the method of choice to detect these early events and is of great help to the clinician [5, 6]. Similarly in dubious cases when the suspected diagnosis is sufficiently probable, lumbar puncture should be performed in order to confirm the diagnosis. Together these diagnostic modalities allow the clinician to make the diagnosis of VKH even when all criteria are not present and they certainly represent a significant improvement in diagnostic and follow-up precision.

References

1. Moorthy RS, Inomata H, Rao NA (1995) Vogt-Koyanagi-Harada syndrome. *Surv Ophthalmol* 39:265–292
2. Snyder DA, Tessler HH (1980) Vogt-Koyanagi-Harada syndrome. *Am J Ophthalmol* 90:69–75
3. Read RW, Holland GN, Rao NA, Tabbara KF, Ohno S, Arellanes-Garcia L, Pivetti-Pezzi P, Tessler HH, Usui M (2001) Revised diagnostic criteria for VKH disease: report of an international committee on nomenclature. *Am J Ophthalmol* 131:647–652
4. Bouchenaki N, Morisod L, Herbert CP (2000) Syndrome de Vogt-Koyanagi-Harada: importance de la rapidité du diagnostic et du traitement. *Klin Monatsbl Augenheilkd* 216:290–294
5. Bouchenaki N, Herbert CP (2001) The contribution of indocyanine green angiography to the appraisal and management of Vogt-Koyanagi-Harada disease. *Ophthalmology* 108:54–64
6. Bouchenaki N, Herbert CP (2000) Indocyanine green angiography (ICGA) in the assessment and follow-up of choroidal inflammation in active chronically evolving Vogt-Koyanagi-Harada disease. In: Dodds EM, Couto CA (eds) *Uveitis in the third millennium*. Elsevier Scienc B.V., pp 35–38
7. Herbert CP (1998) Posterior uveitis: new insights provided by indocyanine green angiography. *Eye* 12:757–759
8. Herbert CP, Bodaghi B, LeHoang P (2001) Angiographie au vert d'indocyanine au cours des maladies oculaires inflammatoires: principes, interprétation schématique, sémiologie et intérêt clinique. *J Fr Ophthalmol* 24:423–447
9. Herbert CP, LeHoang P, Guex-Crosier Y (1998) Schematic interpretation of indocyanine green angiography in posterior uveitis using a standard protocol. *Ophthalmology* 105(3):432–440
10. Tran VT, LeHoang P, Herbert CP (2001) Value of high-frequency ultrasound biomicroscopy in uveitis. *Eye* 15:23–30
11. Tran VT, LeHoang P, Mermoud A, Herbert CP (2000) Hypotonie intraoculaire: revue des mécanismes et utilité de l'UBM (ultrasound biomicroscopique) dans le diagnostic différentiel et la prise en charge systématique. *Klin Monatsbl Augenheilkd* 216:261–264
12. Gentile RC, Berinstein DM, Liebmann J, Rosen R, Stegmann Z, Tello C, Walsh JB, Ritch R (1998) High-resolution ultrasound biomicroscopy of the pars plana and peripheral retina. *Ophthalmology* 105(3):478–484
13. Bouchenaki N, Herbert CP (2004) Stromal choroiditis. In: Pleyer U, Mondino B (eds) *Essentials in ophthalmology: uveitis and immunological disorders*. Springer, Berlin, pp 234–253