

Surgical resection of pediatric skull base meningiomas

Jan-Karl Burkhardt · Marian C. Neidert ·
Michael A. Grotzer · Niklaus Krayenbühl ·
Oliver Bozinov

Received: 12 July 2012 / Accepted: 25 August 2012 / Published online: 13 September 2012
© Springer-Verlag 2012

Abstract

Purpose Meningiomas in children are rare, especially those located at the skull base. In this study, we report our experience of meningioma surgery in the pediatric population and compare our findings of skull base (SB) versus non-skull base (NSB) meningiomas.

Methods From our database of 724 surgically treated meningioma patients at the University Hospital, Zurich between 1995 and 2010, 12 patients under 18 years of age were identified. Data for those patients was retrospectively collected through chart review. A descriptive comparison between SB and NSB meningiomas was undertaken to determine statistical significance.

Results In all 12 children (seven males, five females; mean age 12.2 ± 4.3 years), surgical removal of the meningioma was performed microsurgically with a mean follow-up of 53 months (range 12–137 months). Of the 12 tumors, six were located in the SB and six in the NSB. Comparing SB to NSB lesions, the mean age was 11 ± 3.8 versus 14 ± 4.6 years, male/female gender distribution was 5:1 compared to 1:5, mean tumor size was 7.5 ± 6.2 versus 26 ± 15.8 cm² ($p = 0.03$), and mean surgery time was 347 versus 214 min. While WHO grade was similar for both groups, the Simpson grade revealed more extensive resection for NSB meningiomas. The Glasgow Outcome Scale at last follow-up was favorable for both groups.

Conclusions Meningioma surgery was safe with favorable outcomes. SB meningiomas were significantly smaller in

size, were less likely to undergo complete resection, and had a predilection for younger, male patients.

Keywords Pediatric meningiomas · Skull base meningioma · Neurosurgery · Resection

Introduction

Meningiomas in the pediatric population are rare and represent 0.5–5 % of all primary central nervous system tumors in children and adolescents (compared to approximately 30 % in the adult population) [5]. An epidemiological study from the Netherlands showed that the overall meningioma incidence in children and adolescents is approximately 1:1,700,000/year [15]. Due to the rarity of these lesions, large prospective studies are not available. By contrast, there are a relatively large number of single-center retrospective studies, compromising 5–50 patients, in the literature [4, 7, 8, 11–13]. A recently published meta-analysis compared, for the first time, the characteristics of nearly 700 pediatric meningiomas from 35 studies [6]. With regard to the location of these tumors, the incidence of non-skull base (NSB) meningiomas was higher than that of skull base (SB) meningiomas. Approximately 73 % were NSB meningiomas (convexity, parasagittal, tentorial, intraventricular, or intraparenchymal region) compared to approximately 27 % with a SB location (anterior or middle cranial fossa including sphenoid, clinoid, parasellar, olfactory groove meningiomas or petroclival and foramen magnum meningiomas) [6]. Similar to the adult population, most meningiomas were benign (WHO grade I) with 18.8 % constituting meningiomas of higher grade (WHO II and III) [7]. Although SB meningiomas in the adult population are more difficult to treat than NSB meningiomas, specific differences between NSB and SB meningiomas in the pediatric population have not previously been analyzed [12, 14]. Accordingly, our aim was to

J.-K. Burkhardt (✉) · M. C. Neidert · N. Krayenbühl · O. Bozinov
Department of Neurosurgery, University Hospital of Zurich,
Frauenklinikstrasse 10,
Zurich 8091, Switzerland
e-mail: JanKarl.Burkhardt@gmail.com

M. A. Grotzer
Department of Oncology, Children's Hospital,
Zurich, Switzerland

determine the differences between NSB and SB meningiomas in pediatric patients surgically treated at our center.

Methods

From our database of 724 meningioma patients treated at the University Hospital, Zurich between 1995 and 2010, we identified patients under 18 years of age at the time of surgery for analysis. All patients were operated upon at the Department of Neurosurgery, University Hospital, Zurich and were pre- and postoperatively followed-up at the Department of Oncology, Children's Hospital Zurich. Medical reports, surgical protocols, and histopathological reports were reviewed for all patients included in the study. Preoperative MRI scans were reported by a senior board-certified neuroradiologist, and the greatest cross-sectional area of the enhancing tumor on T1 sequence was chosen for size analysis.

A descriptive comparison between SB and NSB meningiomas was undertaken, and the Mann–Whitney *U* test was used to determine the statistical significance. *p* values less than 0.05 were considered statistically significant. Statistical analyses were performed using SPSS (PASW) version 20.0 (SPSS Inc., Chicago, IL, USA) and Microsoft Excel version 14.2.

Results

Twelve patients under 18 years of age (seven males and five females) were identified from our database (Table 1). The mean age was 12.2 years (SD 4.3, range 4–17 years), and the mean follow-up time was 53 months (SD 40, range 12–137 months). Half of the lesions were located in the SB ($n=6$), and the other half were NSB meningiomas ($n=6$). SB meningiomas were found at the tuberculum sellae ($n=4$), in the olfactory groove ($n=1$), and at the sphenoid wing ($n=1$). The NSB meningiomas were located in the parasagittal region ($n=4$) and in the convexity ($n=2$).

The differences between SB and NSB meningiomas are summarized in Table 2. Although not statistically significant, the gender distribution tended toward males in the SB (M/F 5:1) compared to NSB (M/F 1:5). The mean age was lower for patients with SB lesions (11 years (SD 3.4)) compared to those with NSB lesions (14 years (SD 4.6)). In nearly all cases ($n=11$), patients presented clinically with headaches or other signs of increased intracranial pressure such as emesis. While every SB meningioma patient ($n=6$) displayed cranial nerve impairment, only two patients from the NSB group presented with this clinical feature. Paresis or seizures occurred in four patients with NSB meningiomas, while no patient from the SB group presented such

manifestations. Preoperative embolization was performed in three cases (two NSB and one SB). Two patients had an underlying diagnosis of neurofibromatosis type 2 (both SB meningiomas). None of the meningiomas were radiation-induced.

Preoperative tumor size was significantly smaller in SB compared to NSB meningiomas, with a mean size of 7.5 cm² (SD 6.2) versus 26 cm² (SD 15.8), respectively ($p=0.03$; Fig. 1a). Mean surgery time was longer in the SB group: 347 min (SD 217) versus 214 min (SD 49) of the NSB group ($p=0.06$; Fig. 1b). With regard to the Simpson grade (SG) of surgical resection, none of the SB patients had a SG I, four had a SG II, one had a SG III, and one had a SG IV. As for the NSB group, three patients had a SG I, two had a SG II, one had a SG III, and no patient had a SG IV resection. One NSB meningioma was debulked during the first surgery and subsequently reoperated on after histological examination revealed a grade II meningioma.

Histopathological features were comparable in terms of WHO grade for both groups: grade I, three SB and three NSB; grade II, three SB and two NSB; and grade III, one NSB (Table 2). Three children received postoperative radiation (gamma knife, $n=1$; proton radiation, $n=2$). The outcome was favorable in all patients with no mortality and a Glasgow Outcome Scale of 4 ($n=3$) or 5 ($n=9$) after the most recent follow-up. Tumor recurrence was seen in two cases (both parasagittal), and repeat surgeries were performed. No patient developed postoperative hydrocephalus.

Discussion

In this single-center study, we compared, for the first time, surgically resected pediatric meningiomas of the SB versus NSB region. The literature suggests that the incidence of pediatric meningiomas of the SB is lower than that of the NSB, and that SB meningiomas are more difficult to treat clinically [3, 12, 16]. In our study, however, the distribution was equal, with six meningiomas located in the SB and six in the NSB region. This discrepancy might be due to the small sample size of this study as we analyzed only surgically treated patients based on a retrospective single-center analysis.

Our descriptive review, which compared age and gender distribution, showed a younger, male dominance in the SB group versus an older, female dominance in the NSB group. The reasons for these age and gender distributions remain unclear. A possible explanation may be the influence of puberty on meningioma type [5, 6]. Postpubertal meningiomas are thought to be similar to the adult form, and a higher proportion occurs in female patients [6]. Meningiomas in patients under the age of 12 tend to occur more commonly in males, which was confirmed in our study. No patient

Table 1 Summary of pediatric meningioma patients surgically treated in this study

Number	Sex	Age	Clinical features at first presentation	Location	Infiltrating tissue	Preoperative embolization	Neurofibromatosis type 2	Simpson grade	WHO grade/histology	Postoperative complications	Adjuvant radiation therapy (dose)/time between first surgery and radiation (months)	Recurrence / repeat surgery (Simpson grade)	Total follow-up time (months)/time of recurrence and second surgery	GOS/symptoms at last follow-up
1	M	11	Headache, emesis	Olfactory groove	Bone	Yes	No	3	II/atypical	–	No	No/no	16/–/–	5/headache
2	M	13	Headache, facial paresis	Left sphenoid wing	Bone	No	Yes	2	I/fibroblastic	–	No	No/no	60/–/–	5/headache
3	M	14	Headache, double vision	Tuberculum sellae	Optic nerve compression	No	No	2	II/atypical	Postoperative wound dehiscence	Gamma knife (30.3 Gy)/2	No/no	79/–/–	4/headache, double vision
4	M	8	Headache, double vision	Tuberculum sellae	Optic nerve compression	No	No	2	I/meningothelial	–	No	No/no	137/–/–	4/headache, double vision
5	F	13	Headache	Tuberculum sellae	–	No	Yes	2	I/meningothelial	–	No	No/no	12/–/–	5/headache
6	M	4	Double vision	Tuberculum sellae	Optic nerve compression	No	No	4	II/atypical	Tumor remnant	Proton radiation (61.2 Gy)/3	No/yes (4)	12/–/–	5/headache
7	F	13	Headache, left hemiparesis	Right parietal parasagittal	Superior sagittal sinus	No	No	3	II/atypical	–	No	Yes/yes (3)	93/81/1	5/–
8	M	14	Headache, seizures, hemiparesis	Left parietal parasagittal	Superior sagittal sinus	No	No	2	I/fibroblastic	–	No	Yes/yes (2)	80/46/2	5/–
9	M	16	Headache, aphasia, dizziness	Left parietal parasagittal	–	Yes	No	1	II/atypical	–	No	No/no	30/–	5/headache
10	F	17	Headache	Right frontal convexity	–	No	No	1	I/meningothelial	–	No	No/no	34/–	5/–
11	F	17	Headache, double vision, dizziness	Left frontal convexity	–	Yes	No	2	I/meningothelial	Epileptic seizures	No	No/no	66/–	4/epileptic seizures, double vision
12	F	5	Headache, dizziness	Left frontal convexity	–	No	No	1	III/anaplastic	–	Proton radiation (59.4 Gy)/2	No/no	13/–	5/–

M male, F female, WHO World Health Organization, GOS Glasgow Outcome Scale, Gy Gray

Table 2 Comparison of non-skull base versus skull base meningiomas

	Non-skull base (<i>n</i> =6)	Skull base (<i>n</i> =6)
Gender (m/f)	1:5	5:1
Mean age (range, years)	14 (5–17)	11 (4–13) (<i>p</i> =0.09)
Clinical presentation		
Headache, emesis	6	5
Seizures	1	0
Paresis	3	0
Cranial nerve symptoms	2	6
Mean tumor size (range, cm ²)	26 (6–42)	7.5 (2.3–16) (<i>p</i> =0.03) ^a
Preoperative embolization	2	1
Mean duration of surgery (range, minutes)	214 (170–300)	347 (200–780) (<i>p</i> =0.06)
Simpson grade		
I	3	0
II	2	4
III	1	1
IV	0	1
WHO grade		
I	3	3
II	2	3
III	1	0
GOS (last follow-up)		
5	5	4
4	1	2
3–1	0	0

m male, *f* female, *WHO* World Health Organisation, *GOS* Glasgow Outcome Scale

^a Statistical significance

under the age of three was identified in this study. Meningiomas in this age group usually have a worse prognosis when compared to older children due to higher operative mortality and morbidity [6].

The majority of patients showed signs of increased intracranial pressure at the time of initial presentation and presented with additional clinical symptoms based on the location of their meningiomas (Table 1). The SB meningiomas were smaller on T1-weighted MRI than NSB meningiomas (*p*=0.03), that significant clinical symptoms are elicited by smaller tumors in the SB compared to NSB meningiomas (Fig. 1). This difference could be explained by the anatomical proximity of the surrounding cranial nerves in the SB region.

The SG of the surgical resection and the duration of surgery were more favorable in the NSB group than in the SB group, which is similar to results in the adult population [1, 2]. Poor accessibility, more complex approach, and dural attachments that cannot be sacrificed, which are all characteristic of SB meningiomas, are factors which contribute to this difference.

Histopathological analysis showed a high ratio (50 %) of higher grade meningiomas in both groups, including five grade II meningiomas and one grade III. This result is not concordant with the literature, since only a small number of higher grade meningiomas occur in children compared to the adult population [9]. A closer look at the surgical date of our patients revealed that three patients were treated before the year 2000 (two with grade II meningiomas), and five patients were treated between the years 2000 and 2007 (two with grade II meningiomas).

Before the year 2007, different versions of the WHO grading system were used to classify meningiomas [10]. We suggest that the revisions of the WHO grading system may have resulted in the upgrading of meningiomas that would have previously considered benign prior to the year 2000 and as the majority of the patients in this study were diagnosed after these revisions were implicated [10]. This may subsequently reflect the higher incidence of WHO grade II meningiomas. However, due to the retrospective analysis of the data, we were unable to confirm this hypothesis since reanalyzing the histological tissue was simply not feasible.

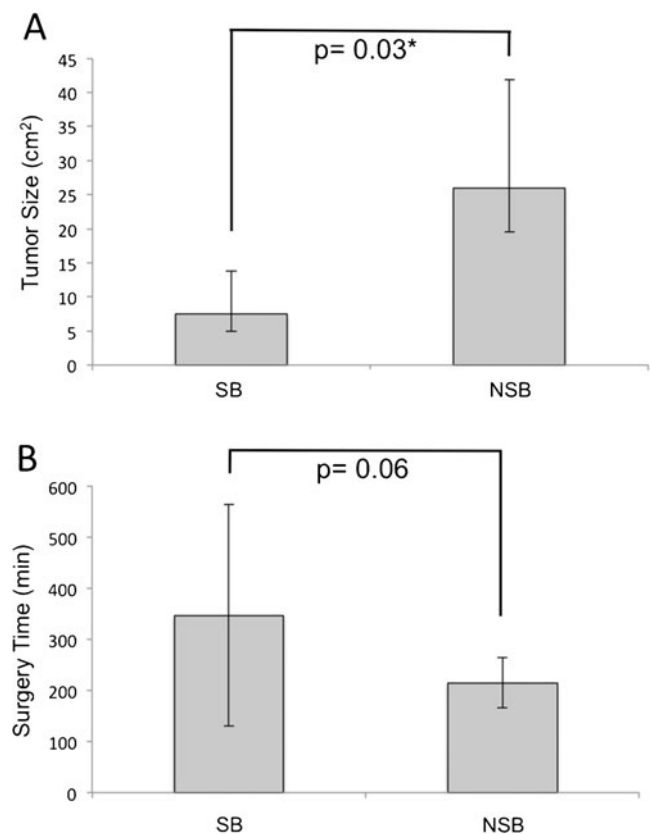


Fig. 1 **a** Bars with standard deviation to compare the mean size of SB (*n*=6) versus NSB (*n*=6) meningiomas. *Indicates statistical significance. **b** Bars with standard deviations to compare the mean duration of surgery for SB versus NSB meningiomas

Our recurrence and complication rates were low with two recurrences and one postoperative infection. In contrast to the adult population, SB meningiomas did not carry an increased risk of hydrocephalus [1].

Summary

Meningioma surgery was safe for this pediatric population with favorable clinical outcomes. Compared to NSB meningiomas, SB meningiomas were significantly smaller in size, were less likely to undergo complete resection, and had a predilection for younger, male patients.

References

- Burkhardt JK, Zinn PO, Graenicher M, Santillan A, Bozinov O, Kasper EM, Krayenbuhl N (2011) Predicting postoperative hydrocephalus in 227 patients with skull base meningioma. *Neurosurg Focus* 30:E9
- Chen CM, Huang AP, Kuo LT, Tu YK (2011) Contemporary surgical outcome for skull base meningiomas. *Neurosurg Rev* 34:281–296, discussion 296
- Erdinçler P, Lena G, Sarioglu AC, Kunday C, Choux M (1998) Intracranial meningiomas in children: review of 29 cases. *Surg Neurol* 49:136–140, discussion 131–140
- Gao X, Zhang R, Mao Y, Wang Y (2009) Childhood and juvenile meningiomas. *Childs Nerv Syst* 25:1571–1580
- Kotecha RS, Junckerstorff RC, Lee S, Cole CH, Gottardo NG (2011) Pediatric meningioma: current approaches and future direction. *J Neurooncol* 104:1–10
- Kotecha RS, Pascoe EM, Rushing EJ, Rorke-Adams LB, Zwerdling T, Gao X, Li X, Greene S, Amirjamshidi A, Kim SK, Lima MA, Hung PC, Lakhdar F, Mehta N, Liu Y, Devi BI, Sudhir BJ, Lund-Johansen M, Gjerris F, Cole CH, Gottardo NG (2011) Meningiomas in children and adolescents: a meta-analysis of individual patient data. *Lancet Oncol* 12:1229–1239
- Lakhdar F, Arkha Y, El Ouahabi A, Melhaoui A, Rifi L, Derraz S, El Khamlichi A (2010) Intracranial meningioma in children: different from adult forms? A series of 21 cases. *Neurochirurgie* 56:309–314
- Li X, Zhao J (2009) Intracranial meningiomas of childhood and adolescence: report of 34 cases with follow-up. *Childs Nerv Syst* 25:1411–1417
- Marosi C, Hassler M, Roessler K, Reni M, Sant M, Mazza E, Vecht C (2008) Meningioma. *Crit Rev Oncol Hematol* 67:153–171
- Mawrin C, Perry A (2010) Pathological classification and molecular genetics of meningiomas. *J Neurooncol* 99:379–391
- Mehta N, Bhagwati S, Parulekar G (2009) Meningiomas in children: a study of 18 cases. *J Pediatr Neurosci* 4:61–65
- Menon G, Nair S, Sudhir J, Rao BR, Mathew A, Bahuleyan B (2009) Childhood and adolescent meningiomas: a report of 38 cases and review of literature. *Acta Neurochir* 151:239–244, discussion 244
- Santos MV, Furlanetti L, Valera ET, Brassescio MS, Tone LG, de Oliveira RS (2012) Pediatric meningiomas: a single-center experience with 15 consecutive cases and review of the literature. *Childs Nerv Syst*. doi:10.1007/s00381-012-1823-8
- Shah MV, Haines SJ (1992) Pediatric skull, skull base, and meningeal tumors. *Neurosurg Clin N Am* 3:893–924
- Thuijs NB, Uitdehaag BM, Van Ouwerkerk WJ, van der Valk P, Vandertop WP, Peerdeman SM (2012) Pediatric meningiomas in The Netherlands 1974–2010: a descriptive epidemiological case study. *Childs Nerv Syst* 28:1009–1015
- Tufan K, Dogulu F, Kurt G, Emmez H, Ceviker N, Baykaner MK (2005) Intracranial meningiomas of childhood and adolescence. *Pediatr Neurosurg* 41:1–7