

D. Ceroni
M. Mousny
A. Lironi
A. Kaelin

Pediatric seatbelt injuries: unusual Chance's fracture associated with intra-abdominal lesions in a child

Received: 20 July 2002
Revised: 14 March 2003
Accepted: 21 March 2003
Published online: 10 July 2003
© Springer-Verlag 2003

D. Ceroni (✉) · M. Mousny · A. Kaelin
Paediatric Orthopaedic Unit,
Children's Hospital,
University Hospital Geneva,
Rue Willy Donzé 6,
1205 Geneva, Switzerland
Tel.: +41-22-3723311,
Fax: +41-22-3824783,
e-mail: dimitri.ceroni@hcuge.ch

A. Lironi
Paediatric Surgery Unit, Children's Hospital,
University Hospital Geneva, Switzerland

Abstract The authors report the case of a 7-year-old child involved in a motor vehicle accident. She sustained an unusual flexion-distraction vertebral injury. This spinal injury was related to seatbelt use and was associated with intra-abdominal lesions. The spinal lesion consisted of a posterior ligamentous disruption with widening of the posterior intervertebral space at two adjacent lumbar levels. The purpose of this case report is to describe an atypical and perhaps often unrecognized spinal lesion and to explain our approach to diagnosis and treatment.

Keywords Chance fracture · Flexion-distraction · Abdominal lesions · Seatbelt

Introduction

Fractures of the thoracolumbar spine are usually considered to be the result of compression, shear, or torsion stresses, acting either singly or in combination [14, 15, 28]. An additional mechanism of injury might occur due to flexion-distraction stress. In 1948, G Q Chance was the first to describe a vertebral fracture consecutive to a flexion trauma extending through the posterior spinous process, the pedicles, and spreading anteriorly through the vertebral body [5]. Subsequently, other fracture patterns similar to those described by Chance became known as "Chance fractures". Until a few years ago, this lesion was thought to be extremely rare in children [22, 23, 25]. However, this injury has become more common in children with the increased use of seatbelts by the pediatric population in motor vehicles. The use of seatbelts significantly reduces the risk of injury or death in a car crash by preventing ejection from the car, but seatbelts also change the distribution of forces, and may be the cause of other injuries [35]. The present

article describes a previously unreported lumbar spine lesion, which might be considered as a variant of Chance injury.

Case report

A 7-year-old girl involved in a motor vehicle accident was admitted to the emergency department. The child was a rear-seat passenger in a car that collided with an embankment head on at high speed. At the time of the accident, she was wearing a seatbelt with a shoulder restraint. On admission, the patient complained of severe abdominal and back pain without history of loss of consciousness. Abdominal examination revealed a diffuse tenderness and guarding with a transverse abrasion over the lower abdomen. On spinal examination, there was a palpable deformity and swelling in the upper lumbar region. No neurologic deficit was present. Initial radiographs (Fig. 1) showed a discrete widening of the interspinous space between the first and the second lumbar vertebrae without visible fracture. On abdominal ultrasonography, the presence of free fluid in the peritoneal cavity was suspect for a visceral injury. Abdominal computed tomography (CT) confirmed the presence of fluid collection in the abdominal cavity, but free air was not noted. No lesion could be detected at the level of the spleen,

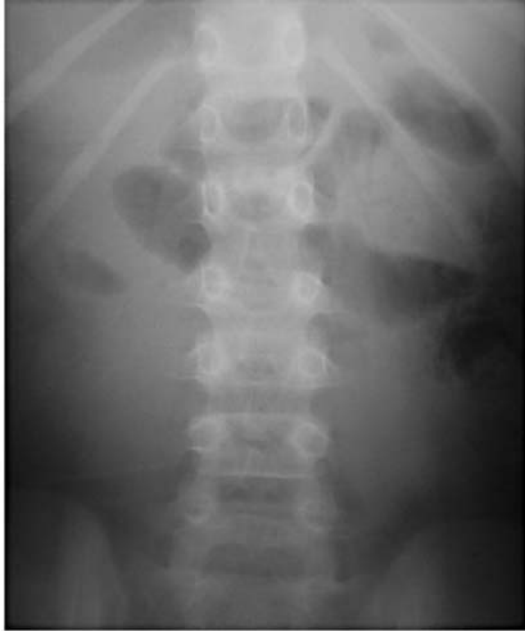

Fig. 1 Widening of the interspinous space between the first and the second and between the second and the third lumbar vertebrae was noted on the thoracolumbar spine radiographs. No fracture was suspected on these films

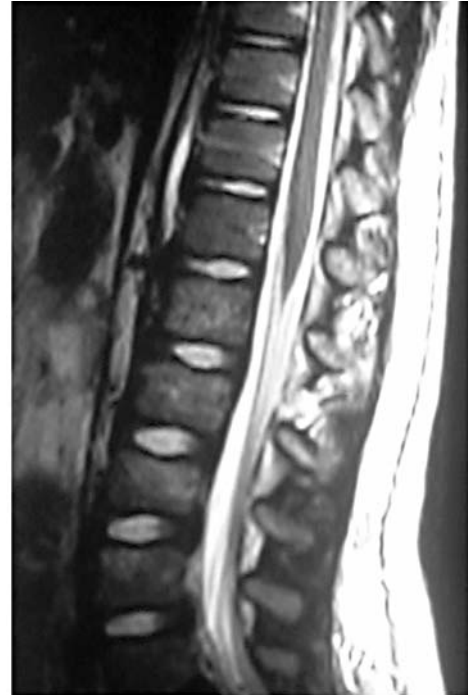

Fig. 2 Magnetic resonance imaging (MRI): on T2-weighted fat-saturated sequences, there is a hyperintensity signal alteration of the posterior ligamentous elements, evocative of a lesion of these structures

the liver, the kidneys or the pancreas. Despite a hematoma in the retroperitoneal space, the spinal CT scan was interpreted as normal. Emergency laparotomy revealed a mesenteric tear with a lesion of a superior mesenteric artery branch leading to an important mesenteric hematoma. A jejunal segmental infarction and a more distal small bowel perforation were discovered. Moreover, there were two small seromuscular tears, one in the descending colon and one at the level of the ilio-caecal valvula. Two segmental resections of small bowel were performed with immediate restoration of the continuity. A magnetic resonance (MR) image (Fig. 2) of the spine showed posterior ligamentous disruption at two levels (L1-L2 and L2-L3). The intervertebral discs appeared fully normal at both levels. Increased height of the intervertebral foramina and widening of the posterior part of the intervertebral space on flexion dynamic X-rays (Fig. 3) confirmed instability at these levels. Ten days after the initial trauma, surgical exploration revealed L1-L2 and L2-L3 instability due to rupture of the supraspinous ligaments, ligamentum flavum and capsules of the posterior joints (Fig. 4). A fracture of the L1 transverse apophysis was discovered during the operative exposure. Reduction was obtained by getting the child lumbar spine into slight lordosis on the operating table, and fixation was performed with two thread loops, one between the spinous processes of L1 and L2, the second between those of L2 and L3 (Fig. 5). The child was then immobilized in a body jacket orthosis for 3 months. Seven months after the trauma, the child was asymptomatic, and conventional dynamic radiographs were interpreted as normal (Fig. 6).

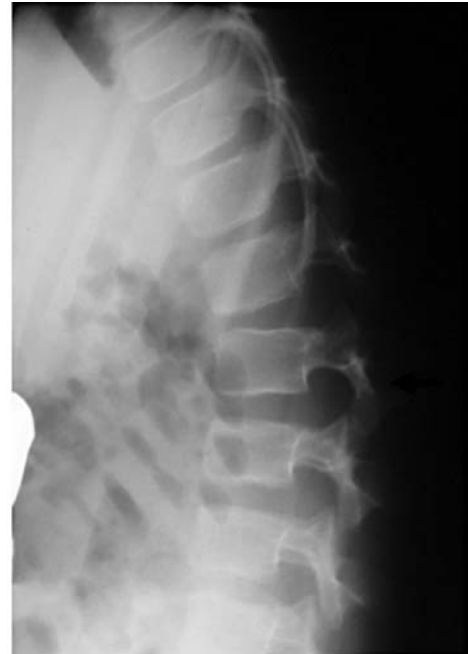

Fig. 3 Dynamic X-rays performed in flexion confirmed instability at two levels (L1-L2 and L2-L3) by the increased height of the intervertebral foramina and by a widening of the posterior part of the intervertebral space

Discussion

In 1948, Chance first described vertebral fractures that extended horizontally through the posterior spinous process and the neural arch, and ended in the vertebral body [5].

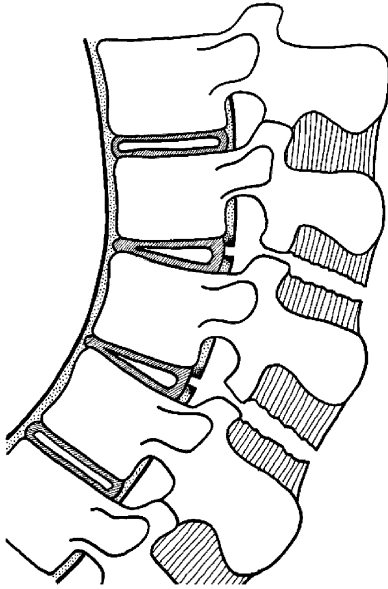


Fig. 4 Surgical exploration revealed L1-L2 instability due to rupture of the lumbodorsal fascia, supraspinous ligaments, ligamentum flavum and capsules of the posterior joints

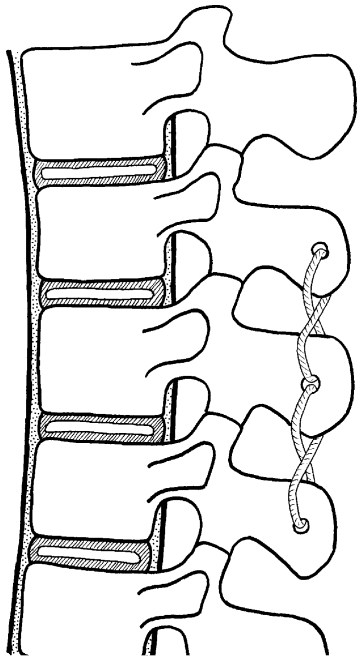


Fig. 5 Fixation of the lesion was obtained with two thread loops, one between the spinous processes of L1 and L2, the second between those of L2 and L3

The mechanism of the injury was thought to be pure flexion. In 1965, Howland et al. associated this particular fracture with lap belt use during a motor vehicle accident [16]. Later, Smith and Kaufer hypothesized that Chance fractures associated with seatbelt injuries were due to distract-

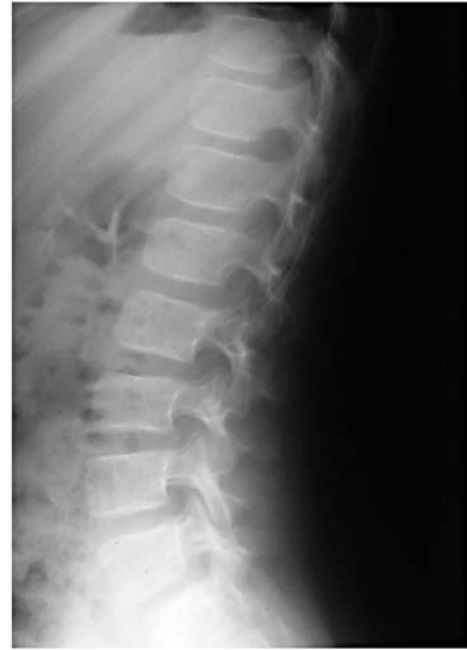

Fig. 6 Final thoracolumbar spine radiograph reveals no residual deformity in standing position

tion forces rather than pure flexion stress [31]. These authors noted that usually there was not an anterior vertebral compression but rather a failure of the posterior elements in tension, given that the fulcrum of rotation was commonly anterior to the vertebral body. The concept of a flexion-distraction mechanism of injury was put forward by Rennie and Mitchell, who considered that compression forces were acting on the anterior portion of the vertebral body, while distraction forces were simultaneously acting on the posterior structures [27]. As seatbelt injuries of the thoracolumbar spine were essentially reported in adults [6, 10, 13, 23, 31, 31], it was thought that this lesion was rare in the pediatric population [22, 23, 25]. An increase in the reported frequency of this injury in children has been reported [1, 2, 4, 8, 11, 17, 19, 20, 22, 23, 26, 30, 32, 34], and is probably related to the legislation that mandates the use of a seatbelt by children in automobiles. As children have a higher center of gravity due to an increased head-to-body ratio [1, 24], the lever arm movement around the axis is increased, which explains why children are susceptible to Chance fracture [1]. Gumley has described the mechanism of action occurring with this injury when the patient slides beneath an improperly placed lap belt [13], resulting in an axis of rotation approximately at the level of the umbilicus [1]. In young children, an ideal placement of the lap belt at the level of the hip is difficult to achieve, because of the poorly developed iliac crest and the problem of maintaining an upright posture [30]. This is a particular problem, as children are frequently rear-seat passengers where shoulder restraints are usually absent

[11]. In the case described, the sudden deceleration caused a hyperflexion of the spine around the lap belt. The pattern of the lesion is consistent with a mechanism of flexion of the spine about an axis anterior to the vertebral body, resulting in a pure distraction separating the posterior elements. However, the failure of the posterior ligamentous structures at two intervertebral levels makes it unique (Fig. 4).

Chance fracture may be difficult to diagnose on the initial radiographs, and CT scans may fail to detect the injury [32]. In the reported case, MRI and especially dynamic X-rays were the most useful additional investigations. Many types of Chance fracture patterns have been described. Some classification systems for Chance fractures have been proposed, and all of them are based on the type of the lesion (only osseous, only ligamentous, or a combination of the both) and on the fracture direction [7, 13, 30]. In the case described, lesions through the posterior elements occurred at two different levels. This particular case of Chance fracture can therefore not be related to the described classifications.

In adults, neurological damage is uncommon, and complete paraplegia has seldom been reported [6, 10, 13, 30, 31]. Rumball and Jarvis have assessed the incidence of paraplegia in children with seatbelt injuries to be 15% [30]. Posterior protrusion of the nucleus pulposus or expulsion of the vertebral apophysis may cause progressive neurologic deficits or spinal canal compromise [31]. As the center of gravity is higher in children than in adults [24], this may result in an increased moment arm, and probably greater distraction, contributing to the higher incidence of paraplegia in children. Additionally, child ligaments and bones can tolerate four times more stretch than the spinal cord [3, 12]. This may lead to normal radiographs in a patient with abnormal neurological findings, known as "spinal cord injury without radiographic abnormality" (SCIWORA) [17, 21]. In our case report, the child showed no neurologic damage.

Treatment of a Chance fracture doesn't only depend on the severity of the injury, but also on the fracture pattern. If the injury is only osseous in all columns, closed reduction and immobilization in an extension brace are appropriate [29]. If the injury is ligamentous, operative reduc-

tion with fusion is indicated, because ligamentous damage does not heal without instability. However, children are noted to have a better prognosis than adults [9]. Results of Chance fracture bracing in children, including those with ligamentous injury, are better than what would be expected in adults [11, 33]. Glassmann et al. [20] reported that brace treatment failed only in patients with an initial kyphosis of more than 20°. So they advocated immobilization if kyphosis was less than 20°. In their series, all children with successful brace treatment had a decrease in kyphosis over time because of the remaining potential for anterior growth. Nevertheless, kyphosis greater than 20° requires surgical stabilization even in children, especially when important ligamentous injuries are present [11], to prevent progression of the kyphosis, instability and chronic pain [18]. In young children, simple interspinous wiring is recommended in order not to disturb the potential of ulterior growth and may be supplemented by postoperative brace immobilization. In adolescents, standard compression devices can be used to counteract the tensile forces acting on the posterior elements [29]. In our case, we opted for a surgical stabilization, given the extended ligamentous injuries. Fixation was performed with two absorbable thread loops, one between the spinous processes of L1 and L2, and the second between those of L2 and L3 (Fig. 5). This treatment was supplemented by postoperative brace immobilization for 3 months.

Conclusion

Chance fractures in a child are potentially devastating injuries and are largely caused by motor vehicle accidents. They occur when the spine is flexed about an axis anterior to the spine. Associated abdominal injuries are common, but their diagnosis is often delayed. We think that the lesion described in this case report is a variant of Chance fracture. This unusual lesion is characterized by a separation of the posterior elements at two levels. MRI and, above all, dynamic conventional radiography are diagnostic. Instability represents a surgical indication, especially when ligamentous damage is extensive.

References

1. Agran PF, Dunkle DE, Winn DG (1987) Injuries to a sample of seat belted children evaluated in a hospital emergency room. *J Trauma* 27:58–64
2. Anderson PA, Rivara FP, Maier RV, Drake C (1991) The epidemiology of seatbelt-associated injuries. *J Trauma* 31:60–67
3. Aufdermaur HR (1974) Spinal injuries in juveniles. Necropsy findings in twelve cases. *J Bone Joint Surg Br* 56: 513–519
4. Blasier RD, Lamont RL (1985) Chance fracture in a child: a case report with non-operative treatment. *J Pediatr Orthop* 5:92–93
5. Chance GQ (1948) Note on a type of flexion fracture of the spine. *Br J Radiol* 21:452–453
6. Dennis R, Allard M, Atlas H, Farkouh E (1983) Changing trends with abdominal injury in seatbelt wearers. *J Trauma* 23:1007–1008
7. Fuentes JM, Bloncourt J, Bourbotte G, et al (1984) La fracture de Chance. *Neurochirurgie* 30:113–118
8. Gallagher DJ, Heinrich SD (1990) Pediatric Chance fracture. *J Orthop Trauma* 4:183–187

9. Garrett JW, Braunstein PW (1962) The seat belt syndrome. *J Trauma* 2:200–204
10. Gertzbein SD, Court-Brown CM (1988) Flexion-distraction injuries of the lumbar spine. *Clin Orthop* 227:52–60
11. Glassman SD, Johnson JR, Holt RT (1992) Seatbelt injuries in children. *J Trauma* 33:882–886
12. Green DA, Green NE, Spengler DM, et al (1991) Flexion-distraction injuries to the lumbar spine associated with abdominal injuries. *J Spinal Disord* 4: 312–318
13. Gumley G, Taylor TKF, Ryan MD (1982) Distraction fractures of the lumbar spine. *J Bone Joint Surg Br* 64: 520–525
14. Holdsworth FW (1963) Fractures, dislocations, and fracture-dislocations of the spine. *J Bone Joint Surg Br* 45: 6–20
15. Holdsworth FW (1970) Fractures, dislocations, and fracture-dislocations of the spine. *J Bone Joint Surg Am* 52: 1534–1551
16. Howland WJ, Curry JL, Buffington CB (1965) Fulcrum fractures of the lumbar spine. *JAMA* 193:240–241
17. Hubbard DD (1974) Injuries of the spine in children and adolescents. *Clin Orthop* 100:56–65
18. Kaufer H, Hayes JT (1966) Lumbar fracture-dislocation: a study of twenty-one cases. *J Bone Joint Surg Am* 48: 712–730
19. Le Gay DA, Petrie DP, Alexander D (1990) Flexion-distraction injuries of the lumbar spine and associated abdominal trauma. *J Trauma* 30:436–444
20. Lesprit E, Pontailler JR, Vergnes P (2000) Fracture de Chance lombaire chez l'enfant associée à une lésion intra-abdominale. *Acta Orthop Belg* 66: 190–193
21. Leventhal HR (1960) Birth injuries of the spinal cord. *J Pediatr* 56:557–563
22. Miller JA, Smith TH (1991) Seatbelt induced Chance fracture in an infant. Case report and literature review. *Pediatr Radiol* 21:575–577
23. Moskowitz A (1989) Lumbar seatbelt injury in a child: case report. *J Trauma* 29:1279–1282
24. Palmer CE (1928) Center of gravity of the human body during the growth. *Am J Phys Anthropol* 11:423–455
25. Raney EM, Bennett JT (1992) Pediatric Chance fracture. *Spine* 17:1522–1524
26. Reid AB, Letts RM, Black GB (1990) Pediatric Chance fractures: association with intra-abdominal injuries and seatbelt use. *J Trauma* 30:384–391
27. Rennie W, Mitchell N (1973) Flexion distraction fractures of the thoracolumbar spine. *J Bone Joint Surg Am* 55: 386–390
28. Roaf R (1960) A study of the mechanics of spinal injuries. *J Bone Joint Surg Br* 42:810–823
29. Rockwood CA, Wilkins KE, Beaty JH (1996) *Fractures in children*, 4th edn. Lippincott, Philadelphia, pp 1062–1105
30. Rumball K, Jarvis J (1992) Seat-belt injuries of the spine in young children. *J Bone Joint Surg Br* 74:571–574
31. Smith WS, Kaufer H (1973) Patterns and mechanisms of lumbar injuries associated with lap seatbelts. *J Bone Joint Surg Am* 51:239–254
32. Taylor GA, Dunne Egli K (1988) Lap-belt injuries of the lumbar spine in children: a pitfall in CT diagnosis. *AJR* 150:1355–1358
33. Tso EL, Beaver BL, Haller JA (1993) Abdominal injuries in restrained pediatric passengers. *J Pediatr Surg* 28: 915–919
34. Voss L, Cole PA, D'Amato C (1996) Pediatric Chance fractures from lap-belts: unique case report of three in one accident. *J Orthop Trauma* 10:421–428
35. Woelfel G, Moore E, Cogbill T, et al (1984) Severe thoracic and abdominal injuries associated with lap-harness seatbelts. *J Trauma* 24:166–167