

---

## Obstetrical and Pediatric Anesthesia

---

# Intubation depth markings allow an improved positioning of endotracheal tubes in children

*[Le marquage de la profondeur d'insertion permet d'améliorer la mise en place de tubes endotrachéaux chez les enfants]*

Markus Weiss MD,\* Christian Balmer MD,† Alexander Dullenkopf MD,\* Walter Knirsch MD,† Andreas Ch. Gerber MD,\* Urs Bauersfeld MD,† Felix Berger MD††

---

**Objectives:** To evaluate the position of the new Microcuff® pediatric tracheal tube, based upon intubation depth markings.

**Methods:** With Institutional Ethics Committee approval and informed parental consent, we included patients from birth ( $\geq 3$  kg) to 16 yr undergoing interventional cardiac catheterization requiring general anesthesia with oro-tracheal intubation. The intubation depth mark of the tracheal tube was placed between the vocal cords by direct laryngoscopy. The distance between tube tip and tracheal carina was measured from routinely taken cardiac catheterization posterior-anterior x-ray computer images with the patient supine and the head in a neutral position. Evaluation was performed for 20 tubes size 3.0 mm internal diameter (ID) and for ten tubes of each size from 3.5 to 7.0 mm ID.

**Results:** 100 patients were studied (47 girls; 53 boys). Tracheal tube tip advancement into the trachea ranged from 40.6% to 68.6% (median 51.4%). The shortest distance from tube tip to the tracheal carina was 15.7 mm using a 3.0 mm ID tube. Using a standard formula for tube insertion in children aged  $\geq$  two years [ $12 \text{ cm} + (\text{age}/2)$ ], in one patient the tube tip would have been below the carina and in seven patients the tube cuffs would have been placed within the larynx.

**Conclusions:** The intubation depth markings of the new Microcuff® pediatric tracheal tube allow safe placement of the tracheal tube with a cuff-free laryngeal zone without the risk for endobronchial intubation. Placement using the intubation depth markings was superior to predicted insertion using a standard formula.

**Objectif :** Évaluer la position du nouveau tube endotrachéal pédiatrique Microcuff® d'après le marquage de la profondeur du tube.

**Méthode :** Avec l'accord du Comité d'éthique et des parents, nous avons étudié des patients, de bébé naissant ( $\geq 3$  kg) à 16 ans, devant subir une exploration cardiaque par cathétérisme nécessitant une anesthésie générale avec intubation oro-trachéale. La marque de la profondeur d'insertion du tube a été placée entre les cordes vocales par laryngoscopie directe. Le patient étant couché et sa tête en position neutre, la distance entre la pointe du tube et la carène de la trachée a été mesurée à partir d'images radiographiques informatisées postéro-antérieures, couramment prises, du cathétérisme cardiaque. L'évaluation a été réalisée pour 20 tubes de diamètre interne (DI) de 3,0 mm et pour 10 tubes de chaque taille entre 3,5 et 7,0 mm de DI.

**Résultats :** Nous avons étudié 100 patients (47 filles et 53 garçons). Le pourcentage d'occupation de la trachée par le tube endotrachéal variait de 40,6 % à 68,6 % (médiane de 51,4 %). La plus courte distance entre la pointe du tube et la carène a été de 15,7 mm avec un tube de DI de 3,0 mm. Selon la formule standard d'insertion d'un tube chez les enfants de  $\geq$  deux ans [ $12 \text{ cm} + (\text{âge}/2)$ ], la pointe du tube aurait été en un point distal de la carène chez un patient et le ballonnet au niveau du larynx chez sept patients.

**Conclusion :** Le marquage de la profondeur d'insertion du nouveau tube endotrachéal pédiatrique Microcuff® permet une mise en place sûre du tube et assure une zone laryngée libre de ballonnet sans le risque d'intubation endobronchique. Le placement guidé par des marques de profondeur du tube a été supérieur à l'insertion prédite selon la formule standard.

From the Department of Anesthesia\* and the Division of Congenital Heart Disease,† University Children's Hospital, Zurich, Switzerland; and the Department of Congenital Heart Disease,‡ German Heart Institute Berlin and Charite-Universitätsmedizin Berlin, Berlin, Germany.

*Address correspondence to:* Dr. Markus Weiss, Department of Anesthesia, University Children's Hospital, Steinwiesstrasse 75, CH-8032 Zurich, Switzerland. Phone: +41 44 266 71 11; Fax: +41 44 266 79 94; E-mail: markus.weiss@kispi.unizh.ch

*Disclosure statement:* Dr. Weiss and Dr. Gerber are involved in design and evaluation of a new cuffed tracheal tube in co-operation with Microcuff GmbH, Weinheim, Germany. No financial benefits or agreements arise from this co-operation.

*Accepted for publication October 28, 2004.*

*Revision accepted February 23, 2005.*

**I**NTUBATION depth markings on pediatric tracheal tubes were introduced to allow the safe positioning of tracheal tubes with the tube tip in the mid-tracheal position.<sup>1</sup> However, in the past manufacturers' markings on tracheal tubes have been reported to be unreliable and to be responsible for critical airway incidents.<sup>2-6</sup>

Recently, a newly designed cuffed pediatric tracheal tube [Microcuff® Pediatric Tracheal Tube (MPTT), Microcuff GmbH, Weinheim, Germany] with redefined intubation depth markings has been introduced into clinical practice (Figure 1).<sup>7</sup> The intubation depth markings of the MPTT are based upon tracheal dimensions published by Griscom and Petterson,<sup>8,9</sup> and potential mean tube tip displacement distances during head and neck manipulations calculated from data found in the literature.<sup>10-13</sup>

The depth marks are placed so that the tube tip becomes advanced to 60–65% of the shortest trachea of the related age group with the patient supine and the head in neutral position (Table). This results in a safety margin for caudal tube displacement of at least 15 mm in the smallest trachea of a neonate [3.0 mm internal diameter (ID) tube], and of 32 mm in a 14-yr-old child (7.0 mm ID tube).

The aim of this study was to evaluate the appropriateness of the intubation depth marks of the MPTT by radiological assessment of the tube tip position.

## Methods

With Institutional Ethics Committee approval and informed parental consent, we included pediatric patients from birth (if weighing  $\geq 3$  kg) up to 16 yr of age scheduled for interventional cardiac catheterization requiring general anesthesia with orotracheal intubation. Exclusion criteria were any known or suspected airway anomalies and difficult tracheal intubation. Premedication and induction of anesthesia (inhalational or *iv*) depended upon the patient's medical condition and preference. After adequate mask ventilation was achieved, a non-depolarizing neuromuscular blocking agent was administered and anesthesia was maintained with sevoflurane in oxygen. Tracheal tube sizes were selected according to the Motoyama's formula for selection of cuffed endotracheal tubes in children aged  $\geq$  two years [ID in mm] = (age in yr/4) + 3.5].<sup>14</sup> For patients below two years of age tubes were chosen according to Khine's recommendations.<sup>15</sup>

The glottic intubation depth mark was placed between the vocal cords using direct laryngoscopy, confirmed by the attending anesthesiologist and the tube was taped to the right lateral corner of the

mouth. Tube insertion depth at the lateral corner of the mouth was recorded.

Tracheal tube size was judged as adequate if air leakage at a maximum of 20 cm H<sub>2</sub>O airway pressure with the cuff not inflated was present and if tracheal sealing (no audible air leakage around the tube) with the cuff pressure not exceeding 20 cm H<sub>2</sub>O was achieved.

The distance from the end of the tube's distal radiopaque line to tracheal carina was measured from chest *x-ray* images routinely taken during cardiac catheterization with the patient supine and the head in a neutral position. Calibration of the cardiac catheter laboratory x-ray measurement system (Philips Integris Allura 9/9 biplane system, Philips DA Best, Netherlands) was performed by measuring the size of a standard cardiac catheter placed in the pulmonary trunk or in the ascending aorta. Calculations were performed off-line after the catheterization procedure. Radiological examinations were performed in 20 patients receiving tubes size ID 3.0 mm and in ten patients with tubes of each size from ID 3.5 to 7.0 mm.

## Data analysis

Since the radiopaque line does not extend to the very end of the tube, radiologically measured distance from the end of the radiopaque line to tracheal carina was corrected for the radiopaque free tube tip length to obtain the effective distance from the very end of the tube tip to carina. Tracheal length (vocal cords to carina) was calculated by adding the intubation depth mark to tube tip distance to the effective distance from the tube tip to carina. The percentage of the trachea to which the tracheal tube tip was advanced within the trachea was calculated. Demographic data are presented as mean  $\pm$  standard deviation and measured data are expressed as median and range.

A linear regression model was employed to relate tube insertion depths measured at the lips to patient age. In patients  $\geq$  two years of age (tube size ID 4.0–7.0 mm) the distance from tube tip to carina was compared to the theoretical distance using a standard formula for oral tube insertion [insertion depth (mm) = 12 + (age/2)].<sup>14,16</sup>

## Results

One hundred patients were studied (47 girls; 53 boys). Adequate tube positioning by laryngoscopy and radiological measurement of the distance from tube tip to tracheal carina could be obtained in all patients. Demographic data of the patients and calculated distances are summarized in the Table. In all except two patients the formula for tube size selection

TABLE Patient and intubation characteristics

<i>Tube size</i>	<i>Intended</i>	<i>Age</i>	<i>Height</i>	<i>Weight</i>	<i>Tube insertion</i>	<i>Measured distance</i>	<i>Calculated</i>	<i>Resulting</i>
<i>Internal</i>	<i>age group</i>				<i>depth noted at</i>	<i>from the carina</i>	<i>tracheal</i>	<i>percentage of</i>
<i>diameter</i>					<i>the lateral corner</i>	<i>to tube tip</i>	<i>length</i>	<i>tube insertion</i>
<i>mm</i>	<i>yr</i>	<i>yr</i>	<i>cm</i>	<i>kg</i>	<i>of the mouth</i>	<i>cm</i>	<i>cm</i>	<i>%</i>
					<i>cm</i>			
3	Newborns ( $> 3$ kg) to $< 1$ yr	$0.5 \pm 0.3$	$64.1 \pm 6.6$	$6.6 \pm 1.9$	10 (9.5-11.5)	2.39 (1.6-3.2)	4.79(3.9-5.6)	50.1 (43.0-60.5)
3.5	1 to $< 2$ yr	$1.4 \pm 0.3$	$78.3 \pm 5.7$	$9.8 \pm 1.5$	11.3 (10.5-13.0)	3.33 (1.8-3.8)	6.03 (4.5-6.5)	44.8 (41.6-60.5)
4	2 to $< 4$ yr	$3.0 \pm 0.7$	$93.2 \pm 6.4$	$12.8 \pm 2.3$	12.8 (11.0-13.5)	3.15 (2.4-3.7)	6.15 (5.4-6.7)	48.7 (44.8-55.3)
4.5	4 to $< 6$ yr	$4.8 \pm 0.5$	$105.2 \pm 6.4$	$18.8 \pm 4.3$	14.0 (12.5-15.0)	3.15 (2.1-5.0)	6.55 (5.5-8.4)	51.9 (40.6-62.0)
5	6 to $< 8$ yr	$6.9 \pm 0.6$	$120.1 \pm 6.3$	$23.6 \pm 4.2$	15.0 (13.5-15.0)	3.27 (2.5-4.5)	7.17 (6.4-8.4)	54.4 (46.6-61.4)
5.5	8 to $< 10$ yr	$8.9 \pm 0.6$	$132.8 \pm 7.6$	$28.5 \pm 5.6$	15.8 (15.0-16.5)	4.22 (3.0-5.3)	8.71 (7.5-9.8)	51.6 (45.9-60.0)
6	10 to $< 12$ yr	$11.0 \pm 0.8$	$143.1 \pm 9.8$	$38.2 \pm 10.7$	16.5 (16.0 -17.5)	4.20 (2.3-5.8)	9.20 (7.3-10.8)	54.3 (46.3-68.6)
6.5	12 to $< 14$ yr	$13.0 \pm 0.7$	$152.7 \pm 8.8$	$41.6 \pm 5.3$	17.3 (16.5-18.5)	5.36 (2.5-6.3)	10.76 (7.9-11.7)	50.2 (46.3-68.1)
7	14 to $< 16$ yr	$15.0 \pm 0.8$	$166.9 \pm 11.7$	$54.7 \pm 10.1$	19.3 (18.0-21.0)	5.09 (3.3-6.7)	10.89 (9.1-12.5)	53.3 (46.5-63.9)

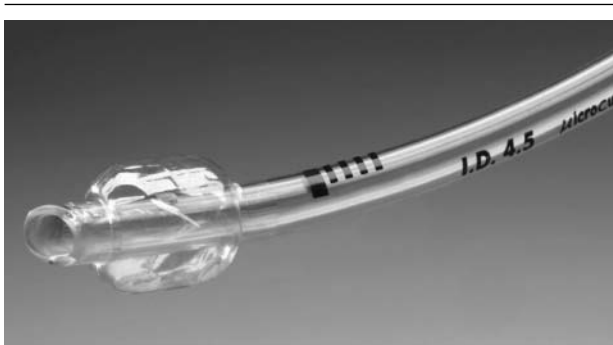

FIGURE 1 Microcuff® pediatric tracheal tube with high volume - low pressure cuff, semi-circular intubation depth-mark, cuff-free laryngeal tube shaft. Four points proximal to the semi-circular marking indicate the distance to it (in total 8 mm) which may be helpful when withdrawing a tube inserted too deeply, and when ary-epiglottic folds obstruct the view to the vocal cords in neonates and infants.

allowed insertion of an MPTT with an air leak at  $\leq 20$  cm H<sub>2</sub>O inspiratory pressure and to seal the airway with a cuff pressure  $\leq 20$  cm H<sub>2</sub>O [median 10 cm H<sub>2</sub>O (range 4–20)]. In two patients there was no air leakage at  $\leq 20$  cm H<sub>2</sub>O inspiratory pressure and the tubes had to be exchanged with a smaller one. No endobronchial intubation or accidental extubation during the cardiac procedures occurred, and no problem related to inadequate exhalation or barotrauma due to the lack of a Murphy eye was observed.

Tracheal length ranged from 3.9 cm to 12.5 cm. The distance from tube tip to tracheal carina ranged

from 15.6 mm in a 74-day-old infant to 66.6 mm in a 14.5-yr-old boy. The percentage of the trachea length occupied by the endobronchial tube ranged from 40.6% to 68.6% (median 51.4) using the revised tube markings, compared to a range of 39.1% to 101.8% if the standard formula-calculated insertion depth [12 cm + (age (yr)/2)] had been used. Overall, tube insertion depth at the lips in children  $\geq$  two years can be calculated from the formula  $11.16 \text{ cm} + [\text{age (yr)} \times 0.51]$ ; ( $r = 0.942$ ); (Figure 2).

In children  $\geq$  two years of age using the standard formula  $12 \text{ cm} + [\text{age (yr)}/2]$ , in one patient the tube tip would have been placed below the carina and in nine patients the tube tip would have been distal enough to risk endobronchial migration during extreme neck flexion, according to published displacement distances.<sup>10–13</sup> In seven patients, standard formula-based insertion depth would have directed the tube cuff into the larynx (Figure 3).

## Discussion

Neonates, infants and small children have short tracheas with a small margin of safety regarding correct endotracheal tube displacement. Therefore, tracheal tube positioning must avoid endobronchial intubation resulting in overinflation of the lung, possible alveolar rupture and interstitial emphysema, and/or hypo-ventilation with atelectasis. Conversely, sufficient intubation depth is essential to avoid accidental extubation during head-neck manipulations.<sup>17,18</sup> Various techniques for accurate tube tip positioning in children have been reported. Among others, these include palpation of the tracheal tube tip in the jugulum,<sup>19</sup> age-dependent formulas for oro- and nasotracheal tube

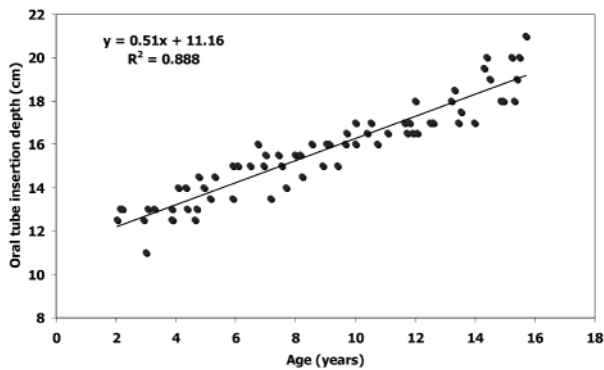


FIGURE 2 Linear regression plots for the comparison of tube insertion depth at the lips for children > two years to 16 yr.

insertion,<sup>16</sup> using the nasal-tragus or sternal length<sup>20</sup> or withdrawing an endobronchially placed tube until bilateral breath sounds or a reduction in inspiratory pressure can be detected.<sup>21,22</sup> These techniques are reliable and work well in clinical practice with uncuffed tracheal tubes in children.

The use of cuffed endotracheal tubes for smaller infants has been discussed by several authors.<sup>15,23-27</sup> When the tube insertion techniques described above are used for cuffed pediatric tracheal tubes, many of the tube cuffs would become positioned within the larynx or even above the vocal cords.<sup>5,28</sup> Thus, it is not surprising that laryngeal lesions have been reported with cuffed tracheal tubes in children and adults.<sup>29-31</sup> Consequently, a laryngeal cuff-free portion of the tube is mandatory for safe placement of cuffed tracheal tubes in children.<sup>32</sup> This is best achieved with intubation depth marks, since these guarantee a constant cuff-free distance between the vocal cords and upper border of the cuff. Unfortunately, in conventional cuffed pediatric tracheal tubes, the intubation depth mark is often misleading, if available at all.<sup>4-6</sup> Further, even with the upper border of the cuff positioned directly below the vocal cords, a small margin of safety for endobronchial intubation has been reported with cuffed pediatric tubes due to long cuffs and the presence of a Murphy eye.<sup>28</sup>

In the MPTT the high volume - low pressure cuffs made from polyurethane have improved sealing characteristics compared to polyvinyl chloride, and allowed the design of substantially shorter cuffs with sealing cuff pressures much lower than usually required in conventional pediatric cuffed tracheal

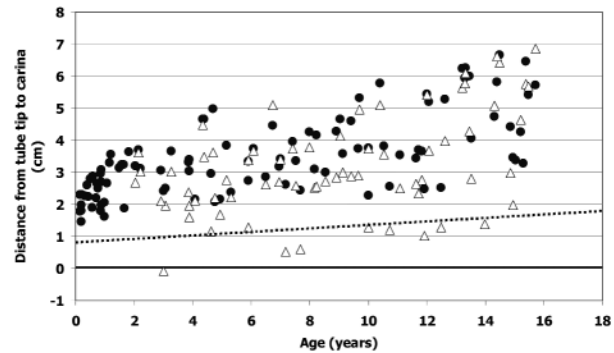


FIGURE 3 Tracheal tube tip position (●) based upon intubation depth marks ( $n = 100$ ). Formula based [ $12.0 \text{ cm} + (\text{age}/2)$ ] corrected tube tip position above the carina (Δ) in children aged  $\geq$  two years ( $n = 70$ ). The dotted line indicates the estimated mean caudal displacement of the tube tip with extreme neck flexion (neonate: 8 mm; adult patient 19 mm).<sup>10-13</sup> Endobronchial intubation is predicted during neck flexion below this line.

tubes.<sup>33,34</sup> Additionally, Murphy eyes were avoided to obtain a shorter tube tip. This allows positioning of the upper border of the cuff more distally and the design of adequate intubation depth markings guaranteeing a cuff-free tube within the larynx.<sup>7,35,36</sup> It may be argued that the lack of a Murphy eye carries the risk for inadequate exhalation and barotrauma if the tube tip is placed inadvertently against the trachea mucosa or can lead to unilateral ventilation, if the tube tip is placed near the tracheal carina. In the author's experience, depth markings provide more protection against endobronchial intubation and unilateral ventilation respectively, and cuffed tubes are at lower risk to have the tube bevel face against the tracheal mucosa, since the cuff stabilizes the tube shaft within the trachea. Furthermore, retrograde intubation using the Murphy eye is not suitable in children and the additional side hole encourages accumulation of secretions and accelerates tube blockage.<sup>37</sup>

According to our findings, the intubation depth markings of the MPTT allowed placement of the tracheal tube without advancing the tube tip further than the theoretically calculated margin of safety for avoiding endobronchial intubation with head-neck flexion.<sup>10-13</sup> Also, a cuff-free laryngeal portion of the tube was ensured by the MPTT markings. Finally, the markings should allow positioning in order to avoid accidental tracheal extubation during head-neck flexion (Appendix).

APPENDIX Age-related tracheal tube size selection,<sup>14,15</sup> technical tube (Microcuff®) and anatomical data<sup>8,9</sup>

<i>Internal diameter (ID)</i> (mm)	<i>Age group</i> (yr)	<i>Distance from depth mark to tube tip</i> (mm)	<i>Percentage of tracheal tube advancement into the shortest trachea</i> (%)	<i>Resulting distance from tube tip to tracheal carina in the shortest trachea</i> (mm)	<i>Tracheal length [normal ranges (-2 SD to +2 SD)] 8,9 Length (mm)</i>
ID 3.0	Newborns ( $\geq 3$ kg) to < 1 yr	24	60.9	15.4	39.4 - 60.5
ID 3.5	1 to < 2 yr	27	62.8	16.0	43 - 65.8
ID 4.0	2 to < 4 yr	30	64.4	16.6	46.6 - 76.4
ID 4.5	4 to < 6 yr	34	63.2	19.8	53.8 - 87.1
ID 5.0	6 to < 8 yr	39	63.9	22.0	61.0 - 97.7
ID 5.5	8 to < 10 yr	45	66.0	23.2	68.2 - 108.3
ID 6.0	10 to < 12 yr	50	66.3	25.4	75.4 - 124.3
ID 6.5	12 to < 14 yr	54	65.5	28.5	82.5 - 129.6
ID 7.0	14 to < 16 yr	58	64.7	31.7	89.7 - 140.2

In children  $\geq$  two years, inserting the MPTT according to the depth marks resulted in a tube insertion depth of approximately 1 cm less than with a conventional formula (insertion depth (mm) = 12 + [age (yr)/2]).<sup>14,17</sup> The main reason for this is that the depth marks of the MPTT are placed to result in tube tip advancement to 60–65% of the shortest predicted tracheal length of each intended age group. Therefore, larger patients within the same age group will have the tube advanced to a shorter percentage of the trachea, resulting in a reduced oral insertion depth and an increased distance from tube tip to carina. This reflects the persistent problem of pediatric tracheal tubes, i.e., that a single tube cannot be perfectly appropriate for all patients within an age-range of two years. Nevertheless, the intubation depth markings of the MPTT allowed safe placement of the tracheal tube in all children, a cardiac patient population with slightly subnormal height and weight, which may be at higher risk for endobronchial intubation. The depth markings were superior to the application of a standard formula, which would have resulted in several glottic and laryngeal placements of the cuff, and unacceptable low or even endobronchial position of the tube tip (Figure 3).

In conclusion, adequate intubation depth markings of cuffed pediatric tubes guarantee tube placement with a cuff-free laryngeal portion of the tube shaft and provide a sufficient margin of safety for preventing accidental endobronchial intubation and tracheal extubation. The intubation depth markings of the new MPTT allowed instant appropriate placement of the tube in children from birth to adolescence and were superior to the conventional age based formula for oral tube insertion depth.

## References

- Loew A, Thibeault DW. A new and safe method to control the depth of endotracheal intubation in neonates. *J Pediatr* 1974; 54: 506–8.
- Munro HM, Ghurye MR, Thomas VL. Potential hazard due to differing markings of paediatric tracheal tubes (Letter). *Paediatr Anaesth* 1995; 5: 339–42.
- Molendijk H. Use of the black area on the tubetip for rapid estimation of the insertional depth of endotracheal tubes in neonates: a potential hazard (Letter). *Arch Dis Child Fetal Neonatal Ed* 2001; 85: 77.
- Goel S, Lim SL. The intubation depth marker: the confusion of the black line. *Paediatr Anaesth* 2003; 13: 579–83.
- Weiss M, Dullenkopf A, Gysin C, Dillier CM, Gerber AC. Shortcomings of cuffed paediatric tracheal tubes. *Br J Anaesth* 2004; 92: 78–88.
- Wallace CJ, Bell GT. Tracheal tube markings (Letter). *Pediatr Anesth* 2004; 14: 283–5.
- Weiss M, Dullenkopf A, Gerber AC. Microcuff pediatric tracheal tube. A new tracheal tube with a high volume-low pressure cuff for children (German). *Anaesthesist* 2004; 53: 73–9.
- Griscom NT, Wohl ME. Dimensions of the growing trachea related to age and gender. *AJR Roentgenol* 1986; 146: 233–7.
- Pettersson H, Ringertz H. *Measurements in Pediatric Radiology*, 1st ed. London: Verlag-Springer; 1991: 103–5.
- Todres ID, deBros F, Kramer SS, Moylan FM, Shannon DC. Endotracheal tube displacement in the newborn infant. *J Pediatr* 1976; 89: 126–7.
- Donn SM, Kubns LR. Mechanism of endotracheal tube movement with change of head position in the neonate. *Pediatr Radiol* 1980; 9: 37–40.

- 12 Sugiyama K, Yokoyama K. Displacement of the endotracheal tube caused by change of head position in pediatric anesthesia: evaluation by fiberoptic bronchoscopy. *Anesth Analg* 1996; 82: 251-3.
- 13 Conrardy PA, Goodman LR, Lainge F, Singer MM. Alteration of endotracheal tube position. Flexion and extension of the neck. *Crit Care Med* 1976; 4: 8-12.
- 14 Motoyama EK. Endotracheal intubation. In: Motoyama EK, Davis PJ (Eds). *Smith's Anesthesia for Infants and Children*, 5th ed. St. Louis: C.V. Mosby Company; 1990: 272-5.
- 15 Khine HH, Corrdry DH, Kettrick RG, et al. Comparison of cuffed and uncuffed endotracheal tubes in young children during general anesthesia. *Anesthesiology* 1997; 86: 627-31.
- 16 Hatch DJ. Paediatric anaesthetic equipment. *Br J Anaesth* 1985; 57: 672-84.
- 17 Kuhns LR, Poznanski AK. Endotracheal tube position in the infant. *J Pediatr* 1971; 78: 991-6.
- 18 Hartrey R, Kestin IG. Movement of oral and nasal tracheal tubes as a result of changes in head and neck position. *Anaesthesia* 1995; 50: 682-7.
- 19 Bednarek FJ, Kuhns LR. Endotracheal tube placement in infants determined by suprasternal palpation: a new technique. *Pediatrics* 1975; 56: 224-9.
- 20 Shukla HK, Hendricks-Munoz KD, Atakent Y, Rapaport S. Rapid estimation of insertional length of endotracheal intubation in newborn infants. *J Pediatr* 1997; 131: 561-4.
- 21 Bloch EC, Ossey K, Ginsberg B. Tracheal intubation in children: a new method for assuring correct depth of tube placement. *Anesth Analg* 1988; 67: 590-2.
- 22 Kim KO, Um WS, Kim CS. Comparative evaluation of methods for ensuring the correct position of the tracheal tube in children undergoing open heart surgery. *Anaesthesia* 2003; 58: 889-93.
- 23 Deakers TW, Reynolds G, Stretton M, Newth CJ. Cuffed endotracheal tubes in pediatric intensive care. *J Pediatr* 1994; 125: 57-62.
- 24 Murrat I. Cuffed tubes in children: a 3-year experience in a single institution (Letter). *Paediatr Anaesth* 2001; 11: 745-50.
- 25 Erb T, Frei FJ. The use of cuffed endotracheal tubes in infants and small children (German). *Anaesthesist* 2001; 50: 395-400.
- 26 Newth CJ, Rachman B, Patel N, Hammer J. The use of cuffed versus uncuffed endotracheal tubes in pediatric intensive care. *J Pediatr* 2004; 144: 333-7.
- 27 Fine GF, Borland LM. The future of the cuffed endotracheal tube. *Pediatr Anesth* 2004; 14: 38-42.
- 28 Ho AM, Aun CS, Karmakar MK. The margin of safety associated with the use of cuffed paediatric tracheal tubes. *Anaesthesia* 2002; 57: 173-5.
- 29 Holzki J. Tubes with cuffs in newborn and young children are a risk! (German). *Anaesthesist* 2002; 51: 321-3.
- 30 Dillier CM, Trachsel D, Baulig W, Gysin C, Gerber AC, Weiss M. Laryngeal damage due to an unexpectedly large and inappropriately designed cuffed pediatric tracheal tube in a 13-month-old child. *Can J Anesth* 2004; 51: 72-5.
- 31 Cavo JW Jr. True vocal cord paralysis following intubation. *Laryngoscope* 1985; 95: 1352-9.
- 32 Mehta S. Intubation guide marks of correct tube placement. A clinical study. *Anaesthesia* 1991; 46: 306-8.
- 33 Dullenkopf A, Schmitz M, Gerber AC, Weiss M. Tracheal sealing characteristics of pediatric cuffed tracheal tubes. *Pediatr Anesth* 2004; 14: 825-30.
- 34 Dullenkopf A, Gerber A, Weiss M. Fluid leakage past tracheal tube cuffs: evaluation of a new Microcuff endotracheal tube. *Intensive Care Med* 2003; 29: 1849-53.
- 35 Schild JA. Relationship of laryngeal dimensions to body size and gestational age in premature neonates and small infants. *Laryngoscope* 1984; 94: 1284-92.
- 36 Kabane JC. Growth of the human prepubertal and pubertal larynx. *J Speech Hear Res* 1982; 25: 446-55.
- 37 Steward DJ, Lerman J. Techniques and procedures of pediatric anesthesia. In: Steward DJ, Lerman J (Eds). *Manual of Pediatric Anesthesia*, 5th ed. New York: Churchill Livingstone; 2001: 69-127.