

# Vacuum-Assisted Closure (V.A.C.<sup>®</sup>) for Temporary Coverage of Soft-Tissue Injury in Type III Open Fracture of Lower Extremities

Ludwig Labler, Marius Keel, Otmar Trentz<sup>1</sup>

## Abstract

**Background and Purpose:** The difficulty in the treatment of severe open fractures is a high infection rate and the problem of an adequate temporary coverage of the soft-tissue damage between successive second-look operations. The vacuum-assisted closure (V.A.C.<sup>®</sup>) offers good temporary soft-tissue coverage with a proven bacterial clearance and protects, at the same time, the soft tissue against secondary damage. The retrospective study reports the soft-tissue management of severe open fractures of Gustilo type IIIA and IIIB with V.A.C.<sup>®</sup> or Epigard<sup>®</sup>.

**Patients and Methods:** All open fractures were in the lower extremity and a result of a nonpenetrating trauma. V.A.C.<sup>®</sup> was used as a temporary dressing in 14 fractures and an Epigard<sup>®</sup> in twelve fractures.

**Results:** One early amputation was observed in each group. In the group with the soft-tissue coverage by Epigard<sup>®</sup>, in spite of less type IIIB fractures and less polytraumatized patients, the rate of infections (6/11) was substantially higher compared with patients managed by V.A.C.<sup>®</sup> therapy (infection: 2/13).

**Conclusion:** V.A.C.<sup>®</sup>, a temporary soft-tissue substitute, reduces the rate of infection and is an alternative of choice for the management of type III open fractures.

## Key Words

Vacuum-assisted closure · V.A.C.<sup>®</sup> · Open fracture · Soft-tissue injury

Eur J Trauma 2004;30:305–12

DOI 10.1007/s00068-004-1389-6

## Introduction

The management of high-energy open fractures continues to be a difficult problem confronting the surgeon. The essential part of an initial soft-tissue damage treatment is copious irrigation and thorough debridement [1, 2], which can cause significant soft-tissue defects. Then it must be decided whether the wound should be closed primarily or left open for delayed suture or reconstructive surgery. Different surgical methods have been developed to perform these difficult closures or temporary coverage. These include closure devices [3], skin grafts, local flaps, and free flap transfers. It was recommended to carry out the definitive soft-tissue coverage as soon as possible, preferably within the first 72 h after trauma [4], by a delayed primary closure of the wound [5] to prevent flap failures, infection and delayed bone healing. This, however, is often impracticable because of a complicated fracture, wound contamination or already existent infection or the associated injuries accompanied by hemodynamic instability and microcirculatory dysfunctions based on systemic inflammation or edema [6, 7] which prevent an early long-lasting reconstructive surgical intervention. Although skin grafts are readily obtainable, they depend on the vascularity of the recipient bed and may be contraindicated by exposed bone, cartilage, tendons or surgical implants. Consequently, one or more “second-look” operations are necessary prior to the definitive closure and an appropriate wound dressing is needed as a temporary coverage between repeated debridements. The essential request for such a temporary closure is to prevent the exposed vital structures from desiccation and bacterial contamina-

<sup>1</sup>Division of Trauma Surgery, Department of Surgery, University Hospital Zurich, Zurich, Switzerland.

Received: December 27, 2003; accepted: August 23, 2004.

tion and to induce a locally normal circulatory situation and proliferation of the wound granulation tissue. The traditional dressings for open wounds are wet-to-dry closures [1, 2, 8–17], antibiotic-impregnated bead pouch [18] and skin substitutes including xenografts, human allografts or synthetic membranes such as, Epigard® (Biovision GmbH, Ilmenau, Germany) [19–23]. The vacuum-assisted closure (V.A.C.®, Kinetic Concepts, Inc., San Antonio, TX, USA), a new, efficient system for the treatment of problematic wounds [24–29], became a generally accepted technique and was applied as a temporary wound closure also in the case of open fractures [30–32]. Epigard® treatment was the standard dressing for soft-tissue management in our clinic until the late 1990s. Since 2000 it was substituted stepwise by V.A.C.®, which finally became the standard temporary closure of problematic wounds of various types. The purpose of this case control report is to compare retrospectively two standard techniques of a temporary wound coverage and to evaluate the results of the use of these therapies in the management of patients with high-energy soft-tissue injuries of Gustilo type III open fractures [2] of lower extremities.

### Patients and Methods

All patients had severe open fractures of the lower extremity classified as type IIIA or IIIB according to Gustilo et al. [2] and were admitted as an emergency to our clinic. In this study we excluded all type IIIC fractures because of the associated vascular injuries, which compromise the circulatory situation of the local soft-tissue injury. The patients not included in the study were treated during the interim when we stepwise introduced V.A.C.®, and both techniques were used simultaneously and partly consecutively in the same patient. All fractures were a result of a high-energy trauma, and the partly polytraumatized patients were treated according to the Advanced Trauma Life Support Guidelines [33] and our standard trauma protocol [34, 35]. After control of the airway, ventilation and cardiovascular functions, life-saving procedures were performed. Afterwards, hemorrhage control, radical wound debridement, decompression of compartments, and primary stabilization of major fractures (“day 1 surgery”) were carried out [34, 35]. Debridement of open fractures was performed in a stepwise manner, i.e., one debridement in the emergency room and two further debridements with copious irrigation in the operating room on the admission day, and primary immobilization of the fracture

was carried out preferably by external skeletal fixation. “Second-look” operations included subsequent thorough debridements, fracture redislocation and repeated irrigation with normal saline solution and were carried out, as far as possible, every 48 h in dependence of the wound and patients condition. The V.A.C.® system or Epigard® was applied at the end of each surgical second look. This procedure was repeated until the soft-tissue defect became macroscopically clean and was free of necrotic tissue.

The V.A.C.® system was applied in a group of twelve patients with 14 open fractures treated between June 2001 and December 2002 (group I). The V.A.C.® system consists of polyurethane soft sponge shaped to fit the wound and placed into the cavity. The 400–600 mm pore size of the sponge maximizes tissue growth [36]. The suction tube with side ports was embedded in the center of the sponge allowing communication of its lumen to all spaces of the foam and attached to an adjustable suction pump. A transparent occlusive gas- and fluid-impermeable plastic film was applied over the foam to seal it airtight and the pump was started to produce a continuous negative pressure of 125 mmHg.

A group of eleven patients with twelve open fractures, hospitalized between March 1998 and November 1999, was treated with Epigard® as the temporary closure (group II). Epigard® dressing, reticulated polyurethane foam laminated to a microporous polypropylene film, is applied in a manner similar to skin grafting, i.e., it is stapled to the wound edges and afterwards covered with a sterile dressing. Both groups of our patients belong to time periods when Epigard® and V.A.C.®, respectively, were used as a standard technique. The dressing change in both groups was performed under general anesthesia during each “second look” in the operating room. Bacterial cultures were obtained routinely on admission and during each “second look”. A cephalosporin of the third generation was systemically applied in therapeutic doses on admission and continued or adapted to the bacterial culture results.

Clinical data in Table 1 include the study population, the cause of the injury, the Injury Severity Score (ISS) [37], associated injuries, and hospital and intensive care unit (ICU) stay. Fracture localization, classification according to Gustilo et al. [2] and Mangled Extremity Severity Score (MESS) [38–40] are summarized in Table 2. Evaluation of both techniques includes the duration of the temporary coverage use, the final wound closure type and its outcome, and the fracture management and

**Table 1.** Clinical characteristics of patients. a: head; b: thorax; c: abdomen; d: extremities; e: skin; F: female; ICU: intensive care unit; ISS: Injury Severity Score [37]; M: male.

	Patient	Gender	Age (years)	Cause of injury			Multiply injured (ISS)	Associated injury	Hospital stay (days)	ICU stay (days)
				Traffic	Impaction	Fall from height				
Group I (V.A.C.®)	1	M	56		+		No		17	–
	2	F	64			+	Yes (41)	a, b, c, d, e	61	15
	3	F	18			+	Yes (41)	a, b, c, d, e	32	32
	4	F	45	+			No		34	–
	5	M	56	+			Yes (34)	a, b, c, d, e	67	37
	6	M	22	+			Yes (57)	a, b, c, d	158	27
	7	M	19	+			Yes (19)	a, b, d	37	10
	8	M	54		+		Yes (34)	a, b, d, e	63	27
	9	M	33		+		No		30	–
	10	F	68	+			Yes (34)	c, d, e	62	20
	11	M	31		+		No		35	–
	12	M	35			+	Yes (34)	b, c, d, e	43	5
Group II (Epigard®)	1	F	30	+			No	b, d	29	6
	2	M	43			+	No		27	–
	3	M	75	+			No		38	–
	4	M	40			+	No		41	2
	5	F	89	+			Yes (20)	d, e	95	–
	6	M	62	+			No		35	–
	7	M	20		+		No		25	–
	8	F	43	+			Yes (18)	b, d	21	–
	9	M	49		+		No		20	–
	10	M	49			+	No		27	–
	11	M	46	+			Yes (38)	b, c, d, e	104	48

its complications (Table 2). Bacterial characteristics and soft-tissue complications are summarized in Table 3. All patients were followed for a minimum of 12 months after definitive soft-tissue coverage to verify healing or complications.

## Results

The temporary wound closure changes averaged 4.3 in group I (range 1–10) and 2.2 in group II (range 1–3). Epigard® was used for a total of 4.9 days on average (range 2–9 days), whereas V.A.C.® covered the wound for 11.3 days (range 2–35 days). Figure 1 shows a severe soft-tissue defect of IIIB fracture with luxation of the right ankle (patient #2), which was temporarily closed by V.A.C.®. Only four wounds out of both groups (group I: patient #9; group II: patients #7, 8, and 10) did not need any further treatment, and the delayed primary closure could be directly performed. All other soft-tissue defects were covered mostly by microvascular flaps or mesh grafts (Table 2). The clinical result of a type IIIB fracture (patient #2) after soft-tissue reconstruction with microvascular flap is shown in Figure 2. Soft-tissue reconstruction was performed after an average of 12.3

days in group I (range 2–35 days) and 4.1 days (range 2–8 days) in group II. An amputation in group I had to be performed 10 days after admission (patient #5) due to complete necrosis of the soft tissues of the foot. We had two serious soft-tissue complications in group I with infections (patients #6 and 11) resulting in a nonunion situation of the bone (one intraarticular fracture of the distal femur and one tibial shaft fracture) where the soft-tissue defect was closed by a microvascular flap 12 and 5 days after trauma, respectively. In both cases the plate implants were removed and a debridement of the soft tissue and of the nonhealing fracture was performed. Both fractures were stabilized by plates and bone grafting from iliac crest. Both fractures consolidated after 6 and 4 months, respectively. One minor complication, also in group I, with an infection in the former bed of the microvascular flap used for reconstruction of the tibial soft-tissue defect occurred in patient #8. After debridement the wound healed uneventfully without any signs of infection. In group II, six complications were severe soft-tissue infections, combined with a nonunion in two cases, and one complication was a nonunion without infection (Tables 2 and 3). In three patients (#1, 2, and 6)

**Table 2.** Open fracture pattern. MESS: Mangled Extremity Severity Score [38–40].

Patient	Injury pattern and fracture classification						Fracture management			Soft-tissue management				Complications	
	Localization						Primary stabilization (admission day)	Secondary stabilization	Definitive stabilization (days after admission)	Delayed primary closure	Mesh	Microvascular flap	Amputation		Nonunion
	Femur	Knee	Tibia Ankle	Foot	IIIA	IIIB									
Group I (V.A.C.®)	1		+			+	5	External fixator	Plate	5			+		
	2					+	7	External fixator	Plate	6			+		
	3				+		4	External fixator	–	–			+		
	4		+			+	4	External fixator	Plate	3			+		
	5				+		5	External fixator	–	10				+	
	6					+	7	External fixator	K-wire	2		+			
	7	+				+	5	External fixator	Plate	6			+	+	
	8					+	5	External fixator	Screw	6		+			
	9				+	+	2	External fixator	Screw	7			+		
	10					+	6	External fixator	Plate	18			+		
	11				+		6	External fixator	Plate	–		+			
	12	+				+	4	External fixator	–	–			+		
	11					+	3	External fixator	Plate	5			+	+	
	12	+				+	3	Plate	–	–		+			
Group II (Epigard®)	1		+			+	5	Plate	–	–			+	+	
	2					+	2	External fixator	Nail	3			+	+	
	3					+	4	Plate	–	–			+		
	4					+	3	Plate	–	–			+		
	5					+	5	External fixator	–	–				+	
	6					+	4	External fixator	Plate	7			+		
	7	+				+	4	External fixator	Plate	5		+			
	8					+	6	External fixator	Plate	9		+			
	9					+	3	Nail	–	–			+	+	
	10					+	3	External fixator	Plate	8		+		+	
	11	+				+	9	External fixator	Plate	2			+		
			+			+	5	External fixator	Cerclage	2			+		

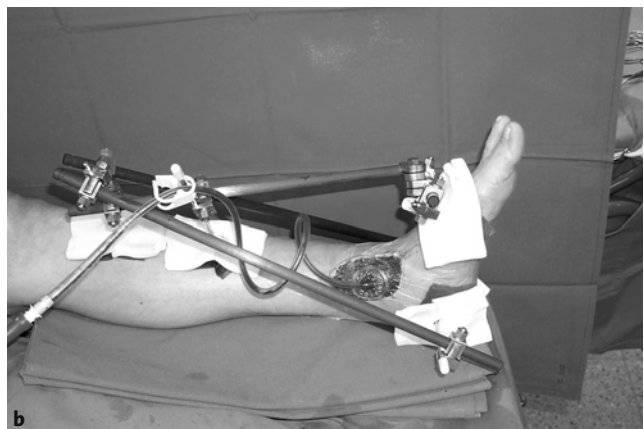
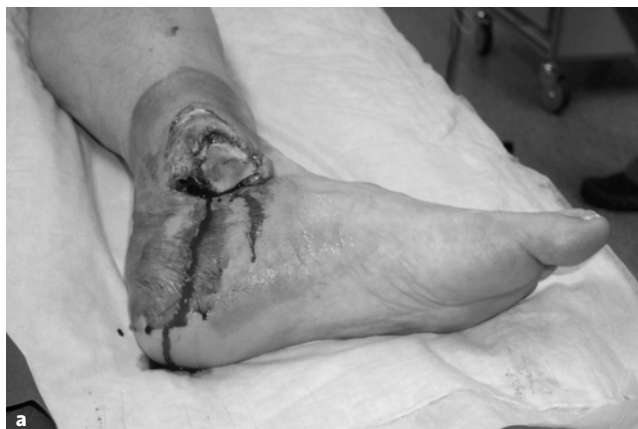the soft-tissue injury was closed by a microvascular flap and in two patients (#8 and 10) by a delayed primary closure. The free flap reconstructions were performed on the 2nd, 3rd and 7th day and the delayed primary closures on the 4th and 8th day after admission. An amputation had to be performed 5 days after admission on the sixth patient (#5) due to an uncontrollable infection situation. The patient died 2 days afterwards due to cardiovascular instability. The three observed nonunions of tibial fractures in group II were caused by a local infection 43 and 125 days after trauma in two cases, and in one case the nonunion was seen after 75 days. The local infection of the tibial fracture in patient #1 resulted in a septic complication of the uncontrollable infection under the free flap, and as a consequence, an amputation

was necessary on the 8th day. Of the remaining five patients, four (#2, 6, 8, and 10) had a debridement 43, 157, 33, and 125 days after trauma with loss of the primary free flap in two cases (#2 and 10) and replacement by a soleus flap. Implants were removed in three patients (#2, 6, and 10) during debridement. In patient #6 the fracture consolidated. After reaming, a new intramedullary nail was used in patient #2, and the tibial nonunion was treated by a new plate and a bone graft from iliac crest in patient #10. Both tibial fractures healed 4 months later. After treatment of the local infection, the fracture of patient #8 healed uneventfully after 5 months. In patient #9 the nonunion situation after bone debridement was treated by a bone graft from the iliac crest and the fracture consolidated after 12 weeks. All seven serious

**Table 3.** Bacteriologic characteristics of soft-tissue defects. No: no bacterial growth; SKN: *Staphylococcus coagulase-negative*.

	Patient	Wound contamination on admission	Primary antibiotic therapy	Change of antibiotic during hospital stay	Wound infection in follow-up (days)	Bacteriologic species of infected wounds
Group I (V.A.C.®)	1	SKN, <i>Brevibacterium</i> spp.	Cephalosporin	–		
	2	<i>Bacillus cereus</i>	β-lactam antibiotic <sup>a</sup>	Vancomycin, β-lactam antibiotic		
	3	<i>Bacillus cereus</i>	Cephalosporin	Vancomycin, cephalosporin		
	4	No	Cephalosporin	–		
	5	<i>Bacillus cereus</i> , <i>Staphylococcus aureus</i>	Cephalosporin	Teicoplanin, ciprofloxacin		
	6	<i>Bacillus cereus</i> , SKN	Cephalosporin	Vancomycin, ciprofloxacin, rifampicin	112	SKN
	7	<i>Bacillus cereus</i>	Cephalosporin	Clindamycin		
	8	No	Cephalosporin	Cephalosporin, β-lactam antibiotic		
	9	SKN	Cephalosporin	–		
	10	SKN	Cephalosporin	Ciprofloxacin		
	11	No	Cephalosporin	Rifampicin, aminopenicillin	211	β-hemolytic <i>Streptococcus</i> group A
	12	<i>Bacillus cereus</i>	Cephalosporin	–		
Group II (Epigard®)	1	<i>Staphylococcus aureus</i> , SKN	Cephalosporin	–	8	<i>Staphylococcus aureus</i> , SKN
	2	No	Cephalosporin	–	43	<i>Staphylococcus aureus</i>
	3	<i>Bacillus cereus</i>	Cephalosporin	Ciprofloxacin, rifampicin		
	4	<i>Bacillus cereus</i> , SKN	Cephalosporin	Vancomycin, ciprofloxacin, rifampicin		
	5	<i>Bacillus cereus</i>	Cephalosporin	Vancomycin, cephalosporin	5	<i>Bacillus cereus</i>
	6	SKN, <i>Pseudomonas</i>	Cephalosporin	Vancomycin, cephalosporin	157	<i>Staphylococcus aureus</i>
	7	No	Cephalosporin	–		
	8	<i>Bacillus cereus</i>	Cephalosporin	Ciprofloxacin, rifampicin	33	<i>Pseudomonas</i>
	9	SKN	Cephalosporin	Ciprofloxacin		
	10	SKN	Cephalosporin	Ciprofloxacin	125	<i>Staphylococcus aureus</i>
	11	<i>Bacillus</i> spp.	Cephalosporin	–		

<sup>a</sup>Meronem® used because of severe lung injury



**Figures 1a and 1b.** a) Severe soft-tissue defect of a IIIB fracture with luxation of the right ankle (patient #2). b) External fixation of the right ankle and coverage of soft-tissue defect by V.A.C.® after debridement of the soft tissue and fracture.

complications in group II occurred in seven out of nine tibial fractures, whereas in group I only one of seven tibial fractures was involved in bacterial infection (Tables 2 and 3). The MESS of the tibial fractures averaged 5.4 in group I (range 3–7) and 4.1 in group II (range 2–7).

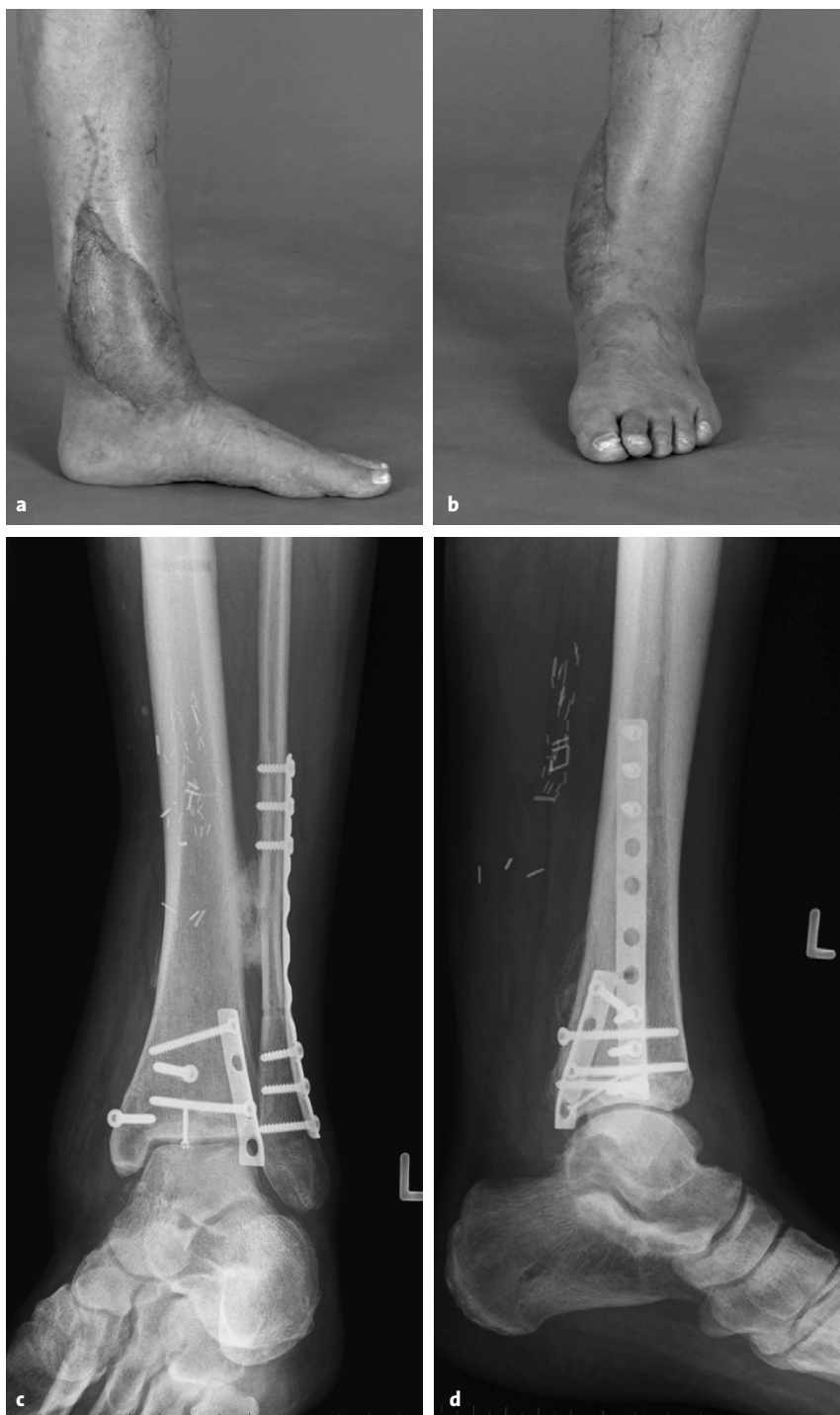All wounds except three amputations (group I: patient #5; group II: patients #1 and 5) were available for follow-up examination. During follow-up, local soft tissue healed uneventfully in 11/13 and 5/10 lower extremities in groups I and II, respectively.

### Discussion

Severe soft-tissue damage, wound contamination, compromised vascularity, and fracture instability are the four factors determining the outcome of severe type III open fractures and are predictive of later complications [2]. The fracture location and its configuration are of less importance [2]. The main obstacle always is the management of the wound injury, and the bone mostly is not a problem when the soft tissue is in order [41]. The studies dealing with the management of open fractures and their delayed definitive stabilization concentrate on skeletal fixation and definitive wound closure. The problem of the open wound mostly is not discussed in detail. In our study, we concentrated on the healing process of the wound before a definitive closure and on the temporary wound dressing. The definitive wound closure as well as the skeletal location and stabilization are not the topic of this study and are listed in Table 2.

The V.A.C.<sup>®</sup> management has not yet been compared with any of the classic methods of temporary closure of open fractures except one case report where poor results of a wet-to-dry dressing were fairly improved by a

successful V.A.C.<sup>®</sup> application [32]. Although the number of our patients is small for firm conclusions to be reached, a drawback of all studies reporting



**Figures 2a to 2d.** a, b) Clinical result of the type IIIB fracture of Figure 1 after soft-tissue reconstruction with a microvascular flap. c, d) X-rays of the IIIB fracture 8 months after trauma with documented bone healing.

open fractures of lower extremities with 16 patients at best [30–32, 42–44], we believe that there is still a higher tendency to an infection when Epigard® is applied. This follows not only from a lower infection rate in group I (Table 2), but also from the fact that the group in question includes more IIIB fractures, more severely injured patients (ISS > 17) with SIRS (systemic inflammatory response syndrome) accompanied with immune deficiency and requiring sometimes a multitude of dressing changes with surgical debridements in the operating room before definitive soft-tissue reconstruction. This also is due to the fact that in many of the severely injured patients (ISS > 17) in group I, the reconstructive surgery by free flap could be performed only when the patients were under stable conditions and this exceeded mostly the time recommended for an early covering of soft-tissue defects in open fractures [4, 5]. The nearly twofold number of surgical debridements in group I, compared with group II, might be responsible for the lower infection rate in the follow-up [45]. This as well might explain that one infection only was observed, and that in the case of debridement after the shortest time of 5 days in group I, where the wounds were generally covered later by a surgical intervention after 6.9 days on average, in comparison with group II where the intervention was carried out earlier after 4.4 days and the number of infections was higher. The low infection rate of the V.A.C.® system corresponds with the results in the literature [30–32, 42, 43]. The MESS values of  $\geq 4$  are sensitive and indicate an amputation [40], and in this connection it is worth mentioning that no amputations were necessary in the tibial fractures of group I despite MESS values of 5.4 (Table 2). In group II, on the other hand, two amputations in this fracture localization by values of 4.1 had to be carried out as a consequence of an uncontrollable infection situation.

Although the difference between both groups is not statistically significant and a striking proof could not yet be supplied, important properties of V.A.C.®, missing in the Epigard® system, speak in favor of the former one. The negative pressure continuously removes the interstitial fluid from the wound together with the factors suppressing the proliferation of keratinocytes, fibroblasts and vascular endothelial cells. This simultaneously improves the capillary blood flow and produces a rapid formation of granulation tissue. The bacterial colonization is substantially reduced after few days. The

dressing completely isolates the wound and decreases a secondary contamination from the environment. The mechanical pressure seems to promote cell mitosis and new blood vessel formation and the suction draws the wound edges slowly together.

### Conclusion

In spite of the small number of patients, the results show the efficiency of the V.A.C.® system, and its use in the wound care of severe open fractures can be recommended as an alternative to Epigard®.

### References

1. Gustilo RB, Anderson JT. Prevention of infection in the treatment of one thousand and twenty-five open fractures of long bones: retrospective and prospective analyses. *J Bone Joint Surg Am* 1976;58:453–8.
2. Gustilo RB, Mendoza RM, Williams DN. Problems in the management of type III (severe) open fractures: a new classification of type III open fractures. *J Trauma* 1984;24:742–6.
3. Narayanan K, Furtrell JW, Bentz M, et al. Comparative clinical study of sure-closure device with conventional wound closure techniques. *Ann Plast Surg* 1995;35:485–91.
4. Godina M. Early microsurgical reconstruction of complex trauma of the extremities. *Plast Reconstr Surg* 1986;78:285–92.
5. Gorman PW, Barnes CL, Fischer TJ, et al. Soft-tissue reconstruction in severe lower extremity trauma. A review. *Clin Orthop* 1989;243:57–64.
6. Shackford SR, Mackersie RC, Holbrook TL, et al. The epidemiology of traumatic death. A population-based analysis. *Arch Surg* 1993;128:571–5.
7. Schimpff SC, Miller RM, Polkavetz S, et al. Infection in the severely traumatized patient. *Ann Surg* 1974;179:352–7.
8. Howe HR Jr, Poole GV Jr, Hansen KJ, et al. Salvage of lower extremities following combined orthopaedic and vascular trauma. A predictive salvage index. *Am Surg* 1987;53:205–8.
9. Lange RH. Limb reconstruction versus amputation decision making in massive lower extremity trauma. *Clin Orthop* 1989;243:92–9.
10. Chapman MW, Mahoney M. The role of early internal fixation in the management of open fractures. *Clin Orthop* 1979;138:120–31.
11. Clancey GJ, Hansen ST Jr. Open fractures of the tibia: a review of one hundred and two cases. *J Bone Joint Surg Am* 1978;60:118–22.
12. Rittmann WW, Schibli M, Matter P, et al. Open fractures. Long-term results in 200 consecutive cases. *Clin Orthop* 1979;138:132–40.
13. Caudle RJ, Stern PJ. Severe open fractures of the tibia. *J Bone Joint Surg Am* 1987;69:801–7.
14. Velazco A, Whitesides TE Jr, Fleming LL. Open fractures of the tibia with the Lotte nail. *J Bone Joint Surg Am* 1983;65:879–85.
15. Holbrook JL, Swiontkowski MF, Sanders R. Treatment of open fractures of the tibial shaft: Ender nailing versus external fixation. A randomized, prospective comparison. *J Bone Joint Surg Am* 1989;71:1231–8.
16. Helfet DL, Howey T, Dipasquale T, et al. The treatment of open and/or unstable tibial fractures with an unreamed double-locked tibial nail. *Orthop Rev* 1994;23:Suppl:9–17.



17. Whittle AP, Russell TA, Taylor JC, et al. Treatment of open fractures of the tibial shaft with the use of interlocking nailing without roaming. *J Bone Joint Surg Am* 1992;74:1162-71.
18. Henry SL, Ostermann PAW, Seligson D. The antibiotic bead pouch technique. The management of severe compound fractures. *Clin Orthop* 1993;295:54-62.
19. Kiffner E, Bohmert H. Experiences with Epigard, a synthetic skin substitute, in the treatment of skin defects. *Fortschr Med* 1976;94:861-4.
20. Alexander JW, Wheeler LM, Rooney RC, et al. Clinical evaluation of Epigard, a new synthetic substitute for homograft and heterograft skin. *J Trauma* 1973;13:374-83.
21. Roth RR, Winton GB. A synthetic skin substitute as a temporary dressing in Mohr surgery. *J Dermatol Surg Oncol* 1989;15:670-2.
22. Weise K, Weller S. Treatment results of comparative study using polyurethane synthografts. *Akt Traumatol* 1981;11:1-6.
23. Knapp U, Weller S. Soft tissue injuries in compound fractures. *Zentralbl Chir* 1979;104:154-60.
24. Morykwas MJ, Argenta LC, Shelton-Brown EI, et al. Vacuum-assisted closure: a new method for wound control and treatment: animal studies and basic foundation. *Ann Plast Surg* 1997;38:553-62.
25. Argenta LC, Morykwas MJ. Vacuum-assisted closure: a new method for wound control and treatment: clinical experience. *Ann Plast Surg* 1997;38:563-77.
26. Morykwas MJ, Argenta LC. Nonsurgical modalities to enhance healing and care of soft tissue wounds. *J South Orthop Assoc* 1997;6:279-88.
27. Fabian TS, Kaufman HJ, Lett ED, et al. The evaluation of subatmospheric pressure and hyperbaric oxygen in ischemic full-thickness wound healing. *Am Surg* 2000;66:1136-43.
28. Philbeck TE Jr, Whittington KT, Millsap MH, et al. The clinical and cost effectiveness of externally applied negative pressure wound therapy in the treatment of wounds in home healthcare Medicare patients. *Ostomy Wound Manage* 1999;45:41-50.
29. Labler L, Oehy K. Vacuum sealing of problem wounds. *Swiss Surg* 2002;8:266-72.
30. Fleischmann W, Strecker W, Bombelli M, et al. Vacuum sealing as treatment of soft tissue damage in open fractures. *Unfallchirurg* 1993;96:488-92.
31. Mooney JF 3rd, Argenta LC, Marks MW, et al. Treatment of soft tissue defects in paediatric patients using the V.A.C.™ System. *Clin Orthop* 2000;376:26-31.
32. Greer S, Kasabian A, Thorne C, et al. The use of a subatmospheric pressure dressing to salvage a Gustilo grade IIIB open tibial fracture with concomitant osteomyelitis to avert a free flap. *Ann Plast Surg* 1998;41:68.
33. Collicott PE, Hughes I. Training in advanced trauma support. *JAMA* 1980;293:1156-9.
34. Ertel W, Trentz O. Causes of shock in severely traumatized patient: emergency treatment. In: Goris RJA, Trentz O, eds. *The integrated approach to trauma care, the first 24 hours*. Heidelberg: Springer, 1995:78-87.
35. Trentz O, Friedl HP. Therapeutic sequences in the acute period in unstable patients. In: Goris RJA, Trentz O, eds. *The integrated approach to trauma care, the first 24 hours*. Heidelberg: Springer, 1995:172-8.
36. Wake MC, Patrick CW, Mikos AG. Pore morphology effects on the fibrovascular tissue growth in porous polymer substrates. *Cell Transplant* 1994;3:339-43.
37. Baker SP, O'Neill B, Haddon W Jr, et al. The Injury Severity Score: a method for describing patients with multiple injuries and evaluating emergency care. *J Trauma* 1974;14:187-96.
38. Gregory RT, Gould RM, Peclet M, et al. The mangled extremity syndrome (M.E.S.): a severity grading system for multisystem injury of the extremity. *J Trauma* 1985;25:1147-50.
39. Johansen K, Daines M, Howey T, et al. Trauma. Objective criteria accurately predict amputation following lower extremity. *J Trauma* 1990;30:568-73.
40. McNamara MG, Heckman JD, Corley FG. Severe open fractures of the lower extremity: a retrospective evaluation of the Mangled Extremity Severity Score (MESS). *J Orthop Trauma* 1994;8:81-7.
41. Allgöwer M. Weichteilprobleme und Infektionsrisiko der Osteosynthese. *Langenbecks Arch Chir* 1971;329:1127-36.
42. Prokuski L. Negative pressure dressing for open fracture wounds. *Iowa Orthop J* 2002;22:20-4.
43. DeFranzo AJ, Argenta LC, Marks MW, et al. The use of vacuum-assisted closure therapy for treatment of lower-extremity wounds with exposed bone. *Plast Reconstr Surg* 2001;108:1184-91.
44. Hersovici D Jr, Sanders RW, Scaduto JM, et al. Vacuum assisted wound closure (VAC therapy) for the management of patients with high-energy soft tissue injuries. *J Orthop Trauma* 2003;17:683-8.
45. Merritt K. Factors increasing the risk of infection in patients with open fractures. *J Trauma* 1988;28:823-7.

**Address for Correspondence**

Ludwig Labler, MD  
 Division of Trauma Surgery  
 Department of Surgery  
 University Hospital Zurich  
 Rämistraße 100  
 8091 Zürich  
 Switzerland  
 Phone (+41/1) 255-1111, Fax -4406  
 e-mail: ludwig.labler@chi.usz.ch