

J Neurooncol (2008) 90:357–362
 DOI 10.1007/s11060-008-9674-6

CLINICAL STUDY - PATIENT STUDY

Anticoagulation for radiation-induced neurotoxicity revisited

Caroline Happold · Ulrike Ernemann · Patrick Roth ·
 Wolfgang Wick · Michael Weller · Friederike Schmidt

Received: 5 May 2008 / Accepted: 4 August 2008 / Published online: 22 August 2008
 © Springer Science+Business Media, LLC. 2008

Abstract No effective treatment for delayed radiation-induced neurotoxicity has been established. Its natural course is highly variable, but spontaneous recovery has been well documented. Here we report our experience with therapeutic anticoagulation in patients with cerebral lesions ($n = 3$), cranial nerve lesions ($n = 1$) or myelopathy ($n = 4$) attributed to irradiation. Two of three patients with cerebral lesions and the patient with cranial nerve lesions showed a minor improvement of clinical symptoms. In contrast, none of the patients with radiation myelopathy improved. No patient suffered hemorrhage or other adverse effects of anticoagulation. Overall, anticoagulation therapy demonstrates only modest activity for delayed radiation-induced neurotoxicity in this small case series.

Keywords Radiation · Neurotoxicity · Anticoagulation · Myelopathy

Abbreviations

CHOP	Cyclophosphamide, doxorubicin, oncovin (vincristine), prednisolone
FEC	5-Fluorouracil, epirubicin, cyclophosphamide
FLAIR	Fluid attenuated inversion recovery
LMWH	Low molecular weight heparin
MRI	Magnetic resonance imaging
MTX	Methotrexate
NHL	Non-Hodgkin lymphoma
PCNSL	Primary CNS lymphoma
PCV	Procabazine, CCNU (lomustine), vincristine
RT	Radiotherapy
T1w	T1 weighted
UH	Unfractionated heparin
VAD	Vincristine, adriablastin, dexamethasone
WBRT	Whole brain radiotherapy

Introduction

Potentially irreversible treatment-induced damage to the nervous system has become a relevant management problem as more cancer patients experience prolonged survival. Long-term radiation-induced neurotoxicity includes cerebral radionecrosis, diffuse cerebral white matter changes, radiation myelopathy, and plexus lesions [1–3]. There may be spontaneous recovery, but most clinical symptoms associated with radiation-induced neurotoxicity are slowly progressive. Treatment with steroids is often insufficiently effective and associated with significant side effects when administered for months. Since a vascular pathogenesis has been proposed to mediate some of these symptoms, anticoagulation using heparin and warfarin has been explored for possible efficacy [4, 5]. The largest series [5] reported some recovery of function in 5 of 8 patients with cerebral

C. Happold · P. Roth · W. Wick · M. Weller · F. Schmidt
 Department of General Neurology, Hertie Institute for Brain Research, Tübingen, Germany

C. Happold (✉) · P. Roth · M. Weller
 Department of Neurology, University Hospital Zurich,
 Frauenklinikstrasse 26, 8091 Zurich, Switzerland
 e-mail: Caroline.Happold@usz.ch

U. Ernemann
 Department of Neuroradiology, University of Tübingen Medical School, Tübingen, Germany

W. Wick
 Department of Neurooncology, University of Heidelberg,
 Heidelberg, Germany

F. Schmidt
 Department of Neurology, Technische Universität München,
 Munich, Germany

radionecrosis and all of 3 patients with myelopathy or plexopathy (1 myelopathy, 2 plexopathies). A further treatment option is hyperbaric oxygen therapy, based on the assumption that oxygen therapy induces neovascularization [6–8]. Finally, some patients with radiation-induced neurotoxicity may benefit from oral treatment with boswellic acid-containing medicines such as H15 [9]. Here we report our experience with anticoagulation using heparin or warfarin or both sequentially as an experimental treatment for delayed radiation-induced neurotoxicity.

Patients and methods

We searched the charts of the Department of Neurology from 1998 to 2007 for patients who received heparin or warfarin or both for the treatment of suspected radiation-induced injury to the nervous system. The diagnosis of radiation injury was based on clinical symptoms and signs that could not be attributed to progressive or recurrent tumor as defined by neuroimaging or to any other neurological disease. Moreover, a history of irradiation of the nervous system region affected was required. Eight patients were identified. Clinical histories, neuroimaging studies and the evolution of symptoms were reviewed.

Results

In 1998, it became practice at our institution to offer anticoagulation to patients with a tentative diagnosis of radiation-induced injury to the nervous system who had not responded to steroids and who had no contraindications for this treatment. Patient characteristics are summarized in the Table 1. There were 3 patients with cerebral lesions, one patient with cranial nerve lesions, and 4 patients with radiation-induced myelopathy. None of the patients had a biopsy of the lesion before anticoagulation was started, but the neuroradiological features were not suggestive of recurrent tumor in any patient (Fig. 1a). Neuroimaging findings were consistent with radiation injury (Fig. 2). Spectroscopy performed in one patient supported the diagnosis of radiation-induced leukencephalopathy (Fig. 1b). An unusual treatment predicted to induce radiation injury to the nervous system was only given to patient 2 who received two courses of WBRT for PCNSL. Six patients had also received chemotherapy before, during or after radiotherapy, which may have contributed to radiation injury of the nervous system. This is particularly true for patient 6 who had received multiple courses of intrathecal chemotherapy, too.

Patients 3, 4, 5, and 6 had had a prior course of steroids and had not responded. No patient was on steroids when

anticoagulation was started. No patient was newly started on steroids when anticoagulation was instituted, excluding confounding effects of steroid comedication.

Two out of three patients with cerebral lesions (patients 2 and 3) and the patient with cranial nerve lesions (patient 4) showed a minor improvement of their clinical symptoms. These patients were switched from heparin to warfarin after a few days because the minor clinical response were seen early. Patient 1 refused to continue warfarin beyond day 2. In contrast, none of the patients with radiation myelopathy improved clinically, although patient 7 showed a distinct regression on MR imaging (Fig. 3). Although this might be attributed to the anticoagulation therapy, it possibly occurred as a result of subsequent hyperbaric oxygen therapy or spontaneous recovery. Since the patient cohort reported earlier [5] included only one patient suffering radiation-induced myelopathy, the evaluation on the effects of anticoagulation on radionecrosis of the myelon is only preliminary.

Our patients 2 and 3 improved with regard to level of consciousness and hemiparesis within 3 days of the institution of anticoagulation, raising the possibility that anticoagulation was the cause for improvement. Partial remission of cranial nerve palsies took days in patient 4, rendering a causal relationship to anticoagulation more doubtful. The neurological deficits in the 4 patients with radiation myelopathy remained stable throughout the therapeutic trial of anticoagulation. No patient suffered hemorrhage or other adverse effects of anticoagulation therapy.

Discussion

The increasing use of more efficacious multimodality treatments for various types of cancer results in significant survival benefits for many patients, but has also raised awareness for therapy-related injury to the nervous system. Such lesions may often be multifactorial in origin and not only caused by irradiation, but also to chemotherapy, pre-existing comorbidities, notably diabetes and cerebrovascular disease, as well as the underlying cancer itself. Although it is often difficult to distinguish radiation injury from recurrent tumor, such patients rarely undergo a biopsy for a histological verification of radiation injury to the nervous system.

Steroids, anticoagulation [5], hyperbaric oxygen [6–8] and boswellic acids [9] have been proposed to alleviate neurological deficits associated with delayed radiation-induced neurotoxicity. Given the relative rarity of this condition and the heterogeneity of patient characteristics, it is unlikely that prospective randomized trials may ever been performed to standardize management. Moreover,

Table 1 Clinical history and course of disease

Patient	Age	Primary tumor	Radiotherapy	Chemotherapy	Symptoms and signs	Neuroimaging (MRI)	Anticoagulation	Steroids	Oxygen	Improvement	Follow-up without evidence of recurrent tumor
1	63	B-NHL 6/01	36 Gy 1/02 WBRT	CHOP 7 × 8–12/01 PCV 2 × 2–5/02	Disturbance of memory pseudoparkinsonism [13] 11/02	11/02 Leukencephalopathy	2 days of warfarin	–	–	–	Progression-free 6/04 (2 years later)
2	40	PCNSL 11/86	40.5 Gy 86 WBRT 25 Gy 2/92 stereotactic RT 45.5 Gy 10/92 WBRT	–	Cognitive impairment global aphasia right-sided hemiparesis 5/98	5/98 Leukencephalopathy	Heparin (UF) for 5 days, then warfarin 5–12/98	–	–	Improvement of level of consciousness and hemiparesis	Progression-free 2/99
3	39	Glioblastoma 11/99	54 Gy 11–12/99 36 Gy 8/00 stereotactic RT	BCNU 6 × 10/00–3/01	Progressive seizures left-sided hemiparesis 1–4/01	4/01 Contrast-enhancing cerebral lesion	Heparin (UF) for 6 days, then warfarin 4–6/01 for 8 weeks	+	–	Mild improvement of hemiparesis	Lost to follow up
4	53	Clivus chordoma 11/00	62.5 Gy 11–12/01 stereotactic RT	–	Oculomotor and lateral rectus palsy 9/07	9/07 Contrast-enhancing nerves	Heparin (UF) for 8 days, then warfarin 9–11/07 for 8 weeks	+	–	Improvement of diplopia	Progression-free 6/08
5	52	Multiple myeloma 11/99	9 Gy 3/00 whole body RT 21.6 Gy 5/00 TH 8–10	Idarubicin + dexamethasone 4 × 11/99–1/00 Busulfan + cyclophosphamide 3–4/02 Stem cell transplantation 4/02	Paresis of the left leg 8/02	8/02 Myelopathy TH 8	Heparin (UF) 5–6/02 for 4 weeks	+	–	–	Progression-free 9/02
6	59	Breast cancer 5/99	38 Gy supraclavicular region 38 Gy local breast 38 Gy left hemithorax 30 Gy 2/00 TH 9–12	FEC 6 × 5–12/99	Urinary incontinence paraplegia TH11 3/02	3/02 Myelopathy TH 9–12	Heparin (UF) for 6/02 for 1 week Tinzaparin (LMWH) 6/02 for 2 weeks	+	–	–	Progression-free 6/02
7	53	Multiple myeloma 4/96	32 Gy 5/96 TH 5–7 32 Gy 5/96 L1–S1 9 Gy 8/96 whole body RT	VAD 2 × 4/96 Cyclophosphamide 1 × 4/96 Co-interferon 4–11/01 Bendamustine 5 × 12/01–3/02	Paresis of the right leg hypesthesia 11/01	4/02 Myelopathy TH 5–6	Heparin (UF) for 4/02 for 10 days Fraxiparine (LMWH) 4–5/02 for 6 weeks	–	40 × 5–7/02	–	Distant progression 4/04 (2 years later)
8	35	T cell lymphoma 11/00	24 Gy 1–2/01 mediastinum 24 Gy 12/00–1/01 WBRT	MTX, Ara-C, thioguanine, adriamycin, etoposide, vindesine, PEG-asparaginase, cyclophosphamide, 4–11/01 intrathecal MTX, Ara-C, dexamethasone 8–11/01	Paresthesia ataxia 11/01	1/02 No lesion	Heparin (UF) 1/02 for 6 days	–	–	–	Lost to follow up

Fig. 1 (a) Sixty three year old woman presenting with disturbance of memory after WBRT with 36 Gy (patient 1). Upper row (A, axial FLAIR and post contrast T1w images) shows several lesions (black arrows) with homogenous contrast enhancement and pronounced perifocal edema representing an intracerebral lymphoma. Lower row (B, axial FLAIR and post contrast T1w images) represents a follow up examination 10 months after radiation therapy showing a pathologic signal in FLAIR images (arrow heads) in the periventricular white matter with no evidence of tumor recurrence in post contrast T1w images. (b) Patient 1: single voxel spectroscopy shows an elevated lactate peak in the periventricular white matter (white arrow), consistent with active inflammation, and strongly suggestive of radiation injury. MRI ruled out tumor recurrence

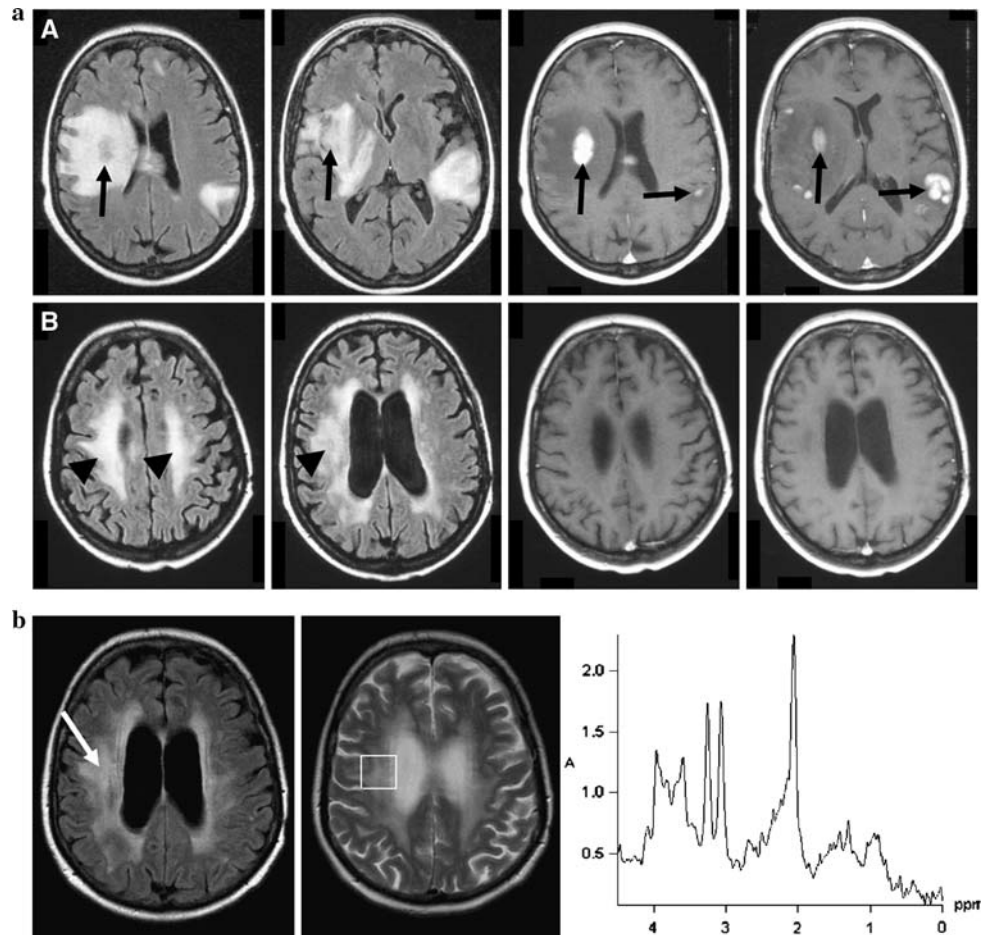
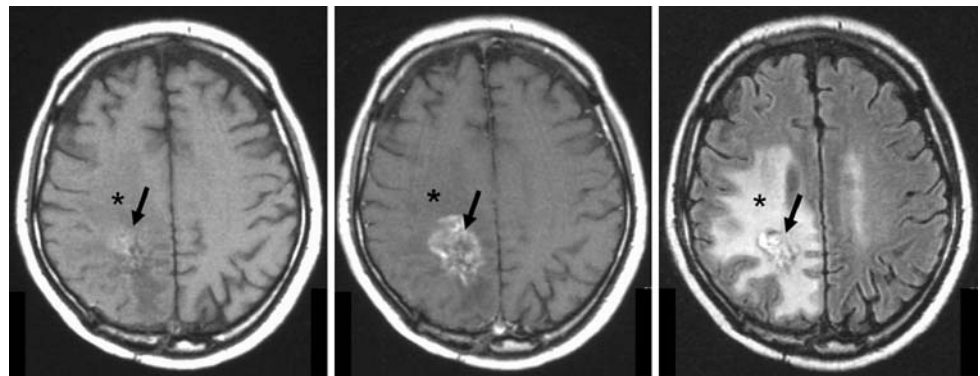


Fig. 2 Thirty nine year old man after irradiation of a glioblastoma in the right parietal lobe (patient 3). Axial T1w, contrast-enhanced T1w, and FLAIR images are presented from left to right. A star-shaped, hemorrhagic, contrast-enhancing lesion (arrow) and a large edema (asterisk), consistent with a radiation injury, can be appreciated in the right parietal lobe



there may be distinct differences in the pathogenesis of various syndromes of radiation injury. Accordingly, specific syndromes may respond differentially to treatments such as steroids, anticoagulation or hyperbaric oxygen. Steroids are considered to be effective mainly for acute and subacute radiation-induced injury to the nervous system.

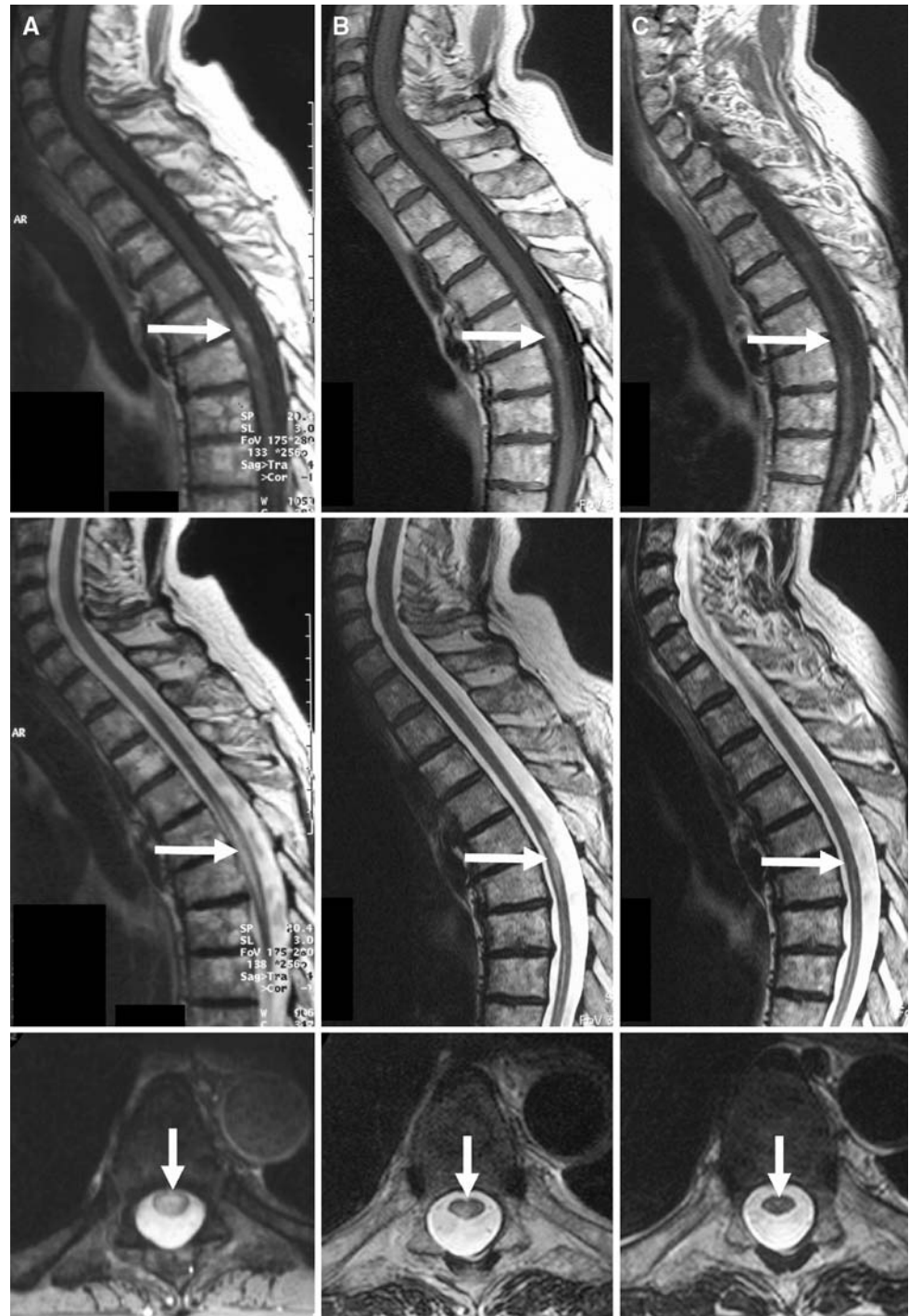No further studies on the possible beneficial role of anticoagulation have been published since 1994 [5]. The rationale of anticoagulation is based on histological observations of endothelial damage and lesions induced by

irradiation [10]. The case series reported here is only the second in the literature to assess this treatment. Patients who responded clinically to i.v. heparin did so early and were then switched to warfarin. The only patient who experienced no benefit from warfarin discontinued warfarin anticoagulation after 2 days. Thus we feel that our observations justify a short trial of up to a week of anticoagulation with i.v. heparin in patients with presumptive radiation-induced cerebral lesions whereas the lack of any change in the symptoms and signs of all 4

patients with radiation-related myelopathy is not encouraging. Moreover, all reports on the apparent beneficial effects of therapeutic interventions for radiation-associated neurotoxicity must be considered with caution in view of the variable course of such lesions which includes spontaneous recovery. For instance, it is impossible to say whether the improvement seen in patient 7 (Fig. 3) was related to heparin or hyperbaric oxygen or reflected the natural course of the lesion.

More importantly, there is an increasing awareness of pseudoprogression of tumors within the CNS as an early misleading MRI feature after focal radiotherapy. This may lead to the erroneous assumption of treatment failure and trigger false therapeutic decisions [11, 12]. In summary, the present case series demonstrates that anticoagulation therapy is safe but has probably only modest activity in patients with delayed radiation-induced neurotoxicity. Prospective studies using stringent diagnostic criteria for therapy-induced

Fig. 3 Fifty three year old man (patient 7) with multiple myeloma after spinal irradiation of Th 5–7 with 32 Gy. Sagittal, contrast-enhanced T1w (upper row), sagittal T2w (middle row), and axial T2w images (lower row) are shown. The first MRI showed a pronounced edema of the myelon at the level Th 5–9 and a significant contrast uptake (A, white arrows). Three months later, MRI showed regression with residual edema and reduced contrast uptake of the myelon at the level Th 5–6 (B, white arrows); 10 days of i.v. heparin therapy and 6 weeks of fraxiparine therapy as well as 40 administrations of hyperbaric oxygen had preceded the MRI. Follow-up 7 months after initial examination showed further improvement with only minimal residual findings (C, white arrows). Another 40 applications of hyperbaric oxygen had been administered



injury to the nervous system are required to explore in more depth the therapeutic potential of both anticoagulants and hyperbaric oxygen therapy.

References

1. Crossen JR, Garwood D, Glatstein E, Neuwelt EA (1994) Neurobehavioral sequelae of cranial irradiation in adults: a review of radiation-induced encephalopathy. *J Clin Oncol* 12:627–642
2. Schultheiss TE, Kun LE, Ang KK, Stephens LC (1995) Radiation response of the central nervous system. *Int J Radiat Oncol Biol Phys* 31:1093–1112. doi:[10.1016/0360-3016\(94\)00655-5](https://doi.org/10.1016/0360-3016(94)00655-5)
3. Behin A, Delattre JY (2004) Complications of radiation therapy on the brain and spinal cord. *Semin Neurol* 24:405–417. doi:[10.1055/s-2004-861535](https://doi.org/10.1055/s-2004-861535)
4. Rizzoli HV, Pagnanelli DM (1984) Treatment of delayed radiation necrosis of the brain: a clinical observation. *J Neurosurg* 60:589–594
5. Glantz MJ, Burger PC, Friedmann AH, Radtke RA, Massey EW, Schold SC (1994) Treatment of radiation-induced nervous system injury with heparin and warfarin. *Neurology* 44:2020–2027
6. Kohshi K, Imada H, Nomoto S, Yamaguchi R, Abe H, Yamamoto H (2003) Successful treatment of radiation-induced brain necrosis by hyperbaric oxygen therapy. *J Neurol Sci* 209:115–117. doi:[10.1016/S0022-510X\(03\)00007-8](https://doi.org/10.1016/S0022-510X(03)00007-8)
7. Feldmeier JJ (2004) Hyperbaric oxygen for delayed radiation injuries. *Undersea Hyperb Med* 31:133–145
8. Ohguri T, Imada H, Kohshi K, Kakeda S, Ohnari N, Morioka T et al (2007) Effect of prophylactic hyperbaric oxygen treatment for radiation-induced brain injury after stereotactic radiosurgery of brain metastases. *Int J Radiat Oncol Biol Phys* 67(1):248–255. doi:[10.1016/j.ijrobp.2006.08.009](https://doi.org/10.1016/j.ijrobp.2006.08.009)
9. Streffer J, Bitzer M, Schabet M, Dichgans J, Weller M (2001) Response of radiochemotherapy-associated cerebral edema to a phytotherapeutic agent, H15. *Neurology* 56:1219–1221
10. Belka C, Budach W, Kortmann RD, Bamberg M (2001) Radiation induced CNS toxicity—molecular and cellular mechanisms. *Br J Cancer* 85:1233–1239. doi:[10.1054/bjoc.2001.2100](https://doi.org/10.1054/bjoc.2001.2100)
11. De Wit MCY, De Bruin HG, Eijkenboom W, Sillevs Smitt PAE, van den Bent MJ (2004) Immediate post-radiotherapy changes in malignant glioma can mimic tumor progression. *Neurology* 63:535–537
12. Brandsma D, Stalpers L, Taal W, Sminia P, van den Bent MJ (2008) Clinical features, mechanisms, and management of pseudoprogression in malignant gliomas. *Lancet Oncol* 9:453–461. doi:[10.1016/S1470-2045\(08\)70125-6](https://doi.org/10.1016/S1470-2045(08)70125-6)
13. Wick W, Hochberg F, O’Sullivan J, Goessling A, Hughes A, Cher L (2000) L-dopa-resistant parkinsonism syndrome following cerebral radiation therapy for neoplasm. *Oncol Rep* 7:1367–1370